

# One-Year Follow-Up After Treatment of Proximal and/or Middle One-Third Humeral Shaft Fractures with a Helical Plate: Healing Rates, Complications and Functional Outcome Measures

Vincent Maes (✉ [drvincentmaes@gmail.com](mailto:drvincentmaes@gmail.com))

UZ Leuven <https://orcid.org/0000-0002-6345-1998>

Guy Putzeys

AZ Groeninge - Campus Kennedylaan: AZ Groeninge

---

## Technical advance

**Keywords:** Helical plate, diaphyseal humeral fracture, humeral shaft fracture, radial nerve palsy, functional outcome

**Posted Date:** March 17th, 2021

**DOI:** <https://doi.org/10.21203/rs.3.rs-329533/v1>

**License:** © ⓘ This work is licensed under a Creative Commons Attribution 4.0 International License.

[Read Full License](#)

---

# Abstract

**Background:** Conventional plate osteosynthesis is a valuable treatment option in displaced proximal and/or middle one-third humeral shaft fractures. Nonetheless, this procedure can be complicated by a radial nerve palsy. To date, many surgical techniques have been developed in an attempt to minimize this high-impact complication. However, a helical plate has the potential to avoid an iatrogenic radial nerve palsy due to its design. This article aims to evaluate safety and functional outcomes of patients treated with a helical plate compared to conventional plate osteosynthesis. In particular healing rates, complications and functional outcome measures.

**Methods:** We retrospectively included all patients with displaced proximal and/or middle one-third humeral shaft fractures who were treated with a helical plate from October 2016 until August 2018 at a single level-1 trauma center (AZ Groeninge, Kortrijk, Belgium). A self-molded long PHILOS plate (DePuy Synthes®) or a pre-contoured A.L.P.S proximal humeral plating system (Zimmer Biomet®) were used. Patient baseline characteristics and standard radiographs were obtained pre- and postoperatively. We retrospectively searched for complications. Patients were reassessed using the Disabilities of the Arm, Shoulder and Hand (DASH), Constant Murley (CMS) and EQ-5D-5L scores with a minimal follow-up of one year.

**Results:** The humeral shaft fractures of all sixteen patients consolidated within three months and no iatrogenic radial nerve palsies were observed. One plate had to be removed after one year due to a late infection. With a minimum follow up of one year, the mean DASH score was 22 \ 19 and the mean normalized CMS was 80 B 19.

**Conclusion:** Operative treatment of proximal and/or middle one-third humeral shaft fractures with a helical plate is a safe procedure with good to excellent shoulder function at one-year follow-up. Contrary to conventional plate osteosynthesis, a helical plate has the potential to completely avoid a radial nerve palsy, while maintaining similar healing rates and functional outcomes.

**Trial registration:** B396201939564. Registered on 6 MAY 2019 – retrospectively registred. Ethics Committee: Medical Ethics Committee, AZ Groeninge, Kortrijk, Belgium.

## Background

### 1. Introduction

Humeral shaft fractures, or diaphyseal humeral fractures, represents 1-3% of all fractures [1]. The majority, approximately 84%, consists of proximal and/or middle one-third humeral shaft fractures [1]. These fractures can be associated with a radial nerve palsy with an overall prevalence of 11,8% [2].

There is a clear bimodal distribution in mechanism of injury. A minor peak of men in the third decade presenting with a high energy trauma and a second major peak of mostly osteoporotic women in their

eight decade, having sustained a humeral shaft fracture due to a simple fall [1].

Although humeral shaft fractures are generally treated conservatively, surgery is a valuable treatment option in displaced fractures as it reduces the risk of non-union and leads to faster restoration of daily activities [3, 4]. Plate osteosynthesis is preferred to intramedullary nailing in humeral shaft fractures as the latter increases the risk of shoulder impingement, restriction of shoulder movement and need for removal of metalwork [5]. A recent meta-analysis comparing conservative versus operative treatment of humeral shaft fractures, showed a 3,5% radial nerve palsy complication in the operative treatment group [3]. However, this percentage is the result of a combination of different operative treatment modalities. For open reduction internal fixation (ORIF) specifically, iatrogenic radial nerve palsy occurred in 8,3% of patients [6]. Additionally, this can vary depending on the surgical approach used [7].

This iatrogenic high impact complication could be avoided with the use of a helical plate due to its design and corresponding surgical approach [8].

In 2002, Fernández published “The principle of helical implants”, wherein the biggest advantage of a helical implant is attributed to its ability to cover different zones in different planes of the same bone [8]. This way, the plate will cover both the lateral side of the proximal third of the humerus, avoiding the long head of the biceps, and the anterior side of the middle/distal third of the humerus, avoiding the radial nerve and deltoid insertion [8]. In other words, a helical plate has the potential to completely avoid an iatrogenic radial nerve palsy and will not compromise the anterior deltoid [8, 9].

Despite the promising concept of helical plates there is still a lack of published evidence to date regarding safety and functional outcome in proximal and/or middle-one third humeral shaft fractures.

In this clinical outcome study, we are the first to report on the use of the pre-contoured A.L.P.S proximal humeral plating system (Zimmer Biomet®) and its functional outcomes after one-year follow-up.

## 2. Objectives

To evaluate safety and functional outcomes of patients with proximal and/or middle one-third humeral shaft fractures treated with a helical plate, compared to conventional plate osteosynthesis. In particular healing rates, complications and functional outcome measures.

## Methods

Study protocols adheres to the principles outlined in the Declaration of Helsinki and were approved by the institution’s ethics committee (B396201939564). A written informed consent was obtained before reassessment for functional outcomes measures.

We retrospectively and consecutively included all patients with humeral shaft fractures who were treated by open reduction and internal fixation with a helical plate from October 2016 until August 2018 at a single level-1 trauma center (AZ Groeninge, Kortrijk, Belgium). The following patient characteristics were

obtained: age, sex, mechanism of injury, attending surgeon, type of fracture (AO/OTA classification), helical plate type and the presence of a preoperative radial nerve palsy. Two types of helical plates were used: a self-molded long PHILOS plate (DePuy Synthes®) or the pre-contoured A.L.P.S proximal humeral plating system (Zimmer Biomet®). A deltopectoral approach was used in combination with a distal anterolateral incision (including a brachial split), whether or not in continuity. Standard radiographs of the upper arm were obtained pre- and postoperatively until union was achieved.

We retrospectively searched for complications, e.g., radial nerve palsy, nonunion, infection, adhesive capsulitis, loosening or failure of osteosynthesis material.

Functional outcome measures were, after written informed consent, prospectively obtained in the Fall of 2019. We used the Disabilities of the Arm, Shoulder and Hand (DASH) score as a patient-reported functional outcome measure and Constant Murley scores (CMS) as a clinician-measured functional outcome measure. The patient's general health status was evaluated using the EQ-5D-5L score [10]. All measures were obtained by one Orthopaedic Surgery resident within one month.

Only descriptive statistical analysis was made in between groups due to the small number of patients.

## Results

Sixteen patients were treated with a helical plate between October 2016 until August 2018 at AZ Groeninge (Kortrijk, Belgium). Patient baseline characteristics can be found in *table 1*. A self-molded long PHILOS plate (DePuy Synthes®) was applied in the first nine patients, while in the last seven patients the pre-contoured A.L.P.S proximal humeral plating system (Zimmer Biomet®) was used (Fig. 1). Age distribution was between 48 and 82 years old (Fig. 2). All patients, except for one, were treated by the same surgeon. There was one delayed union and two periprosthetic fractures. Fractures were classified by the AO/OTA classification.

Table 1: Patient baseline characteristics

			Percentage %
1. Sex	Male / Female	5 / 11	31% / 69%
2. Mechanism of Injury	High energy / Simple fall (low energy)	2 / 14	13% / 87%
3. Preoperative Radial Nerve Palsy	Yes / No	2 / 14	13% / 87%
4. Fracture Type	Proximal third	7	44%
	Middle third	2	13%
	Combined proximal/middle third	5	31%
	Periprosthetic	2	13%
5. Helical Plate	Self-molded long PHILOS plate <i>2016-2017</i>	9	56%
	Pre-contoured A.L.P.S Proximal Humerus Plating System <i>2018</i>	7	44%

All fractures consolidated clinically and radiographically within three months. There were no iatrogenic radial nerve lesions. One self-molded plate was removed after one year due to a late infection. Two preoperative radial nerve palsies fully recovered in a period of 3 months. Two patients developed postoperatively an adhesive capsulitis, which were treated conservatively.

After receiving a written informed consent, twelve patients were prospectively reassessed for functional outcome measures in September 2019. At this point, one patient had died and three refused due to personal reasons. The mean DASH score is  $22 \pm 19$  and the mean CMS is  $68 \pm 18$ . Normalization of the CMS were made following Katolik L. *et al* [11]. The mean normalized CMS is  $80 \pm 19$ . These scores are displayed in Table 2 and Table 3.

Table 2  
 Follow-up time – AO/OTA classification – DASH – CMS – Normalized CMS

Case	Age	Sex	Follow-up (months)	AO/OTA Classification	DASH	CMS	Normalized CMS
1	82	M	35	12B2	13	69	78
2	80	F	31	Type A <sup>3</sup>	5	78	96
3	66	F	34	12A1	0	85	100
4	77	F	14	12C3	63	33	41
5	56	F	22	12C3	35	68	81
6	58	F	23	12B3	39	67	80
7	63	F	16	12A1	33	79	95
8	76	F	13	12A2	4	83	100
9	71	F	16	12C3	23	56	69
10	66	M	15	12A1	2	95	100
11	70	M	21	12B3	20	48	55
12	80	F	16	Type A <sup>3</sup>	24	55	68

<sup>3</sup>Periprosthetic fracture Type A (Wright and Cofield classification)

Table 3  
EQ-5D-5L score

M	S	A	P	AX	E
1	2	1	1	1	80
1	1	1	2	1	80
4	1	2	4	1	70
3	5	5	3	1	30
1	1	3	3	1	70
4	5	5	3	2	50
4	5	3	2	3	50
1	1	1	1	1	80
1	1	1	2	1	60
1	1	1	1	1	75
1	1	1	2	1	90
3	1	2	3	1	70

EQ-5D-5L score was divided into M (= Mobility), S (= Self-care), A (= Activity), P (= Pain), AX (= Anxiety) and E (= EQ VAS)

## Discussion

Operative treatment of proximal and/or middle one-third humeral shaft fractures with a helical plate is a safe procedure with a good to excellent shoulder function at one-year follow-up. Contrary to conventional surgical techniques, we did not observe any iatrogenic radial nerve palsies while maintaining similar functional outcome measures and also obtaining excellent healing rates [3].

Although most humeral shaft fractures can be treated conservatively, conventional plate osteosynthesis is the gold standard in operative treatment of displaced proximal and/or middle one-third humeral shaft fractures. As a result, anatomic reduction could be attempted so angular deformity can be corrected in order to maximize cortical contact. However, radial nerve palsy is a serious complication following conventional plate osteosynthesis [12]. A helical plate could combine the benefits of anatomic reduction while also avoiding radial nerve palsy and deltoid insertion. This is obtained by the design of the plate, covering both the lateral side of the proximal third of the humerus, avoiding the long head of the biceps, and the anterior side of the middle/distal third of the humerus, avoiding the radial nerve and deltoid insertion [8]. Klepps S. *et al*/ noted that a release of more than one fifth of the anterior deltoid insertion could compromise the anterior deltoid [9].

Three nerves are at risk in open reduction internal fixation of humeral shaft fractures, in particular the radial, axillary and musculocutaneous nerves. A radial nerve palsy can be caused by trauma (i.e. fracture) or is due to surgery. Clinically, it will present itself as a loss of sensation of the dorsal hand, as well as loss of active extension of wrist and fingers at the metacarpophalangeal joints [13]. Artico M. *et al.* outlined the surgical anatomy of the radial nerve and showed it has a consistent distance of 121 ( $\pm$  13) mm between the lateral humeral epicondyle to the lateral point of crossing the posterior aspect of the humerus [14]. Belayneh *et al.* showed no statistical differences in recovery time between nonoperative and iatrogenic radial nerve palsies [15]. Mean time to recovery of a complete palsy was 25.2 weeks, and surgical intervention did not lead to faster recovery [15]. Although management of iatrogenic radial nerve palsy is mainly conservative, sometimes late exploration is necessary if there is no spontaneous recovery at three to six months [13]. A systematic review by Shao *et al.* showed a full recovery rate of 88,1%, with a mean time to recovery of 6.1 months (range 3.4–12 mo.) [2].

Although there is a high overall recovery rate, the rehabilitation of patients is delayed with an average of six months and incomplete recovery can necessitate tendon transfers [16]. These arguments show that a radial nerve palsy is a high impact complication. One which could be completely avoided with the use of a helical plate due to its design, a benefit consistently confirmed in all case reports available [4, 17–19]. Recently, Da Silva *et al.* reported a 10-year retrospective study of 62 patients where no radial nerve damage was reported in the helical plate group [17]. This contrasts to conventional open reduction internal fixation (ORIF) where there are approximately 8,3 % iatrogenic radial nerve palsies [6]. However, this percentage can depend on the surgical approach used. Claessen *et al.* reported an iatrogenic radial nerve palsy of 22% when using a lateral approach, 4% with a anterolateral approach and 11% with a posterior approach [7]. However, a posterior approach is not suitable for fractures of proximal and combined proximal/middle humeral shaft fractures [20]. A posterior approach is well favored for distal or combined middle/distal humeral shaft fractures, due to the crossing of the radial nerve on the anterolateral aspect of the distal humerus between the brachialis and brachioradialis [20]. When using a helical plate for proximal and/or middle humeral shaft fractures, the high-risk lateral approach is not indicated anymore.

The axillary nerve, on the other hand, elongates depending on plate-bone distance. Dauwe *et al.* demonstrated on 42 fresh frozen cadaveric humeri that a helical plate significantly lowers plate-bone distance. This could imply less risk of nerve damage due to lower axillary nerve elongation [21].

Lastly, Gardner *et al.* described that the musculocutaneous nerve is most at risk when using a helical plate, due to its location on the anterior side of the middle/distal humerus. However, a 'safe zone' can be created due to a predictable and consistent anatomic location of the musculocutaneous nerve (99% CI: 12,2–18,8 cm distal from the greater tuberosity) [22].

In our study, all sixteen humeral fractures consolidated clinically and radiographically within three months. A consistency in healing rates can be found in other small case reports. Combined, all reported humeral shaft fractures in literature healed when treated with a helical plate [4, 18, 19, 23, 24]. Moreover,



Yang *et al.* recorded a 100% healing rate in ten comminuted fractures of the proximal and/or middle one-third of the humerus [23]. In traditional operative management nonunion rates range from 0–9% [5]. A systematic review of Beeres *et al.* showed a nonunion rate of 8,5% in patients treated with ORIF [6]. These excellent healing rates of a helical plate could be related to biomechanical advantages. Krishna *et al.* described that a helical plate had a better gap closure in oblique fractures, reduced stress shielding, absorbed tensile stress caused by torsion and had a higher screw-holding power due to different orientation of screws [25].

However, in self-molded plates it is known that excessive deformation during contouring will damage the locking mechanism and has an impact on the fatigue properties of the plate [25]. Controlled manufacturing of helical plates could resolve this. In this study the pre-contoured A.L.P.S proximal humeral plating system (Zimmer Biomet®) was used and we are the first to report clinical results.

We reassessed twelve patients, after written informed consent, with a minimum of one-year follow-up. Functional outcome measures were taken and calculated by the same Orthopaedic Surgery resident. All measurements were made within one month to minimize intra-observer variability. Furthermore, it is known that the CMS has a high degree of reproducibility with a low intra-observer error of 3% [26]. Normalized CMS were comparable with those reported in other case reports (80 vs. 77, 88) [18, 24]. The systematic review of van de Wall *et al.* included two randomized controlled trials, for those treated operatively a mean DASH score of 15 was reported [3]. Brunner *et al.* used a PHILOS plate in 15 humeral shaft fractures with a median CMS of 74 (56–100) and a median DASH score 34 (24–48) [27]. These results are comparable with our mean DASH score ( $22 \pm 19$ ) and our mean normalized CMS ( $80 \pm 19$ ).

It is, however, important to note some limitations. First of all, a retrospective single center study design was used with a small study population. Consequently, only descriptive statistical analysis was made in between groups.

Secondly, this study consists of inhomogeneous patient characteristics and fracture types as can be seen in *Table 1* and *Table 2*. Despite these differences, all fractures healed within three months and no radial nerve palsies were detected. On the other hand, these inhomogeneous patient characteristics can account for the large standard deviations in our functional outcome measures. Finally, functional outcome measures were taken at different follow-up times, however, a minimum of one year was respected.

## Conclusion

In conclusion, the treatment of proximal and/or middle one-third humeral shaft fractures with a helical plate is a safe procedure with good to excellent shoulder function at one-year follow-up. Contrary to conventional plate osteosynthesis, a helical plate could promote bone healing due to its biomechanical advantages, minimizes damage to the deltoid muscle insertion region and has the potential to completely avoid a radial nerve palsy. All of this facilitates rapid and good functional recovery. In the future, prospective multi-center randomized controlled studies with reasonable study population are needed to confirm this.

# Abbreviations

DASH: Disabilities of the Arm, Shoulder and Hand

CMS: Constant Murley scores

# Declarations

Ethics approval and consent to participate: Study protocols adheres to the principles outlined in the Declaration of Helsinki and were approved on 6 may 2019 by the Medical Ethics Committee, AZ Groeninge, Kortrijk, Belgium (Reference number: B396201939564). A written informed consent was obtained before reassessment for functional outcomes measures.

Consent for publication: The submitted work is original and has not been published elsewhere.

Availability of data and material: All data generated or analysed during this study are included in this published article and its supplementary information files.

Competing interest: The authors have no conflicts of interest to declare that are relevant to the content of this article.

Funding: No funds were received in support of this work.

Authors' contribution: All authors contributed to the study conception and design. Material preparation, data collection and analysis were made by VM. The first draft of the manuscript was written by VM and all authors commented on previous versions of the manuscript. All authors read and approved the final manuscript.

Acknowledgements: I would like to thank AZ Groeninge and Sarah Naessens for the smooth and pleasant cooperation.

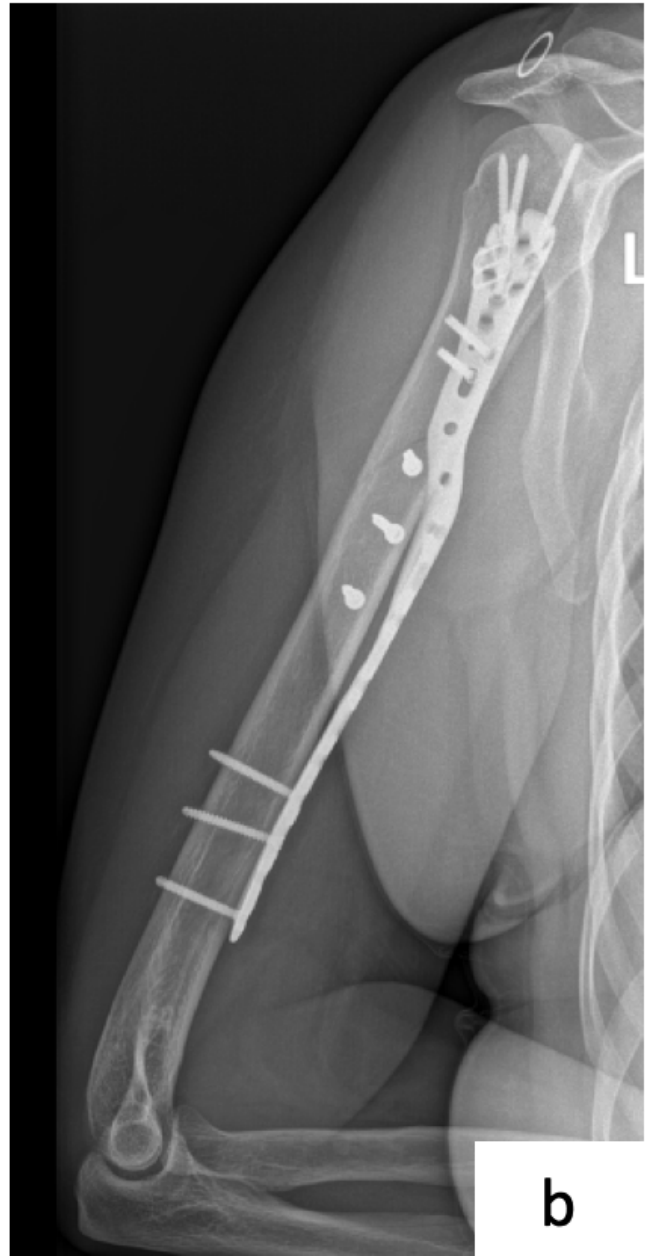
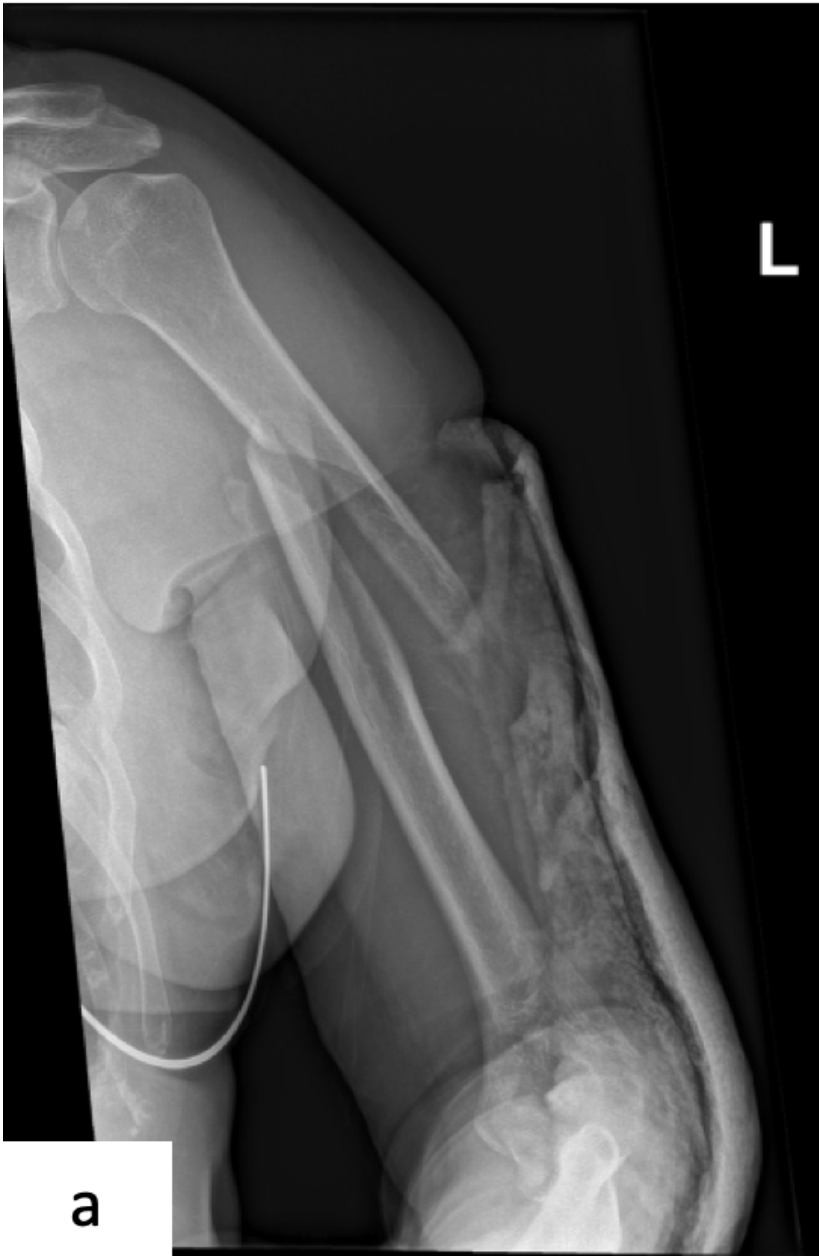# References

1. Ekholm R, Adami J, Tidermark J, et al. Fractures of the shaft of the humerus. An epidemiological study of 401 fractures. *J Bone Jt Surg - Ser B*. 2006;88:1469–73.
2. Shao YC, Harwood P, Grotz MRW, et al. Radial nerve palsy associated with fractures of the shaft of the humerus. A systematic review. *J Bone Jt Surg - Ser B*. 2005;87:1647–52.
3. van de Wall BJM, Ochen Y, Beeres FJP, et al. Conservative vs. operative treatment for humeral shaft fractures: a meta-analysis and systematic review of randomized clinical trials and observational studies. *J Shoulder Elb Surg*. 2020;29:1493–504.
4. Zhang L, Chen L-W, Zhang W-J, et al. Treatment of proximal and middle one-third humeral fractures with lateral distal tibial helical plate. *Eur J Orthop Surg Traumatol*. 2012;22:673–9.

5. Kurup H, Hossain M, Andrew JG. Dynamic compression plating versus locked intramedullary nailing for humeral shaft fractures in adults. *Cochrane Database Syst Rev*. Epub ahead of print 2011. DOI: 10.1002/14651858.cd005959.pub2.
6. Beeres FJ, Diwersi N, Houwert MR, et al. ORIF versus MIPO for humeral shaft fractures: a meta-analysis and systematic review of randomized clinical trials and observational studies. *Injury*. Epub ahead of print 2020. DOI: 10.1016/j.injury.2020.11.016.
7. Claessen FMAP, Peters RM, Verbeek DO, et al. Factors associated with radial nerve palsy after operative treatment of diaphyseal humeral shaft fractures. *J Shoulder Elb Surg*. 2015;24:e307–11.
8. Fernández Dell'Oca AA. The principle of helical implants. Unusual ideas worth considering. *Injury*. 2002;33(Suppl 1):A1–27.
9. Klepps S, Auerbach J, Calhoun O, et al. A cadaveric study on the anatomy of the deltoid insertion and its relationship to the deltopectoral approach to the proximal humerus. *J Shoulder Elb Surg*. 2004;13:322–7.
10. Nowak LL, Davis AM, Mamdani M, et al. A Systematic Review and Standardized Comparison of Available Evidence for Outcome Measures Used to Evaluate Proximal Humerus Fracture Patients. *J Orthop Trauma*. 2019;33:e256–62.
11. Katolik LI, Romeo AA, Cole BJ, et al. Normalization of the Constant score. *J Shoulder Elb Surg*. 2005;14:279–85.
12. Nowak LL, Dehghan N, McKee MD, et al. Plate fixation for management of humerus fractures. *Injury*. 2018;49:33–8.
13. Niver GE, Ilyas AM. Management of radial nerve palsy following fractures of the humerus. *Orthop Clin North Am*. 2013;44:419–24.
14. Artico M, Telera S, Tiengo C, et al. Surgical anatomy of the radial nerve at the elbow. *Surg Radiol Anat*. 2009;31:101–6.
15. Belayneh R, Lott A, Haglin J, et al. Final outcomes of radial nerve palsy associated with humeral shaft fracture and nonunion. *J Orthop Traumatol*; 20. Epub ahead of print 2019. DOI: 10.1186/s10195-019-0526-2.
16. Ekholm R, Ponzer S, Törnkvist H, et al. Primary radial nerve palsy in patients with acute humeral shaft fractures. *J Orthop Trauma*. 2008;22:408–14.
17. Da Silva T, Rummel F, Knop C, et al. Comparing iatrogenic radial nerve lesions in humeral shaft fractures treated with helical or straight PHILOS plates: a 10-year retrospective cohort study of 62 cases. *Arch Orthop Trauma Surg*. Epub ahead of print 2020. DOI: 10.1007/s00402-020-03438-y.
18. Wang Q, Hu J, Guan J, et al. Proximal third humeral shaft fractures fixed with long helical PHILOS plates in elderly patients: benefit of pre-contouring plates on a 3D-printed model—a retrospective study. *J Orthop Surg Res*. 2018;13:203.
19. Chung J, Tan H, Husain F, et al. Minimally Invasive Helical Plating for Shaft of Humerus Fractures: Technique and Outcome. *Open Orthop J*. 2012;6:184–8.

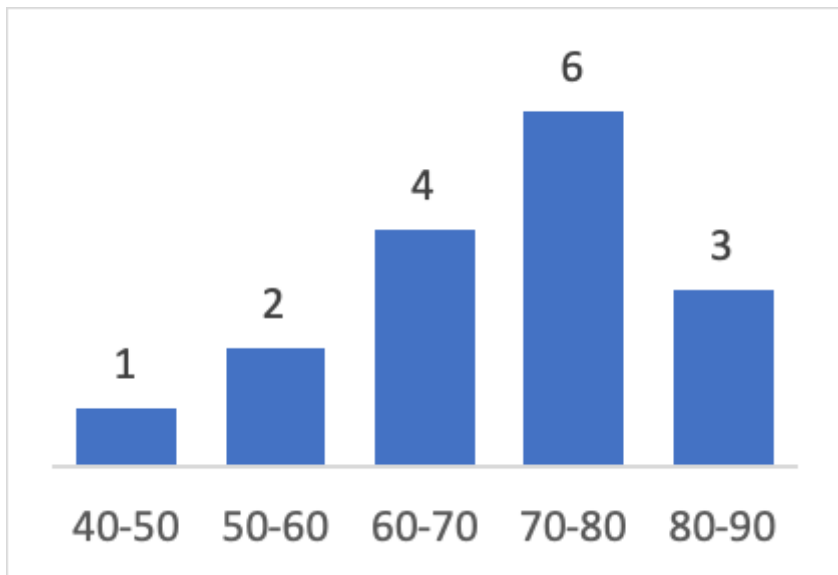
20. Hoppenfeld S, de Boer P, Buckley R. *Surgical Exposures in Orthopaedics: The Anatomic Approach. Fifth Edition.* 2016.
21. Dauwe J, Grechenig P, Unterfrauner I, et al. Axillary nerve elongation in humeral fracture plating: A cadaveric study for comparison between straight and helical Philos plates. *J Orthop.* 2020;19:233–6.
22. Gardner MJ, Griffith MH, Lorich DG. Helical plating of the proximal humerus. *Injury.* 2005;36:1197–200.
23. Yang KH. Helical plate fixation for treatment of comminuted fractures of the proximal and middle one-third of the humerus. *Injury.* 2005;36:75–80.
24. Moon J-G, Kwon H-N, Biraris S, et al. Minimally Invasive Plate Osteosynthesis Using a Helical Plate for Metadiaphyseal Complex Fractures of the Proximal Humerus. *Orthopedics.* 2014;37:e237–43.
25. Krishna KR, Sridhar I, Ghista DN. Analysis of the helical plate for bone fracture fixation. *Injury.* 2008;39:1421–36.
26. Constant CR, Murley AH. A clinical method of functional assessment of the shoulder. *Clin Orthop Relat Res* 1987; 160–164.
27. Brunner A, Thormann S, Babst R. Minimally invasive percutaneous plating of proximal humeral shaft fractures with the Proximal Humerus Internal Locking System (PHILOS). *J Shoulder Elb Surg.* 2012;21:1056–63.

## Figures



**Figure 1**

Example pre-contoured helical plate a. Preoperative spiral humeral fracture (12A1) b. Postoperative A.L.P.S. proximal humeral plating system



**Figure 2**

Age distribution of patient population