

Individualized Laparoscopic Surgery for UPJO Patients with Crossing Vessels

Bobin Ning

Chinese PLA General Hospital

Shuqi Du (✉ 1563105@sntcm.edu.cn)

The First Affiliated Hospital of China Medical University

Research article

Keywords: UPJO, crossing vessels, laparoscopy, pyeloplasty

Posted Date: March 22nd, 2021

DOI: <https://doi.org/10.21203/rs.3.rs-329173/v1>

License:   This work is licensed under a Creative Commons Attribution 4.0 International License.

[Read Full License](#)

Abstract

Background: To characterize the anatomical subtypes of ureteropelvic junction obstruction (UPJO) caused by crossing vessels (CVs) and demonstrate the Individualized operation procedures for these cases.

Methods: From March 2015 to July 2019, 51 consecutive adult patients underwent treatment of primary UPJO via a retroperitoneal laparoscopic approach. The clinical data, iconography inspection results, and surgical procedures for each patient were retrospectively reviewed by our team. The diagnosis of etiological CV was confirmed during the operation in 13 patients (25.49%), which included 7 men and 6 women.

Results: The mean surgical age was 30 ± 11.66 years. The operating time was approximately 233 ± 62.76 minutes, and there were one open conversions. In the follow-up period (mean, 27.23 ± 15.46 months), all patients had a full recovery in the CV group. However, 3 patients without CV did not completely recover from uronephrosis, as determined on iconography inspection, and there was no improvement in the renal colic symptoms. In the CV group, none of the patients had lithiasis whereas 25% of the patients without CV had lithiasis.

Conclusion: CV accounts for approximately 25.49% of the UPJO cases. Based on the anatomical position of the UPJ and CVs, we identified two types of abnormalities, and 84.62% of the CVs were located anterior to the UPJ. The retroperitoneal approach for treating CVs had particular advantages. A comprehensive understanding and intraoperative analysis of the anastomosis between the CVs and UPJ is crucial for at least 4 individual treatments. After dismembered pyeloplasty, suspension of the CVs is recommended in approximately 40% of the cases. The follow-up showed good prognosis in the long term.

Background

Laparoscopic pyeloplasty was first described in 1993 by Schuessler, and since then, it has largely replaced endopyelotomy or open pyeloplasty. It has been adopted as a feasible and reliable treatment for patients with ureteropelvic junction obstruction (UPJO) in the last two decades^[1, 2]. Laparoscopic pyeloplasty has greater than 90% success rates, and the outcomes of this procedure are equivalent to open pyeloplasty^[3]. The advantages of this technique include short convalescence, less usage of analgesic drugs, decreased postoperative pain, low morbidity, short hospital stay, and improved cosmesis^[4, 5].

The etiology of UPJO is heterogeneous, including intrinsic disorganization and/or extrinsic compression^[6, 7]. Moreover, the extrinsic obstruction usually refers to the presence of aberrant lower pole crossing vessels (CVs), fibrous band adhesions, or kinks in a normal caliber UPJ^[2]. The incidence of extrinsic UPJO by CVs was reported to be 38–71%^[8–10]. In the case of long-term endopyelotomy, the presence of CVs

was concurrent with a decrease in the success rate from 82–33%^[11]. This suggests that CVs play an important role in the prognosis of UPJO.

The conventional technique chosen by most urologists for the treatment of UPJO caused by pyeloureteral segment, stenosis, renal pelvis volume, or a possible extrinsic compression, was classical Anderson-Hynes (AH) plasty with dorsal relocation of the vessel. However, cases of failed vascular hitch and redo surgery with dismembered pyeloplasty or endopyelotomy have been described^[2, 8, 11]. Depending on the anatomic situation, the new reanastomosis and CVs are not always stress-free^[12]. The management of the CVs during laparoscopic pyeloplasty has become controversial and specific, such as the division, transposition, and suspension of the CVs and the treatment of the relative UPJ.

Currently, there is little evidence in the literature that discusses the different procedures that should be used by urologists when faced with anatomic variability in the association between the renal pelvis and the CVs. Therefore, to aid in the determination of the correct procedure for a given case, we collected and reviewed our cases as well as those in the literature that focused on the treatment of lower pole vessels. We have characterized the anatomical subtypes of UPJO caused by etiological CV and demonstrated the potential operation procedures for these cases.

Methods

Patients

A total of 51 patients with UPJO underwent retroperitoneal laparoscopic dismembered AH pyeloplasty consecutively at our hospital between 2015 and 2019. We collected the characteristics of the patients including age at surgery, preoperative imaging results, operative time, need for conversion, length of hospital stay, need for drainage, and postoperative complications (Table 1). Each patient was evaluated preoperatively with routine blood tests, renal function, urinalysis, diuretic renography, ultrasound, and abdominal computed tomography CT. The diagnosis of UPJO was based on medical history, clinical symptom, and imaging examination. In addition, we conducted angio-CT to evaluate the presence of CVs prior to surgery. There were 13 patients (25.49%) who had a pathogenic CV that compressed the UPJ, causing a potential obstruction, 7 of whom underwent a classic dismembered pyeloplasty (DP) with or without CVs' transposition, and 4 underwent DP with further treatment for CVs.

Table 1
Patients and surgical demographics based upon the presence or absence of a crossing vessel found at the time of surgery.

	Crossing Vessel present	Crossing Vessel absent	P
No. of patients	13	38	-
Average age at surgery (years)	30(\pm 11.66)	31(\pm 11.98)	-
Male/Female	6/7	20/18	-
Side (L/R)	6/7	25/13	-
Lithiasis	0	13	0.01456
Operative time (mins)	233.58(\pm 62.76)	197.85(\pm 60.72)	-
Open conversions		1	-
Hospital stay (days)	8.85(\pm 2.51)	8.49(\pm 3.86)	-
Complication rate	7.69%	5.56%	-
Follow-up (months)	27.23(\pm 15.46)	26.43(\pm 12.53)	-
Success rate	100%	92.1%	-

Surgical Procedure

After general anesthesia, all patients underwent retroperitoneal laparoscopic surgery. Subsequently, the surrounding tissues were meticulously separated, and the CVs were isolated. The vein was routinely clipped and divided. According to anatomical criteria, in cases with the posterior crossing artery, an AH procedure was performed after the CVs were suspended to the psoas muscle with a 3 – 0 suture. In the case of anterior CVs, the patients were selected for different techniques depending on the findings during the procedure. First, AH pyeloplasty with or without translocation of the artery was performed. In the absence of compression, further maneuver was not needed. However, if the CVs compressed the UPJ to a certain degree even after relocation, the CVs were suspended anterior to the pelvis or posterior to the psoas at least 1 cm away from the anastomosis with a 3 – 0 suture. In case the suspension of CVs did not give satisfactory results, we transected the CVs.

The outcome was assessed during the follow-up period of 3 months after the surgery. The patients were evaluated by ultrasound and for pain 6 months after the surgery. Radiological follow-up was continued yearly with CT. Success was defined as 80% or greater pain relief according to the VAS score, no sign of obstruction on IVU (patent UPJ), decreasing excretion curve with T1/2 < 12 min, and improved or stable differential renal function on DR.

Statistical analysis

For statistical analysis, Chi-square test and Fisher's exact test were used to compare categorical values. The independent samples t-test was used to compare numerical variables. A p value of < 0.05 was considered statistically significant.

Results

Among the 51 consecutive patients, 13 patients (25.49%) had CVs during the surgery, including 7 men and 6 women. The average age of patients was 30 and 31 years for group 1 and group 2, respectively. The success rate was 92.1% and 100% for group 1 and group 2, respectively. Mean operating time was 197.85 minutes and 233.58 minutes for group 1 and group 2, respectively. All clinical data between the two groups were statistically different, except for a higher incidence of lithiasis in the patients without CVs than in those with CVs (Table 1). One patient finally converted to open surgery to avoid the cumbersome procedure. The mean hospital stay after surgery was 8.49 and 8.85 days for group 1 and group 2, respectively. In the post-operative time, the patients in group 1 had three complications including fever, perirenal effusion, and shedding of the double-J stent. In addition, group 2 had one patient with a fever. During the follow-up period, the subjective feelings of the patients, renal ultrasound at 3 months, and IVU and diuretic renogram at least 6 months after surgery showed 3 patients in the control group with evidence of obstruction. However, all patients with CVs had a substantial renal functional recovery with improvement in hydronephrosis (Fig. 1A, B, C, D). The preoperative data and success rate between the two groups was statistically insignificant.

According to the intraoperative anatomical relationship between the CVs, the renal pelvis, the UPJ, and the ureter in the cases that we reviewed, we mainly distinguished two different types, the anterior and posterior CVs groups, and this is illustrated in Table 2. The hydronephrosis between the two groups was statistically significant. The patients with anterior CV usually had more severe hydronephrosis than those with posterior CVs. To ensure that there is no pressure between the CVs and reanastomosis after the operation, we further summarized at least five surgical schemes for the first anatomical position. Meanwhile, there was possibly only one best solution for the second anatomical type.

Table 2
Clinical and surgical characteristics of UPJO patients with CVs

	Anterior crossing vessel	Posterior crossing vessel	P
No. of patients	11	2	-
Average age at surgery (years)	30(\pm 12.11)	26(\pm 11.31)	-
Male/Female	4/7	2/0	-
Side (L/R)	5/6	1/1	-
Patients according to degree of hydronephrosis (N.)			
Grade 1 ~ 2	1	2	0.0385
Grade 3 ~ 4	10	0	
Surgical treatment of crossing vessel	No more procedure:7, suspend the crossing vessel on the wall of the renal pelvis or psoas:3, dividend the crossing vesssl:1.	Suspend the crossing vessel on the psoas:1.	-
Surgical time (mins)	239(\pm 67.48)	203(\pm 9.90)	-
Hospital stay (days)	8.55(\pm 1.69)	10.5(\pm 6.36)	-
Follow-up (months)	29(\pm 16.19)	17.5(\pm 4.95)	-

Type 1. When the vessels are placed in front of the UPJ.

A. After DP, there is no pressure against the UPJ or the reanastomosis: no further treatment was necessary.

B. After DP and relocation of CVs, there is no pressure against the UPJ or the reanastomosis: no further treatment was necessary.

C. CVs located in front of the UPJ can obtain a pressure-free position, but they may still exert pressure on UPJ: the CVs were suspended on the renal pelvis.

D. CVs located behind the UPJ can obtain a pressure-free position, but they may still exert pressure on UPJ: the CVs were transferred to the posterior of UPJ and fixed on the psoas.

E. No satisfactory anatomical relationship between the CV and UPJ could be obtained: the CV was transected.

Type 2. The vessels were placed behind the UPJ: the CVs were suspended on the psoas.

Discussion

In the past few decades, there have been controversies whether the ectopic blood vessels is the main cause of UPJO. Due to the development of minimally invasive urological techniques, a more comprehensive understanding has been proposed by urologists regarding the etiology heterotopic perirenal vessels. Although some experts believe that the CVs may not always exert pressure on the UPJ, the decrease in the success rate of endoscopic treatment due to heterotopic blood vessels and the success of the Hellström technique confirm the importance of the heterotopic blood vessels in UPJO surgery. Leavitt et al. reported that the CVs accounted for approximately 22.7% of 601 UPJO cases. Further, they summarized six different deplaning positions between the UPJ and CVs, of which the probability of the CVs compressing the UPJ from the posterior position was 7.4%^[13]. These results are consistent with the data obtained in our study (Table 1).

Although routine transposition of CVs during laparoscopic AH plasty is the gold standard for treating UPJO patients with CVs, an increasing number of urologists are questioning the validity of this traditional method. Szydelko T and Ng CS reported that the traditional dorsal transposition of the vessel would not necessarily create a tension-free anastomosis, a better planing structure may be obtained with its cephalad translocation^[14, 15]. Further, Janetschek G et al. claimed that dorsal displacement of the CVs may worsen the anatomic conditions^[16]. In a multi-center study, Chiarenza SF et al. suggest that carefully selected patients with CVs could be treated with vascular surgery^[17]. A systematic description of three types of patients according to the different locations of UPJ and ventral CVs were summarized by A. Schneider et al. They suggested that AH pyeloplasty should be performed when the CVs are present anterior to the dilated pelvis or the UPJ with intrinsic stenosis site, while vascular suspension should be performed when the vessels are present posterior to the UPJ, resulting in ureteral kinking^[18].

Although the current procedure of transposing, fixing, and suspending the CVs is controversial, the consensus among experts is that after careful dissection during the operation, further selection is made on the basis of the etiology of the CVs, endogenous obstruction, laparoscopic approach, relationship with the surrounding tissues, such as the UPJ, and the potential for obstruction^[12, 15, 19, 20]. In our study, the techniques were selected according to the anatomy between UPJ and CVs. Some experts believe that transposition facilitates anastomosis in the transperitoneal approach, and it can provide better anterior access to the renal pelvis and renal CVs^[21, 22]. In contrast, we believe that the posterior approach can provide us with a clear understanding of whether the CVs exert pressure on the UPJ because the position of the CVs and UPJ is not affected during the surgery with the posterior approach. Moreover, we found

that the degree of hydronephrosis for the dorsal CVs was relatively mild compared to that for the anterior CVs (Table 2). In the case of posteriorly located CVs, they can be suspended on the psoas muscle without affecting the subsequent operation (Fig. 2C, D).

As described previously, besides AH pyeloplasty, the tension-free renal pelvis and ureteral reanastomosis after the operation is an important aspect^[12]. Zeltser IS et al. showed that CVs located within 5–6 mm of the ureteropelvic junction can cause a problem^[23]. Boylu U et al. considered that transposition was performed when the anastomosis after mobilization was less than 1 cm from the CVs^[12]. We suggest that the distance between the CVs and the new anastomosis should be at least 1 cm based on the changes in position during and after the operation. Therefore, according to the relationship between the new anastomosis and CVs after pyeloplasty, we have further divided treatment of the CVs into the following five individual procedures. When there is no pressure on the anastomotic site after pyeloplasty or transposition of CVs to the posterior side, we do not provide any further treatment. When the location of the CV is too close to the new anastomosis, we consider suspending the CV anterior to the pelvis or posterior to the psoas major muscle (Fig. 2A, B). If none of the above methods meet our requirements, we may consider transecting the vessel. Kelly cut the vessels using laparoscope in 2 cases with clinical improvement and without hypertension^[24]. We had a similar case in this study, and the postoperative outcome was commendable during the follow-up. In conclusion, the final decision was made by the surgeon after visualization and tactile sensation of the new association between the renal pelvis, ureter, and CV in each individual.

The limitations of this study are the small sample size, the subjective judgment of intrinsic pathogeny, and the possibility of complex and rare vascular anatomic position. Further studies will be carried out to validate our classification through intraoperative opacification and postoperative pathological examination and confirm the intrinsic stenosis. A prospective and multicentric study will be conducted with increased sample size. A comprehensive evaluation of the relationships between blood vessels and UPJ according to the individual situation is necessary to provide the appropriate treatment plan.

Conclusion

CVs compression is one of the common causes of ureteropelvic junction obstruction. The degree of pressure on UPJ varies significantly with each anatomical type. Our experience suggests that AH pyeloplasty should be performed first. Further, there are at least 2 anatomical subtypes. For the treatment of CVs, a comprehensive scheme should be adopted: Type I have 4 individual treatments for specific patients to attain an ideal anatomy after surgery; Type II should be suspended on the posterior psoas, to keep it away from the UPJ anastomosis and facilitate further operation; in rare cases the blood vessels should be transected. However, the general principle is a comprehensive judgment and individualized program; the only overall purpose is to keep the vessels away from the UPJ and not to continue to produce compression.

Abbreviations

UPJO

ureteropelvic junction obstruction

CV

crossing vessel

A-H plasty

Anderson-Hynes plasty

DP

dismembered pyeloplasty

Declarations

- Ethics approval and consent to participate

The data covered in this article were reviewed by the The First Affiliated Hospital of China Medical University Ethics Clerks Association and informed consent was obtained from patients before the procedure.

- Consent to publish

The images are entirely unidentifiable and there are no details on individuals reported within the manuscript.

- Availability of data and materials

The datasets used and/or analysed during the current study are available from the corresponding author on reasonable request.

- Competing interests

The author declares that they have no competing interests.

- Funding

Not applicable.

- Authors' Contributions

SD have made substantial contributions to the conception, and design the work.

BN have made the acquisition and analysis of the data. Both authors have drafted the work or substantively revised it.

- Acknowledgements

Not applicable.

References

1. Schuessler WW, Grune MT, Tecuanhuey LV, Preminger GM. Laparoscopic dismembered pyeloplasty. *J Urol*. 1993;150(6):1795–9.
2. Khan F, Ahmed K, Lee N, Challacombe B, Khan MS, Dasgupta P. Management of ureteropelvic junction obstruction in adults. *Nat Rev Urol*. 2014;11(11):629–38.
3. Ahmed K, Jawad M, Abboudi M, et al. Effectiveness of procedural simulation in urology: a systematic review. *J Urol*. 2011;186(1):26–34.
4. Jarrett TW, Chan DY, Charambura TC, Fugita O, Kavoussi LR. Laparoscopic pyeloplasty: the first 100 cases. *J Urol*. 2002;167(3):1253–6.
5. Soulié M, Thoulouzan M, Seguin P, et al. Retroperitoneal laparoscopic versus open pyeloplasty with a minimal incision: comparison of two surgical approaches. *Urology*. 2001;57(3):443–7.
6. Cohen B, Goldman SM, Kopilnick M, Khurana AV, Salik JO. Ureteropelvic junction obstruction: its occurrence in 3 members of a single family. *J Urol*. 1978;120(3):361–4.
7. Thomas AK, June CH. The promise of T-lymphocyte immunotherapy for the treatment of malignant disease. *Cancer J*. 2001;7(Suppl 2):67–75.
8. Nakada SY, Wolf JS, Brink JA, et al. Retrospective analysis of the effect of crossing vessels on successful retrograde endopyelotomy outcomes using spiral computerized tomography angiography. *J Urol*. 1998;159(1):62–5.
9. Sampaio FJ. Vascular anatomy at the ureteropelvic junction. *Urol Clin North Am*. 1998;25(2):251–8.
10. Gupta M, Smith AD. Crossing vessels. Endourologic implications. *Urol Clin North Am*. 1998;25(2):289–93.
11. Van Cangh PJ, Nesa S, Galeon M, et al. Vessels around the ureteropelvic junction: significance and imaging by conventional radiology. *J Endourol*. 1996;10(2):111–9.
12. Boylu U, Oommen M, Lee BR, Thomas R. Ureteropelvic junction obstruction secondary to crossing vessels-to transpose or not? The robotic experience. *J Urol*. 2009;181(4):1751–5.
13. Leavitt DA, Nicholson AF, Ortiz-Alvarado O, et al. Nature of crossing vessels in patients with radiographically normal ureteropelvic junctions: prevalence and anatomic characteristics. *Urology*. 2013;81(6):1168–72.
14. Szydelko T, Apoznanski W, Koleda P, Rusiecki L, Janczak D. Laparoscopic pyeloplasty with cephalad translocation of the crossing vessel - a new approach to the Hellström technique. *Wideochir Inne Tech Maloinwazyjne*. 2015;10(1):25–9.
15. Ng CS, Gill IS, Ramani AP, et al. Transperitoneal versus retroperitoneal laparoscopic partial nephrectomy: patient selection and perioperative outcomes. *J Urol*. 2005;174(3):846–9.
16. Janetschek G, Peschel R, Frauscher F, Franscher F. Laparoscopic pyeloplasty. *Urol Clin North Am*. 2000;27(4):695–704.

17. Chiarenza SF, Blevé C, Caione P, et al. Minimally Invasive Treatment of Pediatric Extrinsic Ureteropelvic Junction Obstruction by Crossing Polar Vessels: Is Vascular Hitching a Definitive Solution? Report of a Multicenter Survey. *J Laparoendosc Adv Surg Tech A*. 2017;27(9):965–71.
18. Schneider A, Ferreira CG, Delay C, Lacreuse I, Moog R, Becmeur F. Lower pole vessels in children with pelviureteric junction obstruction: laparoscopic vascular hitch or dismembered pyeloplasty. *J Pediatr Urol*. 2013;9(4):419–23.
19. Canes D, Desai MM, Haber GP, et al. Is routine transposition of anterior crossing vessels during laparoscopic dismembered pyeloplasty necessary. *J Endourol*. 2009;23(3):469–73.
20. Amón SJH, Delgado MC, de la Cruz Martín B, Serrano MR, Mainez RJA, Tapia HAM. Laparoscopic Pyeloplasty: Always Dismembered. *J Endourol*. 2016;30(7):778–82.
21. Mitre AI, Brito AH, Srougi M. Laparoscopic dismembered pyeloplasty in 47 cases. *Clinics (Sao Paulo)*. 2008. 63(5): 631–6.
22. Gundeti MS, Reynolds WS, Duffy PG, Mushtaq I. Further experience with the vascular hitch (laparoscopic transposition of lower pole crossing vessels): an alternate treatment for pediatric ureterovascular ureteropelvic junction obstruction. *J Urol*. 2008;180(4 Suppl):1832–6. discussion 1836.
23. Zeltser IS, Liu JB, Bagley DH. The incidence of crossing vessels in patients with normal ureteropelvic junction examined with endoluminal ultrasound. *J Urol*. 2004;172(6 Pt 1):2304–7.
24. Poulakis V, Witzsch U, Schultheiss D, Rathert P, Becht E. [History of ureteropelvic junction obstruction repair (pyeloplasty). From Trendelenburg (1886) to the present]. *Urologe A*. 2004;43(12):1544–59.

Figures

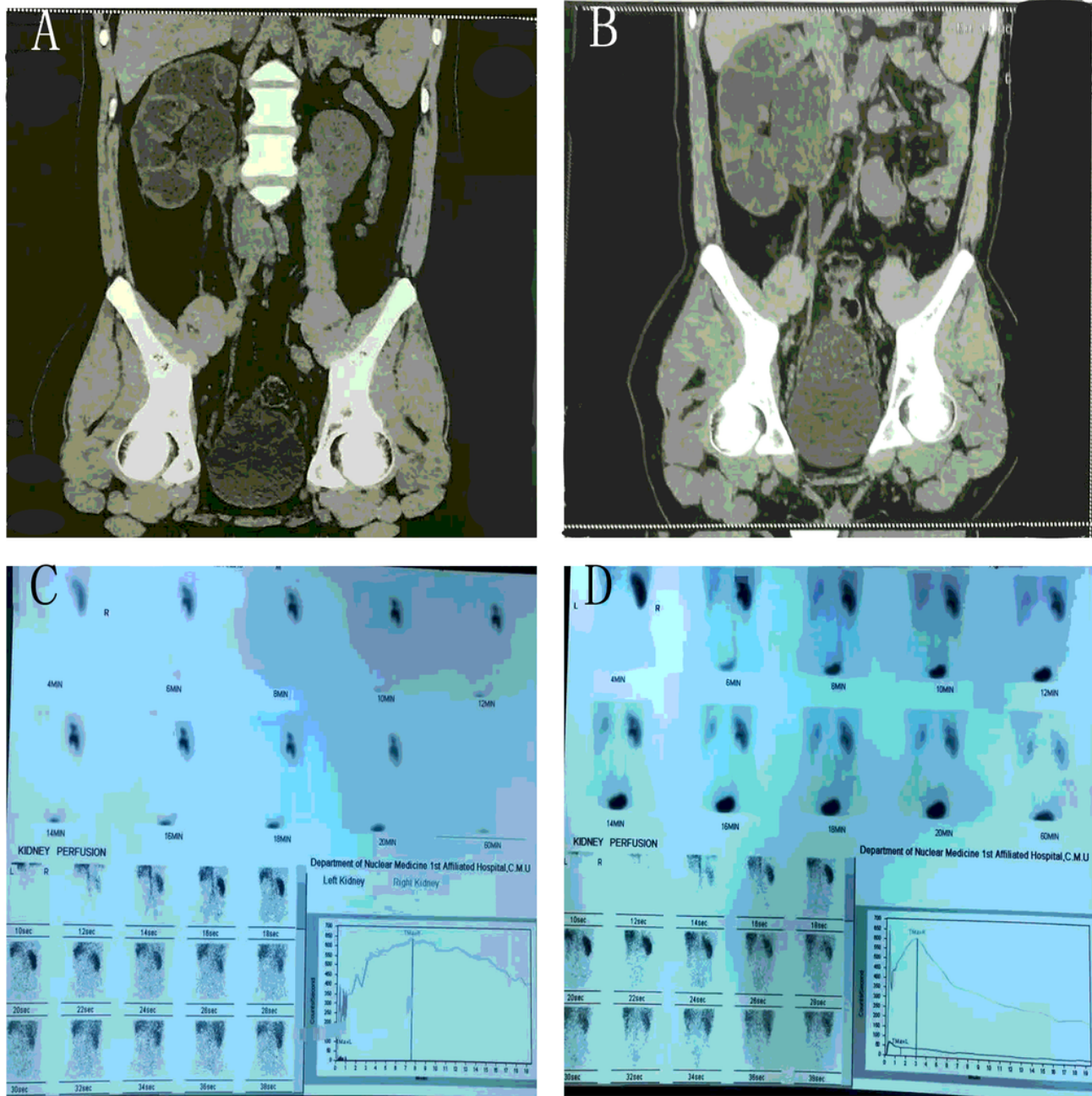


Figure 1

A. Pre-operative CTU of a female patient. On the left side, a ureteropelvic junction obstruction, clear hydronephrosis in the pelvis, and enlarged renal pelvis is observed. B. Post-operative CTU of the female patient. A reduced pelvis and no hydronephrosis can be observed on the left side. C. Pre-operative left kidney perfusion of a male patient. D. Post-operative left kidney perfusion of a male patient.

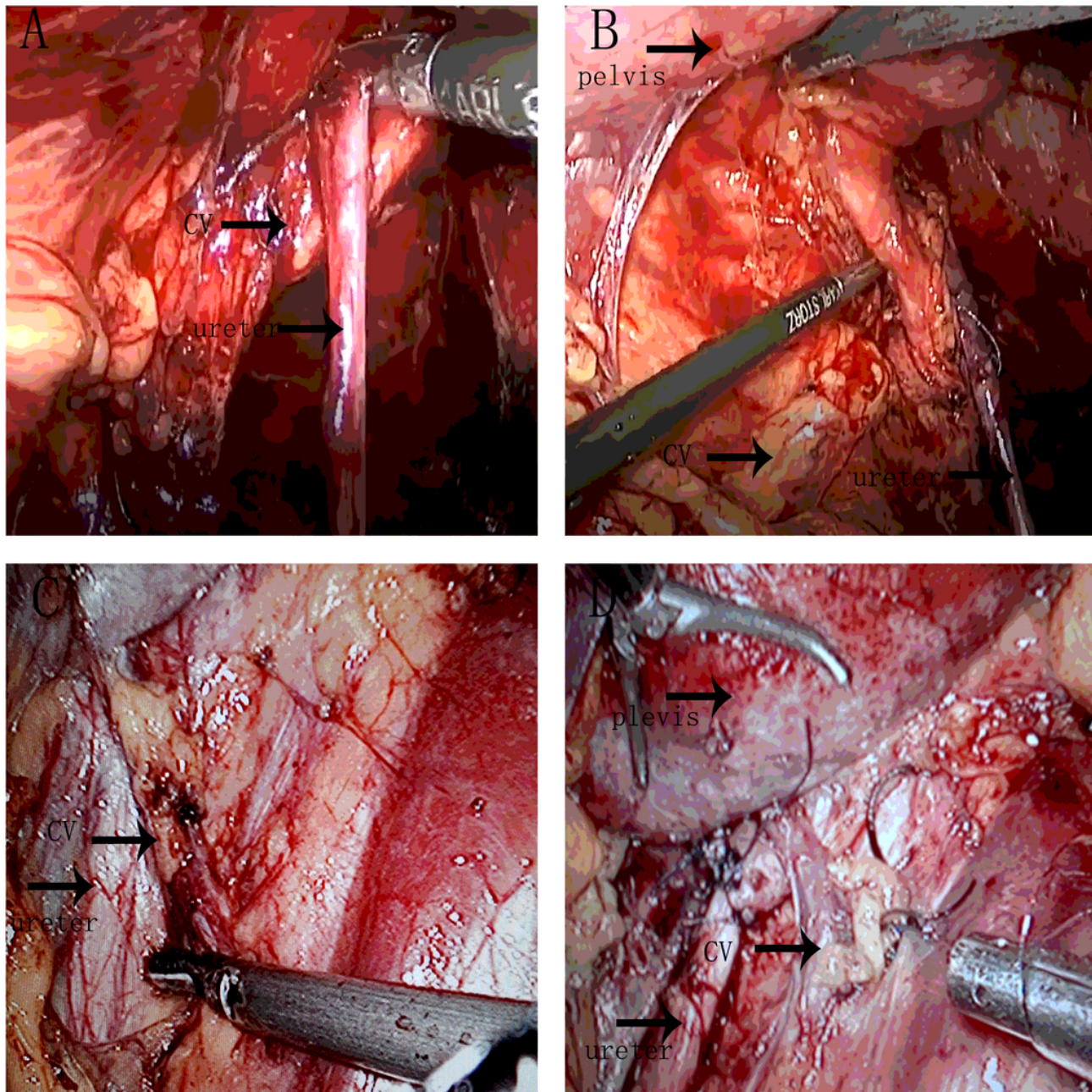


Figure 2

A. Dilated pelvis because of the anteriorly crossing artery in the lower pole of the kidney. B. New anatomical relationship of the ureteropelvic junction and the crossing vessel. Improved dilation of the pelvis after posterior relocation of the crossing artery. C. Dilated pelvis because of the posteriorly crossing artery in the lower pole of the kidney. D. The crossing vessel is relocated on the wall of the psoas; improved dilation of the pelvis after dismembered pyeloplasty is observed.