

# Medial patellofemoral ligament reconstruction combined with biplanar supracondylar femoral derotation osteotomy in recurrent patellar dislocation with increased femoral internal torsion and genu valgum: a retrospective study

**Xiangtian Deng**

Nankai University

**Lingzhi Li**

Southwest Medical University

**Peng Zhou**

Southwest Medical University

**Yuan Li**

Southwest Medical University

**Yanwei He**

Southwest Medical University

**Ge Chen**

Southwest Medical University

**Sifan Yang**

Hebei Medical University Third Affiliated Hospital

**Xiaodong Cheng**

Hebei Medical University Third Affiliated Hospital

**Zhong Li**

Southwest Medical University

**Juncai Liu** (✉ [ljc646000@163.com](mailto:ljc646000@163.com))

The Affiliated Hospital of Southwest Medical University

---

## Research Article

**Keywords:** Recurrent patellar dislocation, Genu valgum, femoral anteversion angle, Femoral derotation osteotomy, Biplanar, Medial patellofemoral ligament reconstruction, Alignment correction

**Posted Date:** March 22nd, 2021

**DOI:** <https://doi.org/10.21203/rs.3.rs-327972/v1>

**License:** © ⓘ This work is licensed under a Creative Commons Attribution 4.0 International License.

[Read Full License](#)

---

**Version of Record:** A version of this preprint was published at BMC Musculoskeletal Disorders on November 26th, 2021. See the published version at <https://doi.org/10.1186/s12891-021-04816-2>.

# Abstract

## Background

The purpose of this study was to evaluate the clinical and radiographic outcomes after medial patellofemoral ligament (MPFL) reconstruction combined with supracondylar biplanar femoral derotation osteotomy (FDO) in recurrent patellar dislocation (RPD) with increased femoral anteversion angle (FAA) and genu valgum.

## Methods

Between January 2017 to December 2020, a total of 13 consecutive patients (13 knees, 4 males and 9 females, mean age 18.7 (range, 15–29) years) with RPD with increased FAA and genu valgum who underwent supracondylar biplanar FDO using a Tomofix-locking plate combined with MPFL reconstruction in our institution were included. Preoperative full-leg standing radiographs, lateral views, and hip-knee-ankle computed tomography (CT) scans were used to evaluate the mechanical lateral distal femoral angle (mLDFA), patellar height, tibial tubercle-trochlear groove (TT-TG) distance, and torsional angle of the tibial and femoral in the axial plane. Patient reported outcomes were evaluated using the International Knee Documentation Committee (IKDC) score, Kujala score, Lysholm score, visual analog scale (VAS), and Tegner score preoperatively and postoperatively. Postoperative CT scans were used to evaluate the changes of FAA and TT-TG, and full-leg standing radiographs was used to evaluate the changes of mLDFA.

## Results

A total of 13 patients (13 knees) were included with an average follow-up period of 14.7 months (range 12–26). No cases of patients developed wound infection, soft tissue irritation, and recurrent dislocation during the follow-up period after surgery. Bone healing at the osteotomy site was achieved in all cases, and all patients regained full extension and flexion. Clinical outcomes (VAS, Kujala, IKDC, Lysholm, and Tegner scores) improved significantly at the final follow-up after surgery ( $p < 0.05$ ). The mean mLDFA changed significantly from  $82.72^\circ \pm 3.27^\circ$  to  $88.63^\circ \pm 2.35^\circ$ . The mean TT-TG distance significantly decreased from  $19.63 \pm 3.21$  mm to  $13.29 \pm 2.78$  mm, while the CDI did not change significantly after surgery ( $p = 0.05$ ). The mean FAA significantly decreased from  $32.77^\circ \pm 3.78^\circ$  to  $19.08^\circ \pm 3.14^\circ$ , while the tibial torsion did not change significantly after surgery ( $p = 0.05$ ).

## Conclusion

MPFL reconstruction combined with supracondylar biplanar FDO showed satisfactory clinical outcomes and radiographic results in the short-term follow-up period.

# Background

Recurrent patellar dislocation (RPD) is a complex condition and often associated with multiple contributing factors. Several of these risk factors, including patella alta, genu valgum, disrupted or weakened medial soft tissue, trochlear dysplasia, increased tibial tuberosity and the trochlear groove (TT-TG) distance, and torsional alignment of the femur or tibia <sup>[1–5]</sup>. Specially, osseous deformities in the coronal and axial plane, such as genu valgum and torsional deformities of the lower extremity, are now considered to be associated with adverse effects on patellofemoral instability. Herein, the increased femoral anteversion angle (FAA) and genu valgum are thought to create a sustaining lateralizing force vector applied on the patella, which might increase excessive loading forces on the reconstructed graft and even lead to patellar redislocation.

At present, there is still much controversy in the surgical techniques of RPD combined with knee valgus deformity. In recent years, various surgical techniques for addressing RPD with genu valgum have been described. Nha et al. <sup>[6]</sup> demonstrated the satisfactory improvement of knee function of 14 patients (23 knees) who underwent closing-wedge distal femoral osteotomy without MPFL reconstruction. Similarly, Swarup et al. <sup>[7]</sup> demonstrated that lateral opening wedge distal femoral osteotomy combined with lateral retinacular release yield satisfactory clinical results in this population.

In practice, genu valgum combined with excessive femoral internal torsion remains as the primary risk factors for RPD and is rarely corrected by the surgery simultaneously. Despite the association between mechanical malalignment of multi-plane, soft tissue dynamics and patellar instability, until now, there is a paucity of studies regarding clinical and radiographic results after MPFL reconstruction combined with supracondylar biplanar FDO procedure in this population.

The purpose of this study was to a) analyze the clinical and radiographic results of the MPFL reconstruction combined with biplanar supracondylar FDO procedure, b) to evaluate the differences between pre- and post-operative knee function and radiographic results including effects on patellar parameters and alignment correction, c) to assess complications associated with bone healing, soft tissue irritation, wound infection, and recurrence of dislocation. It was our hypothesis that patients with RPD associated with increased FAA and genu valgum treated by FDO can achieve satisfactory clinical and radiographic results in the short-term follow-up period.

## Methods

### Patients

This study was approved by the Ethics Committee of the Affiliated Hospital of Southwest University. Between January 2017 and December 2020, a retrospective single-center cohort study was conducted to evaluate the clinical and radiographic outcomes of all included patients who experienced recurrent patellar instability due to genu valgum in the coronal plane and increased FAA in the axial plane. All

included patients were treated by MPFL reconstruction combined with supracondylar biplanar FDO procedure and all surgeries were performed by a senior orthopaedic surgeon (Z.L).

Inclusion criteria were as follows: a) recurrent patellar dislocations ( $\geq 2$  times); b) increased FAA  $\geq 25^\circ$ ; c) genu valgum; d) physiologic trochlea and/or Dejour type A dysplasia <sup>[8]</sup>; e) patients with at least 1-year follow-up period.

Exclusion criteria were as follows: a) tibial rotational deformity; b) patients with open epiphysis; c) patients with lateral compartment knee osteoarthritis; d) patients with previous knee surgery; e) posttraumatic deformities; f) patients who lost to follow up; g) incomplete clinical data.

## **Surgical technique**

### **Supracondylar biplanar femoral derotation osteotomy**

Supracondylar biplanar FDO was performed according to a method described previously by Hinterwimmer et al. <sup>[9]</sup>, in which they developed an anterior closed-wedge technique of biplanar supracondylar DFO for patellofemoral malalignment.

Patients received general anesthesia and were placed on a radiolucent operating table in a supine position, and a tourniquet was used to the proximal thigh. First, an arthroscopic examination was performed at the beginning of surgery to evaluate the patellar tracking under the direct visualization.

Second, all cases were performed by the standard medial subvastus approach through a longitudinal skin incision of approximately 10-12 cm in length to access the medial metaphysis of the distal femur. The subcutaneous tissue and fascia were separated and the vastus medialis was stripped with a blunt Hohmann retractor to protect the neurovascular behind the femoral shaft. The axial osteotomy was performed perpendicular to the femoral shaft axis and involved the posterior two-thirds of the femur. The frontal plane osteotomy runs in an oblique direction from the superior margin of the axial osteotomy to the anterior femoral cortex (**Fig.2a**). After that, the first cut of the anterior plane osteotomy is performed with an oscillating saw from medial to lateral with the saw blade slightly angled towards the floor. Both the medial and contralateral lateral cortex is completely cut through. For derotation osteotomy, the target correction rotation angle calculated in preoperative planning and was marked using two Kirschner wires intra-operatively under the fluoroscopic guidance. The lateral cortex was cut completely and two Steinmann nails were placed proximally and distally to the osteotomy site to allow the distal femur external rotated to the predetermined angle. After that, a medial-based anterior wedge is produced by a second anterior saw cut inferior to the first wedge (**Fig.2b**). The wedge is removed (**Fig.2c**), and the gap created by anterior osteotomy is closed by rotating residual fragments using the two Schanz screws (**Fig.2d**).

After that, patellar tracking was re-evaluated under arthroscopic visualization after osteosynthesis with Tomofix-locking plate fixation (Depuy Synthes, Umkirch, Germany). Of note, it is important to place the

Tomofix-locking plate fixation in a position where they do not impede the later positioning of the femoral tunnel of MPFL. Typical case was presented in **Fig.3**.

### **MPFL reconstruction**

MPFL double-bundle anatomical reconstruction using autologous semitendinosus tendon autograft was performed in all patients and our surgical technique was similar to Schoettle et al. <sup>[10]</sup>. Two bony grooves were drilled in the patellar medial edge, which were placed into the center and the upper inner corner of the patellar medial edge, respectively. The graft fixed in patella side by two anchors inserted into the bony grooves. Subsequently, a femoral tunnel was made at the femoral insertion site of the MPFL, and the graft was fixed by a bioabsorbable interference screw with the knee in 20° to 30° of flexion.

### **Rehabilitation protocol**

All patients started functional exercises within 24 hours post-operation, including active circum-movements of ankle and isometric quadriceps muscle training. Patients were instructed to begin partial weight-bearing with crutches for the first 4 weeks, and strengthening exercise of vastus medialis muscle was encouraged. Full-weight bearing without limitation was allowed at 6-8 weeks postoperatively.

### **Functional scores evaluation**

Functional scores, including visual analogue scale (VAS), Kujala score <sup>[11]</sup>, International Knee Documentation Committee (IKDC) score <sup>[12]</sup>, Lysholm score <sup>[13]</sup>, and Tegner activity score <sup>[14]</sup> were used to evaluate knee function preoperatively and at the last follow-up after surgery.

### **Radiographic assessment**

Preoperative radiological analysis prior to surgery, including full-leg standing anteroposterior (AP) radiographs of lower extremity, lateral views, and standardized hip-knee-ankle computed tomography (CT) scans were used to evaluate the mechanical lateral distal femoral angle (mLDFA), trochlear dysplasia, TT-TG distance, patellar height, and tibial and femoral torsion deformities in the axial plane.

The mLDFA was measured on the full-leg standing AP radiograph and was defines as a lateral angle between a line connecting the center of the femoral head to the center of the knee and a line tangent to distal femoral condylar. Trochlear dysplasia and TT-TG distance were evaluated by axial CT images. The TT-TG distance was measured between the two parallel lines that perpendicular to the posterior condylar tangents on superimposed axial slices: a line passed the most cephalad point of the tibial tubercle and a line passed through the deepest point of the trochlear groove [8]. Caton-Deschamps index (CDI) was measured on lateral radiographs to evaluate the patellar alta [15].

Tibial and femoral torsion deformity was measured on reconstructed 3-dimensional axial CT images utilizing the method described by Takagi et al. [16], as shown in **Fig.1**. Tibial torsion was defined as the angel between a line connecting the posterior tibial condyles and a line connecting the midpoints of the

medial and lateral malleoli. The FAA was defined as the angle between a line connecting the midpoint of the femoral neck and the center of the femoral head and a line connecting the most posterior points of the medial and lateral femoral condyles.

## Statistical analysis

SPSS software (version 24.0, IBM Corp., USA) was performed for statistical analysis. Clinical and radiographic results were present with mean and standard deviation (SD). Paired *t* test was used to compare the differences in the pre- and post-operative clinical and radiographic outcome data. For all tests, *p* values < 0.05 were considered statistically significant.

# Results

## Patient demographics

A total of 13 patients (13 knees) who treated by double-bundle anatomical MPFL reconstruction combined with biplanar supracondylar FDO were include in the study. Of the 13 patients, 4 cases were males and 9 cases were females. The average age of the included patients at the time of surgery was 18.7 years (range, 15-29 years). The average body mass index (BMI) was  $25.7 \pm 3.6$  (21.8-31.2). The average follow-up period was 14.7 months (range, 12-26 months).

Pre-operative standing full-leg AP and lateral radiographs and CT scans for hip-knee-ankle were available for all cases, and patients demographics were presented in **Table 1**.

## Clinical outcome

Range of motion and functional scores after surgery were shown in **Table 2**. The average VAS score for pain significantly decreased from  $4.81 \pm 2.13$  preoperatively to  $1.83 \pm 1.47$  at the final follow-up ( $p < 0.001$ ). The average Kujala score improved significantly from  $57.48 \pm 8.76$  preoperatively to  $87.43 \pm 4.25$  at the final follow-up ( $p < 0.001$ ). The average IKDC score improved significantly from  $51.42 \pm 8.36$  preoperatively to  $83.59 \pm 7.27$  at the final follow-up ( $p < 0.001$ ). The average Lysholm score improved significantly from  $59.85 \pm 9.71$  preoperatively to  $83.88 \pm 6.45$  at the final follow-up ( $p < 0.001$ ). The median Tegner activity score illustrated significant preoperative to postoperative improvement from 2 (range, 1-4) to 4 (range, 3-6) ( $p < 0.001$ ).

## Radiographic outcomes

Radiographic outcomes after surgery were shown in **Table 3**. The mean mLDFA changed significantly from  $82.72^\circ \pm 3.27^\circ$  to  $88.63^\circ \pm 2.35^\circ$  ( $p < 0.001$ ). The mean TT-TG distance significantly decreased from  $19.63 \pm 3.21$  mm to  $13.29 \pm 2.78$  mm ( $p < 0.001$ ), while the CDI did not change significantly after surgery ( $p = 0.05$ ). The mean FAA significantly decreased from  $32.77^\circ \pm 3.78^\circ$  to  $19.08^\circ \pm 3.14^\circ$  ( $p < 0.001$ ), while the tibial torsion did not change significantly after surgery ( $p = 0.05$ ).

## Complications

No cases of patients developed wound infection, soft tissue irritation, and recurrence of subluxation or dislocation during the follow-up period after surgery. Bone healing at the osteotomy site was achieved in all cases, and all patients regained full extension and flexion and no limited range of motion was observed.

## Discussion

Patella instability associated with genu valgum treated by supracondylar distal femoral osteotomy have been reported in several studies [17-19]. However, the clinical significance and potential advantages of MPFL reconstruction combined with biplanar supracondylar FDO procedure in RPD with increased FAA and genu valgum have not yet been identified. In this retrospective study, MPFL reconstruction combined with biplanar supracondylar FDO procedure achieved significant functional improvement after surgery in knee function scores (VAS, Kujala score, IKDC score, Lysholm score, and Tegner scores) and satisfactory radiographic outcomes (FAA, TT-TG, and mLDFA) in patellar instability with increased FAA and genu valgum, and no recurrence of dislocation cases had been found within the follow-up period.

Several orthopaedic surgeons have emphasized the role that osseous deformities of the axial and coronal plane acts as a significantly higher risk factor for patellofemoral maltracking. Dejour et al. [8] identified that patients with patellofemoral instability had a higher value of FAA than healthy controls (15.6 vs. 10.8) following CT evaluation. Similarly, Zhang et al. [20] have reported that the adverse effects of increased femoral internal torsion on reconstructed MPFL, especially in patients when the FAA greater than 30°, which could be partially explained by the fact that the excessive lateralizing force vector acting on the patella due to the increased Q angle [21]. Recently, biomechanical studies further demonstrated that the adverse effect of isolated MPFL reconstruction for patellar instability associated with increased FAA. Kaiser et al. [22] revealed that isolated MPFL reconstruction for patella instability is insufficient for higher degrees of FAA, which indicated that increased FAA may result in a persistent lateral force vector on the patella.

Due to these abnormal biomechanics of osseous deformity, it is vital to identify these underlying predisposing risk factors and to early make intervention for RPD. Despite isolated anatomical MPFL reconstruction is considered to be a standard treatment for patellofemoral instability with satisfactory results [23, 24], subsequent studies have demonstrated that a high rate of subjective dissatisfaction in patients with increased femoral internal torsion [25]. Supracondylar femoral derotation osteotomy as an isolated procedure has been shown good clinical outcomes for RPD with increased FAA [26, 27]. However, isolated FDO procedure at the distal femur may increase the risk of graft failure when ignoring the correction of the knee valgus deformity, because the laterally-oriented vector forces applied to patellofemoral joint which can result in excessive tension into the reconstructed MPFL graft [5, 28].

Recently, there has been a great focus of investigating the effect of derotation femoral osteotomy on the changes of coronal alignment. Nelitz et al. [29] reported that FDO procedure tend to result in an increased



valgus angulation in the frontal plane due to a decreased mLDFA. Similarly, Konrads et al. [30] also identified that supracondylar femoral external osteotomy would lead to valgus deformity of the coronal limb alignment, which may be attributed to the reorientation of the femoral antecurvature and the femoral neck. Thus, isolated FDO procedure may not address the problem involving increased FAA combined with genu valgum in the presence of RPD patients.

Despite a biplanar supracondylar DFO has been performed in the correction of valgus deformity and excessive femoral internal torsion simultaneously, none of this group of patients showed signs for delayed union or non-union of the osteotomy, which was comparable to Imhoff et al. [26] on a combined varus and external rotation producing distal femoral osteotomy.

There are several limitations in this study. First, the number of patients was relatively small and the follow-up period was short. However, RPD patients both with increased FAA and genu valgum are rare. Second, a missing comparative group of patients who treated by other surgical techniques. However, considering that the significant functional improvement and absence of redislocation, FDO combined with MPFL reconstruction may be a treatment option for RPD with increased FAA and genu valgum. Third, second-look arthroscopic evaluation was not performed to evaluate the changes of trochlear and retropatellar cartilage.

## Conclusion

MPFL reconstruction combined with biplanar supracondylar FDO is a safe and reliable treatment for RPD with increased FAA and genu valgum, which demonstrated a satisfactory clinical and radiographic results in the short-term follow-up.

## Abbreviations

**MPFL:** medial patellofemoral ligament

**FDO:** femoral derotation osteotomy

**RPD:** recurrent patellar dislocation

**FAA:** femoral anteversion angle

**CT:** computed tomography

**mLDFA:** mechanical lateral distal femoral angle

**TT-TG:** tibial tubercle-trochlear groove

**IKDC:** International Knee Documentation Committee

**VAS:** visual analog scale

**AP:** anteroposterior

**CDI:** Caton-Deschamps index

**SD:** standard deviation

**BMI:** body mass index

## **Declarations**

### **Availability of data and materials**

All the data and material involving this article will be available upon request by send an e-mail to the first author.

### **Acknowledgements**

We are grateful to the Sifan Yang and Xiaodong Cheng of the Third Hospital of Hebei Medical University for their kind assistance.

### **Funding**

There is no funding in our work.

### **Author's contributions**

ZL and JCL designed the study; XTD, LZL, PZ, YL, YWH, SFY, and XDC searched relevant studies; XTD, LZL, and GC analyzed and interpreted the data; XTD wrote the manuscript; ZL and JCL approved the final version of the manuscript.

### **Ethics declarations**

#### **Ethics approval and consent to participate**

This study was approved by the ethics committee of the Affiliated Hospital of Southwest Medical University. Informed consent was obtained from all individual participants included in the study.

#### **Consent for publication**

Consent to publish was obtained from each patient.

#### **Competing interests**

All the authors declare that they have no conflict of interest with any organization.

## **References**

- [1] Nelitz M, Dreyhaupt J, Williams S R, et al. Combined supracondylar femoral derotation osteotomy and patellofemoral ligament reconstruction for recurrent patellar dislocation and severe femoral anteversion syndrome: surgical technique and clinical outcome[J]. *Int Orthop*. 2015, 39(12): 2355-2362.
- [2] Souza R B, Draper C E, Fredericson M, et al. Femur rotation and patellofemoral joint kinematics: a weight-bearing magnetic resonance imaging analysis[J]. *J Orthop Sports Phys Ther*. 2010, 40(5): 277-285.
- [3] Rogers B A. Patella alta: association with patellofemoral alignment and changes in contact area during weight-bearing[J]. *J Bone Joint Surg Am*. 2008, 90(2): 446-447, 447.
- [4] Van Haver A, De Roo K, De Beule M, et al. The effect of trochlear dysplasia on patellofemoral biomechanics: a cadaveric study with simulated trochlear deformities[J]. *Am J Sports Med*. 2015, 43(6): 1354-1361.
- [5] Frosch K H, Schmeling A. A new classification system of patellar instability and patellar maltracking[J]. *Arch Orthop Trauma Surg*. 2016, 136(4): 485-497.
- [6] Nha K W, Ha Y, Oh S, et al. Surgical Treatment With Closing-Wedge Distal Femoral Osteotomy for Recurrent Patellar Dislocation With Genu Valgum[J]. *Am J Sports Med*. 2018, 46(7): 1632-1640.
- [7] Swarup I, Elattar O, Rozbruch S R. Patellar instability treated with distal femoral osteotomy[J]. *Knee*. 2017, 24(3): 608-614.
- [8] Dejour H, Walch G, Nove-Josserand L, et al. Factors of patellar instability: an anatomic radiographic study[J]. *Knee Surg Sports Traumatol Arthrosc*. 1994, 2(1): 19-26.
- [9] Hinterwimmer S, Minzlaff P, Saier T, et al. Biplanar supracondylar femoral derotation osteotomy for patellofemoral malalignment: the anterior closed-wedge technique[J]. *Knee Surg Sports Traumatol Arthrosc*. 2014, 22(10): 2518-2521.
- [10] Schottle P B, Romero J, Schmeling A, et al. Technical note: anatomical reconstruction of the medial patellofemoral ligament using a free gracilis autograft[J]. *Arch Orthop Trauma Surg*. 2008, 128(5): 479-484.
- [11] Kujala U M, Jaakkola L H, Koskinen S K, et al. Scoring of patellofemoral disorders[J]. *Arthroscopy*. 1993, 9(2): 159-163.
- [12] Irrgang J J, Anderson A F, Boland A L, et al. Development and validation of the international knee documentation committee subjective knee form[J]. *Am J Sports Med*. 2001, 29(5): 600-613.
- [13] Kocher M S, Steadman J R, Briggs K K, et al. Reliability, validity, and responsiveness of the Lysholm knee scale for various chondral disorders of the knee[J]. *J Bone Joint Surg Am*. 2004, 86(6): 1139-1145.

- [14] Tegner Y, Lysholm J. Rating systems in the evaluation of knee ligament injuries[J]. Clin Orthop Relat Res. 1985(198): 43-49.
- [15] Caton J H, Dejour D. Tibial tubercle osteotomy in patello-femoral instability and in patellar height abnormality[J]. Int Orthop. 2010, 34(2): 305-309.
- [16] Takagi S, Sato T, Watanabe S, et al. Alignment in the transverse plane, but not sagittal or coronal plane, affects the risk of recurrent patella dislocation[J]. Knee Surg Sports Traumatol Arthrosc. 2018, 26(10): 2891-2898.
- [17] Tan S, Hui S J, Doshi C, et al. The Outcomes of Distal Femoral Varus Osteotomy in Patellofemoral Instability: A Systematic Review and Meta-Analysis[J]. J Knee Surg. 2020, 33(5): 504-512.
- [18] Frings J, Krause M, Akoto R, et al. Combined distal femoral osteotomy (DFO) in genu valgum leads to reliable patellar stabilization and an improvement in knee function[J]. Knee Surg Sports Traumatol Arthrosc. 2018, 26(12): 3572-3581.
- [19] Dickschas J, Ferner F, Lutter C, et al. Patellofemoral dysbalance and genua valga: outcome after femoral varisation osteotomies[J]. Arch Orthop Trauma Surg. 2018, 138(1): 19-25.
- [20] Zhang Z, Zhang H, Song G, et al. Increased femoral anteversion is associated with inferior clinical outcomes after MPFL reconstruction and combined tibial tubercle osteotomy for the treatment of recurrent patellar instability[J]. Knee Surg Sports Traumatol Arthrosc. 2020, 28(7): 2261-2269.
- [21] Diederichs G, Kohlitz T, Kornaropoulos E, et al. Magnetic resonance imaging analysis of rotational alignment in patients with patellar dislocations[J]. Am J Sports Med. 2013, 41(1): 51-57.
- [22] Kaiser P, Schmoelz W, Schottle P B, et al. Isolated medial patellofemoral ligament reconstruction for patella instability is insufficient for higher degrees of internal femoral torsion[J]. Knee Surg Sports Traumatol Arthrosc. 2019, 27(3): 758-765.
- [23] Howells N R, Barnett A J, Ahearn N, et al. Medial patellofemoral ligament reconstruction: a prospective outcome assessment of a large single centre series[J]. J Bone Joint Surg Br. 2012, 94(9): 1202-1208.
- [24] Matsushita T, Kuroda R, Oka S, et al. Clinical outcomes of medial patellofemoral ligament reconstruction in patients with an increased tibial tuberosity-trochlear groove distance[J]. Knee Surg Sports Traumatol Arthrosc. 2014, 22(10): 2438-2444.
- [25] Zhang Z, Song G, Li Y, et al. Medial Patellofemoral Ligament Reconstruction With or Without Derotational Distal Femoral Osteotomy in Treating Recurrent Patellar Dislocation With Increased Femoral Anteversion: A Retrospective Comparative Study[J]. Am J Sports Med. 2020: 985801354.

[26] Imhoff F B, Cotic M, Liska F, et al. Derotational osteotomy at the distal femur is effective to treat patients with patellar instability[J]. Knee Surg Sports Traumatol Arthrosc. 2019, 27(2): 652-658.

[27] Tian G, Yang G, Zuo L, et al. Femoral derotation osteotomy for recurrent patellar dislocation[J]. Arch Orthop Trauma Surg. 2020.

[28] Mcwalter E J, Cibere J, Macintyre N J, et al. Relationship between varus-valgus alignment and patellar kinematics in individuals with knee osteoarthritis[J]. J Bone Joint Surg Am. 2007, 89(12): 2723-2731.

[29] Nelitz M, Wehner T, Steiner M, et al. The effects of femoral external derotational osteotomy on frontal plane alignment[J]. Knee Surg Sports Traumatol Arthrosc. 2014, 22(11): 2740-2746.

[30] Konrads C, Ahrend M D, Beyer M R, et al. Rotation osteotomy of the distal femur influences coronal femoral alignment and the ischiofemoral space[J]. Arch Orthop Trauma Surg. 2020.

## Tables

**Table 1.** Patient demographics

Variable	Value
Number of patients	13
Age <sup>a</sup> , years (range)	18.7 (15-29)
Sex <sup>b</sup> , male/female	4/9
Side <sup>b</sup> , left/right	5/8
BMI <sup>a</sup> , kg/m <sup>2</sup> (range)	25.7±3.6 (21.8-31.2)
Follow-up period, months (range)	14.7 (12-26)

*BMI*/body mass index

<sup>a</sup> Results presented as mean±standard deviation

<sup>b</sup> Results presented as number of patients

**Table 2.** Comparison of pre- and post-operative knee functional scores and pain

Variables	Pre-operative	Post-operative	<i>p</i> -value
ROM	128.90±5.60	133.20±7.60	n.s
VAS pain	4.81±2.13	1.83±1.47	<0.001*
Kujala score	57.48±8.76	87.43±4.25	<0.001*
IKDC score	51.42±8.36	83.59±7.27	<0.001*
Lysholm score	59.85±9.71	83.88±6.45	<0.001*
Tegner activity score	2.0 (1-4)	4.0 (3-6)	<0.001*

The values (ROM, VAS, Kujala, IKDC, and Lysholm) are presented as the mean ± standard deviation, and the Tegner score are presented as median values.

*n.s* not significant, *ROM* range of motion, *VAS* visual analog scale, *IKDC* International Knee Documentation Committee.

\*Significant difference compared to preoperatively

**Table 3.** Comparison of pre- and post-operative radiological parameters

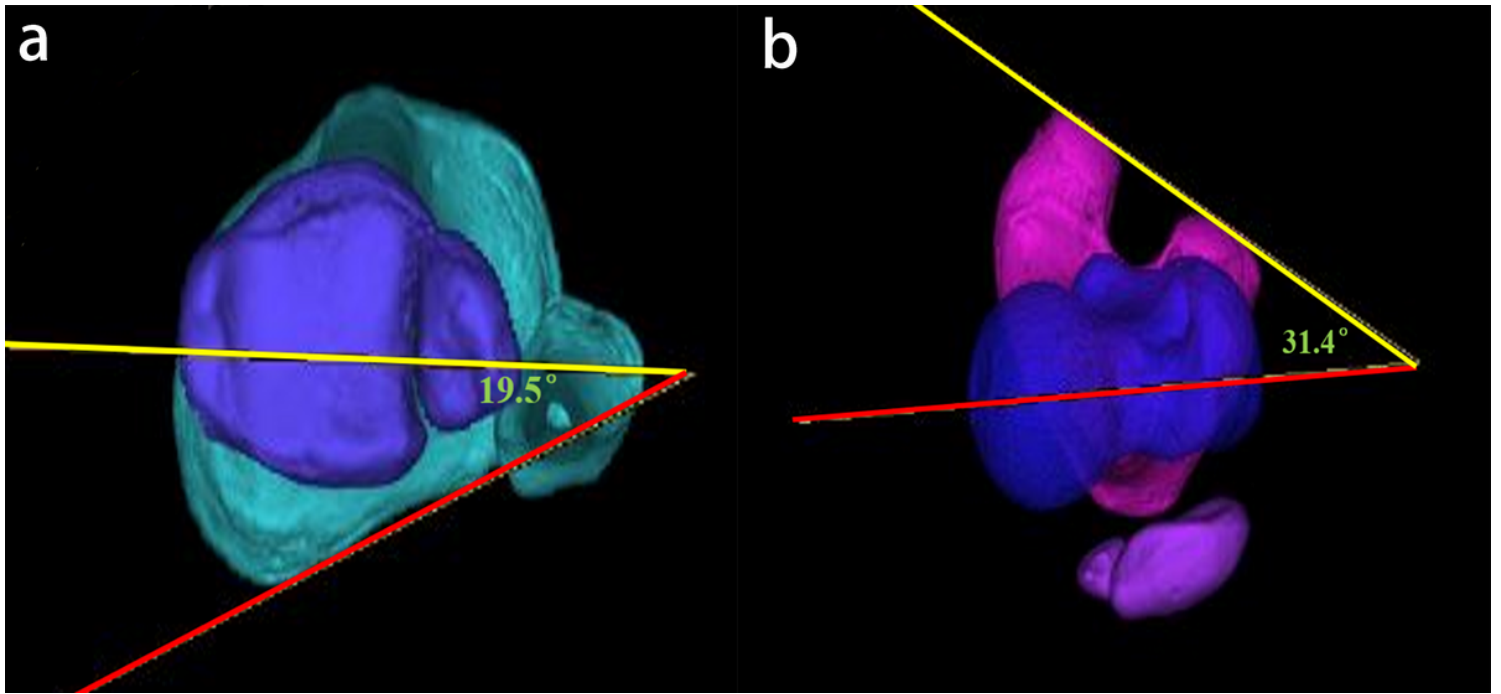
Variables	Pre-operative	Post-operative	<i>p</i> -value
mLDFA, degree	82.72±3.27	88.63±2.35	<0.001*
TT-TG (mm)	19.63±3.21	13.29±2.78	<0.001*
CDI	1.11±0.13	1.15±0.08	n.s
Femoral anteversion, degree	32.77±3.78	19.08±3.14	<0.001*
Tibial torsion, degree	26.17±4.21	27.53±4.38	n.s

Values are presented as mean±standard deviation

*n.s* not significant, *CDI* Caton-Deschamps index, *mLDFA* mechanical lateral distal femoral angle, *TT-TG* tibial tubercle to trochlear groove.

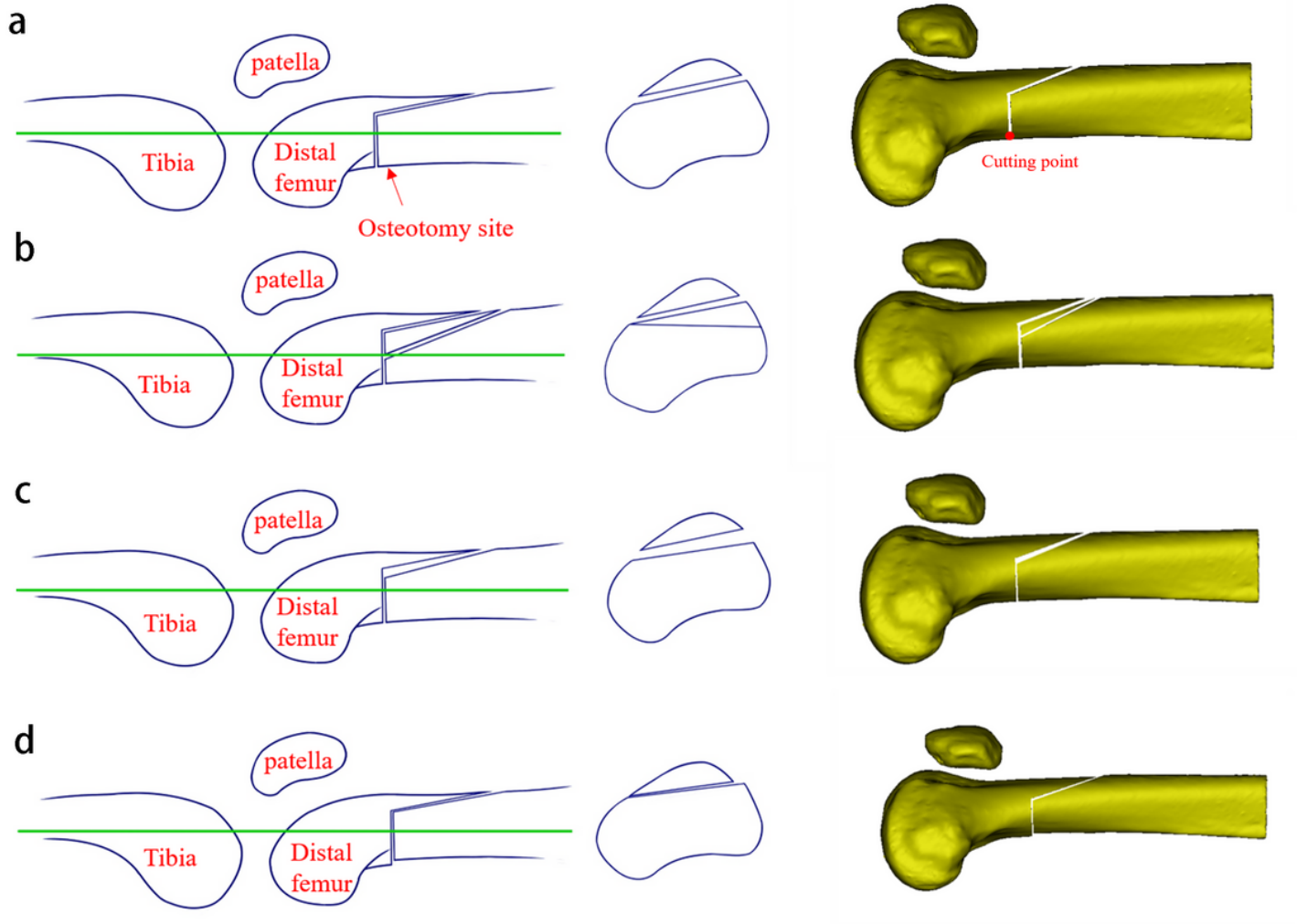
\*Significant difference compared to preoperatively

## Figures



**Figure 1**

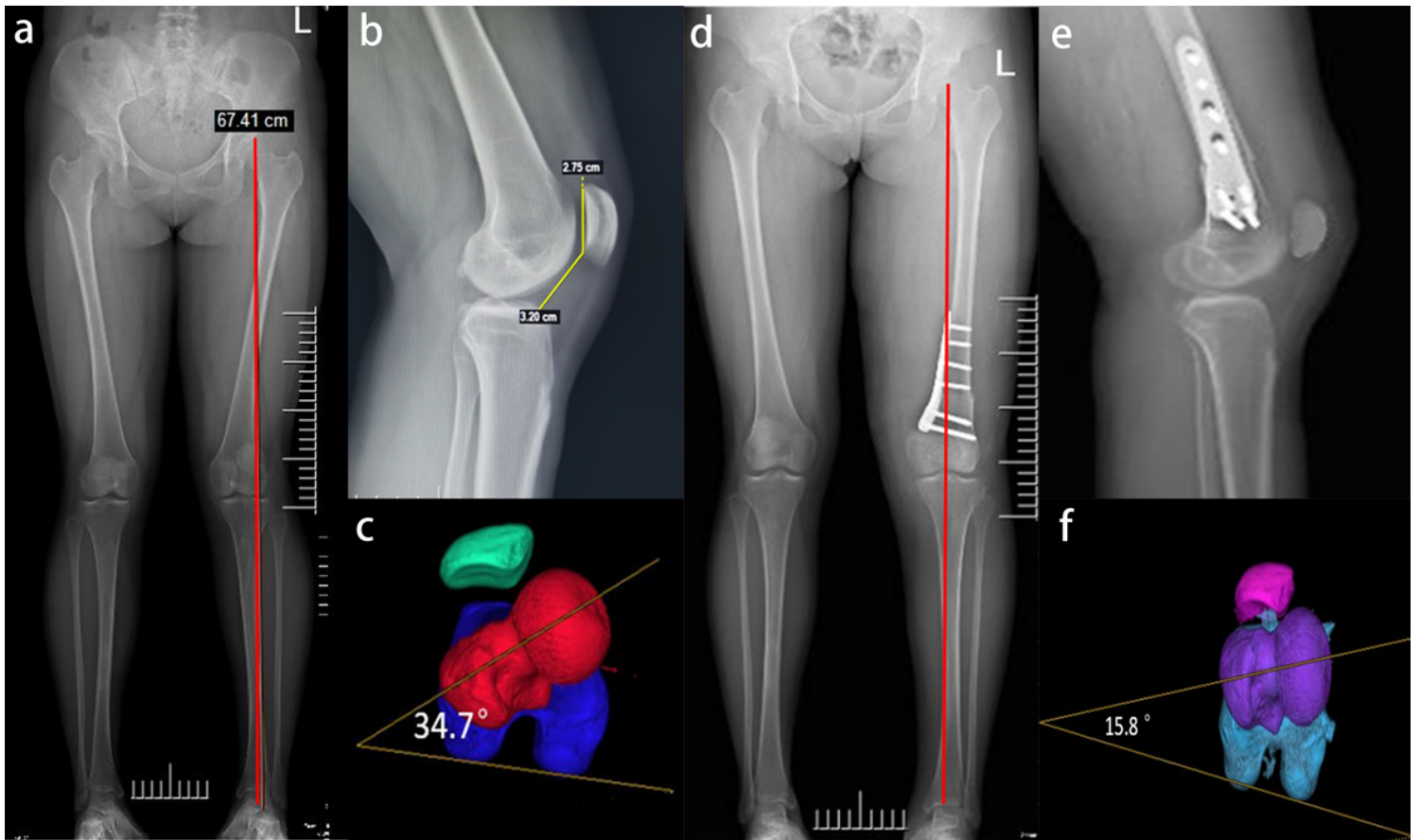
Measurement of torsional parameters of the lower extremity on 3-dimensional computed tomography. a. The femoral anteversion angle was defined as the angle between femoral neck axis (red line) and posterior condylar of distal femoral axis (yellow line). b. The tibia external rotation was defined as the angle between the line connecting the posterior tibial condyles and the line connecting the midpoints of the medial and lateral malleoli.



**Figure 2**

Schematic illustration of the biplanar supracondylar femoral derotation osteotomy, including a perpendicular osteotomy in the axial plane and a wedge osteotomy in the frontal plane. a-d. Left column: medial view of a distal femur; Middle column: axial cut through the distal femur. Right column: corresponding 3-dimensional reconstructed CT images.





**Figure 3**

Genu valgum deformity with recurrent patellar dislocation of a 19-year-old female. a. Preoperative full-leg standing anteroposterior radiographs showed knee valgus deformity. b. Preoperative lateral radiograph. c. The preoperative femoral anteversion angle was increased to 34.7°. d. Postoperative full-leg standing anteroposterior radiographs showed neutral alignment. e. Postoperative lateral radiograph showed stable fixation with a Tomifix-locking plate. f. CT scans postoperatively showed an improvement in femoral anteversion angle.