

# A new traction method (traction ring) for colorectal endoscopic submucosal dissection: a retrospective study

**Xinyuan Huang**

Capital Medical University Affiliated Beijing Friendship Hospital

**Hui-Hong Zhai**

Capital Medical University Affiliated Beijing Friendship Hospital <https://orcid.org/0000-0002-8452-6311>

**Ming Ji**

Capital Medical University Affiliated Beijing Friendship Hospital

**Peng Li**

Capital Medical University Affiliated Beijing Friendship Hospital

**Yinglin Niu**

Capital Medical University Affiliated Beijing Friendship Hospital

**Fandong Meng**

Capital Medical University Affiliated Beijing Friendship Hospital

**Li Yu**

Capital Medical University Affiliated Beijing Friendship Hospital

**Yongjun Wang**

Capital Medical University Affiliated Beijing Friendship Hospital

**Haiying Zhao**

Capital Medical University Affiliated Beijing Friendship Hospital

**Fujing Lv**

Capital Medical University Affiliated Beijing Friendship Hospital

**Shutian Zhang** (✉ [zhangshutian@ccmu.edu.cn](mailto:zhangshutian@ccmu.edu.cn))

<https://orcid.org/0000-0003-2356-4397>

---

## Research article

**Keywords:** Endoscopy, Endoscopic Submucosal Dissection, Colorectal Neoplasms, Traction, Traction Ring

**Posted Date:** July 20th, 2020

**DOI:** <https://doi.org/10.21203/rs.3.rs-32330/v1>



# Abstract

## Background

Colorectal endoscopic submucosal dissection (ESD) is a challenging operation because it is often difficult to attain good visualization of the submucosal layer. Lots of traction methods have been developed to facilitate submucosal dissection, but still not widely applied. Therefore, we designed a new traction device "traction ring". This pilot study is to evaluate if traction ring is feasible and safe for colorectal ESD.

## Methods

We retrospectively analyzed 20 patients with colorectal lesions who had undergone traction ring assisted ESD. The main outcome was the rate of en bloc resection, R0 resection rate, procedure time, resection time, intraoperative and postoperative complications.

## Results

The median procedure time was 74.5 min (range 35–269 min.). The median resection time was 55 min (range 25–209 min.). The application of the traction system accounting for only 2.7% of the whole procedure time. Rate of en bloc resection was 95% (19/20). Rate of R0 resections was 90% (18/20). All traction rings were successfully settled and retrieved. No serious excessive intraoperative bleeding was observed. One patient was found perforation after treatment, no further intervention was required. No delayed complications were observed within one month after the operation.

## Conclusions

This retrospective study demonstrated that the new countertraction method (traction ring) may become a safe, effective and simple way to assist ESD for colorectal lesions.

## Background

The emergence of endoscopic mucosal resection (EMR) enables endoscopists to resect colorectal lesions directly, but EMR is difficult to achieve en bloc resection for neoplasms larger than 2 cm. Piecemeal resection may lead to histopathological evaluation becomes uncertain, and caused a high risk of local recurrence (20%; 95% confidence interval: 16–25) [1]. With the progress of endoscopic technology, the advent of endoscopic submucosal dissection (ESD) extended indications of endoscopic treatment and increased the en bloc resection rate [2]. ESD has become the standard endoscopic treatment for early-stage colorectal cancer according to the Japanese guideline [3]. Whereas perforation for colorectal ESD are more frequent than gastric because of the thin colorectal walls, poor endoscopic maneuverability, and

the abundant vessels present in the rectum [4]. Technical difficulties and long learning curve hinder the promotion of colorectal ESD. Colorectal ESD has not been widely used in most of the countries especially the western country where most cases of colorectal cancer are detected (55%) [5].

The main reason why colorectal ESD is complex is that the mucosa couldn't be lifted as in surgery due to the absence of counter traction. If the mucosa is lifted by traction after the initial mucosal incision, submucosa can be observed directly, good visibility of the dissection line and the vessels of the submucosa would be obtained. This allows for swift dissection of appropriate portion of submucosa and prevention the injury of blood vessels and muscular layer, the difficulty of ESD would be greatly reduced. The simplest traction method is to alter patient's position. However, traction provided by gravity may be insufficient in the initial stage of submucosa dissection and in fibrosis lesions. Based on obtaining stable and reliable traction under ESD, variety of devices for traction have been designed. Many has been reported to be effective with adequate visualization under endoscopy, still have some limitation yet [6–8]. For instance, clip with line method require exited and reinsertion of endoscope and offer limited directions of traction [6], and double scope method is difficult to operation [7]. For this reason, the instrument assisted traction method has not been widely used. Therefore, we designed a new traction device "traction ring" for colorectal ESD. The aim of this study was to evaluate the feasibility of traction ring assisted colorectal ESD. Traction ring may become a safe, effective and simple countertraction method to assist ESD for colorectal lesions and will reduce the difficulty of the producer.

## Methods

The aim of this retrospective study was to evaluate the feasibility of traction ring assisted colorectal ESD.

### Patients

From January 2018 to December 2019, patients who had ESD indication for colorectal lesions, and performed ESD at Beijing Friendship Hospital Affiliated to Capital Medical University were reviewed. Patients who used traction ring as auxiliary traction method during the operation were involved in the study. The use of the traction ring method was approved by Bioethics Committee of Beijing Friendship Hospital, Capital Medical University, and informed consent was obtained from each patient before ESD (Approved No. of ethic committee: 2019-P2-024-01).

Included in the analysis were patient's basic information (gender and age), endoscopic clinical characteristics (location and size, etc.), ESD operation related characteristics (en bloc resection rate, R0 resection rate, procedure time, resection time, intraoperative and postoperative complications, etc.), pathological findings (pathological diagnosis, cutting edge, etc.). Procedure time was defined as time from initial insertion to final withdrawal of the colonoscopy (including the treatment of other lesions). Resection time was measured from the start of the submucosal injections to removal of the lesion, including retrieval of the traction ring. R0 resection was defined as en bloc resection without identification of a tumor at both lateral or vertical margin. Intraoperative excessive bleeding was defined as difficulty of hemostasis under endoscopy during operation, which requires interruption of operation and / or blood

transfusion. Delayed bleeding was defined as hemorrhage that occurs after endoscopic treatment and needs endoscopic intervention again or reduction in hemoglobin level greater than 2 g/dl within 24 h after ESD. Perforation was defined as full-thickness defect of the colorectal wall or presence of extra-gastrointestinal air on abdominal imaging examination.

### **Design of the traction ring**

Traction ring (No. of patent: WO2020015692A1; MICRO-TECH, Nanjing, China) is made of subtransparent rubber material, which has certain elasticity and can be stretched according to the required length. The basic shape of traction ring is two connected hoops, similar to the Arabic number "8". The hole at the each ends of ring is larger than 2mm which allows arm of endoclip pass easily. The traction ring has kinds of length, operator can select the appropriate device according to characteristics of the lesion. In this study, we used 5-mm long traction ring for colorectum (shown in Fig. 1). The traction ring can be pass through the endoscopic instrument channel.

### **Traction ring assisted ESD procedure**

All procedures were performed by experienced endoscopists from our center. Repeatedly opened and closed Endoclips (MICRO-TECH, Nanjing, China) were recommended in the operation thus it was easier to clamp the traction ring to move and fix it to the target point. During the producer, if the submucosa cannot be adequately visualized for dissection, endoscopists would use traction ring to apply tension to the lesion. Traction ring assisted ESD procedure is as follow.

1. Tags and injection, circumferential incision of the mucosa. Firstly, applied multipoint injections into the submucosal tissue. Then cut the mucosa along the marked points, a circumferential incision in the submucosal layer was performed.
2. Placement of traction ring system. When the cutting line was difficult to see operator will decide anticipated fixed point of traction system, an endoclip was then inserted through working channel of endoscopy after firstly grasped the traction ring and was applied to the exfoliated mucosa (shown in Fig. 2. a). Submucosal injections will be applied into submucosal tissue of colorectal wall opposite to the lesion, to make an elevated point as marker for fixation. The other end of traction ring then fixed to the elevated point by endoclip (shown in Fig. 2. b). These procedures enabled excellent traction and visualization of the submucosal layer. During the dissection, the pulling force of the traction ring will gradually decrease. At this time, the direction of pulling force can be changed by removing and repositioning the traction ring, so as to obtain a lasting and effective pulling force (shown in Fig. 2. c).
3. Wound closure and specimen retrieved. After the dissection, the traction ring can be pull down by forcep, since submucosal injections was firstly made that laceration of muscular layer can be avoided. There was no need to withdraw the endoscope during the procedure described. We made sure that there was no active bleeding or perforation, and then closed the defect with endoclips. Finally, the specimen connected to traction ring is brought out using the forcep.

## Results

The patient and lesion characteristics are shown in Table 1. The study subjects were 11 men and 9 women with a median age of 63 years (range 36–88 years) .Altogether, we removed 20 lesions located, in the cecum (n = 3), in the ascending (n = 3) or descending (n = 2) colon, in the transverse colon (n = 2), and at the hepatic flexure (n = 1), at the splenic flexure(n = 1), in the sigmoid (n = 3), in the rectum (n = 5). The median lesion size was 20 mm (range 5–60 mm).

Table 1  
Patient characteristics

	<b>N (%)</b>
Age, yr	63 (36–88)
Gender, n	
Male	11 (55%)
Female	9 (45%)
Location, n	
Cecum	3 (15%)
Ascending colon	3 (15%)
Hepatic flexure	1 (5%)
Transverse colon	2 (10%)
Splenic flexure	1 (5%)
Descending colon	2 (10%)
Sigmoid	3 (15%)
Rectal	5 (25%)
Lesion size	
Median(range), mm	20 (5–60)
<20 mm, n	9 (45%)
20–40 mm, n	10 (50%)
>40 mm, n	1 (5%)
Paris classification, n	
0–Is	1 (5%)
0–Is <sub>p</sub>	1 (5%)
0–Ia	13 (65%)
0–Ia+Ic	5 (25%)

Outcomes of ESD using the traction ring method are shown in Table 2. The median procedure time was 74.5 min (range 35–269 min.). The median resection time was 55 min (range 25–209 min.). The application of the traction system took 2 min (range 1–4 min.). All lesions were removed en bloc using the traction ring technique except one case at the ascending colon was resected in two pieces, the lateral

margin of each pieces was negative on histologic examination. One lesion located in cecum was found horizontal margin positive. R0 resection confirmed in 18/20 lesions (90%).

Table 2  
Outcomes of treatment assisted by traction ring

	N (%)
Procedure time, min, median (range)	74.5 (35–269)
Resection time, min, median (range)	55 (25–209)
Application of traction, min, median (range)	2 (1–4)
Histology, n	
Adenoma	6 (30%)
Intramucosal or minute submucosal invasive cancer	11 (55%)
Deeply submucosal invasive cancer	3 (15%)
Horizontal margin (+), n	1 (5%)
Vertical margin (+), n	0 (0%)
Vessel invasion, n	0 (0%)
En bloc resection, n	19 (95%)
Piecemeal resection, n	1 (5%)
R0 resection, n	18 (90%)
Adverse event, n	
Excessive intraoperative bleeding	0 (0%)
Delayed bleeding	0 (0%)
Perforation	1 (5%)
Retention of traction ring	0 (0%)
Torn muscular layer by traction ring	0 (0%)

All traction ring were successfully retrieved, there was no muscular layer injured by traction ring. No serious excessive intraoperative bleeding was observed. One patient found no perforation during operation, however, after ESD free gas in abdominal cavity can be seen on CT. This patient suffered none obvious abdominal distention and pain, considering that the perforation has been clamped during operation, no further intervention was necessary. No delayed complications were observed within one month after the operation. In all cases, the traction ring could provide the necessary traction during ESD in an effective fashion, and are depicted in the images shown in Figs. 3–4.



## Discussion

The number of colorectal cancer patients in the world ranks 3 of all types of tumor, and morbidity is on the rise in recent years[3, 9]. However, there are not enough hospitals and doctors that are capable to complete colorectal ESD operation, and patients in remote areas couldn't get early treatment. The novel traction ring method was successfully applied in cases of our pilot trial. This simple technique does not require withdrawal and reinsertion of the colonoscope and takes only a few minutes to attain good visualization of the submucosal layer during procedure. We found that this method is feasible for colorectal ESD. We hope that ESD will be easier to learn by the traction ring, to reduce the difficulty for new scholars to master this practical technic, and can quickly promote ESD to large-scale application.

For colorectal, due to the special anatomical characteristic, such as the thin wall of colon, the existence of folds and curvature, etc., the technical difficulty of ESD is greatly increased. Difficult ESD is related to the prolongation of operation time, the decrease of en bloc resection rate and the occurrence of perforation. According to clinical research, some traction techniques are safe and effective in ESD treatment, which can reduce the difficulty of operation [8, 10]. At present, the traction methods in clinical research can be roughly divided into internal traction pattern, external traction pattern and special traction pattern. External traction pattern such as the clip with line method, grasping forceps [6, 11]. Grasping forceps could only be used in rectal lesion, and contact between the endoscope and the forceps causes them to interfere with each other [11]. Clip with line method which is easily to obtain countertraction effect at rectum, but as in deep colon it may be strenuous because of difficulty in reinserting the endoscope and adjusting direction of traction. Moreover, controlling traction force precisely in the proximal colon is difficult because the air volume and peristalsis in the colon could strengthen the traction force, excessive traction may lead to the traction system slipped from the lesion or even laceration may occur. Clip with line method that can access to the deep colon have been reported, which does not require withdrawal and reinsertion of the endoscope [12]. However, it is difficult to modulate the counteraction which is adjusted solely by pulling. Special equipment traction is obtained by additional equipment such as magnetic anchor, double scope method [7, 13]. These methods requires special equipment, which cost high and occupy large space. Double scope method is technically difficult to operate, and the technique is limited to the rectum and distal sigmoid colon because of difficulty in inserting the second endoscope into the oral side of the descending colon [7]. Internal traction method was firstly introduced by Saito et al [14], which use sinker to supply the lack of counter traction provided by gravity. Internal traction method which stable and continuous traction exerted by the internal system avoid the interference by the operation, but placement of sinker needs exit of endoscope and patient needs to change position for cooperation. If traction device can pass through the working channel of endoscopy, there is no need to withdraw and reinsert the endoscope for traction system settlement. Simplified the operation will reduce air-filling volume, avoid deformation of intestinal tract and movement of lesion position. Endoscopists have developed such internal traction methods as silk thread, elastic band and S-O clip [8, 10, 15]. These methods could offer variety of traction direction meet the clinical need.

Therefore, we designed a new traction device "traction ring" which can be used in colorectal ESD. The materials are easy to obtain and manufacture of the ring is simple. The traction can be completed by matching with the clips which is commonly available. The Annular duct at both ends of the traction ring can assist doctors to locate and fix by clips, as to reduce the difficulty of setting the traction device. Besides, the design of the traction ring can avoid the situation that the tension on both ends of the elastic ring is unequal due to the asymmetry of the fixed position in the ESD operation. Internal traction can be achieved through traction ring, and will not be interfered by the physiological structure of the colon and movement of endoscope, such independence prevented paradoxical or unintended movements. In the colon that above sigmoid, especially the lesions at transverse and descending colon and cecum, satisfactory traction can also be obtained. By employed the same way to obtain countertraction in lower gastrointestinal lesions, will decrease the time cost of learning traction method.

Our retrospective study suggests that the traction ring is relatively successful in exposing the tumor margins for resection. Besides, the mean en bloc rate and R0 resection rate in our study respectively was 95% and 90%, which was the more than that the rate in the other reports [16–18], and this might be a potential advantage of this method. Preparation and retrieve of the traction system are quick and easy, settlement of the system never took more than 4 minutes, accounting for only 2.7% of the whole procedure time. All traction rings were successfully retrieved, and procedures were safely proceeded, none of the lesions was there damage caused by traction. The rate of adverse event which was the same or less than the rate of previous study [16–18]. Research shows that giant tumor, lateral developmental tumor, right hemicolon, severe fibrosis, deep invasion of T1 phase tumor are risk factors of perforation [19–20]. In our study, a patient with a 50 mm laterally spreading tumor located at splenic flexure suffered from perforation. Since it has been successfully closed during operation, no extra treatment was required.

This study has the following limitations: Firstly, the small sample size included in this retrospective study. Moreover, the patients included in this trial were according to operators' preference. Further studies are required to verified the applicability of traction ring.

## Conclusion

This retrospective study demonstrated that the new countertraction method (traction ring) may become a safe, effective and simple way to assist ESD for colorectal lesions. At present, a prospective study is being carried out in our center to evaluate the validity and safety of traction ring assisted colorectal ESD.

## Abbreviations

Endoscopic Mucosal Resection (EMR)

Endoscopic Submucosal Dissection (ESD)

## Declarations

## **Ethics approval and consent to participate**

The use of the traction ring method was approved by Bioethics Committee of Beijing Friendship Hospital, Capital Medical University, and informed consent was obtained from each patient (Approved No. of ethic committee: 2019-P2-024-01). This is an observation study, the research has not been registered. The consents for collecting data have been obtained by written form from all the patients that included in this study.

## **Consent for publication**

The consents for publication have been obtained by written form from all the patients that included in this study.

## **Availability of data and materials**

The datasets analysed during the current study are available from the corresponding author on reasonable request.

## **Competing interests**

The authors declare that they have no competing interests

## **Funding**

The research has no funding source to declare.

## **Authors' Contributions**

All the authors have contributed significantly: HZ and SZ: Study concept and design, revision of the manuscript, approval of the final version of the manuscript (These two authors contributed equally to this article.). XH: Study design, acquisition of data, statistical analysis, drafting of the manuscript. MJ: Study design, Operator for endoscopic submucosal dissection. PL, YN, FM Li Yu, YW, HZ, FL: Operators for endoscopic submucosal dissection. Furthermore, every author listed has had the opportunity to read and comment upon the submitted manuscript and has approved of the version to be published.

## **Acknowledgments**

Not applicable

## **References**


1. Belderbos TD, Leenders M, Moons LM, Siersema PD. Local recurrence after endoscopic mucosal resection of nonpedunculated colorectal lesions: systematic review and meta-analysis. *Endoscopy*. 2014;46(5):388–402.

2. Arezzo A, Passera R, Marchese N, Galloro G, Manta R, Cirocchi R. Systematic review and meta-analysis of endoscopic submucosal dissection vs endoscopic mucosal resection for colorectal lesions. *United Eur Gastroenterol J*. 2016;4(1):18–29.
3. Tanaka S, Kashida H, Saito Y, Yahagi N, Yamano H, Saito S. Japan gastroenterological endoscopy society guidelines for colorectal endoscopic submucosal dissection/endoscopic mucosal resection. *Dig Endosc*. 2020;32(2):219–39. doi:10.1111/den.13545.
4. Takeuchi Y, Iishi H, Tanaka S, Saito Y, Ikematsu H, Kudo S, et al. Factors associated with technical difficulties and adverse events of colorectal endoscopic submucosal dissection:retrospective exploratory factor analysis of a multicenter prospective cohort. *Int J Colorectal Dis*. 2014;29(10):1275–84.
5. Marmol I, Sanchez-de-Diego C, Pradilla Dieste A, Cerrada E, Rodriguez Yoldi MJ. Colorectal carcinoma:A general overview and future perspectives in colorectal cancer. *Int J Mol Sci*. 2017;18(1):197.
6. Cai SL, Shi Q, Chen T, Zhong YS. Dental floss traction assists in treating gastrointestinal mucosal tumors by endoscopy. *J Laparoendosc Adv Surg Tech A*. 2015;25(7):571–6.
7. Uraoka T, Kato J, Ishikawa S, Harada K, Kuriyama M, Takemoto K, et al. Thin endoscope-assisted endoscopic submucosal dissection for large colorectal tumors (with videos). *Gastrointest Endosc*. 2007;66(4):836–9.
8. Ritsuno H, Sakamoto N, Osada T, Goto SP, Murakami T, Ueyama H, et al. Prospective clinical trial of traction device-assisted endoscopic submucosal dissection of large superficial colorectal tumors using the S-O clip. *Surg Endosc*. 2014;28(11):3143–9.
9. Ferlay J, Soerjomataram I, Dikshit R, Eser S, Mathers C, Rebelo M, et al. Cancer incidence and mortality worldwide:sources, methods and major patterns in GLOBOCAN 2012. *Int J Cancer*. 2015;136(5):359–86.
10. Mori H, Kobara H, Nishiyama N, Fujihara S, Matsunaga T, Masaki T. Novel effective and repeatedly available ring-thread counter traction for safer colorectal endoscopic submucosal dissection. *Surg Endosc*. 2017;31(7):3040–7.
11. Imaeda H, Hosoe N, Ida Y, Nakamizo H, Kashiwagi K, Kanai T, et al. Novel technique of endoscopic submucosal dissection by using external forceps for early rectal cancer (with videos). *Gastrointest Endosc*. 2012;75(6):1253–7.
12. Cai SL, Shi Q, Chen T, Zhong YS. Dental floss traction assists in treating gastrointestinal mucosal tumors by endoscopy. *J Laparoendosc Adv Surg Tech A*. 2015;25:571–6.
13. Matsuzaki I, Isobe S, Hirose K, Marukawa T, Esaki M. Magnetic anchor-guided endoscopic submucosal dissection for colonic tumor. *Gastrointest Endosc*. 2017;85(5):1111–2.
14. Saito Y, Emura F, Matsuda T, Uraoka T, Nakajima T, Ikematsu H, et al. A new sinker-assisted endoscopic submucosal dissection for colorectal cancer. *Gastrointest Endosc*. 2005;62(2):297–301.
15. Lupu A, Jacques J, Rivory J, Rostain F, Pontette F, Ponchon T, et al. Endoscopic submucosal dissection with triangulated traction with clip and rubber band: the "wallet" strategy. *Endoscopy*.

2018; 50.

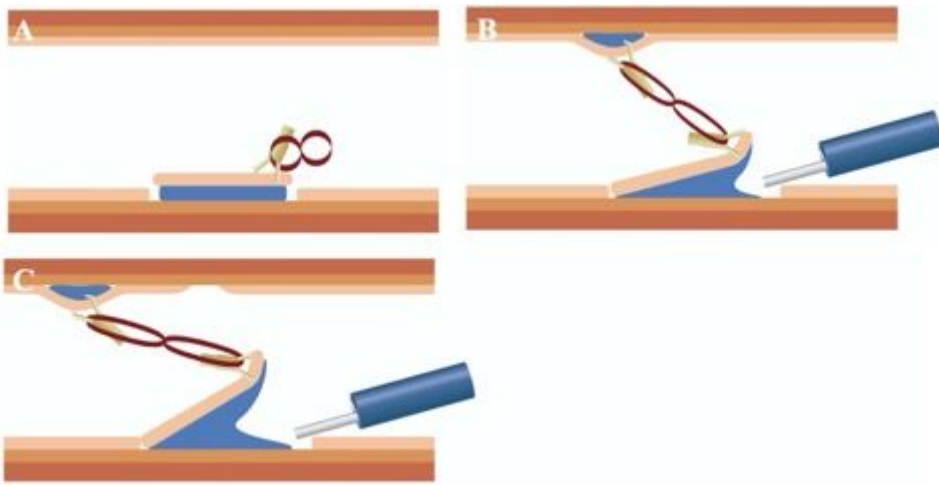
16. Yamamoto H. Endoscopic submucosal dissection—current success and future directions. *Nat Rev Gastroenterol Hepatol*. 2012;9(9):519–29.
17. Niimi K, Fujishiro M, Kodashima S, Goto O, Ono S, Hirano K, et al. Long-term outcomes of endoscopic submucosal dissection for colorectal epithelial neoplasms. *Endoscopy*. 2010;42(9):723–9.
18. Nishiyama H, Isomoto H, Yamaguchi N, Fukuda E, Ikeda K, Ohnita K, et al. Endoscopic submucosal dissection for colorectal epithelial neoplasms. *Dis Colon Rectum*. 2010;53(2):161–8.
19. Isomoto H, Nishiyama H, Yamaguchi N, Fukuda E, Ishii H, Ikeda K, et al. Clinicopathological factors associated with clinical outcomes of endoscopic submucosal dissection for colorectal epithelial neoplasms. *Endoscopy*. 2009;41:679–83.
20. Kim ES, Cho KB, Park KS, Lee KI, Jang BK, Chung WJ, et al. Factors predictive of perforation during endoscopic submucosal dissection for the treatment of colorectal tumors. *Endoscopy*. 2011;43:573–8.

## Figures



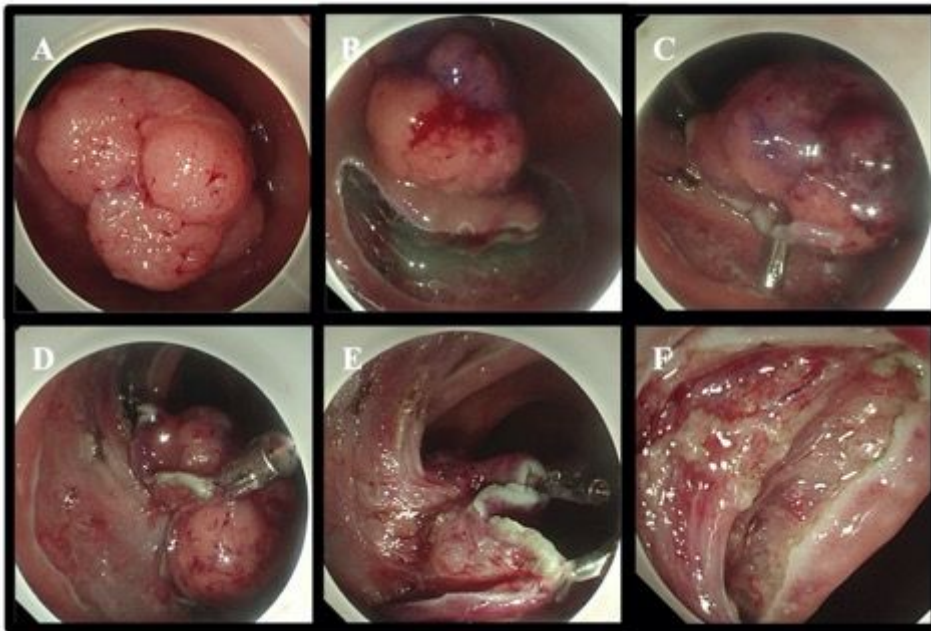
**Figure 1**

Basic structure of traction ring. Traction ring assisted ESD. Traction ring is made of subtransparent elastic rubber material. The basic shape is two connected hoops, similar to the Arabic number "8". The length of device used in this study was 5mm (shown in Fig. 1. a). The hole at each end allows arm of endoclip pass easily (shown in Fig. 1. b).



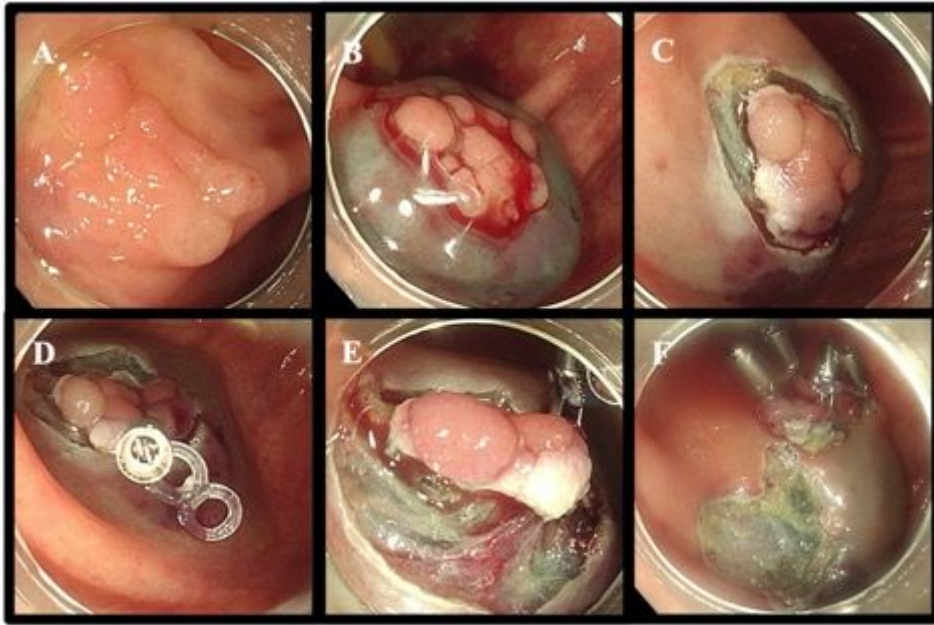
**Figure 2**

Traction ring assisted ESD. Traction ring was firstly applied to the exfoliated mucosa by endoclip (shown in Fig. 2. a). Submucosal injections then applied into submucosal tissue of colorectal wall opposite the lesion, the other end of traction ring then fixed to the elevated point by endoclip, enabled excellent traction and visualization of the submucosal layer. (shown in Fig. 2. b). The direction of pulling force can be changed by removing and repositioning the traction ring (shown in Fig. 2. c).



**Figure 3**

Images of traction ring assisted ESD for rectal lesions. (A. 25-mm Isp tumor at rectum was observed; B. Submucosal injection shown positive lifting sign, circumferential dissection of normal tissue was performed; C. Poor visibility due to the angularity of rectum; D. The edge of exfoliated mucosa was grasped with the first traction ring; E. A second traction ring had to be applied, and the submucosal layer was lifted, achieving good visibility; F. Wound shown no active bleeding or perforation.)



**Figure 4**

Images of traction ring assisted ESD for colonic lesions. (A. 15-mm laterally spreading tumor at cecum can be seen under the white light colonoscope; B. Submucosal injection shown positive lifting sign; C. Poor exposure of submucosa during the dissection process; D. Traction ring was fixed at the edge of the exfoliated mucosa; E. Submucosa layer was clearly exposed; F. Wound shown no active bleeding or perforation, fully exfoliated lesion was attached to traction ring.)