

Interleukin 37 Expression was Negatively Associated with Pathological Grading in Human Gliomas

Sheng Liu

Binzhou Medical University Hospital

Ying Ba

Binzhou Medical University Hospital

Chenglong Li

Binzhou Medical University Hospital

Mengyang Xing

Binzhou Medical University Hospital

Tao Zhang

Binzhou Medical University Hospital

Yongliang Liu

Binzhou Medical University Hospital

Yang Gao

Binzhou Medical University Hospital

Guangming Xu (✉ sdslxuguangming@163.com)

Shandong Provincial Hospital, Cheeloo College of Medicine, Shandong University

Research

Keywords: Glioma, interleukin 37, prognosis, cytokine

Posted Date: March 15th, 2021

DOI: <https://doi.org/10.21203/rs.3.rs-318636/v1>

License: © ⓘ This work is licensed under a Creative Commons Attribution 4.0 International License.

[Read Full License](#)

Abstract

Background: Little is known about the roles of interleukin 37 (IL-37), a newly identified cytokine, in the pathogenesis of cancer. In this study, we aimed to determine the expression of IL-37 in gliomas with different pathological grades and evaluated its effects on survival.

Methods: Ninety-five participants with different pathological grades of glioma were included in this study, which were classified into grade I-II (n=27), grade III (n=30), and grade IV (n=38). Ten normal brain tissues that were resected for intracranial decompression after traumatic brain injuries served as control group. The expression of IL-37 mRNA and protein in glioma tissues was determined using Real-time PCR and immunohistochemical techniques. The association between IL-37 expression and various clinicopathologic factors was evaluated.

Results: IL-37 mRNA was expressed in normal tissues and tumor tissues, and the expression of IL-37 in tumor tissues were significantly higher than normal brain tissue ($p<0.05$). IL-37 expression showed decline with the increase of grade level. The expression of IL-37 was significantly lower in glioma tissues of a high malignancy compared with the glioma tissues of a low malignancy. Patients with low IL-37 expression showed a shorter survival time.

Conclusions: Low IL-37 expression was negatively correlated with pathological grade, rather than pathological type. Low IL-37 was positively correlated with survival time. Thus, IL-37 maybe plays an inhibitory role in glioma progression.

Background

Glioma is one of the most common malignant brain tumors arising throughout the central nervous system (CNS).[1] Nowadays, several factors have been considered to be associated with the pathogenesis of glioma, including occupational exposure, gene mutation, and ionizing radiation.[2] The treatment of high-grade glioma is mainly relied on the multimodality therapy, including mini-invasive therapy, radiotherapy, and chemotherapy. However, its therapeutic efficacy is still not satisfactory, with a low 5-year survival rate of 20%, especially in patients with poorly differentiated glioma. Invasion and angiogenesis have been reported to induce post-operative recurrence and poor prognosis.[3] Up to now, there is still a lack of biomarkers closely related to the occurrence, growth, invasion and prognosis of glioma. Increasing evidence indicates that immune cells and inflammatory signaling pathways contribute to the tumor growth and immune escape. Besides, the anti-inflammatory cytokines might play important roles in these processes.[4] Therefore, it is necessary to develop cytokines-based strategy for predicting the prognosis of glioma.

As a newly identified inhibitor of innate and adaptive immunity,[5, 6] interleukin 37 (IL-37) was located on chromosome 2 containing six exons that encoded the protein with a molecular weight of 17–26 KD.[7] It was reported to be constitutively expressed in several organs and tissues such as brain, lymph nodes, thymus, lungs, placenta, colon, testis, skin, uterus, monocytes, as well as bone marrow.[8] To date, five

splice variants of IL-37, designated as IL-37a-e, encoding 157–218 residues have been identified.[9] Among these variants, only IL-37a has been recognized to be expressed in brain,[5] and little is known about its roles in the biomedical processes, especially the pathogenesis of cancer. Recent studies indicated that IL-37 could suppress the progression of several malignancies such as colon cancers,[10] hepatocellular cancer,[11, 12] renal cancer,[13] as well as lung cancer.[14, 15] Besides, it has been identified as a fundamental suppressor of innate immunity and inflammatory responses. Moreover, growing evidence showed that IL-37 involved in regulating a variety of biological properties, such as proliferation, apoptosis, and invasion. In this study, we investigated the roles of IL-37 in modulating the invasion and migration of glioma.

Methods

Patients and sample collection

In this study, 95 gliomas patients of various types and grades admitted to our hospital between September 2013 and December 2019 were included. The diagnosis of glioma was given based on histological examination. Gliomas were categorized as grade I-IV according to the WHO classification systems of tumors involving CNS. In addition, ten normal brain tissues that were resected for intracranial decompression after traumatic brain injuries served as control group. Patients with the following conditions were excluded from this study: i) with infectious diseases, nervous system diseases, tumors of other organs, autoimmune diseases, and liver and kidney dysfunction, trauma or other chronic diseases; and ii) patients received any preoperative chemotherapy or radiotherapy prior to sample collection. The clinicopathological features, including age, gender, preoperative Karnofsky Performance Status (KPS) score and image findings were collected before the initial surgery. All patients underwent craniotomy with tumor resection.

Quantitative Real-Time PCR

Total RNA was extracted from glioma and non-neoplastic brain tissues using Trizol reagent (Invitrogen, Carlsbad, CA, USA). The U6 small nuclear RNA was amplified as a loading control. The IL-37 and endogenous control U6-Specific cDNA were synthesized from total RNA using gene-specific primers and MultiScribe reverse transcriptase according to the TaqMan MicroRNA assays protocol (Applied Biosystems, Foster City, CA, USA). PCR was performed on the 7500 RT-PCR ABI system (ABI, USA) using the specific primer sequences as follows: IL-37, 5'-GATCACAAAGTACTGGTCCTGG-3' and 5'-TCCTTTATCCTTGTCACAGTAG-3'; U6, 5' -CGC TTC AGC ACA TAT ACT A-3', and 5' -CGC TTC ACG AAT TTG CGT GTC A-3'. PCR was carried out in a 20 μ L reaction volume containing 10 μ L Platinum_SYBR Green (Invitrogen, Guangzhou, China), 0.8 μ L each primer (10 μ M), and 1 μ L cDNA. The PCR conditions consisted of denaturation at 95°C for 10 min, followed by 40 cycles of denaturation at 94°C for 15 sec, annealing at 60°C for 60 sec. The amplification results for real-time PCR was calculated as $2^{-(\Delta\Delta Ct)}$.

Immunohistochemical stain

Immunohistochemistry (IHC) was given to the glioma and non-neoplastic brain tissues. Upon fixation using formalin, tumor sections (3 μm) were de-paraffinized in xylene dewaxing and gradient ethanol hydration. A microwave-based antigen retrieval process was conducted with sodium citrate solution (pH 6.0) for 15 min. Endogenous peroxidase was inactivated with 3% H_2O_2 for 10 min at room temperature. The non-specific binding was blocked by fetal bovine serum (FBS) for 15 min, and then sections were incubated with the mouse anti-human IL-37 monoclonal antibody (Abcam: ab57187, USA; dilution 1/250) overnight at 4°C. Afterwards, the sections were then incubated with horseradish peroxidase labeled anti-mouse IgG (Santa Cruz Biotechnology, USA; dilution 1/1000) at 37°C for 1 h. Finally, the sections were stained with DAB (Beyotime, Beijing, China) in 0.3% H_2O_2 for 2 min, followed by counterstaining with hematoxylin.

IHC staining results were evaluated by two independent pathologists in a blinded manner. The sections were scored semi-quantitatively according to the number of IL-37-producing cells observed under a magnification of 200 \times and 400 \times , respectively. The number of positive staining cells was counted in three representative fields that were randomly selected. The staining extent was scored from 0 to 3 based on the percentage of positive cells (0, no staining; 1–3, light to dark brown). Positive cell rate was defined based on random selection of 5 visual fields as follows: 0, no positive cells; 1, a positivity of 25%; 2, a positivity of 25%–50%; 3, a positivity of > 50%. The final score of IL-37 expression was calculated as the sum of percentage positive score and the staining intensity score. Low expression was defined as a score in a range of 0–1, and high expression was considered in the presence of a score of 2–3.

Prognosis and follow-up

Clinical follow-up was available for all patients. For the analysis of survival and follow-up, the follow-up was performed since the day when the surgery was given. The follow-up was given by telephone every 3 months until February 2020. The overall survival (OS) was defined as the time from surgery to death or the last follow-up.

Statistical analysis

GraphPad Prism was used for the statistical analysis. Measurement data were presented as mean \pm standard deviation. Countable data were expressed by cases or percentage. A statistical comparison between glioma tissues and normal brain tissues was determined by the independent-samples t-test. Multiple-group comparison was analyzed by one-way analysis of variance. The Chi-square test was used to analyze the association between IL-37 expression and various clinicopathologic factors. A multivariate Cox proportional hazards regression model was used for multivariable analysis to evaluate the effect of multiple independent prognostic factors on survival outcome. $p < 0.05$ was considered to be statistically significant.

Results

Patient characteristics

In total, 95 cases (male: 41; female: 54) were enrolled in the present study. They were aged in a range of 30 to 74 years (mean ages: 55.5 ± 8.7 years). No statistical differences were noticed in the baseline data between the two groups ($p > 0.05$). For the tumor staging, 27 were of grade I-II, 30 of grade III, and 38 of grade IV, respectively (Table 1).

Table 1
Association between IL-37 expression and clinic pathological characteristics of gliomas.

Variables	Total, n	IL-37 expression		<i>p</i> value
		Low expression, n	High expression, n	
Gender				0.6729
Male	41	29	12	
Female	54	36	18	
Age				0.2617
≤ 45	33	25	8	
> 45	62	40	22	
Tumor size				0.3514
≤ 5 cm	44	28	16	
> 5cm	51	37	14	
Tumor location				0.8520
Frontal	31	22	9	
Temporal	26	19	7	
other	38	24	12	
KPS				0.0003
≤ 80	57	47	10	
> 80	38	18	20	
WHO grade				< 0.0001
I-II	27	8	19	
III-IV	68	57	11	

IL-37 was poorly expressed in glioma samples

As shown in Fig. 1, low expression of IL-37 mRNA was observed in 65 (68.42%) glioma samples. Expression of IL-37 mRNA in glioma tissues was significantly lower than that of non-neoplastic brain

tissues ($p < 0.01$). Consistent with the qRT-PCR findings, IHC findings indicated that IL-37 protein expression in the glioma tissues was significantly down-regulated compared with that of the non-neoplastic brain tissues ($p < 0.05$). Moreover, the down regulation of IL-37 was more significant in those with a higher glioma grade. Positive IL-37 staining was mainly detected in the non-neoplastic brain tissues, which was located in the cytoplasm of the gliocytes (Fig. 2).

Association of IL-37 expression with clinicopathological parameters of human gliomas

To investigate the association between the IL-37 expression and the clinicopathological characteristics of human gliomas, clinical follow-up was performed for all patients (Table 1). In glioma tumor tissues, there was variation in the level of IL-37 expression (Fig. 1). Based on the IHC results and the relative expression of IL-37, the 95 glioma specimens were divided into low expression group ($n = 65$) and high expression group ($n = 30$), based on the IL-37 expression of less than or above the median expression level, respectively. Our data showed that IL-37 expression was significantly correlated with the pathological grade. As shown in Fig. 1, IL-37 down-regulation was associated with the ascending histopathological grade of glioma. For the glioma grades proposed by WHO, there was a significant down-regulation of IL-37 in both grade III and IV gliomas tissues compared to grade I and II gliomas ($p < 0.001$). This indicated that there was a negative correlation between the IL-37 expression and gliomas malignancy. Similarly, low IL-37 expression was commonly detected in the glioma patients with a lower KPS score ($p = 0.0003$). On this basis, we speculated that glioma tissues with down-regulation of IL-37 showed a higher pathological grade and lower KPS. In addition, no significant differences were observed between IL-37 expression and other clinicopathological parameters, including gender, age at diagnosis, or tumor location and size.

Down-regulation of IL-37 was associated with poor prognosis in glioma patients

Cox proportional hazards regression model was utilized to evaluate the association between IL-37 down-regulation and the prognosis of patients. Univariate survival analysis strongly suggested that pathological grade, IL-37 expression and the KPS were closely correlated with the OS. As determined by the log-rank test, patients with high IL-37 expression had a longer survival time than those with low IL-37 expression. Multivariate Cox regression analysis showed that OS was significantly associated with the pathological grade ($p = 0.0054$) and IL-37 expression levels ($p = 0.0036$). Furthermore, the prognosis of glioma patients with low IL-37 expression was poorer than those with a high IL-37 expression (720 vs. 1036 days, $p = 0.0019$). These results suggested that there was reduction of IL-37 expression in human glioma. In addition, IL-37, WHO grade, and KPS score were closely correlated with OS. Besides, these were independent prognostic factors for patients with gliomas (Fig. 3).

Follow-up

In this study, 77 patients (81.1%) received adjuvant chemotherapy and 62 (65.3%) received radiotherapy. By the end of follow-up, 65 patients (68.4%) were still alive, while 20 (21.1%) were died and 10 (10.5%) were lost in the follow-up.

Discussion

Despite the advances in the treatment options, the prognosis of glioma is still poor.[16] Thus, it is urgent to develop novel diagnostic, prognostic, and therapeutic modalities.[2] To date, the diagnosis and treatment of glioma are mainly based on histopathology and grading according to the WHO classification system.[1] Up to now, some cytokines differentially expressed in glioma tumors have been implicated in upregulating cell growth, proliferation, migration, invasion, angiogenesis and transformation, as well as apoptosis.[4] We focused on the roles of IL-37 in modulating the invasion and migration of glioma. Our data showed that IL-37 expression was low in glioma, which may serve as a predictor for the prognosis of glioma.

IL-37 has been identified as a natural suppressor for inflammatory and immune responses in immunological field.[17] It has been shown that IL-37 is highly expressed in inflammatory tissues, which inhibits excessive inflammatory responses both in innate and acquired immune responses by down-regulating pro-inflammatory molecules.[18] Cancer and inflammation are two reciprocally regulated events. Tumor cells can usually generate a regional inflammatory environment, and conversely, inflammatory environment will further promote malignant transformation.[19] Nowadays, IL-37 is recognized as a major mediator in either immunoregulation or tumorigenesis.[20] Some studies have investigated the protective roles of IL-37 in a wide range of human cancers. IL-37 has antitumor effects in hepatocellular carcinoma,[11, 12] cervical cancer,[21, 22] breast cancer, renal cancer [13, 19] non-small cell lung cancer (NSCLC),[15, 23] and oral squamous cell carcinoma.[6] In gastric cancer, IL-37 involved in the tumor inhibition in mice.[24] In NSCLC, cervical cancer and renal cell carcinoma, IL-37 expression was observed to inhibit the proliferation and invasion of cancer cells through IL-6/stat3 pathway.[13, 15, 21] In a previous study based on colorectal carcinoma cells, overexpression of IL-37 suppressed cell migration and invasion by inhibiting β -catenin.[10] These studies implicated that IL-37 may involve in the inhibition of tumor cells. Nevertheless, little is known about the precise clinical implications of IL-37 in the pathogenesis, progression, and prognosis of glioma.

IL-37 was expressed in a variety of normal cells and tissues, while some IL-37 isoforms were seem to be expressed in a tissue specific manner.[5] Whereas, IL-37b was generally focused upon, it would be critical to investigate the role of other functional isomers, especially IL-37a that was merely expressed in brain tissues containing 4 exons of the gene except exon 1 and exon 2. IL-37a showed a unique N-terminus encoded by exon 3 that was absent in IL 37c-e, encompassing a very typical NLS just upstream of the putative elastase cleavage site.[9] The sequence encoded by exon 3 gave rise to a prodomain, which was processed into the mature form of IL 37a protein.[8] The exons 4–6 encode 12 putative strands predicted to form the trefoil structure, which was the characteristics of IL-1 family.[7] This suggested that IL-37a might be a functional cytokine.

In this study, we investigated the expression of IL-37 protein and the effects of IL-37 level on the glioma grade. IHC findings indicated that IL-37 was expressed in normal brain tissues, which was down-regulated in glioma tissues. Our data indicated that the expression of IL-37 in glioma tissues was negatively associated with advanced WHO grade and low KPS score. This implied that the loss of IL-37 may promote the aggressive progression of glioma. Moreover, Kaplan Meier analysis and multivariate Cox regression analysis showed that low intratumoral IL-37 expression was correlated with a shorter OS and disease-free survival (PFS). This demonstrated that IL-37 might present inhibitory ability in the pathogenesis of glioma. Subgroup analyses further suggested that IL-37 might act as an independent prognosticator for glioma patients with high histopathologic grades (grade III and IV) rather than those with low histopathologic grades (I and II). To our knowledge, this is the first analysis to systematically estimate the relationship between IL-37 and the WHO glioma grade. However, no significant correlations were found between the IL-37 level and other clinical features such as gender, age, tumor location, or extent of surgical resection. The above results indicated that IL-37 may be suitable to predict prognosis in human gliomas after operation, but these results should be validated based on more representative cohorts of glioma patients involving a large sample size.

There are some limitations in our study. First, this is a clinical study with no experimental data on the animals and cell lines. Second, all the subjects included in this study are from Asia, without individuals from the other races. Third, it is unknown whether IL-37 could serve as an independent prognostic index as there is a lack of comparison with the other acknowledged indices for the classification of glioma. Finally, more evidences are needed to support the roles of miRNAs in the pathogenesis of glioma.

In conclusion, the expression of IL-37 was low in glioma. Low IL-37 expression was negatively correlated with pathological grade, rather than pathological type. Low IL-37 was positively correlated with survival time and plays an inhibitory role in glioma progression.

Declarations

Ethics approval and consent to participate

Each patient signed the informed consent. The study procedures were approved by the Ethics Committee of Shandong Provincial Hospital and Binzhou Medical University Hospital.

Consent for publish

Written informed consent was obtained from the participants for publication of this article and any accompanying tables/images. A copy of the written consent is available for review by the Editor of this journal.

Availability of data and material

The datasets used and analysed during the current study are available from the corresponding author on reasonable request.

Competing interest

None.

Funding

This study was supported by the Natural Science Foundation of Binzhou Medical University (BY2019KJ24).

Author contributions

LS wrote the manuscript; YG and XGM revised the manuscript; BY, LCL and XMY did the data analysis; ZT and LYL did the data collection. All authors have read and approved the manuscript.

Acknowledgments

Not applicable.

References

1. Chen R, Smith-Cohn M, Cohen AL, Colman H. Glioma Subclassifications and Their Clinical Significance. *Neurotherapeutics*. 2017;14(2):284–97.
2. Reni M, Mazza E, Zanon S, Gatta G, Vecht CJ. Central nervous system gliomas. *Crit Rev Oncol Hematol*. 2017;113:213–34.
3. Tom MC, Cahill DP, Buckner JC, Dietrich J, Parsons MW, Yu JS. Management for Different Glioma Subtypes: Are All Low-Grade Gliomas Created Equal? *Am Soc Clin Oncol Educ Book*. 2019;39:133–45.
4. Gusyatiner O, Hegi ME. Glioma epigenetics: From subclassification to novel treatment options. *Semin Cancer Biol*. 2018;51:50–8.
5. Dinarello CA, Bufler P. Interleukin-37. *Semin Immunol*. 2013;25(6):466–8.
6. Ding VA, Zhu Z, Xiao H, Wakefield MR, Bai Q, Fang Y. The role of IL-37 in cancer. *Med Oncol*. 2016;33(7):68.
7. Nold MF, Nold-Petry CA, Zepp JA, Palmer BE, Bufler P, Dinarello CA. IL-37 is a fundamental inhibitor of innate immunity. *Nat Immunol*. 2010;11(11):1014–22.
8. Boraschi D, Lucchesi D, Hainzl S, Leitner M, Maier E, Mangelberger D, et al. IL-37: a new anti-inflammatory cytokine of the IL-1 family. *Eur Cytokine Netw*. 2011;22(3):127–47.
9. Tete S, Tripodi D, Rosati M, Conti F, Maccauro G, Saggini A, et al. IL-37 (IL-1F7) the newest anti-inflammatory cytokine which suppresses immune responses and inflammation. *Int J Immunopathol Pharmacol*. 2012;25(1):31–8.
10. Yan X, Zhao J, Zhang R. Interleukin-37 mediates the antitumor activity in colon cancer through β -catenin suppression. *Oncotarget*. 2017;8(30):49064–75.

11. Li TT, Zhu D, Mou T, Guo Z, Pu JL, Chen QS, et al. IL-37 induces autophagy in hepatocellular carcinoma cells by inhibiting the PI3K/AKT/mTOR pathway. *Mol Immunol.* 2017;87:132–40.
12. Zhang Z, Zhang J, He P, Han J, Sun C. Interleukin-37 suppresses hepatocellular carcinoma growth through inhibiting M2 polarization of tumor-associated macrophages. *Mol Immunol.* 2020;122:13–20.
13. Jiang Y, Wang Y, Liang L, Gao Y, Chen J, Sun Y, et al. IL-37 mediates the antitumor activity in renal cell carcinoma. *Med Oncol.* 2015;32(11):250.
14. Chen YH, Zhou BY, Wu GC, Liao DQ, Li J, Liang SS, et al. Effects of exogenous IL-37 on the biological characteristics of human lung adenocarcinoma A549 cells and the chemotaxis of regulatory T cells. *Cancer Biomark.* 2018;21(3):661–73.
15. Jiang M, Wang Y, Zhang H, Ji Y, Zhao P, Sun R, et al. IL-37 inhibits invasion and metastasis in non-small cell lung cancer by suppressing the IL-6/STAT3 signaling pathway. *Thorac Cancer.* 2018;9(5):621–9.
16. Ostrom QT, Gittleman H, Stetson L, Virk SM, Barnholtz-Sloan JS. Epidemiology of gliomas. *Cancer Treat Res.* 2015;163:1–14.
17. Jia H, Liu J, Han B. Reviews of Interleukin-37: Functions, Receptors, and Roles in Diseases. *Biomed Res Int.* 2018;2018:3058640.
18. Cavalli G, Dinarello CA. Suppression of inflammation and acquired immunity by IL-37. *Immunol Rev.* 2018;281(1):179–90.
19. Mei Y, Liu H. IL-37: An anti-inflammatory cytokine with antitumor functions. *Cancer Rep (Hoboken).* 2019;2(2):e1151.
20. Abulkhir A, Samarani S, Amre D, Duval M, Haddad E, Sinnett D, et al. A protective role of IL-37 in cancer: a new hope for cancer patients. *J Leukoc Biol.* 2017;101(2):395–406.
21. Wang S, An W, Yao Y, Chen R, Zheng X, Yang W, et al. Interleukin 37 Expression Inhibits STAT3 to Suppress the Proliferation and Invasion of Human Cervical Cancer Cells. *J Cancer.* 2015;6(10):962–9.
22. Ouyang P, Wu K, Su L, An W, Bie Y, Zhang H, et al. Inhibition of human cervical cancer cell invasion by IL-37 involving runt related transcription factor 2 suppression. *Ann Transl Med.* 2019;7(20):568.
23. Ge G, Wang A, Yang J, Chen Y, Yang J, Li Y, et al. Interleukin-37 suppresses tumor growth through inhibition of angiogenesis in non-small cell lung cancer. *J Exp Clin Cancer Res.* 2016;35:13.
24. Zhang Y, Tang M, Wang XG, Gu JH, Zhou LN, Jin J, et al. Elevated serum levels of interleukin-37 correlate with poor prognosis in gastric cancer. *Rev Esp Enferm Dig.* 2019;111(12):941–5.

Figures




Figure 1

Expression of IL-37 mRNA after Real-Time PCR in the normal tissues and gliomas of various grades. $p < 0.05$.

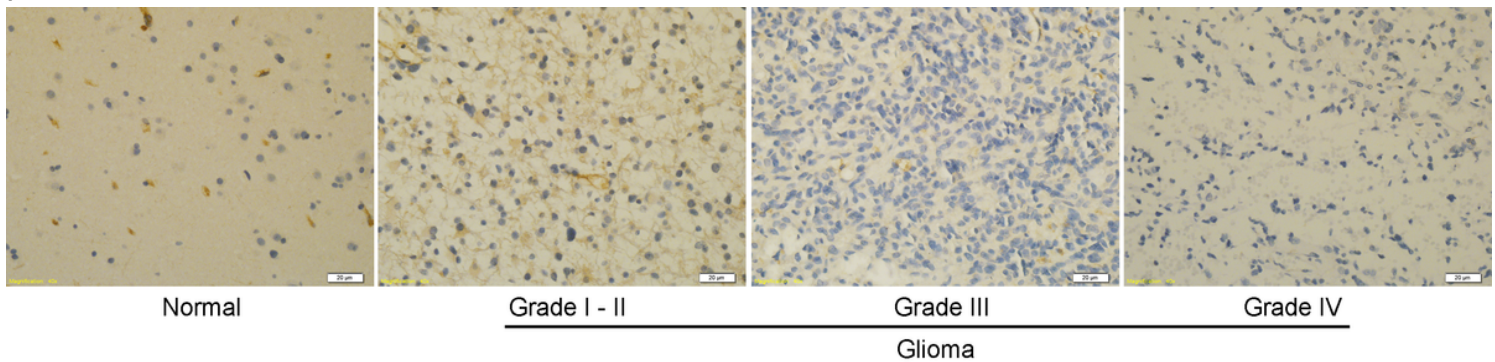
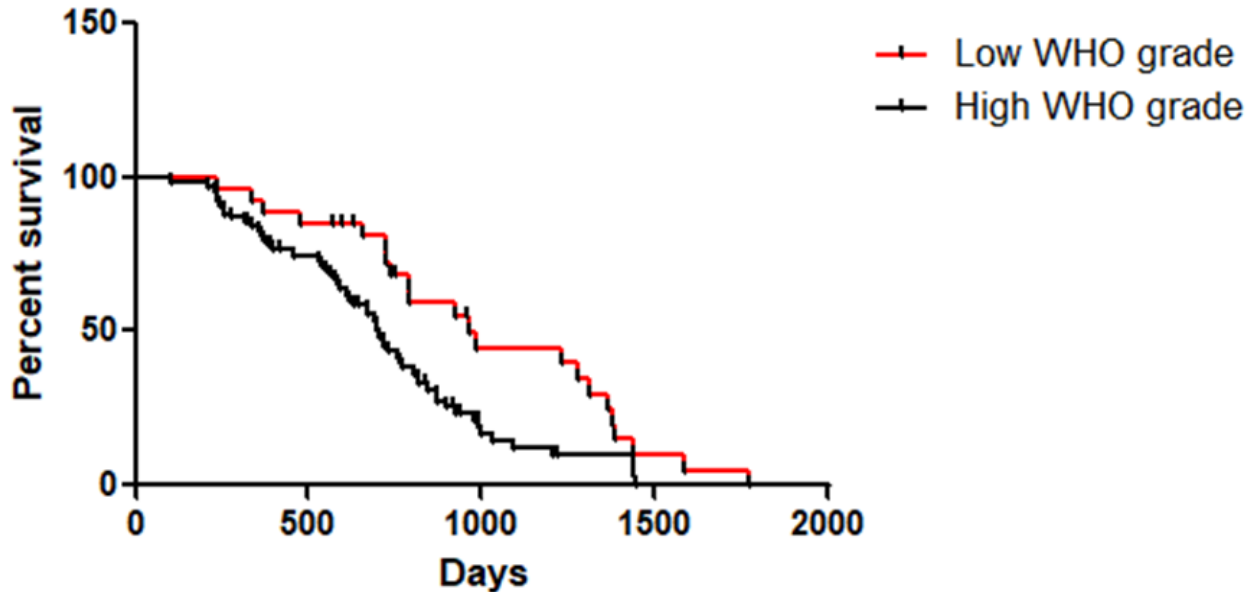
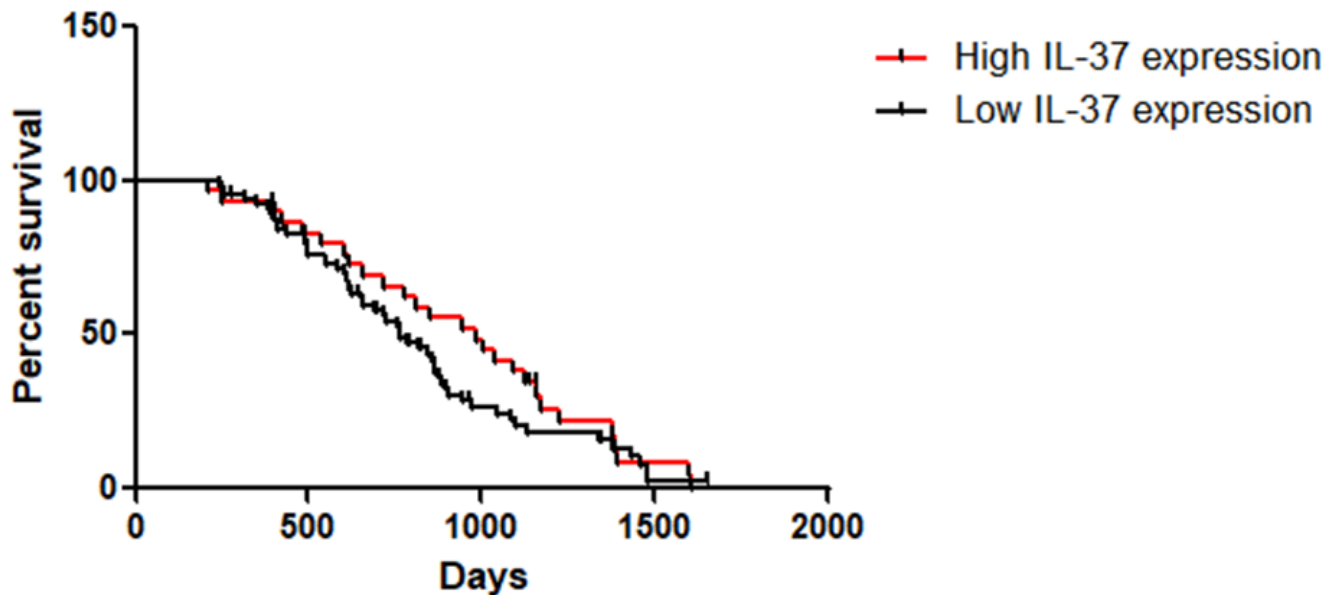


Figure 2

Immunohistochemical staining of IL-37 in the normal tissues and glioma tissues of various grades. The images were observed under a magnification of 40 ×.

A**Survival of Two groups: Survival proportions****B****Survival of Two groups: Survival proportions****Figure 3**

Kaplan–Meier curves for survival time in patients with gliomas divided according to IL-37 expression and WHO grade. (A) Glioma patients with of a high WHO grade showed a significantly shorter survival time compared to those with a low grade ($p < 0.05$); (B) Patients with low IL-37 expression showed a significantly shorter survival time than those with high IL-37 expression ($p < 0.001$).