

A Comparison between Placement of three interrupted sutures after Triangular Three-snip Punctoplasty vs conventional Triangular Three-snip Punctoplasty for treatment of lower punctal stenosis

Hesham Mohammed Abdulhady (✉ dr.hesham.abdulahady87@gmail.com)

Menoufia University Faculty of Medicine <https://orcid.org/0000-0002-5060-1002>

Hany Khairy

Menoufia University Faculty of Medicine

Amr Awara

Tanta University Faculty of Medicine

Sameh S. Mandour

Menoufia University Faculty of Medicine

Research Article

Keywords: Punctoplasty (TSP), agenesis, post-operative, surgical outcome, 2-snip punctoplasty, triangular 3-snip punctoplasty

Posted Date: March 13th, 2021

DOI: <https://doi.org/10.21203/rs.3.rs-307211/v1>

License:   This work is licensed under a Creative Commons Attribution 4.0 International License.

[Read Full License](#)

Abstract

Aim

is to evaluate surgical outcome of Triangular Three-snip Punctoplasty (TSP) with three interrupted sutures and compare it to conventional Triangular Three-snip Punctoplasty (TSP) in treatment of acquired lower punctal stenosis.

Methods

This prospective study included 40 eyelids of 24 patients with acquired lower punctal stenosis grade 1 or grade 2 were classified in two groups. Group A was treated by triangular 3-snip punctoplasty of the lower punctum followed by three interrupted sutures at the posterior ampulla and group B was treated by conventional triangular 3-snip punctoplasty of the lower punctum. Grade of epiphora and grade of FDDT were measured preoperative then post-operative after 1 week, 1 month, 3 months and 6 months. Success was defined as postoperative improvement of epiphora and FDDT grading with no restenosis to occur.

Results

from 20 eyelids in group A, 16 cases showed success (80%) with patent puncta, 2 cases (10%) showed no change and 2 cases (10%) showed failure with restenosis. While from 20 eyelids in group B, 14 cases showed success (60%) with patent puncta, 4 cases (20%) showed no change and 4 cases (20%) showed failure with restenosis.

Conclusion

proposed triangular 3-snip punctoplasty of the lower punctum followed by three interrupted sutures seems to have better results compared to conventional triangular 3-snip punctoplasty of the lower punctum in treatment of grade 1 or 2 lower punctal stenosis.

Introduction

Punctal stenosis is a common disorder affecting the punctum and accounts for 8% of all cases with epiphora. Kashkouli et al., proposed a grading system for the puncta based on its size and shape. Grade 0: No punctum (agenesis) Grade 1: Papilla is covered with a membrane (difficult to recognize) Grade 2: Less than normal size, but recognizable Grade 3: Normal Grade 4: Small slit (< 2 mm) Grade 5: Large slit (≥ 2 mm) ([1, 2]

However, there is no acceptable universal guideline for the management of punctal stenosis. Several modalities described in the literature including punctal dilatation, 1-snip punctoplasty, 2-snip

punctoplasty, triangular 3-snip punctoplasty, rectangular 3-snip punctoplasty, 4-snip punctoplasty, punctal punching with Kelly's or Riess punch, punctoplasty with mitomycin-C, and inserting perforated punctal plugs, self-retaining bicanalicular stents, or mini-monoka. [2–10]

The triangular 3-snip in its traditional form is based on one cut in the vertical canaliculus, one in the horizontal canaliculus and one cut at the base [11]. The current study examines the role of placing 3 interrupted sutures at posterior wall of the ampulla after triangular 3-snip punctoplasty in achieving successful outcomes and preventing re-approximation of the cut ends in cases of acquired lower punctal stenosis. [12]

Patient And Methods

This is a prospective randomized study which included 40 eyelids of 24 patients with acquired lower punctal stenosis grade 1 or grade 2 according to Kashkouli scale. Patients included in the study were recruited from Menoufia University hospitals in the period from January 2019 to June 2020. Informed consent was obtained from all patients, and the study was approved by the institutional review board. All measures were in accordance with the tenets of the Declaration of Helsinki.

All patients of the study were complaining of epiphora which was graded according to Munk score as follows; grade 0: no epiphora, grade1: occasional epiphora requiring drying or dabbing less than twice a day, grade3: epiphora requiring dabbing two to four times per day, grade4: epiphora requiring dabbing five to 10 times per day & grade 5: epiphora requiring dabbing more than ten times daily or constant tearing. [13]

Patients were classified in two groups. Group A patients were treated by triangular 3-snip punctoplasty of the lower punctum followed by three interrupted sutures at the ampulla. Group B patients were treated by conventional triangular 3-snip punctoplasty of the lower punctum.

Inclusion criteria included; primary acquired lower punctal stenosis grade 1 or 2 according to Kashkouli grading, with patent upper punctum and both canaliculi as well as patent nasolacrimal duct revealed after syringing, with normal lower eyelid margin position.

Exclusion criteria included; Patients with Congenital punctal stenosis, Acute conjunctival allergic punctal stenosis, Punctal stenosis associated with radiotherapy, Lid malposition, Canalicular, lacrimal sac and nasolacrimal duct obstruction revealed after syringing, Previous eyelid or lacrimal drainage system surgery, Blepharitis and ocular surface disorders, Patients with dry eye.

A full history was taken and thorough ophthalmological examination was done for all patients including evaluation of proximal lacrimal drainage system regarding punctal orifices position, shape, grading of stenosis according to Kashkouli et al and exclusion of other causes of epiphora rather than punctal stenosis. Inspection of face and periorbital region for position of the eyelids and puncta, Gross nasal deformity, Facial symmetry, presence of any swelling or fistula in the lacrimal sac area , palpation of

lacrimal sac for regurge test , slitlamp examination of eyelid margin for coaptation with the globe , blepharitis or rubbing lashes , skin for laceration or eczema , conjunctiva for papillae , follicles, hyperemia or discharge , cornea for punctate keratitis, filaments or abrasions , lower Tear meniscus height (TMH) using a 1 mm slit beam.

Fluorescein dye disappearance test (FDDT) where a drop of sterile 2% fluorescein solution or a moistened fluorescein strip is instilled into the conjunctival fornices and tear meniscus was observed after 5 minutes with the help of cobalt-blue filter and results were graded according to Ozgur et al., scale depending on the time of dye clearance as follows; grade1 (<3 minutes), grade2 (3-5 minutes) & grade3 (>5 minutes). [14]

Diagnostic probing and syringing were done to ensure anatomically patent nasolacrimal system and to detect any obstruction distal to the punctum.

Surgical technique

Surgery was performed using an operating microscope under local anaesthesia. We transconjunctivally infiltrate 2% (w/v) lidocaine (with epinephrine in a 1:100,000 weight ratio) from the posterior aspect of the eyelid into the region of the lacrimal canaliculus and punctum. A Nettelship dilator is used to enlarge the stenotic lacrimal punctum. A single blade of a small Westcott spring scissor or Vannus scissor is placed within the ampulla of the lacrimal canaliculus, with the remaining blade placed on the conjunctival surface of the posterior aspect of the eyelid. The first vertical snip is made at the vertical canaliculus. The second vertical snip is made from the edge of the first snip to create a flap. The final horizontal snip was made at the base. The triangular flap is removed and three sutures are placed, in an interrupted manner, at the posterior wall of the ampulla using 10–0 nylon. The sutures are removed 1 week after the surgery. Topical moxifloxacin 0.5% eye drops and fluorometholone 0.1% eye drops were used four times daily for one week.

Patients were examined in visits at one week, 1 month, 3 months and 6 months for patency of the lower eyelid punctum, FDDT grade and Munk score of epiphora.

Satisfactory surgical outcome was defined as postoperative patent lower eyelid punctum and improved Epiphora score and FDDT grade at 6 months after surgery.

Statistical analysis:

Data were collected, coded and entered PC for statistical analysis using the Statistical Package for the Social Sciences (SPSS: statistical package version 20. Armonk NY USA: IBM Corp). For descriptive statistics, mean and standard deviation (SD) were used for quantitative data, number (n) and percentage (%) were used for qualitative data and Kolmogorov-Smirnov for normality test was used to differentiate between parametric data and non-parametric data. For Analytical statistics, Independent sample t-test was used for analysis of quantitative data and paired sample t-test was used for analysis of paired quantitative data. For all tests, probability (p) was considered non-significant if it is ≥ 0.05 , significant if it

is < 0.05 , highly significant if it is < 0.01 and very highly significant if it is < 0.001 . Bivariate correlation analysis was used for association analysis. Correlation (r) was considered weak or no correlation if it is 0.00 to 0.24, fair correlation if it is 0.25 to 0.49, moderate correlation if it is 0.50 to 0.74 and strong correlation if it is 0.75 more.

Results

Forty eyes of 24 patients were enrolled in the study, including 20 eyes in group A and 20 eyes in group B. There were 6 (30%) men and 14 (70%) women in Group A and 7 (35%) men and 13 (65%) women in Group B. The mean age of patients in group A was 59.25 ± 10.50 years, while the mean age in group B was 58.75 ± 10.68 years, with no statistically significant difference between both groups regarding gender and age distribution.

According to Kashkouli; 6 puncta (30%) were grade 1 and 14 puncta (70%) were grade 2 in group A while 8 puncta (40%) were grade 1 and 12 puncta (60%) were grade 2 in group B, with no statistically significant difference between both groups regarding stenosis grade distribution.

Pre- and post-operative data were collected and are shown in tables 1 to 3

Study results are shown in table 4. In group A: 16 (80%) eyes showed improvement, 2 (10%) eyes showed failure with anatomical recurrence (restenosis of the punctum) and 2 (10%) eyes showed post-operative functional epiphora. on the other hand, in group B: 12 (60%) eyes showed improvement, 4 (20%) eyes showed failure with anatomical recurrence (restenosis of the punctum) and 4 (20%) eyes showed post-operative functional epiphora.

Table (1): comparison between the 2 groups regarding pre- and 6 months post-operative grade of epiphora according to Munk score

Grade of epiphora	Group A (n = 20)		Group B (n = 20)		χ^2	p
	No.	%	No.	%		
Preoperative						
0	0	0.0	0	0.0	0.100	0.752
1	0	0.0	0	0.0		
2	0	0.0	0	0.0		
3	9	45.0	10	50.0		
4	11	55.0	10	50.0		
6 Months post-op						
0	4	20.0	2	10.0	2.419	MC _p = 0.698
1	6	30.0	4	20.0		
2	6	30.0	6	30.0		
3	2	10.0	4	20.0		
4	2	10.0	4	20.0		

Table (2): comparison between the 2 groups regarding improvement of grade of epiphora according to Munk score after 6 months follow up

Improvement of epiphora after 6 months follow up	Group A (n = 20)		Group B (n = 20)		χ^2	p
	No.	%	No.	%		
Improved	16	80.0	12	60.0	1.905	0.168
No change	4	20.0	8	40.0		
Worsened	0	0.0	0	0.0		

Table (3): comparison between the 2 groups regarding improvement of FDDT according to Ozgur scale

Improvement of FDDT after 6 months follow up	Group A (n = 20)		Group B (n = 20)		χ^2	FE _p
	No.	%	No.	%		
Improved	18	90.0	15	75.0	1.558	0.407
No change	2	10.0	5	25.0		
Worsened	0	0.0	0	0.0		

Table (4): Comparison between the two studied groups according to result

Result	Group A (n = 20)		Group B (n = 20)	
	No.	%	No.	%
Success	16	80.0	12	60.0
Failed (restenosis)	2	10.0	4	20.0
Functional epiphora	2	10.0	4	20.0

Discussion

The anatomical principle of punctoplasty is to widen a stenosed punctum constantly and bring the widened punctum near the tear meniscus. The posterior wall of the vertical canaliculus needs to be excised to achieve these aims. The raw edges are not in contact and this prevents immediate healing and restenosis of the punctum.

However, anatomical recurrence and restenosis was observed in some cases who underwent conventional 3 snip punctoplasty, thus placing 3 interrupted sutures at the posterior ampulla was first introduced by Park et al. 2018 to improve the outcomes of the conventional 3 snip punctoplasty.[12]

In 2018, Park et al.'s proposed a modification in the conventional 3 snip punctoplasty by placing 3 interrupted sutures in a trial to prevent or decrease the restenosis rate. They reported, after 17-months follow-up period; anatomical success rate of 91.7% (44 of 48 eyes enrolled), and four eyes (8.3%) remained unchanged. Among the four eyes (8.3%) who were determined as symptomatic failure, anatomical recurrence (restenosis of the punctum) was observed in only one eye (2.1%) and the other three eyes (6.2%) had post-operative functional epiphora.

Authors of the current study adopted this modification in group A patients. And in spite of the shorter follow up period (6-months); anatomical success was observed in only 80% of cases (16 of 20 eyes enrolled); while four eyes (20%) remained unchanged. Among the four eyes, determined as symptomatic failure, anatomical recurrence (restenosis of the punctum) was observed in only two eyes (10%) and the other two eyes (10%) had post-operative functional epiphora.

On comparing placing 3 interrupted sutures to conventional 3-snip punctoplasty; placing 3 interrupted had better functional and anatomical results. Subjective improvement of epiphora using Munk score was better in group A. Also, FDDT indicated objective functional improvement. By the end of the follow up period, FDDT was grade 1 in 10 eyes (50%), grade 2 in 8 eyes (40%) and grade 3 in 2 eyes (10%) in group A. On the other hand, in group B it was grade 1 in 6 eyes (30%), grade 2 in 10 eyes (50%) and grade 3 in 4 eyes (20%). 18 eyes (90%) among group A versus 15 eyes (75%) in group B improved regarding FDDT grade with significant difference.

Anatomically, restenosis occurred in 2 eyes (10%) in group A while it occurred in 4 eyes (20%) in group B by the end of the follow up period. This may be attributed to the fact that the interrupted sutures help to decrease the raw surface of the dilated punctum and making restenosis of the dilated punctum less likely [12]. However, the present study showed higher anatomical recurrence rate in both groups. This may be explained by the prevalence of trachoma in Egyptian patients rendering them more vulnerable to cicatrization.

As regard safety, both techniques were well tolerated with no intraoperative or postoperative complications apart from foreign body sensation that was felt in 100% of eyes in group A during the early postoperative period and disappeared after one week when stitches were removed. This complaint was not present in patients of the other group.

Limitations of the current study include the relatively small sample sizes and the relative short follow up period with lack of long-term evaluation. More studies with larger scale and longer follow up period would be recommended.

In conclusion, although 3-snip punctoplasty is not the most effective procedure for treatment of acquired lower punctal stenosis grade 1 and 2, it remains of choice in certain circumstances, regarding the low cost of the procedure, and not requiring general anaesthesia which is a problem in old patients with possible unfit general conditions. Thus, proposing that placing three interrupted sutures at the posterior ampulla after 3-snip punctoplasty may enhance the effect of the procedure would be of a great value.

Declarations

Conflict of interest

The authors declare that they have no conflict of interest.

Funding

The author(s) received no financial support for the research, authorship, and/or publication of this article.

Authors' contribution

All authors contributed to the study conception and design.

Material preparation, data collection and analysis were performed by Hesham Abdulhady, Sameh S. Mandour, and Hany Khairy. The first draft of the manuscript was written by Hesham Abdulhady, Amr Awara, and all authors commented on previous versions of the manuscript. All authors read and approved the final manuscript.

Data availability and material

All data and material are available if required.

Compliance with ethical standards

Ethical approval

This study adhered to the tenets of the Declaration of Helsinki (1964) and was approved by the Research Ethics Committee of the Faculty of Medicine, Menoufia University (Approval No.19719opht1).

Animal Research

Not applicable

Informed consent

Informed consent was obtained from all individual participants included in this study after they received a detailed explanation of the procedures involved.

Consent to publish

Participants provided informed consent for publication of the images in Fig. 1.

All participants have consented to the submission of the study to the journal.

References

- 1 Kashkouli, M. B., Beigi, B. & Astbury, N. 2005. Acquired external punctal stenosis: surgical management and long-term follow-up. *Orbit*, 24, 73-78.
- 2 Kashkouli, M. B., Beigi, B., Murthy, R. & Astbury, N. 2003. Acquired external punctal stenosis: etiology and associated findings. *American journal of ophthalmology*, 136, 1079-1084.
- 3 Caesar RH, McNab AA. A brief history of punctoplasty: The three snips revisited. *Eye* 2005; 19: 16–18.

- 4 Mathew RG, Olver JM. Mini-monoka made easy: A simple technique for mini-monoka insertion in acquired punctal stenosis. *Ophthal Plast Reconstr Surg* 2011; 27: 293–294.
- 5 Hussain RN, Kanani H, McMullan T. Use of mini- monoka stents for punctal and canalicular stenosis. *Br J Ophthalmol* 2012; 96: 671–673.
- 6 Konuk O, Urgancioglu B, Unal M. Long term success rates of perforated punctal plugs in the management of acquired punctal stenosis. *Ophthal Plast Reconstr Surg* 2008; 24: 399–402.
- 7 Chalvatzis NT, Tzamalakis AK, Mavrikakis I, Tsinopolous I, Dimitrakos S. Self-retaining bicanaliculus stents as an adjunct to 3-snip punctoplasty in the management of upper lacrimal duct stenosis. A comparison to standard 3-snip procedures. *Ophthal Plast Reconstr Surg* 2013; 29: 123–127.
- 8 Chak M, Irvine F. Rectangular 3-snip punctoplasty outcomes: Preservation of lacrimal pump in punctoplasty surgery. *Ophthal Plast Reconstr Surg* 2009; 25: 134–135.
- 9 Kim SE, Lee SJ, Lee SY, Yoon JS. Outcomes of 4-snip punctoplasty for severe punctal stenosis: Measurement of tear meniscus height by optical coherence tomography. *Am J Ophthalmol* 2012; 153: 769–773.
- 10 Ma'luf RN, Hamush NG, Awwad ST, Nouredin BM. Mitomycin C as adjunct therapy in correcting punctal stenosis. *Ophthal Plast Reconstr Surg* 2002; 18: 285–288.
- 11 Thomas JB. A modification of Graves' operation for epiphora due to stenosis of the lacrimal punctum. *Br J Ophthalmol* 1951; 35: 306.
- 12 Seong Jun Park , Ju Hee Noh , Ki Bum Park , Sun Young Jang & Jong Won Lee. A novel surgical technique for punctal stenosis: placement of three interrupted sutures after rectangular three-snip punctoplasty. *BMC Ophthalmology* 2018 18:70
- 13 Munk, P. L., Lin, D. & Morris, D. C. 1990. Epiphora: treatment by means of dacryocystoplasty with balloon dilation of the nasolacrimal drainage apparatus. *Radiology*, 177, 687-690.
- 14 Ozgur, O. R., Akcay, L., Tutas, N. & Karadag, O. 2015. Management of acquired punctal stenosis with perforated punctal plugs. *Saudi journal of ophthalmology*, 29, 205-209.

Figures

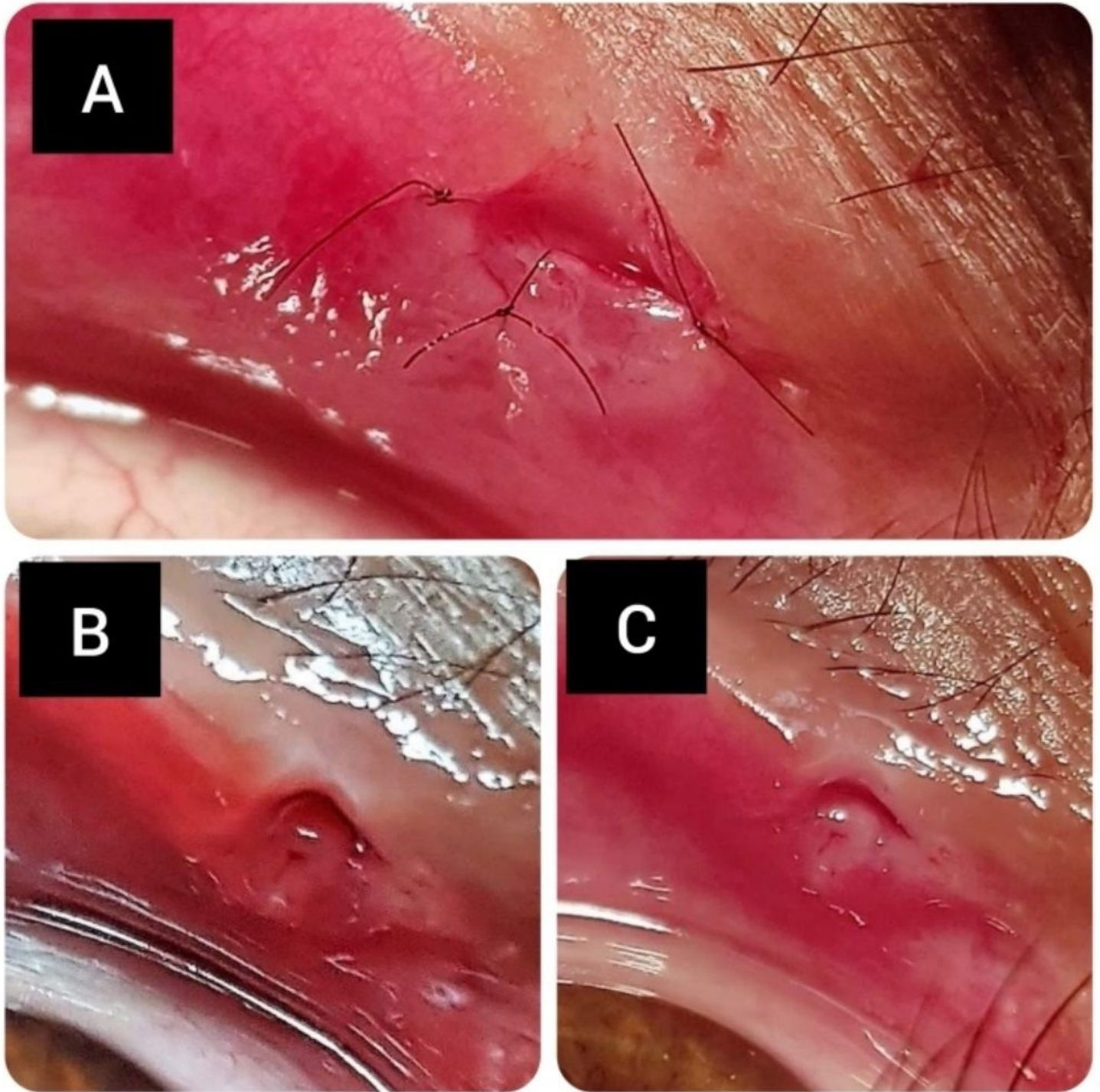


Figure 1

A- immediate postoperative photograph. Note the placed three interrupted sutures . B- 1 week post-operative photograph after removal of the placed sutures. C- 6 months post-operative follow-up photograph. Note the patency of the punctum.