

# Surgical treatment in nervous system echinococcosis in Qinghai-Tibet Plateau

Chaonan Du

Jing Li

Qiang Zhang

Mingfei Yang (✉ [iloveyoucmu@163.com](mailto:iloveyoucmu@163.com))

Qinghai Provincial People's Hospital



---

## Research

**Keywords:** echinococcosis; cerebral; spinal; surgery; outcome.

**Posted Date:** May 28th, 2020

**DOI:** <https://doi.org/10.21203/rs.3.rs-29103/v1>

**License:**   This work is licensed under a Creative Commons Attribution 4.0 International License. [Read Full License](#)

---

# Abstract

**Purpose:** To summarize the experience of diagnosis and treatment of echinococcosis in nervous system in Qinghai-Tibet Plateau.

**Methods:** Patients with echinococcosis of nervous system treated in Qinghai Provincial People's Hospital from January 2010 to September 2018 were selected. All patients were examined by enzyme linked immunosorbent assay and imaging examination. During the hospital, all patients received surgery. After operation, patients examined regularly and followed up for one year.

**Results:** A total of 13 patients were included in this study. The average age was  $38.8 \pm 13.7$  and seven cases (54%) were male. Among these patients, six cases had cystic echinococcosis and seven cases with alveolar echinococcosis, meanwhile, eight patients had cerebral echinococcosis and five patients with spinal echinococcosis. The enzyme linked immunosorbent assay indicated positive results in 8 cases and one patient was misdiagnosed as vertebral metastases by imaging examination before operation. One patient recurred after operation but refused treatment. After follow-up for one year, the mRS (Modified Rankin Scale) of cerebral echinococcosis improved from  $3.3 \pm 0.5$  to  $2.1 \pm 0.4$ , four cases of spinal echinococcosis improved in ASIA (American Spinal Injury Association).

**Conclusion:** Current evidence indicated that early surgical treatment and oral albendazole might improve the outcome of patients with nervous system echinococcosis in short time.

## 1. Introduction

Echinococcosis is a zoonotic disease, which could be divided into cystic echinococcosis (CE) and alveolar echinococcosis (AE), led to high mortality and poor outcome in the world<sup>1</sup>. About million people were at risk of contracting echinococcosis, and more than two million people were diagnosed with echinococcosis in worldwide<sup>2,3</sup>. Echinococcosis is usually in the liver or lung, involving the nervous system is relatively rare to see. Echinococcosis of the nervous system accounts for 2% – 3% of the total cases<sup>4</sup>. However, the diagnosis of echinococcosis in the nervous system was still difficult, what's more, the therapeutic effect of spinal echinococcosis was uncertain due to fewer samples or case reports<sup>5,6</sup>. In Qinghai-Tibet Plateau, a large proportion of inhabitant are herdsmen, they raised dogs to protect their sheep and cattle<sup>7</sup>. The economics of this region was backward, medical conditions were limited, and the radius of prehospital rescue was long<sup>8</sup>. The herdsmen had a low understanding of echinococcosis and the incidence of echinococcosis was high. Therefore, we aimed to analyze the patients with echinococcosis of nervous system and summarized the experience of treatment in Qinghai-Tibet Plateau.

## 2. Methods

Patients with echinococcosis of nervous system admitted into Qinghai Provincial People's Hospital from January 2010 to September 2018 were selected. In order to determine the disease status of patients, X-ray, computed tomography (CT) or magnetic resonance imaging (MRI) were performed. In addition, enzyme-linked immunosorbent assay (ELISA) was used to analyze the antibodies against hydatid. Patients were examined and positive signs were recorded after admission. All patients were excluded from surgical taboo and received surgical treatment. After operation, pathological and immunohistochemical examinations of the lesion were performed. Regular follow-up for one year after operation. This was a single center, retrospective study and the study was conducted in accordance with the amended Declaration of Helsinki. The study was approved by the ethics committee of Qinghai Provincial People's Hospital, and written informed consent was obtained from all patients.

## 2.1 Cerebral echinococcosis

For patients with CE, Dowling's technique<sup>9</sup> was used to remove lesion. However, for CE with functional or deep area, puncture–aspiration–injection–re-aspiration (PAIR) method<sup>10</sup> was used. Patients with AE accompanied with obvious symptoms of intracranial hypertension, seizures or transient loss of consciousness, microsurgery technique was used. The authors completely removed the lesion along the edematous area, including an area about 5 mm around the lesion. After operation, patients received inflammatory therapy, prevention of epilepsy, fluid replacement and oral albendazole (20 mg / kg · d orally). The liver function of these patients was monitored regularly. Preoperative and postoperative conditions were assessed by mRS (Modified Rankin Scale).

## 2.2 Spinal echinococcosis

All patients with spinal echinococcosis had pain, movement or defecation disorders in this study, these patients were treated with one-stage fusion and pedicle screw fixation under general anesthesia.

After operation, isometric muscle contraction exercise of both lower limbs was started, and muscle antagonism exercise was started on the third day after operation. After operation for 6–12 weeks, weight bearing was carried out with the protection of support walker. Albendazole (20 mg / kg · d orally) was taken from the next day after operation. Preoperative and postoperative conditions were assessed by ASIA (American Spinal Injury Association).

## 3. Results

A total of 28 patients had echinococcosis of nervous system, however, two patients with multiple intracranial hydatid lesions and three patients with other reasons were discharged automatically after admission. Nine patients were lost of follow up because of they lived in the pastoral area. Finally, 13 patients were included in this study. The average age was  $38.8 \pm 13.7$  and seven cases (54%) were male. The enzyme linked immunosorbent assay indicated positive results in 8 cases. All patients were herdsmen and came from Yushu or Guoluo Tibetan Autonomous Prefecture in Qinghai-Tibet Plateau. In this study, six patients had cystic echinococcosis and seven patients had alveolar echinococcosis; eight patients had cerebral echinococcosis and five patients had spinal echinococcosis (Table 1).

Table 1  
General clinical data and follow-up data of patients

Gender	Age	Location	Symptom				mRS / ASIA		Pathological
			Pain	Epilepsy	ELISA	Neurological dysfunction	Preoperative	Follow up one year	
male	38	basal ganglia	+	+	+	+	4	3	AE
female	42	occipital lobe	+	-	-	+	3	2	CE
male	22	fronto parietal lobe	+	+	+	+	3	2	AE
female	13	temporal lobe	+	-	+	-	3	2	CE
male	17	temporal lobe	+	-	-	-	3	2	CE
female	51	frontal and temporal lobe	+	+	+	+	4	2	AE
male	49	frontal lobe	+	+	+	+	3	2	AE
male	53	parietal lobe	+	-	-	+	3	2	CE
male	46	T <sub>10</sub> -L <sub>1</sub>	+	-	-	+	D	E	CE
female <sup>%</sup>	48	T <sub>10</sub> -12	+	-	+	+	B	died	AE
male	41	T <sub>8</sub>	+	-	+	+	D	E	AE
female	33	L <sub>1</sub> -2	+	-	-	+	C	E	CE
female	52	T <sub>11</sub> -12	+	-	+	+	C	D	AE

<sup>%</sup>: patients with recurrence; +: positive; -: negative.

### 3.1 Cerebral echinococcosis

Four patients were diagnosis as AE and four patients were diagnosis as CE. The average age was  $35.6 \pm 16.1$  and five cases were male. The enzyme linked immunosorbent assay indicated positive results in four cases. All patients were accompanied with hepatic echinococcosis. The mRS of preoperative and follow-up for one year were respectively  $3.3 \pm 0.5$  and  $2.1 \pm 0.4$  (Fig. 1).

### 3.2 Spinal echinococcosis

Three patients were diagnosis as AE and two patients were diagnosis as CE. The average age was  $44.0 \pm 7.3$ . The enzyme linked immunosorbent assay indicated positive results in three patients. One patient was misdiagnosed as

vertebral metastases by imaging examination before operation. Another one patient recurred after operation but refused treatment, the patient died during the follow up. After follow-up for one year, four cases of spinal echinococcosis were improved in ASIA (Fig. 2).

## 4. Discussion

Echinococcosis of nervous system included cerebral echinococcosis and spinal echinococcosis. Cerebral echinococcosis could be divided into primary (CE) and secondary (AE) echinococcosis. AE was mainly due to the transfer of echinococcosis in other organs or tissues. Bone echinococcosis was rare in all echinococcosis, which accounted for 0.5% – 4% of all echinococcosis, the incidence of spine was the top<sup>11</sup>.

The symptoms of headache and neurological dysfunction in patients with CE appeared slowly and the frequency of epileptic attack was low. On the contrary, for AE, the symptoms of these above symptoms appeared early and even threatened patient's life<sup>12</sup>. AE was almost originated from the liver, and its symptoms were very similar to those of intracranial metastasis. The most common neurological dysfunction was unilateral limb weakness, which was progressive aggravation. However, for patients with extradural or skull echinococcosis, hydatid cyst could destroy the dura and skull, which was manifested as a mass under the scalp<sup>13, 14</sup>. The symptoms were pain in the lesion site or radiation pain, showing gradual development. It could also show symptoms of spinal cord compression, such as nerve root and cauda equina injury. In this study, patients were accompanied with pains, epilepsy and neurological dysfunction. Therefore, all patients received operation in this study.

In imaging examination for cerebral echinococcosis, the results of CT scan indicated that the cystic disease was round, and the content of the cyst was low density shadow. But the CT manifestations of AE were similar to intracranial metastasis, with low density shadow. When the lesion was large, the surrounding edema was obvious and most patients had calcification. MRI could effectively indicate the CE of brain, which was characterized by round and clear boundary cystic lesions. MRI of AE were multiple mixed signal lesions with obvious perifocal edema and edema would be more clearly in enhanced scan. Therefore, cerebral echinococcosis needed to be differentiated from cystic neoplasm or intracranial metastasis. However, for patients with spinal echinococcosis, MRI indicated cystic or multicystic masses, with signal intensity similar to that of cerebrospinal fluid. T1 weighted image indicated circular and multilocular low signal; T2 weighted image showed medium high signal, with continuous, smooth and sharp linear low signal around. Therefore, Echinococcosis of spine might be differentiated from bone tuberculosis and bone tumor<sup>15</sup>. In this study, one patient was misdiagnosed as vertebral metastases. Therefore, the possibility of echinococcosis should be considered for the patients with vertebral disease who came from pastoral areas.

Drug therapy (albendazole) was one of the main treatment methods of nervous system echinococcosis, but the effects remained controversial. The authors indicated that patients with multiple intracranial hydatid cysts, unable to achieve complete internal capsule resection, echinococcosis of other organs, and other cases of CE and AE might need to take albendazole. However, patients with cerebral echinococcosis who took albendazole might have poor efficacy due to the protective effect of blood-brain barrier on brain tissue<sup>16</sup>. In this study, all patients were treated with albendazole, and the short-term outcome was good, but long-term follow-up data were missing.

For cerebral echinococcosis, Dowling's technique<sup>9</sup> was used by most neurosurgeon. But for lesions with functional or deep area, PAIR method<sup>10</sup> was selected. The authors indicated that AE patients with single intracranial lesion, especially the superficial and non-functional lesion, might be removed as early as possible. However, for the patients with intracranial multiple lesions, doctors might consider according to the location, quantity, size and edema of lesions, combined with the symptoms and signs of the patients. When the high intracranial pressure increased continuously,

part of the lesions of AE might be removed, or even a certain size of cranial bone might be removed to relieve the high intracranial pressure. For patients with spinal echinococcosis, the key to the operation was to remove the cyst wall of echinococcosis completely. However, there are important anatomical structures around the spine, such as spinal cord, nerve root, and the aorta in front of the vertebral body. In addition, the long-term pathological changes cause extensive adhesion between the diseased tissue and the surrounding and the weakness of the capsule wall itself. It is not easy to achieve complete extracapsular removal during the operation. At present, the most widely recognized and accepted method of spine reconstruction was bone transplantation<sup>17</sup>. Most commonly used method were titanium cage interbody graft<sup>18</sup> or cage interbody fusion<sup>19</sup> and polymethylmethacrylate<sup>20</sup> to fill bone defects. All patients in this study received operation, but one patient recurred and refused treatment, finally died during the follow up time. However, some patients with echinococcosis relapsed more than ten years after neurosurgery. Therefore, regular follow-up of echinococcosis patients might be necessary.

However, there are some shortcomings might be discussed in this study. all patients in this study received operation, and lack of conservative treatment. This is a single center, retrospective study and follow-up time was short. Therefore, multicenter, large sample studies with long-term follow-up might be carried out in the future.

## 5. Conclusion

Current evidence indicated that early surgical treatment and oral albendazole might improve the prognosis of patients with nervous system echinococcosis in short time.

## List Of Abbreviations

CE=cystic echinococcosis;

AE=alveolar echinococcosis;

ELISA=enzyme-linked immunosorbent assay;

CT=Computed Tomography;

MRI=Magnetic Resonance Imaging;

mRS=Modified Rankin Scale;

ASIA=American Spinal Injury Association; PAIR=puncture–aspiration–injection–re-aspiration.

## Declarations

**Ethics approval and consent to participate:** This study was approved by the Ethics Committee of Qinghai Provincial People's Hospital.

**Consent for publication:** Not applicable.

**Availability of data and materials:** Not applicable.

**Competing interests:** The authors declared that they had no competing interests.

**Funding:** The study was found by the National Natural Science Foundation of China (81860370).

**Authors' contributions:** Chaonan Du and Jing Li collected information and wrote articles. Qiang Zhang and Mingfei Yang designed the research modified the article. All authors read and approved the final manuscript.

**Acknowledgements:** none.

## References

1. McManus DP, Zhang W, Li J, Bartley PB. Echinococcosis. *The Lancet*. 2003;362(9392): 1295-1304.
2. Ito A, Urbani C, Jiamin Q, et al. Control of echinococcosis and cysticercosis: a public health challenge to international cooperation in China. *Acta tropica*. 2003;86(1): 3-17.
3. McManus DP, Gray DJ, Zhang W, Yang Y. Diagnosis, treatment, and management of echinococcosis. *Bmj*. 2012;344: e3866.
4. Altinörs N, Bavbek M, Caner HH, Erdoğan B. Central nervous system hydatidosis in Turkey: a cooperative study and literature survey analysis of 458 cases. *Journal of neurosurgery*. 2000;93(1): 1-8.
5. Ashraf A, Kirmani AR, Bhat AR, Sarmast AH. A rare case of recurrent primary spinal echinococcosis. *Asian journal of neurosurgery*. 2013;8(4): 206.
6. Kalacı A, Sevinç TT, Yanat AN. Sciatica of nondisc origin: hydatid cyst of the sciatic nerve: Case report. *Journal of Neurosurgery: Spine*. 2008;8(4): 394-397.
7. Han X-M, Cai Q-G, Wang W, Wang H, Zhang Q, Wang Y-S. Childhood suffering: hyper endemic echinococcosis in Qinghai-Tibetan primary school students, China. *Infectious diseases of poverty*. 2018;7(1): 71.
8. Du C-N, Yang M-F, Zhang Q, Jin X-Q, Yan C, Huang Y-W. Establishment and Verification of the Hematoma Expansion Prediction Score of Intracerebral Hemorrhage in the Qinghai-Tibetan Plateau. *World neurosurgery*. 2019;123: e465-e473.
9. Carrea R, Dowling jr E, Guevara JA. Surgical treatment of hydatid cysts of the central nervous system in the pediatric age (Dowling's technique). *Pediatric Neurosurgery*. 1975;1(1): 4-21.
10. Brunetti E, Kern P, Vuitton DA. Expert consensus for the diagnosis and treatment of cystic and alveolar echinococcosis in humans. *Acta tropica*. 2010;114(1): 1-16.
11. Song X, Ding L, Wen H. Bone hydatid disease. *Postgraduate medical journal*. 2007;83(982): 536-542.
12. Özek M. Complications of central nervous system hydatid disease. *Pediatric neurosurgery*. 1994;20(1): 84-91.
13. Cemil B, Tun K, Gurcay AG, Uygur A, Kaptanoglu E. Cranial epidural hydatid cysts: Clinical report and review of the literature. *Acta neurochirurgica*. 2009;151(6): 659.
14. Erman T, Tuna M, Göçer İ, İldan F, Zeren M, Çetinalp E. Intracranial intraosseous hydatid cyst: Case report and review of the literature. *Neurosurgical focus*. 2001;11(1): 1-3.
15. Türkoğlu E, Demirtürk N, Tünay H, Akıcı M, Öz G, Embleton DB. Evaluation of patients with cystic echinococcosis. *Türkiye Parazitoloji Dergisi*. 2017;41(1): 28.
16. Meinel TR, Gottstein B, Geib V, et al. Vertebral alveolar echinococcosis—a case report, systematic analysis, and review of the literature. *The Lancet Infectious Diseases*. 2018;18(3): e87-e98.
17. Tammam A, Crockard HA. Quadriplegia with cervical cord compression. *Postgraduate medical journal*. 1997;73(860): 381.
18. Moharamzad Y, Kharazi HH, Shobeiri E, Farzanegan G, Hashemi F, Namavari A. Disseminated intraspinal hydatid disease: Case report. *Journal of Neurosurgery: Spine*. 2008;8(5): 490-493.
19. Sengul G, Kadioglu HH, Kayaoglu CR, Aktas S, Akar A, Aydin IH. Treatment of spinal hydatid disease: a single center experience. *Journal of Clinical Neuroscience*. 2008;15(5): 507-510.

20. Yildiz Y, Bayrakci K, Altay M, Saglik Y. The use of polymethylmethacrylate in the management of hydatid disease of bone. *The Journal of bone and joint surgery British volume*. 2001;83(7): 1005-1008.

## Figures

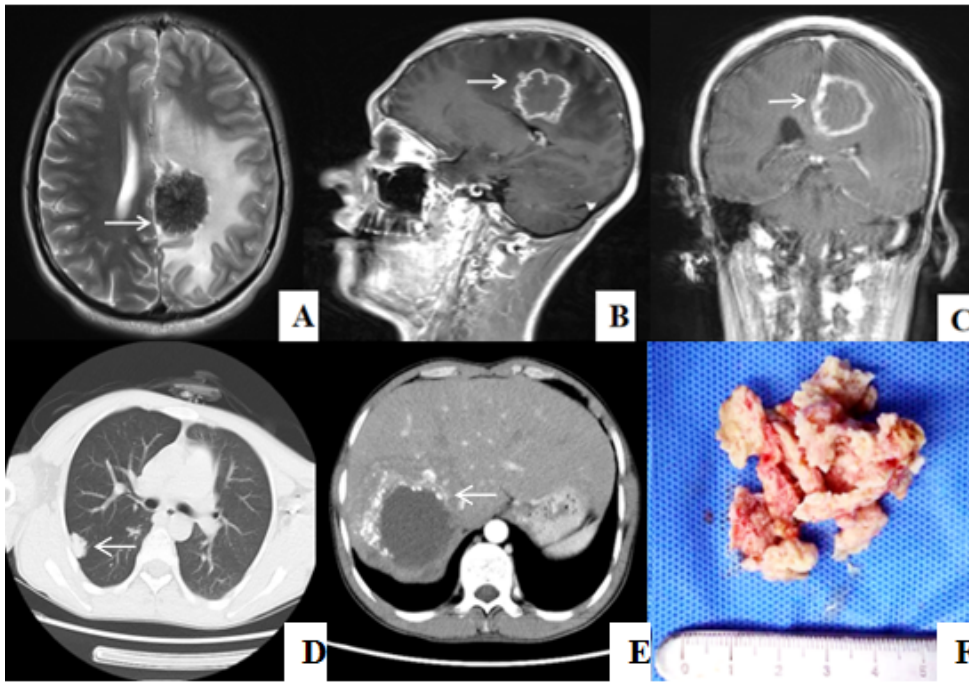


Figure 1

Typical case for cerebral. The result of brain MRI showed that circular T1 mixed T2 signal beside the falx of the left frontal parietal lobe and a garland like enhancement in the enhancement scan(A was axial scan, B was sagittal scan and C was coronary scan). The results of chest(D) and abdomen(E) CT scan. In the central anterior sulcus, near the falx of the brain, it enters the cortex, and in the depth of 2.5cm, there was porcelain white focus tissue with hard texture and clear boundary. The author carefully excised the focus in blocks(F).

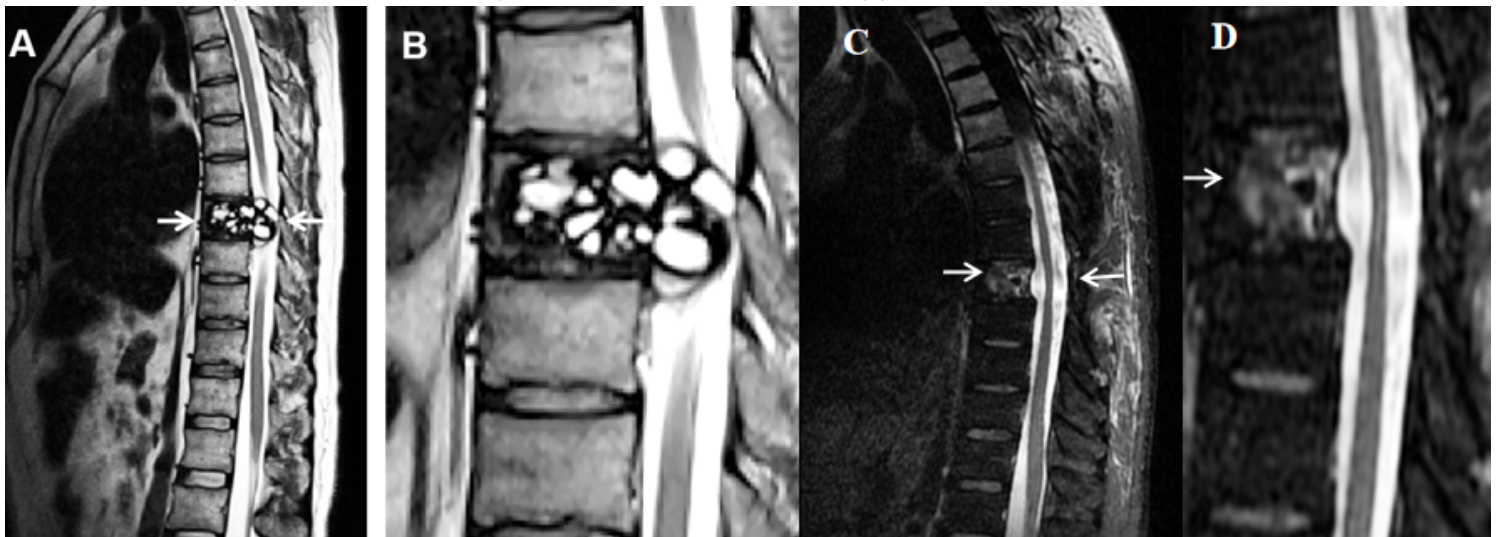


Figure 2



Typical case for spinal. In the eighth thoracic vertebrae, multiple small cystic signal shadows were screened, the edge of the lesion was slightly enhanced, the lesion protruded into the spinal canal and the spinal cord was compressed (B was enlarged at the arrow in A). The MRI indicated no recurrence after operation for one year (D for zoom of the selected cutout in C).