

Sitosterolemia: Inherited Disorder of Plant Sterols Absorption and Biliary Excretion

Xiaoquan He

Capital Medical University Affiliated Beijing Friendship Hospital <https://orcid.org/0000-0002-9130-1321>

Hui Chen (✉ 13910710028@163.com)

Capital Medical University

Case report

Keywords: Sitosterolemia, lipid metabolism

Posted Date: March 9th, 2021

DOI: <https://doi.org/10.21203/rs.3.rs-290087/v1>

License: © ⓘ This work is licensed under a Creative Commons Attribution 4.0 International License.

[Read Full License](#)

Abstract

Sitosterolemia is a rare, inherited, autosomal recessive disorder of lipid metabolism, we report on the diagnosis and treatment of a child with sitosterolemia misdiagnosed as a skin disease.

Introduction

A 6-year-old girl presented to her local health-care center with skin lesions on her sacrococcygeal region and legs (Panels A and B). The lesions were small initially and were noted when she was 6 months old. She was diagnosed as familial hypercholesterolemia and was asked to decrease animal fat intake but vegetable oil was not restricted and no other medical care was sought. The lesions were getting more apparent. The laboratory evaluations showed a total cholesterol level of 413 mg per deciliter (10.68mmol per liter); a triglyceride level of 64 mg per deciliter (0.73mmol per liter); a low density lipoprotein (LDL) cholesterol level of 270 mg per deciliter (6.98mmol per liter) and a high-density lipoprotein cholesterol level of 46 mg per deciliter (1.21mmol per liter). She presented no cirrhosis, macrothrombocytopenia, hemolytic anemia with normal liver function and blood routine test result. Evaluation of her systemic vascular disease with multi-detector helical CT angiography found suspected middle segment stenosis of the anterior descending artery.

She was referral to our hospital for further diagnosis and treatment. On examination, she presented with growth retardation but intelligence normal. Her parents were healthy and their lipid levels were in the normal range. Given the initial diagnosis of familial hypercholesterolemia, we further confirmed genetic mutations consisted of the exons of the ABCG5 genes. The Child carried a homozygous pathogenic mutation in ABCG5 at c.1336C > T located on chromosome chr2:44050063(Panel C), which caused a premature stop codon at amino acid position 446, leading to a predicted truncated protein. Her father carried a heterozygous mutation in ABCG5 at c.1336C > T (Panel D). Her mother checked twice but found no genetic mutation. Furthermore, we performed coronary angiography to identify coronary artery lesions but no stenosis was found. Eventually, she was diagnosed with Sitosterolemia.

The child was treated with ezetimibe and referred to a nutritionist for dietary advice of a low phytosterol diet. With two-year treatment the total cholesterol decreased to 134 mg per deciliter (3.48mmol per liter), the LDL cholesterol concentration decreased to 86 mg per deciliter (2.23mmol per liter) and her xanthoma has getting smaller.

Sitosterolemia is a rare, inherited, autosomal recessive disorder of lipid metabolism characterized by increased absorption and decreased biliary excretion of plant sterols and cholesterol, thus resulting in increased LDL cholesterol, plant sterols and cardiovascular disease risk. Clinical manifestations primarily present with tendinous and tuberous xanthomas. The monogenic causes of Sitosterolemia involve gene mutations either ATP-binding cassette sub-family G member 5 or member 8 (ABCG5 and ABCG8, respectively).

The best treatment for sitosterolemia is ezetimibe and reduction of vegetable oil intake, statins and PCSK9 inhibitors may be considered if the LDL cholesterol level is very high.

Declarations

Conflict of Interest Statements

None.

Contributors

We were all involved in the care and manage writing and editing the manuscript. Written consent for publication was obtained from her parents.

Figures

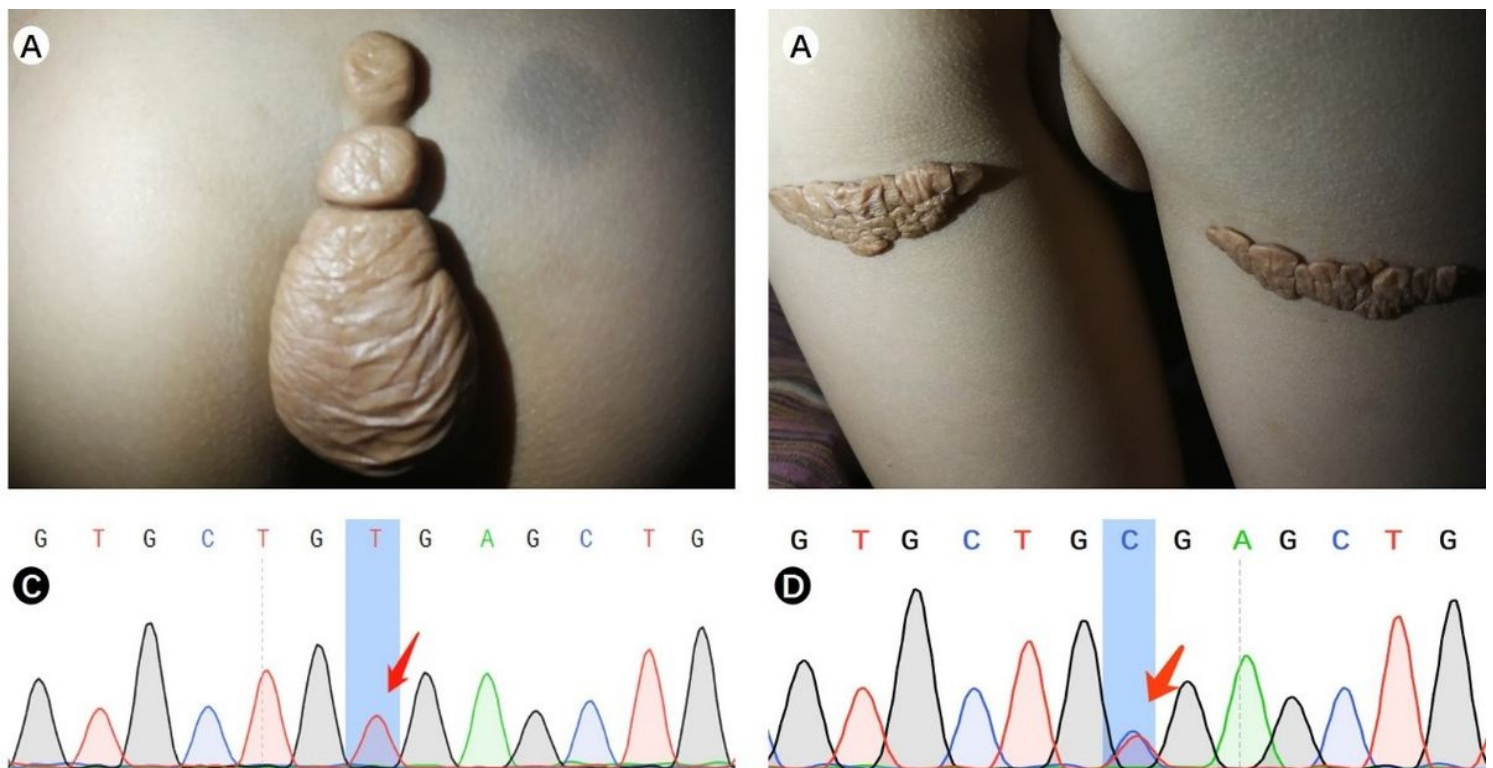


Figure 1

Primary Clinical manifestations with xanthomas and pathogenic gene mutations of Sitosterolemia
Xanthomas on her sacrococcygeal region (A). Xanthomas on her legs (B). The child carried a pathogenic homozygous mutation(C). Her father carried a heterozygous mutation (D).