

# Effect of Anterior Capsule Polishing on the Rate of Neodymium: YAG Laser Capsulotomy in Multifocal Intraocular Lens

**Honglei Li**

qingdao eye hospital

**Huiran Bai**

qingdao eye hospital

**Dongle Liu**

qingdao eye hospital

**Yanfeng Han**

qingdao eye hospital

**Xiaoming Wu** (✉ [wuxiaominglmm@126.com](mailto:wuxiaominglmm@126.com))

qingdao eye hospital

---

## Research Article

**Keywords:** Anterior capsule polishing, Nd: YAG laser capsulotomy, multifocal intraocular lens

**Posted Date:** March 19th, 2021

**DOI:** <https://doi.org/10.21203/rs.3.rs-283817/v1>

**License:** © ⓘ This work is licensed under a Creative Commons Attribution 4.0 International License.

[Read Full License](#)

---

# Abstract

## Purpose

Herein, we elucidated the effect of anterior capsule polishing (ACP) during cataract surgery on the rate of neodymium: YAG (Nd: YAG) laser capsulotomy in multifocal intraocular lens (MIOL).

## Methods

We extracted the medical records of patients who underwent phacoemulsification with MIOL between May 2016 and April 2017 from the files of the patients, and the follow-ups of fewer than 3 years were excluded. The participants were divided into the ACP group and the non- ACP group based on whether the anterior capsule was polished. The primary outcome was whether to perform Nd: YAG capsulotomy during the follow-up. We analyzed the time from IOL implantation to Nd: YAG laser capsulotomy using the Kaplan-Meier survival curves.

## Results

The ACP group comprised 70 eyes and non-ACP group, 60 eyes. One year postoperatively, 7.14% of the eyes in the ACP group and 8.33% in the non-ACP group required Nd: YAG laser capsulotomy ( $P > 0.99$ ). After 2 years, it was 24.29% and 18.33%, respectively ( $P = 0.52$ ). After 3 years, it was 30.0% and 28.33% respectively ( $P = 0.85$ ). There was no distinct difference in the probability for Nd: YAG laser between the ACP group and the non-ACP group evaluated using Kaplan-Meier survival curves ( $P = 0.81$ ). Patients with implantation of diffractive MIOL (AT LISA tri 839MP) had a high probability of requiring Nd: YAG laser capsulotomy.

## Conclusion

Polishing the anterior capsule had no remarkable effect on reducing the rate of Nd: YAG laser capsulotomy after phacoemulsification in MIOL.

## Introduction

Posterior capsule opacification (PCO) constitutes the most frequent long-term adverse event of cataract surgery, which can lead to visual impairment and require additional surgery<sup>[1]</sup>. While PCO could be treated using Nd: YAG laser by cutting a hole in the dorsal capsule, this process might result in other adverse effects<sup>[2]</sup>.

Several strategies have been developed to prevent PCO. These include the material and the organization of the implanted IOL, utilizing cortical cleaving hydrodissection during the operation, continuous

curvilinear capsulorhexis (CCC), gene therapy, the introduction of osmotic variations in LECs, and lens regeneration [3]. However, in routine clinical practice, none of these approaches is acceptably practical, efficacious, and safe.

Numerous studies have assessed the pathogenicity of PCO to establish potential prevention methods. Capsular opacification is caused by proliferation, migration, and transdifferentiation of lens epithelial cells (LECs) that are usually located on the inside of the frontal capsule and remain in the capsule after cataract operation [4, 5]. These LECs try to go through the usual differentiation or epithelial-mesenchymal transformation, creating different kinds of cell groups in the posterior capsule, resulting in contraction and fibrosis of the lens capsule [5, 6]. Therefore, removing residual LECs could reduce the likelihood of PCO development.

Here, we retrospectively examined the effect of ACP on PCO and the requisite for Nd: YAG laser capsulotomy after implantation of MIOL.

## Patients And Methods

This 3-year retrospective study was conducted at Shandong Eye Institute, Qingdao Eye Hospital. We mined and collected the medical data from the files of the patients maintained in our hospital. A clinical research assistant supervised the anonymous completion of the form. The protocol of the study and measurements were in line with the tenets of the Declaration of Helsinki. The study was performed in accordance with appropriate guidelines and were approved by Qingdao Eye hospital committee. Informed consents for this study participation have been obtained.

Exclusion criteria: glaucoma, high myopia (axial length > 26.0mm), traumatic cataracts, complicated cataracts, progressive retinopathy, uveitis, history of ocular surgery. Besides, the follow-ups of fewer than 3 years were excluded.

Through the medical recording system, a list of patients who underwent cataract surgery and implanted segmental refractive MIOL (SBL-3) or diffracted MIOL (AT Lisa tri 839MP) from May 2016 to April 2017 was collected. We examined all the corresponding medical records, and patients who met the criteria were included. The relevant data before and after surgery were checked and extracted by the end of April 2020.

Patients were categorized into 2 groups based on the mode of operation,, the anterior capsule polishing (ACP) group or the non-anterior capsule polishing (non-ACP) group. The mode of operation was randomly selected; ACP and non-ACP were almost evenly distributed throughout the study period by watching videos of previous surgery (from May 2016 to April 2017). The surgeon was unaware that the relevant data could be used later in this comparative study.

An experienced ophthalmologist (WXM) conducted all the operations with topical anesthesia. The ophthalmologist made a 2.2mm precise corneal incision and then a 5-5.5mm CCC, phacoemulsification, and irrigation and aspiration of the cortex. A segmental refractive MIOL (SBL-3) or a diffractive MIOL (AT

LISA tri 839MP) was then put into the capsular bag. In the ACP Group, polishing of the undersurface of the anterior capsule was done in all the quadrants and all the clock hours within the visible range by a polisher.

All patients were administered with topical prednisolone (1.0% eye-drops, 4-times daily, in a tapering dose for 4 weeks), topical levofloxacin (0.5% eye-drops 4-times daily for 2 weeks), and sodium bromfenate (0.1% eye-drops, 2 times daily for 4 weeks).

Our primary observation included establishing the incidence of Nd: YAG laser capsulotomy. The secondary observation constituted documenting the time of Nd: YAG laser capsulotomy from the day of surgery.

We defined PCO as any central whitening or wrinkling of the posterior capsule on the slit lamp examination. Manifestations for Nd: YAG laser capsulotomy was similar for the two groups, taking into account the visual acuity and clinical signs as follows: proximal or distal visual acuity decreased and verified by PCO in clinical examination.

The data herein were statistically analyzed using IBM SPSS Statistics versions 22.0 (IBM Corp., NY, USA). Group comparisons at the time of intervention were assessed using the chi-square or Fisher exact test for qualitative data or independent t-test for quantitative data. We utilized the Kaplan-Meier probability curves to compute the risk of Nd: YAG laser capsulotomy in a certain period after surgery. The logarithmic rank test was employed to analyze the difference between two groups of probability curves.  $P \leq 0.05$  designated statistical significance.

## Results

We enrolled one hundred and twenty-one patients (130 eyes) in the study. Among them, 66 were male and 55 female. The ACP group comprised 70 eyes and the non-ACP group, 60 eyes. The characteristics of the patients and correlated ocular parameters are shown in Table 1. There were no remarkable differences in age, gender, and axial length between the ACP group and the non-ACP group.

Table 1  
Preoperative patient characteristics.

| Group  |              |               |                   |
|--|--------------|---------------|-------------------|
| Parameter  | ACP          | Non-ACP       | P Value           |
| Patients/Eyes(n)   | 65/70        | 56/60         | -                 |
| Male/Female(n)   | 34/31        | 32/24         | 0.71 <sup>+</sup> |
| Age(years)   | 50.2 ± 11.03 | 53.13 ± 13.14 | 0.17*             |
| AL(mm)   | 23.49 ± 0.90 | 23.52 ± 0.91  | 0.85*             |
| AL = axial length; <sup>+</sup> chi-square test; * independent t test; |              |               |                   |

Table 2 primarily shows the characteristics of patients who underwent Nd: YAG capsulotomy in the course of the follow-up period. There were 21 eyes in the ACP group and 17 eyes in the non-ACP group operated using the Nd: YAG capsulotomy approach. UDVA in the ACP group before Nd: YAG capsulotomy was  $0.42 \pm 0.22$  and  $0.49 \pm 0.42$  in the non-ACP group, and not distinctly different ( $P = 0.50$ ). One year postoperatively, 7.14% of eyes in the ACP arm and 8.33% in the non-ACP arm needed Nd: YAG laser capsulotomy ( $P > 0.99$ ). After 2 years, it was 24.29% and 18.33%, respectively ( $P = 0.52$ ). After 3 years, it was 30.0% and 28.33%, respectively ( $P = 0.85$ ).

Table 2  
Characteristics of patients who underwent Nd: YAG capsulotomy during the follow-up period

| Group  |              |               |                     |
|--|--------------|---------------|---------------------|
| Parameter  | ACP          | Non-ACP       | P Value             |
| Eyes (n)   | 21           | 17            | -                   |
| Mean time(months)*   | 18.05 ± 6.50 | 19.06 ± 11.45 | 0.74 <sup>#</sup>   |
| UDVA   | 0.42 ± 0.22  | 0.49 ± 0.42   | 0.50 <sup>#</sup>   |
| Nd:YAG rate (%)  |              |               |                     |
| 1year  | 7.14         | 8.33          | > 0.99 <sup>+</sup> |
| 2years   | 24.29        | 18.33         | 0.52 <sup>+</sup>   |
| 3years   | 30.0         | 28.33         | 0.85 <sup>+</sup>   |
| ACP = anterior capsule polishing; UDVA = uncorrected distance visual acuity before ND:YAG; <sup>#</sup> independent t test; * days from surgery to Nd:YAG; <sup>+</sup> chi-square test; |              |               |                     |

Table 3 shows the segmental refractive MIOL and diffractive MIOL patients that had underwent Neodymium: YAG laser capsulotomy in the distribution of the ACP and non-ACP arms during the three-year follow-up examination. The patients in the ACP and non-ACP groups were operated using the Nd: YAG laser capsulotomy of segmental refractive MIOL in the first two years.

Table 3  
Neodymium: YAG laser capsulotomies performed in the first year, the second year, and the third year follow-up examination.

| IOL   | Group   | Years |   |   |
|---|---------|-------|---|---|
|   |         | 1     | 2 | 3 |
| Segmental Refractive MIOL (n = 41)                                    | ACP     | 1     | 4 | 0 |
| Diffractive MIOL (n = 29)   | ACP     | 4     | 8 | 4 |
| Segmental Refractive MIOL (n = 27)                                    | Non-ACP | 3     | 1 | 0 |
| Diffractive MIOL (n = 33)   | Non-ACP | 2     | 5 | 6 |
| MIOL = multifocal intraocular lens; ACP = anterior capsule polishing; |         |       |   |   |

The survival curves of the percentage of patients not in need of Nd: YAG laser therapy as a function of time after IOL implantation are indicated in Fig. 1. The survival curves validated that there was no remarkable difference in the probability for Nd: YAG laser between the ACP arm and non-ACP arm ( $P = 0.81$ ). Based on the kind of IOL implanted, we conducted an analysis using Kaplan-Meier survival curves by mode of operation with respect to IOL type. Consequently, there were statistical differences ( $P = 0.0002$ ) (Fig. 2). Patients with an implantation of diffractive MIOL (AT LISA tri 839MP) were more likely to require Nd: YAG laser capsulotomy. There was no distinct difference in patients with implantation of a segmental refractive MIOL with or without ACP ( $P = 0.69$ ) (Fig. 3). Moreover, there was no marked difference in patients with implantation of a diffractive MIOL ( $P = 0.13$ ) (Fig. 4).

## Discussion

The occurrence of postoperative PCO is considered as a wound healing outcome of the residual LECs [7, 8]. LECs play an essential role in the progression and development of capsular fibrosis and contraction [9, 10]. In our study, a polisher was used to polish the anterior capsule to eliminate the LECs. Theoretically, PCO could be reduced by the removal of these cells. Numerous clinical studies have compared PCO between eyes with capsule polishing and eyes without anterior capsule polishing. Nevertheless, no consensus has been reached on the effectiveness of polishing.

A three-year randomized trial revealed that ACP does not prevent the formation of PCO but allows for more regenerative cataract [11]. Similarly, herein, we established that the rate of Nd: YAG capsulotomy in non-polishing is higher than polishing 3 years postoperatively, but there is no significant difference.

Another study showed that the incidence of PCO in the 360-degree polishing group is lower, although not markedly different during a one-year follow-up<sup>[12]</sup>. Consistently, in a different study, the results revealed no apparent advantages of scraping on ACO development in a cohort of 120 eyes with a 6-month follow-up<sup>[13]</sup>. Three years following a cataract operation, the ACO of the eyes with polished anterior capsule decreases significantly. However, polishing does not reduce the incidence of PCO when the sharp-edged IOL is implanted in the bag. Even though the results showed that ACP promotes the development of regenerative PCO, this trend is not statistically significant<sup>[14]</sup>.

Another study explained why polishing the anterior capsule did not reduce the PCO rate<sup>[15]</sup>. The surgical techniques, including ACP, have a crucial effect on the growth of residual cells *in vitro*. Notably, although the cells under the anterior capsule are almost entirely removed by polishing before culture, ACP significantly promotes the growth of pouch cells cultured *in vitro* during phacoemulsification in the human eyes. In the study, capsule polishing did not eliminate all the LECs, and that capsule polishing stimulated strong remaining cell proliferation *in vitro*, while numerous living cells in unpolished eyes tended to die, leading to less proliferation.

However, some studies indicated that ACP remarkably lessens the incidence of PCO. In one study, the results posited that lower anterior capsule opacification (ACO) and fibrotic PCO with both round-edged silicone IOLs 3-years postoperatively in eyes which the anterior capsule was extensively polished<sup>[16]</sup>. A meta-analysis of studies for 1-year or longer follow-up showed that the PCO rate was reduced in the ACP group based on the summary odds ratio on the PCO rate (OR 0.42 95% CI 0.24–0.73)<sup>[17]</sup>.

Besides, some studies show that ACP changes the position stability of IOL. A previous study indicated decreasing the polishing of anterior capsule enhances the rotational firmness of a toric IOL<sup>[18]</sup>. However, a study involving 30 patients (60 eyes) revealed that the eyes that did not undergo intraoperative ACP had a likelihood for backward IOL movement by about 0.2mm, at two months after surgery<sup>[19]</sup>. Another study posited that 360° ACP effectively reduces the incidence of the anterior capsule contraction and raises the firmness of IOL in cataract patients with high myopia<sup>[20]</sup>.

In the present study, we primarily analyzed the rate of Nd: YAG capsulotomies between two groups using Kaplan-Meier survival curves. Based on the type of IOL implanted in the two groups, there were statistical differences between the two groups by different types of IOL. We found that diffractive MIOL (AT LISA tri 839MP) had a higher incidence of PCO than segmental refractive MIOL (SBL-3) in both the ACP and the non-ACP groups. The kind of intraocular lens could affect the occurrence of PCO. We analyzed the two types of MIOL with Kaplan-Meier survival to verify the effect of ACP on the incidence of PCO in the two kinds of MIOL. Consequently, there were no distinct differences between the two types of MIOL. Therefore, ACP did not affect diffractive MIOL (AT LISA tri 839MP) and segmental refractive MIOL (SBL-3).

We demonstrate that ACP shows no difference in terms of PCO formation in MIOL. A recent study recommended ACP for eyes only with a higher risk of anterior capsule contraction, such as myotonic

dystrophy and high myopia, and for those who must undergo a peripheral retinal examination after surgery [21]. Therefore, intraoperative ACP might not be a routine choice for ophthalmologists to reduce the incidence of PCO. However, the role of ACP in maintaining the stability of IOL cannot be ignored, especially for MIOL, because some studies have shown that it reduces the occurrence of ACO and the anterior capsule contraction [18–20].

## **Conclusion**

There is no significant advantage of polishing on the anterior capsule to decrease the rate of Nd: YAG laser capsulotomy after phacoemulsification in MIOL. ACP might not be a routine choice for ophthalmologists to reduce PCO.

## **Declarations**

### **Competing Interests**

The authors declare that there is no conflict of interest.

### **Funding Info**

No funding or grant support was used for the writing of this report.

### **Author Contribution**

Honglei Li and Xiaoming Wu were the major contributors to the experimental design and drafting of the manuscript. Huiran Bai analyzed and interpreted collected data. Dongle Liu and Yanfeng Han contributed to the study concept and design. All authors reviewed and approved the final manuscript.

### **Data Availability**

The corresponding author had full access to all the data in the study and takes responsibility for the integrity of the data and the accuracy of the data analysis as well as the decision to submit for publication.

### **Animal Research (Ethics)**

Not applicable

### **Consent to Participate (Ethics)**

The nature of the study was explained to all participants in simple language and an Informed consent was obtained from all individual participants included in the study.

### **Consent to Publish (Ethics)**



There is no prior publication by any other journal.

## References

1. Findl O, Buehl W, Bauer P, Sycha T. Interventions for preventing posterior capsule opacification. The Cochrane database of systematic reviews. 2010; (2): CD003738. <https://doi.org/10.1002/14651858.CD003738.pub3> PMID: 20166069.
2. Shetty NK, Sridhar S. Study of Variation in Intraocular Pressure Spike (IOP) Following Nd- YAG Laser Capsulotomy. *Journal of clinical and diagnostic research : JCDR*. 2016; 10(12): NC09-NC12. <https://doi.org/10.7860/JCDR/2016/21981.9037> PMID: 28208899.
3. Nibourg LM, Gelens E, Kuijer R, Hooymans JM, van Kooten TG, Koopmans SA. Prevention of posterior capsular opacification. *Experimental eye research*. 2015; 136: 100-115. <https://doi.org/10.1016/j.exer.2015.03.011> PMID: 25783492.
4. Awasthi N, Guo S, Wagner BJ. Posterior capsular opacification: a problem reduced but not yet eradicated. *Archives of ophthalmology*. 2009; 127(4): 555-562. <https://doi.org/10.1001/archophthalmol.2009.3> PMID: 19365040.
5. Marcantonio JM, Vrensen GF. Cell biology of posterior capsular opacification. *Eye*. 1999; 13 ( Pt 3b): 484-488. <https://doi.org/10.1038/eye.1999.126> PMID: 10627829.
6. Wormstone IM, Tamiya S, Anderson I, Duncan G. TGF-beta2-induced matrix modification and cell transdifferentiation in the human lens capsular bag. *Investigative ophthalmology & visual science*. 2002; 43(7): 2301-2308. PMID: 12091431.
7. Hanson RJ, Rubinstein A, Sarangapani S, Benjamin L, Patel CK. Effect of lens epithelial cell aspiration on postoperative capsulorhexis contraction with the use of the AcrySof intraocular lens: randomized clinical trial. *Journal of cataract and refractive surgery*. 2006; 32(10): 1621-1626. <https://doi.org/10.1016/j.jcrs.2006.04.035> PMID: 17010857.
8. Nichamin LD. Reduction in the area of the anterior capsule opening after polymethylmethacrylate, silicone, and soft acrylic intraocular lens implantation. *American journal of ophthalmology*. 1997; 124(5): 710-711. [https://doi.org/10.1016/s0002-9394\(14\)70921-3](https://doi.org/10.1016/s0002-9394(14)70921-3) PMID: 9372737.
9. McDonnell PJ, Zarbin MA, Green WR. Posterior capsule opacification in pseudophakic eyes. *Ophthalmology*. 1983; 90(12): 1548-1553. [https://doi.org/10.1016/s0161-6420\(83\)34350-5](https://doi.org/10.1016/s0161-6420(83)34350-5) PMID: 6677855.
10. Wong TT, Daniels JT, Crowston JG, Khaw PT. MMP inhibition prevents human lens epithelial cell migration and contraction of the lens capsule. *The British journal of ophthalmology*. 2004; 88(7): 868-872. <https://doi.org/10.1136/bjo.2003.034629> PMID: 15205227.
11. Menapace R, Wirtitsch M, Findl O, Buehl W, Kriechbaum K, Sacu S. Effect of anterior capsule polishing on posterior capsule opacification and neodymium:YAG capsulotomy rates: three-year randomized trial. *Journal of cataract and refractive surgery*. 2005; 31(11): 2067-2075. <https://doi.org/10.1016/j.jcrs.2005.08.051> PMID: 16412917.

12. Sachdev GS, Soundarya B, Ramamurthy S, Lakshmi C, Dandapani R. Impact of anterior capsular polishing on capsule opacification rate in eyes undergoing femtosecond laser-assisted cataract surgery. *Indian journal of ophthalmology*. 2020; 68(5): 780-785. [https://doi.org/10.4103/ijo.IJO\\_1787\\_19](https://doi.org/10.4103/ijo.IJO_1787_19) PMID: 32317445.
13. Shah SK, Praveen MR, Kaul A, Vasavada AR, Shah GD, Nihalani BR. Impact of anterior capsule polishing on anterior capsule opacification after cataract surgery: a randomized clinical trial. *Eye*. 2009; 23(8): 1702-1706. <https://doi.org/10.1038/eye.2008.355> PMID: 19079142.
14. Bolz M, Menapace R, Findl O, Sacu S, Buehl W, Wirtitsch M, et al. Effect of anterior capsule polishing on the posterior capsule opacification-inhibiting properties of a sharp-edged, 3-piece, silicone intraocular lens: three- and 5-year results of a randomized trial. *Journal of cataract and refractive surgery*. 2006; 32(9): 1513-1520. <https://doi.org/10.1016/j.jcrs.2006.04.020> PMID: 16931265.
15. Liu X, Cheng B, Zheng D, Liu Y, Liu Y. Role of anterior capsule polishing in residual lens epithelial cell proliferation. *Journal of cataract and refractive surgery*. 2010; 36(2): 208-214. <https://doi.org/10.1016/j.jcrs.2009.08.020> PMID: 20152599.
16. Sacu S, Menapace R, Wirtitsch M, Buehl W, Rainer G, Findl O. Effect of anterior capsule polishing on fibrotic capsule opacification: three-year results. *Journal of cataract and refractive surgery*. 2004; 30(11): 2322-2327. <https://doi.org/10.1016/j.jcrs.2004.02.092> PMID: 15519082.
17. Han MY, Yu AH, Yuan J, Cai XJ, Ren JB. Effect of anterior capsule polish on visual function: A meta-analysis. *PloS one*. 2019; 14(1): e0210205. <https://doi.org/10.1371/journal.pone.0210205> PMID: 30620750.
18. Zhu X, He W, Zhang K, Lu Y. Factors influencing 1-year rotational stability of AcrySof Toric intraocular lenses. *The British journal of ophthalmology*. 2016; 100(2): 263-268. <https://doi.org/10.1136/bjophthalmol-2015-306656> PMID: 26089212.
19. Bang SP, Yoo YS, Jun JH, Joo CK. Effects of Residual Anterior Lens Epithelial Cell Removal on Axial Position of Intraocular Lens after Cataract Surgery. *Journal of ophthalmology*. 2018; 2018: 9704892. <https://doi.org/10.1155/2018/9704892> PMID: 30210870.
20. Wang D, Yu X, Li Z, Ding X, Lian H, Mao J, et al. The Effect of Anterior Capsule Polishing on Capsular Contraction and Lens Stability in Cataract Patients with High Myopia. *Journal of ophthalmology*. 2018; 2018: 8676451. <https://doi.org/10.1155/2018/8676451> PMID: 30425856.
21. Biswas P, Batra S. Commentary: Anterior capsule polishing: The present perspective. *Indian journal of ophthalmology*. 2020; 68(5): 785-786. [https://doi.org/10.4103/ijo.IJO\\_2088\\_19](https://doi.org/10.4103/ijo.IJO_2088_19) PMID: 32317446.

## Figures

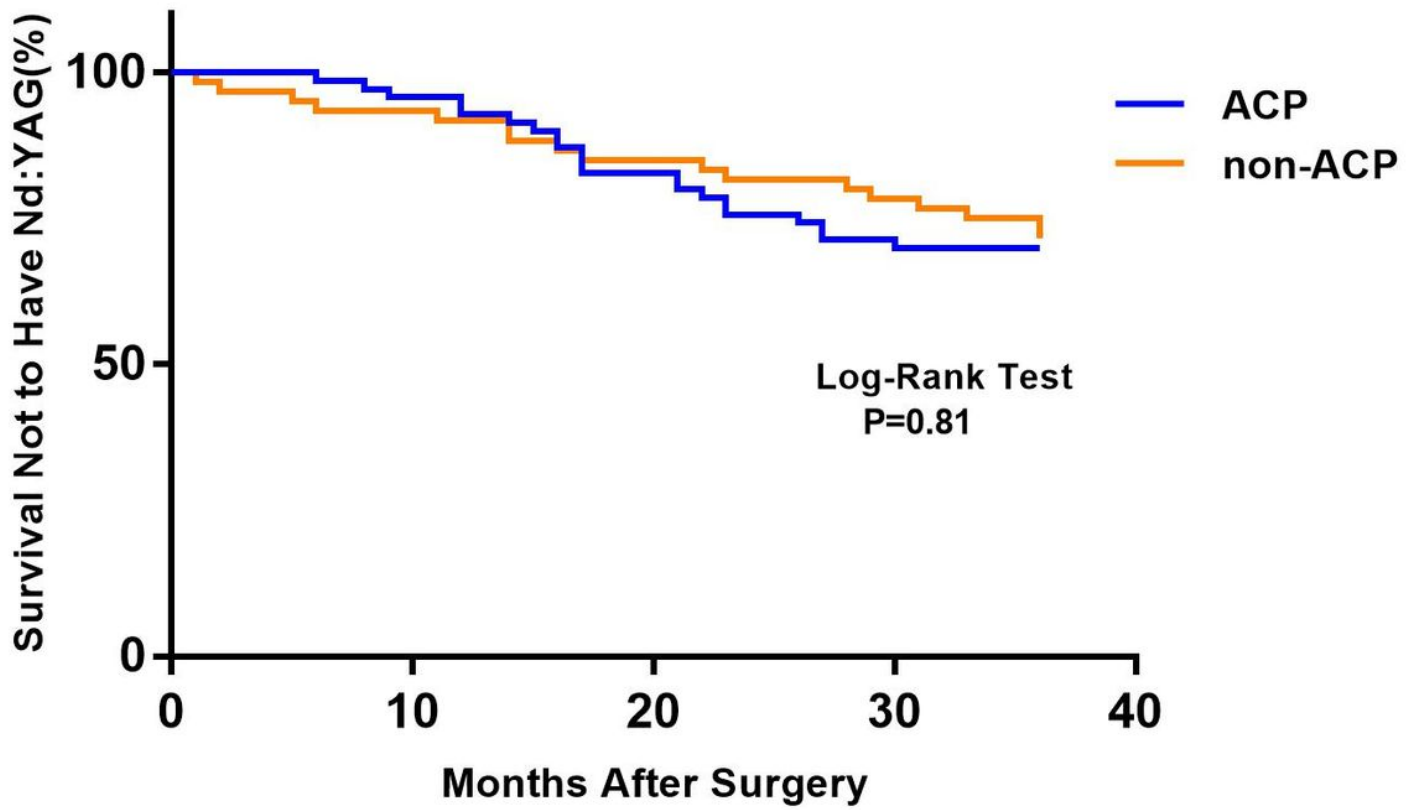


Figure 1

Kaplan-Meier survival plots for eyes by surgical treatment (Nd:YAG=neodymium:YAG laser capsulotomy (ACP=anterior capsule polishing))

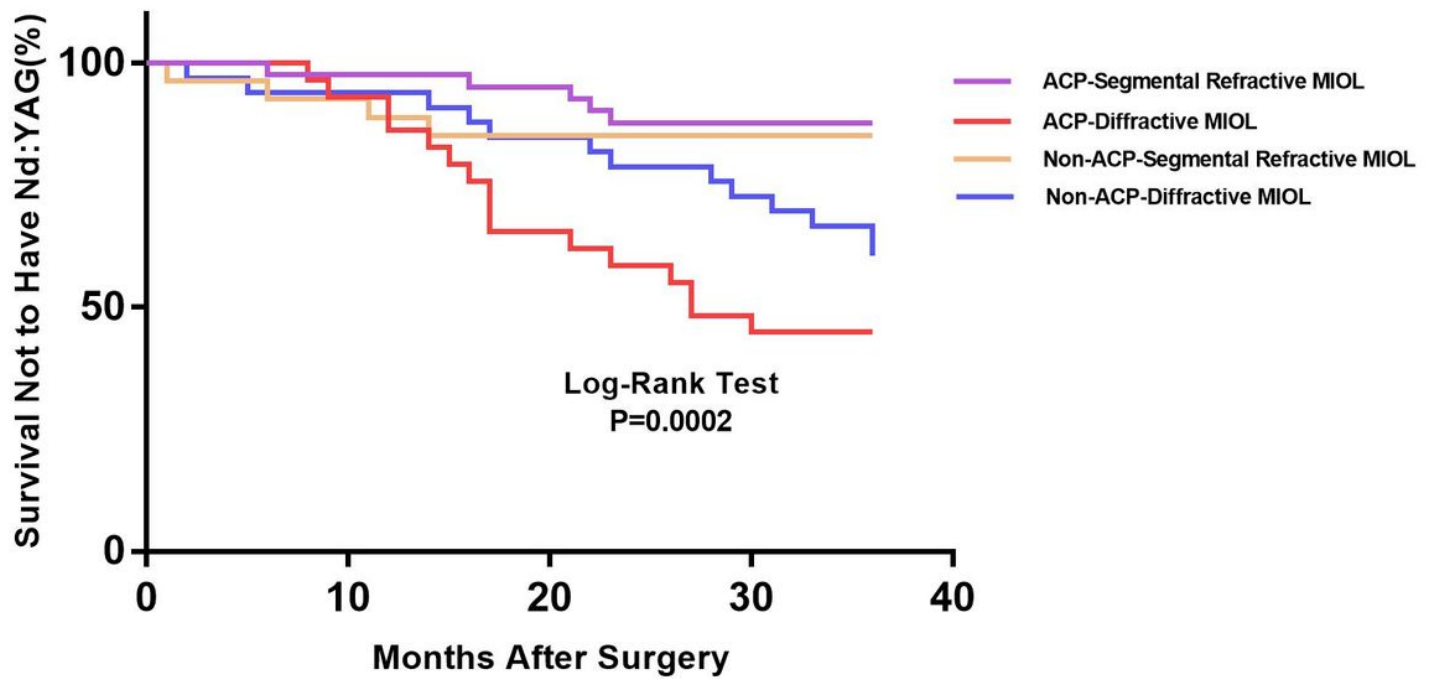


Figure 2

Kaplan-Meier survival plots for eyes by different IOL types in different surgical treatments  
 ☒Nd:YAG=neodymium:YAG laser capsulotomy☒ACP=anterior capsule polishing☒

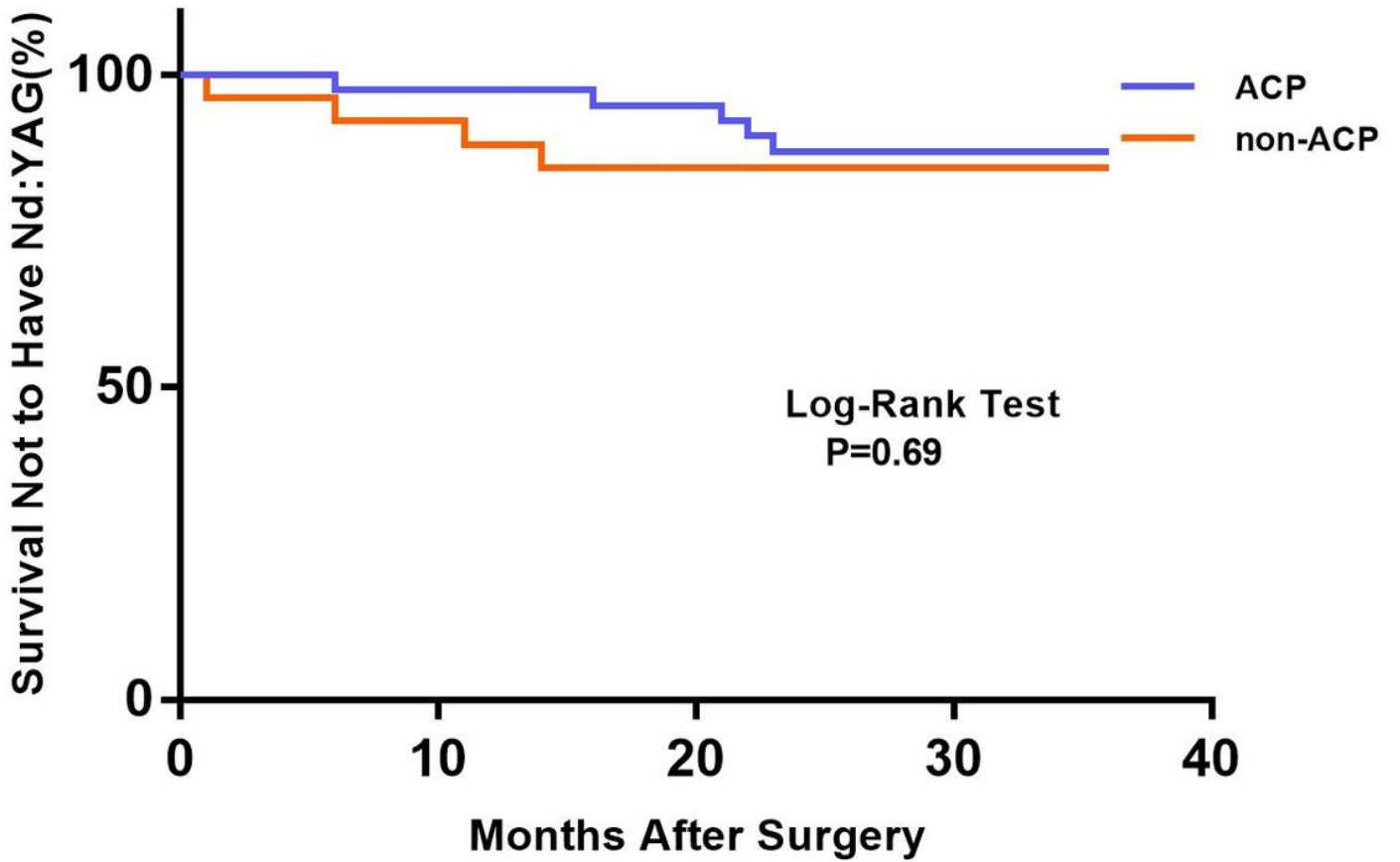


Figure 3

Kaplan-Meier survival plots for eyes by different surgical treatments about segmental refractive MIOL(SBL-3) Nd:YAG=neodymium:YAG laser capsulotomy ACP=anterior capsule polishing

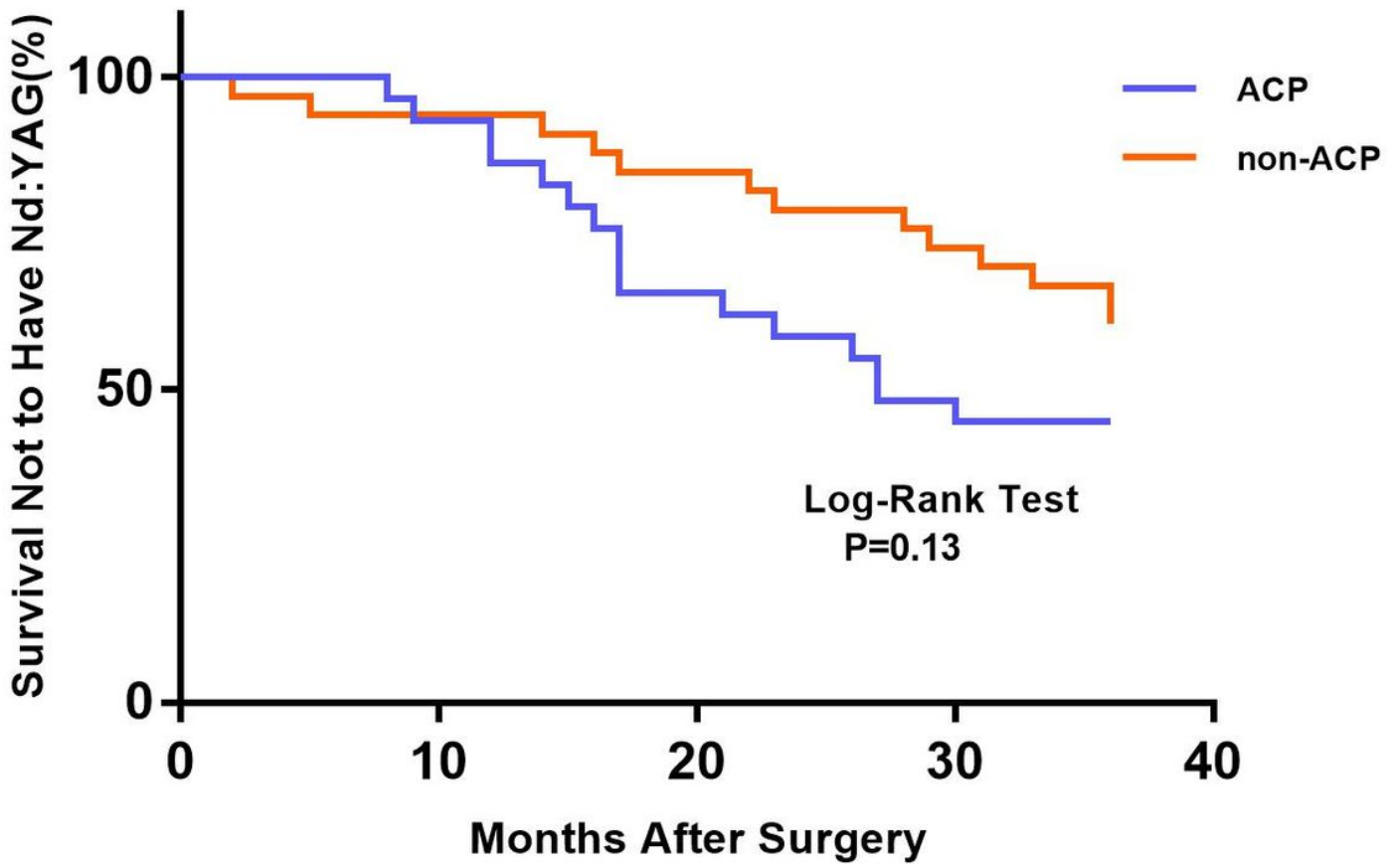


Figure 4

Kaplan-Meier survival plots for eyes by different surgical treatments about diffractive MIOL (AT LISA tri 839MP) Nd:YAG=neodymium:YAG laser capsulotomy ACP=anterior capsule polishing