

# Attenuation of Liver Damage After Partial Liver Resection by Piezo Actuator-driven Pulsed Water Jet System and Faster Recovery of the Liver in a Rat Model: an Experimental Study

**Tomoki Yokosawa**

Department of Surgery, Tohoku University Graduate School of Medicine

**Chikashi Nakanishi** (✉ [chikashi-n@med.tohoku.ac.jp](mailto:chikashi-n@med.tohoku.ac.jp))

<https://orcid.org/0000-0003-0364-9801>

**Atsuhiko Nakagawa**

Department of Neurosurgery, Tohoku University Graduate School of Medicine

**Yoshihiro Kamiyama**

Department of Urology, Tohoku University Graduate School of Medicine

**Shinichi Yamashita**

Department of Urology, Tohoku University Graduate School of Medicine

**Shigehito Miyagi**

Department of Surgery, Tohoku University Graduate School of Medicine

**Toru Nakano**

Department of Surgery, Tohoku University Graduate School of Medicine

**Takaaki Abe**

Department of Clinical Biology and Hormonal Regulation, Tohoku University Graduate School of Medicine

**Teiji Tominaga**

Department of Neurosurgery, Tohoku University Graduate School of Medicine

**Takashi Kamei**

Department of Surgery, Tohoku University Graduate School of Medicine

---

## Research

**Keywords:** minimally invasive surgery, pulsed water jet, partial liver resection

**Posted Date:** May 15th, 2020

**DOI:** <https://doi.org/10.21203/rs.3.rs-28285/v1>



# Abstract

## Background

Pulsed water jet dissection is an emerging surgical method for achieving maximal resection of a lesion and postoperative function preservation. We aimed to clarify liver damage and long-term results after liver resection using a novel surgical device, piezo actuator-driven pulsed water jet (ADPJ), in a rat model.

## Methods

We categorized Sprague–Dawley rats into four groups and subjected them to sham operation or liver resection using an ADPJ, an ultrasonic aspirator (UA), or a radio knife. At 1, 3, 7, 14, 28, and 56 days postoperatively, we euthanized five rats from each group after collecting blood samples and harvested residual livers. We measured serum aspartate aminotransferase (AST), alanine aminotransferase (ALT), and glutamate dehydrogenase (GLDH) concentrations. Morphological characteristics and resection surfaces were assessed by hematoxylin–eosin staining.

## Results

On day 1, serum AST and ALT levels were significantly lower with an ADPJ than with an UA and a radio knife (AST: ADPJ vs. UA,  $P < 0.05$ , ADPJ vs. radio knife,  $P < 0.01$ ; ALT: ADPJ vs. UA,  $P < 0.05$ , ADPJ vs. radio knife,  $P < 0.01$ ). GLDH levels on day 1 were significantly lower with an ADPJ than with other devices (ADPJ vs. UA,  $P < 0.05$ ; ADPJ vs. radio knife,  $P < 0.01$ ). Degree of degeneration from the resection surface was mild with an ADPJ. Number of rats in which denaturation completely disappeared was significantly more with an ADPJ than with other devices on day 28 (ADPJ vs. UA,  $P < 0.05$ ; ADPJ vs. radio knife,  $P < 0.01$ ).

## Conclusions

Liver damage after liver resection was markedly less with an ADPJ than with an UA or a radio knife. Furthermore, the liver recovered faster after an ADPJ.

## Background

Recent years have witnessed the introduction of several interventions to decrease intraoperative blood loss during liver surgery because excessive blood loss exacerbates the risk of postoperative complications.[1] Previously, vascular occlusion techniques, including inflow occlusion (Pringle maneuver),[2] outflow occlusion, or both, have been used to decrease bleeding during parenchymal resection.[3, 4] Reportedly, concomitant use of hypoventilation [5] and low central venous pressure (CVP) anesthesia [6] further minimizes blood loss by evading retrograde bleeding from the hepatic veins. Considering inflow occlusion and low CVP anesthesia could cause marked damage by ischemia and reperfusion, especially in patients with declined liver functional reserve, developing new devices is necessary to facilitate bloodless resection by precluding the need for vascular occlusion. In the 1960s, the finger fracture technique was developed to dissect the liver parenchyma while preserving the hepatic

vessels,[7] which was followed by the introduction of the clamp-crushing technique,[8] ultrasonic aspirators (UAs),[9] and water jet dissectors with continuous water flow.[10, 11] Nevertheless, to date, the optimal method for liver parenchymal resection while preserving the hepatic vessels to minimize blood loss and procedure time awaits establishment. At present, selecting the type of parenchymal dissection method during surgery is primarily at the surgeons' discretion.

Water jet devices with continuous water flow [12] facilitate the dissection of an organ while preserving vessels exceeding 100–200  $\mu\text{m}$  in diameter [13]; however, some limitations of these tools are the formation of air bubbles, which obscure the operative field, and the splashing of bloody fluids. Meanwhile, pulsed water jet dissection [14, 15] is an evolving technology that could attain dissection with remarkably decreased water consumption.[16] Some recent neurosurgical studies using laser-induced pulsed water jet devices reported a marked reduction in intraoperative blood loss and procedure time along with the increased tumor removal volume in cases of complex pituitary and skull base lesions.[17]

The novel piezo actuator-driven pulsed water jet (ADPJ) system [16] offers intermittent water flow, contributing to dissection at a constant depth and reduction in the water volume. Compared with laser-induced pulsed water jet devices, the ADPJ system can be pulsed at a higher frequency (laser: 1–10 Hz, ADPJ:100–800 Hz) and adjust the output more precisely by altering the driving voltage. Thus, compared with other techniques mentioned above, the ADPJ system can make an incision more quickly, precisely, and safely.[16] In an *ex vivo* study using swine livers, the ADPJ system enabled the operator to dissect the liver parenchyma while preserving the hepatic veins and Glisson's sheaths.[18] A 7-day observational study in a swine model reported successful liver resection with the new ADPJ system; however, it did not evaluate liver damage and the observation period was short.[19] Moreover, the UA used was SonoSurg<sup>™</sup> (Olympus Corporation, Tokyo, Japan), not CUSA<sup>™</sup> Excel+ (Tullamore, Co. Offaly, Ireland), which is used most often [19]. Thus, for the future clinical application, studies investigating liver damage after liver resection with the ADPJ system, along with prolonged observation, are warranted. Furthermore, the ADPJ system merits comparison with CUSA<sup>™</sup> Excel+. Hence, this study aimed to evaluate liver damage and long-term results after partial liver resection using the ADPJ system and compare the findings with a commercially available UA (CUSA<sup>™</sup> Excel+) or radio knife. A rat model was used in the present study because long-term results are easy to obtain and the number of animals used increases.

## Results

### Subjects

We observed no differences in the preoperative body weights of the rats among the four groups ( $P=0.669$ ) and no significant differences among the three groups regarding partial liver resection volumes ( $P=0.981$ ). In addition, operative procedure times were significantly shorter with an UA than with the ADPJ system and a radio knife ( $P<0.01$ ; Table 1). No complications were observed in any rat during the experiments.

On day 7, postoperative changes in body weight were significantly lower in the radio knife group than that in the ADPJ system and UA groups ( $P < 0.05$ ; Fig. 1). We observed no difference between the ADPJ system group and the UA group in all periods (Fig. 1).

Table 1  
Surgical outcomes

		Radio Knife	ADPJ	UA	Sham
Preoperative body weight (g)	Mean	303.67	305.13	303.87	302.20
	SD	7.71	10.57	6.90	10.16
Operative procedure time (min)	Mean	16.27	15.93	14.57	4.33
	SD	1.65	1.29	1.48	0.54
Liver resection volume (g)	Mean	1.48	1.47	1.48	-
	SD	0.27	0.24	0.26	-

No differences were noted in the preoperative body weights of the rats among the four groups ( $P = 0.669$ ). Operative procedure times were significantly shorter with an ultrasonic aspirator (UA) than with the actuator-driven pulsed water jet (ADPJ) system and a radio knife ( $P < 0.01$ ). Furthermore, no significant differences were observed among the three groups regarding partial liver resection volumes ( $P = 0.981$ ).

## Blood samples

On day 1, serum AST and ALT levels were significantly lower in the ADPJ system group than in the UA and radio knife groups (AST: ADPJ vs. UA,  $136.0 \pm 27.29$  U/L vs.  $191.4 \pm 29.33$  U/L,  $P < 0.05$ ; ADPJ vs. radio knife,  $136.0 \pm 27.29$  U/L vs.  $318.6 \pm 76.34$  U/L,  $P < 0.01$ ; ALT: ADPJ vs. UA,  $82.0 \pm 21.70$  U/L vs.  $141.4 \pm 36.85$  U/L,  $P < 0.05$ ; ADPJ vs. radio knife,  $82.0 \pm 21.70$  U/L vs.  $283.6 \pm 72.23$  U/L,  $P < 0.01$ ). We observed no differences between the sham group and the ADPJ system group (AST,  $P = 0.082$ ; ALT,  $P = 0.153$ ). After day 3, both AST and ALT levels declined to the preoperative levels in all groups with no difference between each group (Figs.2 and 3).

On day 1, serum GLDH levels were significantly lower with the ADPJ system than with other devices (ADPJ vs. UA,  $8.10 \pm 1.59$  mU/mL vs.  $12.91 \pm 3.39$  mU/mL,  $P < 0.05$ ; ADPJ vs. radio knife,  $8.10 \pm 1.59$  mU/mL vs.  $15.76 \pm 2.75$  mU/mL,  $P < 0.01$ ). On day 3, higher GLDH levels were observed in the radio knife group alone compared with the ADPJ system group (ADPJ vs. radio knife,  $3.42 \pm 0.76$  mU/mL vs.  $6.18 \pm 0.61$  mU/mL,  $P < 0.01$ ). Conversely, compared with the sham group, the ADPJ system was the first group in which the GLDH difference disappeared (Fig.4).

## Histopathological examination

The HE staining of the liver tissue dissected by the ADPJ system exhibited marginal crush injury and degeneration on postoperative day 1; this change was almost not visible at 14 days postoperatively and completely disappeared on day 28. Contrarily, we observed broad necrosis below the resection surface in almost all livers coagulated by a radio knife, which persisted even after 28 days postoperatively. Although not as much as the radio knife group, degenerative parts persisted on day 28 in the UA group (Fig.5).

Despite observing no significant difference compared with UA, the maximum depth of degeneration from the resection surface was mild in the ADPJ system group (Fig.6). The number of rats in which denaturation completely disappeared was significantly higher in the ADPJ system group than in the radio knife group by day 14 ( $P < 0.05$ ) and the UA group by day 28 ( $P < 0.05$ ; Table 2).

Table 2  
Number of rats in which denaturation completely disappeared

Day	Device			Fisher's exact test (vs.ADPJ)	
	Radio Knife	ADPJ	UA	$P$ (Radio Knife)	$P$ (UA)
Day 1	0	0	0		
Day 3	0	0	0		
Day 7	0	0	0		
Day 14	0	4	1	0.0238	0.1032
Day 28	0	5	1	0.0040	0.0238
Day 56	0	5	5	0.0040	

The number of rats in which denaturation had completely disappeared was significantly higher in the actuator-driven pulsed water jet (ADPJ) system group than in the radio knife group by day 14 ( $P < 0.05$ ) and the ultrasonic aspirator (UA) group by day 28 ( $P < 0.05$ ).

## Discussion

Water jet technology, which is based on a conventional pressure-driven continuous method [13, 20] or pulsed laser method,[15] is promising in terms of tissue dissection. Reportedly, water jet technology can selectively dissect a tissue while preserving fine blood vessels ( $\sim 100\text{--}200\text{ }\mu\text{m}$ ) and nerves based on different tensile strengths of tissues against the jet flow.[13] Thus, compared with ultrasonic aspiration or blunt dissection, water jet technology has been frequently used to decrease blood loss and parenchymal trauma during liver surgery because the liver contains an abundant small vessel network.[10]

Previously, surgeons using water jet devices with continuous water flow for liver resection have reported that compared with other conventional methods such as UA, water jet devices decreased blood loss, transection time, and complication rates.[10, 11] Another advantage of water jet technology is the absence of thermal damage, which is inevitable with other commercially available instruments. Recently

developed piezoelectric actuator can replace a pulsed laser system, and we have developed a piezo ADPJ system that can dissect tissues while preserving fine blood vessels and causing no thermal injury.[16] Of note, the ADPJ system is markedly different from a conventional water jet dissector because the ADPJ system offers intermittent water flow providing more precise dissection within a certain depth and less water volume compared with a conventional continuous water jet. In a basic engineering experiment, Seto et al. reported that the dissection characteristics of pulsed jets were superior to those of existing continuous water flows.[16]

Furthermore, thermal injury should be regarded as a risk factor for liver damage. Regarding liver damage after partial liver resection using the ADPJ system in this study, the serum AST, ALT, and GLDH levels immediately after surgery were markedly lower in the ADPJ group than in the UA and radio knife groups, suggesting that compared with other devices, the ADPJ system might exert no effect of thermal injury on liver cells during surgery. In addition, the resection surface with the ADPJ system was less injured than that with other devices on HE staining. Remarkably, compared with the other available devices, the ADPJ system exhibited the best recovery after dissection. Hence, the ADPJ system could attenuate liver damage after partial liver resection.

In this study, because one surgeon performed all partial liver resections under similar conditions, the liver enzyme elevation and differences of damage in the resection surface could be attributed to the characteristics of each surgical device. In addition, compared with conventional surgical devices, the ADPJ system could minimize liver damage after partial liver resection. Moreover, water jet technology could be useful for endoscopic surgery. Sato et al. reported that an endoscopic pulsed water jet system is a feasible alternative to endoscopic submucosal dissection in a swine model.[21] Similarly, Shi et al. [22] safely conducted natural orifice transluminal endoscopic liver resection using a water jet device in a non-surviving swine model. Perhaps, the ADPJ system could overcome some of the limitations related to water jet devices that arise from the continuous water flow. Reportedly, the peak pressure of the pulsed water jet is controllable in the ADPJ system by changing the input voltage [18]; thus, this device could be used to dissect various tissues with different physical properties. Yamada et al. reported the difference in the physical properties of the liver parenchyma, hepatic veins, and Glisson's sheaths and successfully dissected the liver parenchyma while preserving the hepatic veins and Glisson's sheaths.[18] Similarly, assessing the physical properties of liver tumors in the future could facilitate the excavation of only the tumor without breaking the tumor, which would be useful in cases of liver resection when a tumor is adjacent to the main vessel.

Although we used a rat model in this study, we previously reported successful liver resection using the ADPJ system in a surviving pig model.[19] Remarkably, the ADPJ system causes less liver damage than CUSA™ Excel+, one of the most commonly used devices. In addition, our 56-day observation revealed that liver recovery could be faster using the ADPJ system than using CUSA™ Excel+. These findings suggested that the ADPJ system could be safely used in clinical liver resection.

This study has several limitations. First, operation times were markedly shorter with UA than with the ADPJ system. The characteristic of the ADPJ system prolongs the time required to stabilize the output, thereby extending the operation time. Although this limitation warrants further investigation, it could be solved by improving the pump. Second, we used a rat model in this study because of the number of animals needed to assess liver damage and histological changes after partial liver resection. Finally, the experimental period of 56 days after partial liver resection was not very long because no differences existed between the ADPJ system and UA, although the observation was ended to minimize the number of animals used.

## Conclusions

In this study, compared with the existing UA or radio knife, the ADPJ system caused less liver damage after partial liver resection, highlighting a possibility of accelerating tissue repair. Therefore, this study suggests that the ADPJ system could cause less liver function impairment in partial liver resection, thereby contributing to improved outcomes after partial liver resection.

## Methods

### Partial liver resection in rats

This study was designed based on a previous study.[23] In this study, we randomly categorized 120 (age, 9 weeks; male) Sprague–Dawley rats into four groups and subjected them to sham operation, partial liver resection by the ADPJ system, an UA (CUSA™ Excel+; aspiration, 30%; irrigation, 2 mL/min; amplitude, 30; tissue select, standard), and a radio knife (Diatermo MB122K; GIMA, Gessate, Italy; Monopolar COAG mode, 15 V;  $n = 30$ /group). The rats were supplied by Kumagai-shigeyasu Co.,Ltd, (sendai, Miyagi, Japan). These rats were placed inside each cage in a temperature-controlled room, with food and water provided ad libitum under a 12-h light/dark diurnal cycle. All rats were anesthetized with inhalation of an isoflurane anesthesia apparatus (MK-A110; Muromachi Kikai Co., Ltd., Tokyo, Japan). In the sham group, the rats' abdomens were opened but immediately closed. In the ADPJ system group, after opening the abdomen, we lifted the left lateral lobe of the liver. Then, the liver capsule was cut with a scalpel, and the liver parenchyma was dissected by the ADPJ system (input voltage, 25 V; water supply, 4 mL/min; pulsed water jet ejection rate, 400 Hz; Fig. 7a). Next, we ligated the preserved fine blood vessels using the ADPJ system by silk thread (Fig. 7b). Notably, the mean weight of the removed liver tissue was 1.47 g. Likewise, in the radio knife and UA groups, we dissected the liver parenchyma using each device. The weight of the removed liver in these groups corroborated that in the ADPJ system group ( $P = 0.981$ ). All operative procedure times were recorded, and all operations were performed by a single surgeon.

All rats were again anesthetized with isoflurane. At 1, 3, 7, 14, 28, and 56 days after partial liver resection, we humanely euthanized five rats from each group with exsanguination under deep anesthesia in the laboratory, after collecting blood samples and harvested all residual livers ( $n = 5$ /group, during each period). In addition, blood was also collected from 5 new 9-week-old rats for comparison. All experiments



conducted in this study were approved by the Institutional Review Board at the Center for Laboratory Animal Research, Tohoku University (the approval code: 2017Mda-202).

## Blood samples

We assessed liver damage after partial liver resection by aspartate aminotransferase (AST), alanine aminotransferase (ALT), and glutamate dehydrogenase (GLDH) concentrations in the serum. AST and ALT were measured using a clinical analyzer (FUJI DRI-CHEM 7000V; Fuji Film Co., Ltd., Tokyo, Japan), whereas GLDH was measured using an Enzyme-Linked ImmunoSorbent Assay kit (CSB-E13841r; Cusabio Technology LLC, Houston, USA).

## Histopathological examination

All harvested entire livers were immediately immersed in 10% neutral-buffered formalin solution. First, we embedded the livers in paraffin, which were sectioned to 3-mm sections, and examined using hematoxylin–eosin (HE) staining. Next, coagulation necrosis was defined as degeneration, and the maximum depth of degeneration from the resection surface was vertically measured. In addition, we counted the number of rats in which denaturation had completely disappeared in the preparations. All preparations were observed with a microscope (AxioCam MRc, Carl Zeiss Microimaging GmbH, Göttingen, Germany) and measured.

## Statistical analysis

In this study, statistical analyses were performed using JMP 13 Pro statistical software (SAS Institute Inc., Cary, NC). All data are presented as mean  $\pm$  standard deviation. All four groups were compared using one-way analysis of variance. In addition, individual groups were compared using *t*-test, whereas the number of rats with disappeared denaturation was compared using Fisher's exact test.  $P < 0.05$  was considered statistically significant.

## Abbreviations

ADPJ  
piezo actuator-driven pulsed water jet  
UA  
ultrasonic aspirator  
AST  
aspartate aminotransferase  
ALT  
alanine aminotransferase

GLDH  
glutamate dehydrogenase  
CVP  
central venous pressure  
HE  
hematoxylin–eosin

## **Declarations**

## **Ethics**

All experiments conducted in this study were approved by the Animal Experiment Committee of Tohoku University.

## **Consent for publication**

Not applicable.

## **Availability of data and materials**

Not applicable.

## **Competing interest**

AN and TT received research support for this study from Seiko Epson Co., Ltd. under a collaborative research contract with Tohoku University. Other authors have no conflicts of interest to declare.

## **Funding**

This research was supported by The Clinical Research Promotion Program for Young Investigators of Tohoku University Hospital and a grant from the Miyagi Kidney Foundation, in the design of the study; the Translational Research Network Program of the Japanese Ministry of Education, Culture, Sports, Science, and Technology (MEXT), the Japanese Foundation for Research and Promotion of Endoscopy Grant and Grants-in-Aid for Scientific Research of the Japan Society for the Promotion of Science (A: 15H01707; B: 26282116 and 15H04945; C: 26462196, 26462197, 24592049, 26461297, 15K10353, 15K10572, 15K10018, and 18K08561), in data collection, analysis and interpretation.

## **Author contributions**

TY, CN, and AN designed the research. TY and CN performed most of the experiments. YK and SY performed the experiments. AN, SM, TN, TA, TT, and TK provided scientific advice. TY, CN, and AN wrote the manuscript. All authors reviewed the manuscript and approved the final manuscript.

## Acknowledgments

The piezo actuator-driven pulsed water jet system was supplied by Seiko Epson Corporation as part of a collaborative research contract with Tohoku University. The authors thank Chikako Sato (Department of Surgery, Tohoku University Graduate School of Medicine, Sendai, Miyagi, Japan) and Yasuko Furukawa (Department of Surgery, Tohoku University Graduate School of Medicine, Sendai, Miyagi, Japan) for technical support in data collection.

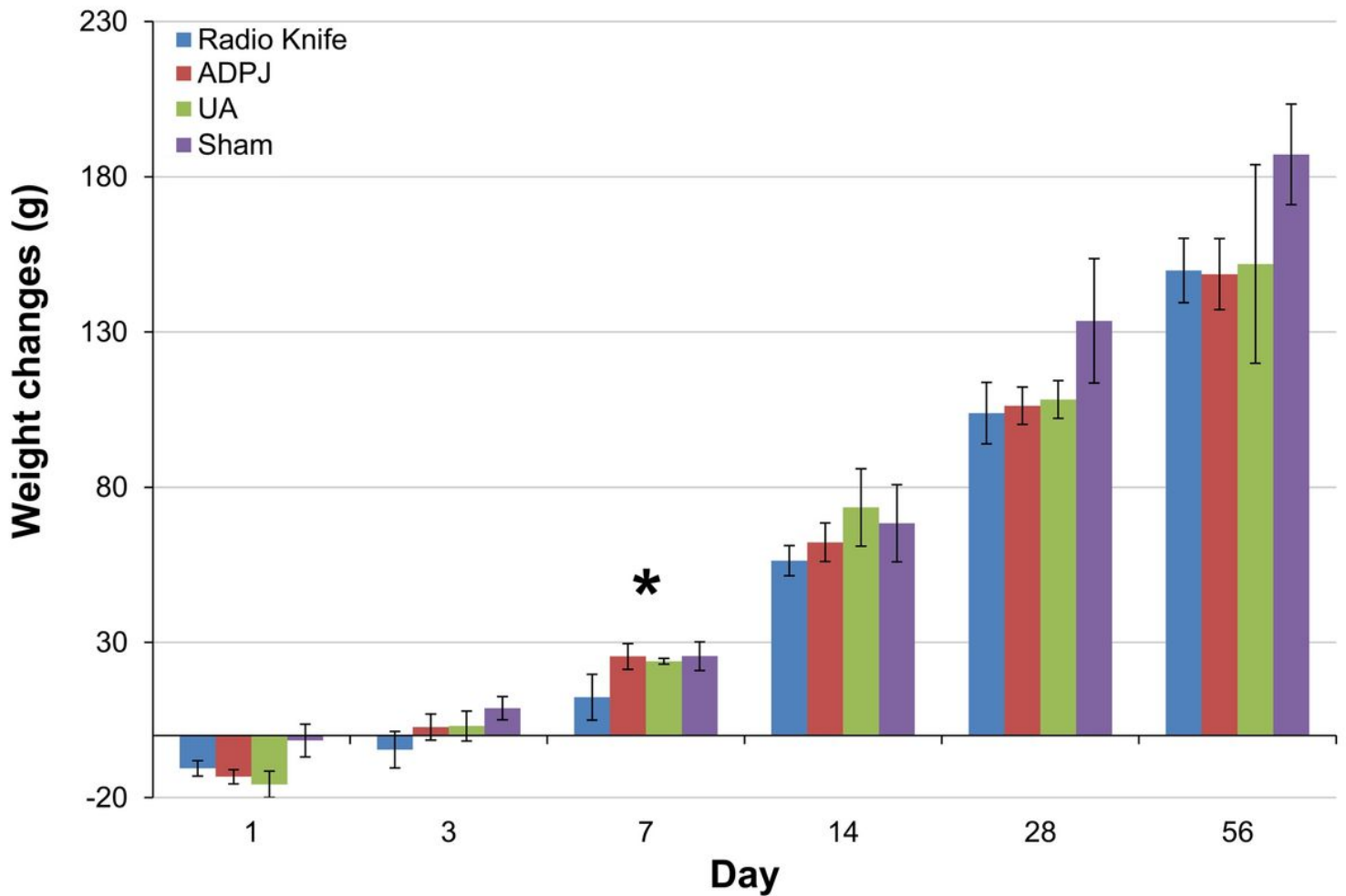
## References

1. Jarnagin WR, Gonen M, Fong Y, DeMatteo RP, Ben-Porat L, Little S, et al. Improvement in perioperative outcome after hepatic resection: analysis of 1,803 consecutive cases over the past decade. *Ann Surg.* 2002;236:397–406.
2. Pringle JH. Notes on the arrest of hepatic hemorrhage due to trauma. *Ann Surg.* 1908;48:541.
3. Belghiti J, Noun R, Zante E, Ballet T, Sauvanet A. Portal triad clamping or hepatic vascular exclusion for major liver resection. A controlled study. *Ann Surg.* 1996;224:155–61.
4. Belghiti J, Noun R, Malafosse R, Jagot P, Sauvanet A, Pierangeli F, et al. Continuous versus intermittent portal triad clamping for liver resection: a controlled study. *Ann Surg.* 1999;229:369–75.
5. Hasegawa K, Takayama T, Oritani R, Sano K, Sugawara Y, Imamura H, et al. Effect of hypoventilation on bleeding during hepatic resection: a randomized controlled trial. *Arch Surg.* 2002;137:311–5.
6. Wang WD, Liang LJ, Huang XQ. Low central venous pressure reduces blood loss in hepatectomy. *World J Gastroenterol.* 2006;12:935–9.
7. Lin TY, Chen KM, Liu TK. Total right hepatic lobectomy for primary hepatoma. *Surgery.* 1960;48:1048–60.
8. Bismuth H, Houssin D, Castaing D. Major and minor segmentectomies “réglées” in liver surgery. *World J Surg.* 1982;6:10–24.
9. Hodgson WJ, Morgan J, Byrne D, DelGuercio LR. Hepatic resections for primary and metastatic tumors using the ultrasonic surgical dissector. *Am J Surg.* 1992;163:246–50.
10. Rau HG, Duessel AP, Wurzbacher S. The use of water-jet dissection in open and laparoscopic liver resection. *HPB (Oxford).* 2008;10:275–80.
11. Vollmer CM, Dixon E, Sahajpal A, Cattral MS, Grant DR, Gallinger S, et al. Water-jet dissection for parenchymal division during hepatectomy. *HPB (Oxford).* 2006;8:377–85.
12. Oertel J, Gaab MR, Warzok R, Piek J. Waterjet dissection in the brain: review of the experimental and clinical data with special reference to meningioma surgery. *Neurosurg Rev.* 2003;26:168–74.

13. Oertel J, Gaab MR, Knapp A, Essig H, Warzok R, Piek J. Water jet dissection in neurosurgery: experimental results in the porcine cadaveric brain. *Neurosurgery*. 2003;52:153–9.
14. Hirano T, Komatsu M, Saeki T, Uenohara H, Takahashi A, Takayama K, et al. Enhancement of fibrinolytics with a laser-induced liquid jet. *Lasers Surg Med*. 2001;29:360–8.
15. Nakagawa A, Hirano T, Komatsu M, Sato M, Uenohara H, Ohyama H, et al. Holmium: YAG laser-induced liquid jet knife: possible novel method for dissection. *Lasers Surg Med*. 2002;31:129–35.
16. Seto T, Yamamoto H, Takayama K, Nakagawa A, Tominaga T. Characteristics of an actuator-driven pulsed water jet generator to dissecting soft tissue. *Rev Sci Instrum*. 2011;82:055105.
17. Ogawa Y, Nakagawa A, Takayama K, Tominaga T. Pulsed laser-induced liquid jet for skull base tumor removal with vascular preservation through the transsphenoidal approach: a clinical investigation. *Acta Neurochir (Wien)*. 2001;153:823–30.
18. Yamada M, Nakano T, Sato C, Nakagawa A, Fujishima F, Kawagishi N, et al. The dissection profile and mechanism of tissue-selective dissection of the piezo actuator-driven pulsed water jet as a surgical instrument: Laboratory investigation using swine liver. *Eur Surg Res*. 2014;53:61–72.
19. Nakanishi C, Nakano T, Nakagawa A, Sato C, Yamada M, Kawagishi N, et al. Evaluation of a newly developed piezo actuator-driven pulsed water jet system for liver resection in a surviving swine animal model. *BioMed Eng Online*. 2016;15:9.
20. Oertel J, Gaab MR, Pillich DT, Schroeder HW, Warzok R, Piek J. Comparison of waterjet dissection and ultrasonic aspiration: an in vivo study in the rabbit brain. *J Neurosurg*. 2004;100:498–504.
21. Sato C, Nakano T, Nakagawa A, Yamada M, Yamamoto H, Kamei T, et al. Experimental application of pulsed laser-induced water jet for endoscopic submucosal dissection: mechanical investigation and preliminary experiment in swine. *Dig Endosc*. 2013;25:255–63.
22. Shi H, Jiang SJ, Li B, Fu DK, Xin P, Wang YG. Natural orifice transluminal endoscopic wedge hepatic resection with a water-jet hybrid knife in a non-survival porcine model. *World J Gastroenterol*. 2011;17:926–31.
23. Yoshihiro K, Shinichi Y, Atsuhiko N, Shinji F, Takuro G, Koji M, et al. Effects of a novel piezo actuator-driven pulsed water jet system on residual kidney after partial nephrectomy in a rat model. *Urology*. 2019;123:265 – 72.

## Figures

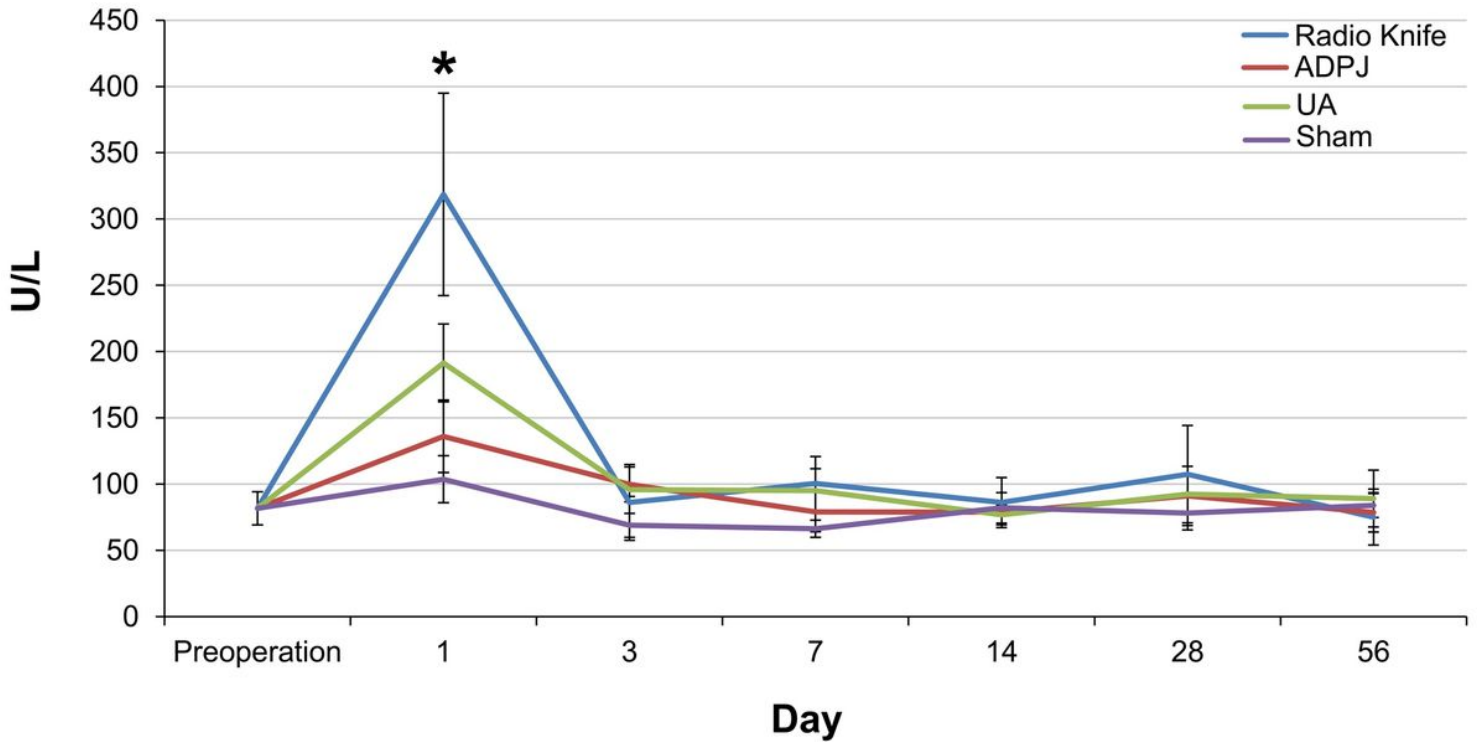
# Weight changes after surgery



**Figure 1**

Postoperative weight changes. On day 7, the postoperative weight changes were significantly smaller in the radio knife group than in the actuator-driven pulsed water jet (ADPJ) system group and the ultrasonic aspirator (UA) group (\* $P < 0.05$ ).

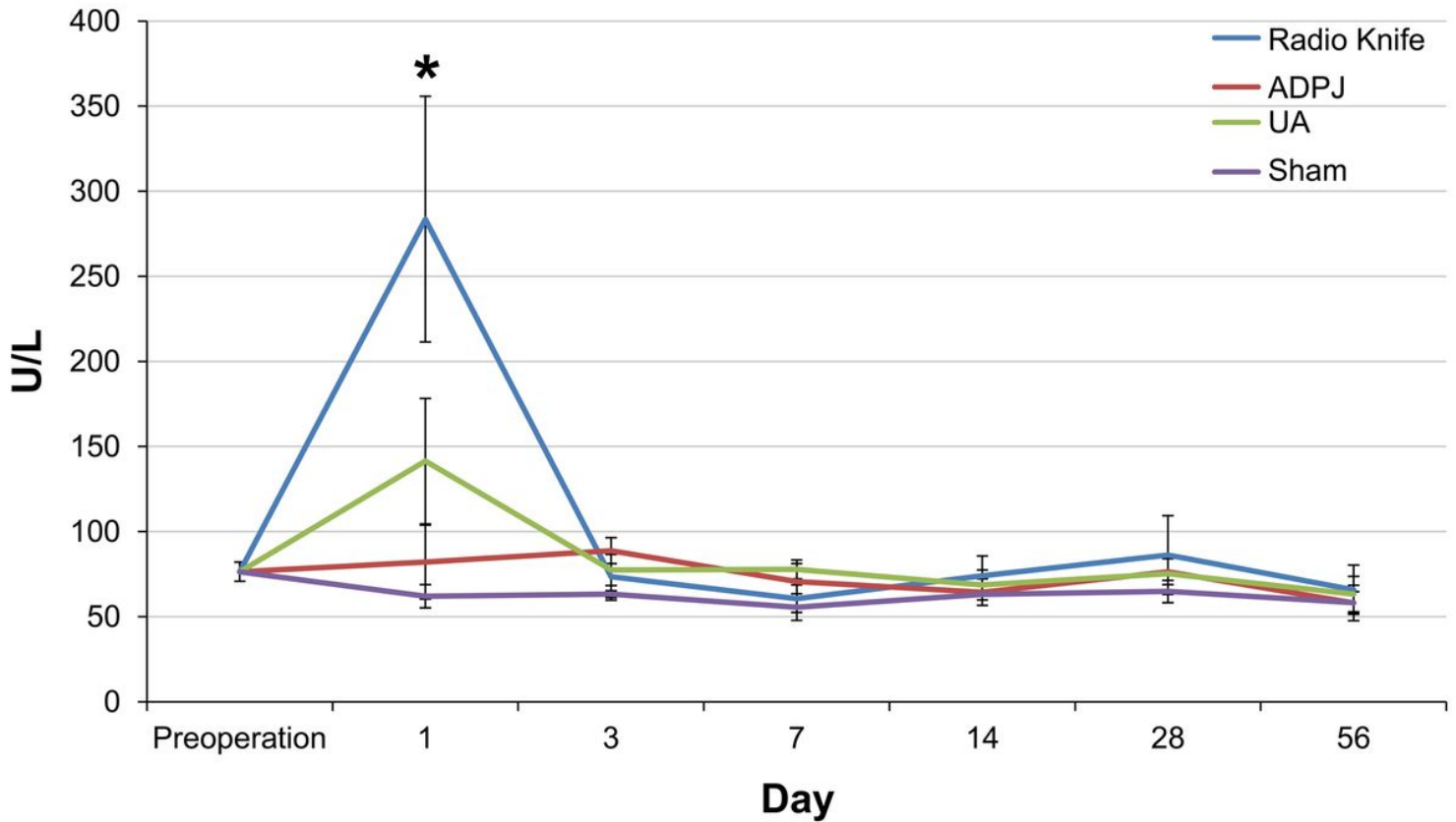
# AST



**Figure 2**

Changes in the serum aspartate aminotransferase (AST) levels. The serum AST levels on day 1 were significantly lower with the actuator-driven pulsed water jet (ADPJ) system than with an ultrasonic aspirator (UA) and radio knife (ADPJ vs. UA,  $*P < 0.05$ ; ADPJ vs. radio knife,  $*P < 0.01$ ). No differences were noted between the sham group and the ADPJ system group (AST,  $P = 0.082$ ).

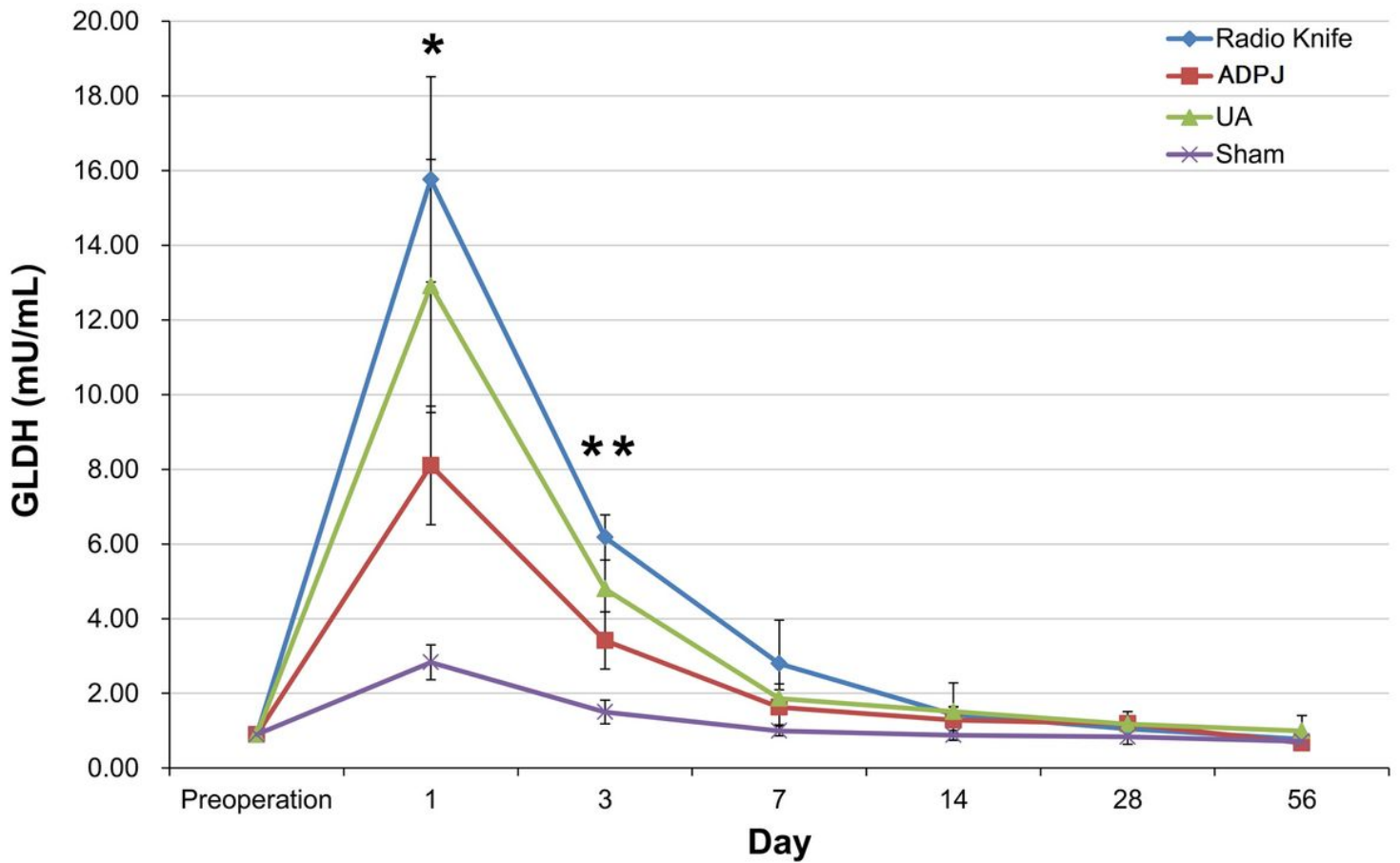
# ALT



**Figure 3**

Changes in the serum alanine aminotransferase (ALT) levels. The serum ALT levels on day 1 were significantly lower with the actuator-driven pulsed water jet (ADPJ) system than with an ultrasonic aspirator (UA) and radio knife (ADPJ vs. UA,  $*P < 0.05$ ; ADPJ vs. radio knife,  $*P < 0.01$ ). No differences were observed between the sham group and the ADPJ system group (ALT,  $P = 0.153$ ).

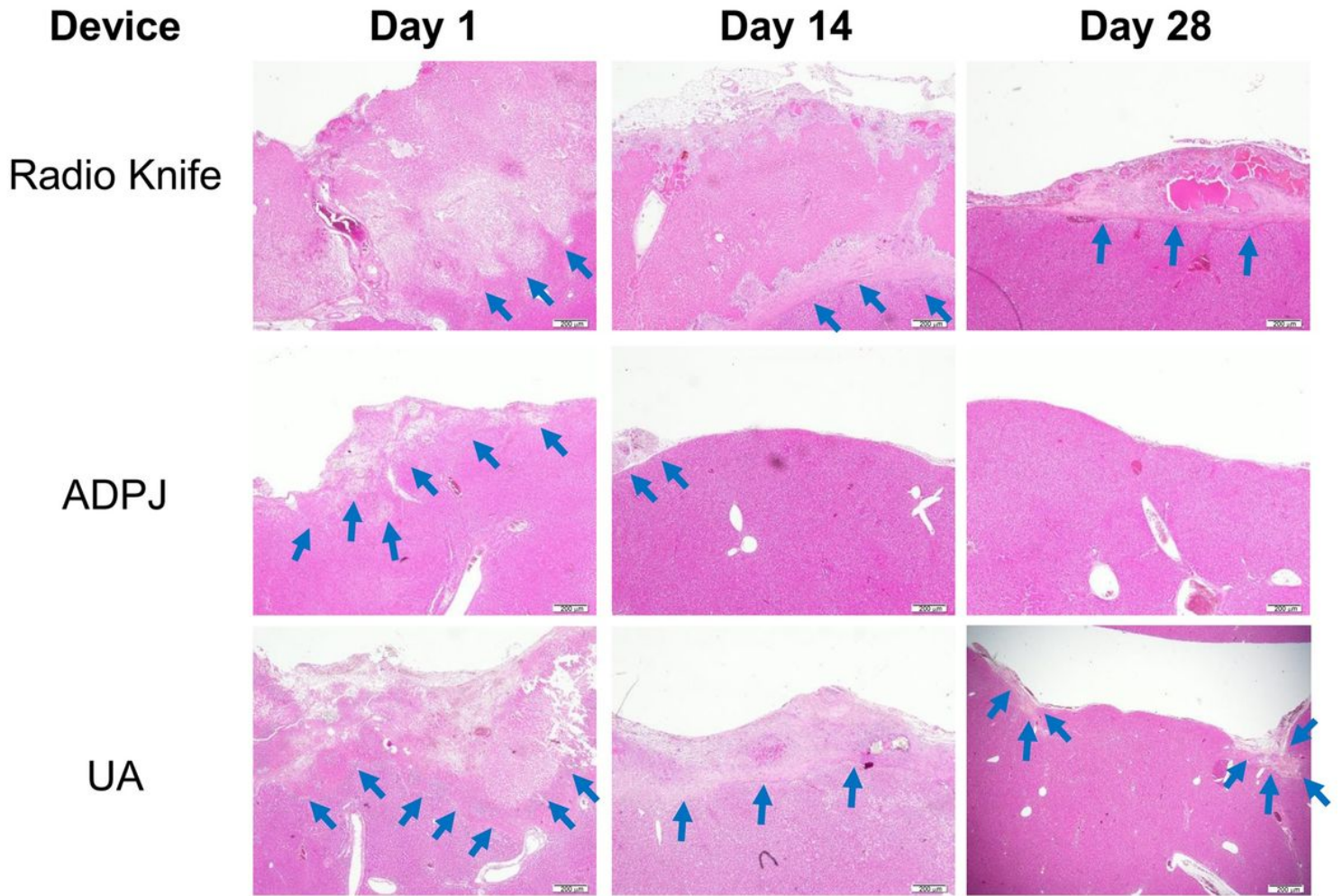
# GLDH



**Figure 4**

Changes in the serum glutamate dehydrogenase (GLDH) levels. The serum GLDH levels on day 1 were significantly lower with the actuator-driven pulsed water jet (ADPJ) system than with other devices (ADPJ vs. ultrasonic aspirator[UA], \* $P < 0.05$ ; ADPJ vs. radio knife, \* $P < 0.01$ ). On day 3, changes in the GLDH levels were high only in the radio knife group compared with the ADPJ system group (\*\* $P < 0.01$ ). Compared with the sham group, the ADPJ system group exhibited no significant difference from day 7, but the UA group displayed no difference from day 14 and the radio knife group from day 28.





**Figure 5**

Chronological changes in the resection surface (hematoxylin–eosin [HE]). The boundary between the area of degeneration and normal tissue is indicated by an arrow. The HE staining of the liver tissue dissected by the actuator-driven pulsed water jet (ADPJ) system exhibited marginal crush injury and degeneration on 1 day after liver resection; this change was almost not visible at 14 days after liver resection and completely disappeared on day 28. Contrarily, we observed broad necrosis below the resection surface in almost all livers coagulated by the radio knife, which persisted even after 28 days postoperatively. Although not as much as the radio knife group, degenerative parts persisted on day 28 in the ultrasonic aspirator (UA) group. Scale bar, 200  $\mu$ m.

## Maximum depth of degeneration

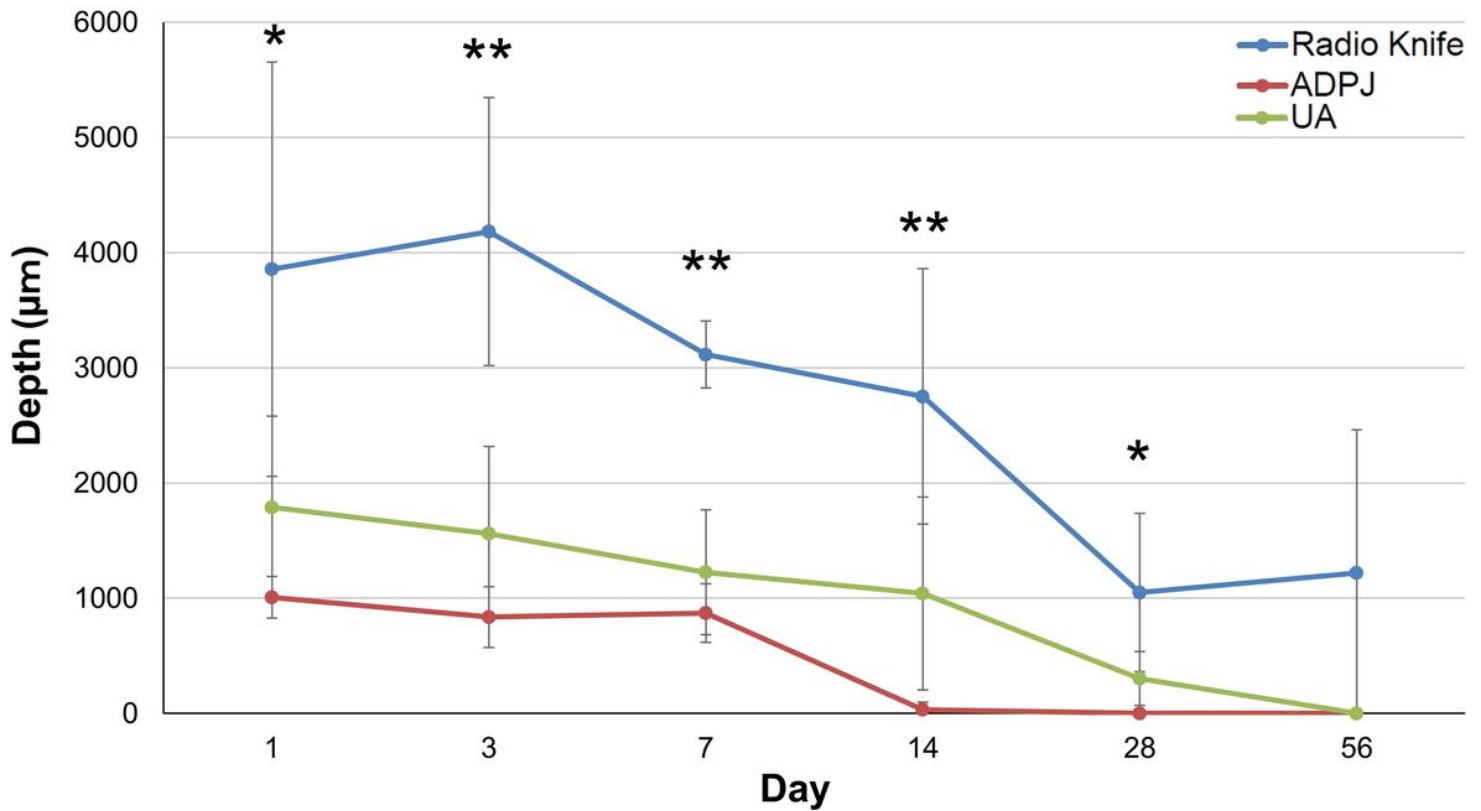
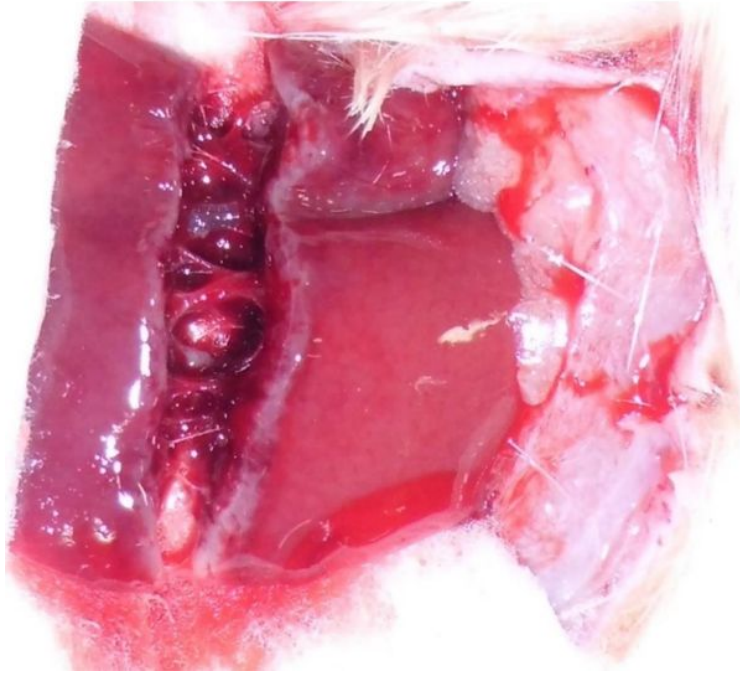
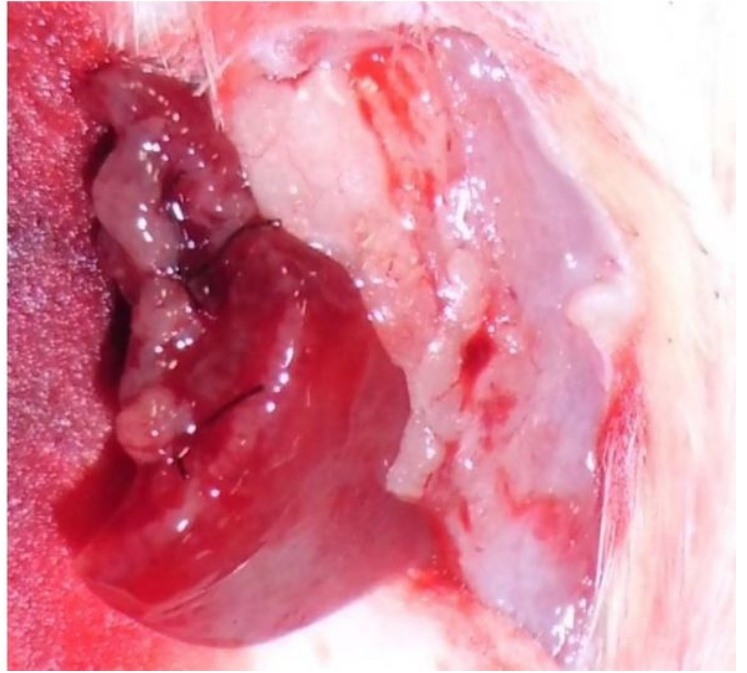


Figure 6

Maximum depth of degeneration. The maximum depth of degeneration from the resection surface in the actuator-driven pulsed water jet (ADPJ) system group was significantly milder than that in the radio knife group at 1,3,7,14, and 28 days (\* $P < 0.05$ ; \*\* $P < 0.01$ ). No significant difference was observed in the maximum depth of degeneration between the ADPJ system and ultrasonic aspirator (UA) groups.

**a****b**

**Figure 7**

Partial liver resection with the actuator-driven pulsed water jet (ADPJ) system. a The ADPJ system can resect the hepatic parenchyma while preserving the liver vessels. b The preserved liver vessels using the ADPJ system are ligated by a silk thread and cut.