

# Evaluation of the effects of Vitamin C on Epithelialization of Burn Wounds: A Randomized Clinical Trial

**Mohammd Haddadi**

Islamic Azad University of Tabas

**Elaheh Jaghouri**

Sabzevar University of Medical Sciences

**Davood Robot Sarpooshi**

Sabzevar University of Medical Sciences

**Fateme Ghobadi**

Sabzevar University of Medical Sciences

**Hamid Robot Sarpooshi** (✉ [Hamid.Robatsarpooshi@protonmail.com](mailto:Hamid.Robatsarpooshi@protonmail.com))

Sabzevar University of Medical Sciences

---

## Research note

**Keywords:** vitamin C, healing, epithelization, burn, wound

**DOI:** <https://doi.org/10.21203/rs.3.rs-28024/v2>

**License:**   This work is licensed under a Creative Commons Attribution 4.0 International License.

[Read Full License](#)

---

# Abstract

**Objectives** The purpose of this study is to determine the effect of topical vitamin C on second-degree burn wounds restoration. This was a clinical trial. The sample size was determined as 30. Participants were selected from patients suffering from second-degree burns who visited the Burn Center of Vaseei Hospital in Sabzevar. Both intervention and control groups targeted one patient. Dressing was changed in a daily manner after cleansing. A topical vitamin C solution was administered on the wounds. The Bates-Jensen Wound Assessment Tool was used to evaluate burn wound parameters in the 1<sup>st</sup>, 3<sup>rd</sup>, 7<sup>th</sup>, and 14<sup>th</sup> days of treatment. Data was analyzed using SPSS v.16 and "repeated measures ANOVA.

**Results** The average age of participants was  $43.33 \pm 11.9$  years and 60% of the participants were males and 40% of them were females. The results of repeated measures ANOVA showed a statistically significant difference in mean scores of the wound between the two treatments ( $P = 0.047$ ), wound healing significantly differed in the two groups and topical vitamin C solution had a significant effect on the acceleration of wound Epithelialization. The administration of topical vitamin C is recommended for epithelialization of second-degree burns.

## Introduction

Burn lesions are the third leading cause of unintentional injury deaths at all age groups and the second cause of trauma in children younger than 4 years of age. Approximately, two million people are given medical services for the treatment of burn injuries every year in the United States [1]. According to relevant statistics in Iran, eight people with an average age of 35.7 die because of burning Daily. Burn mortality rates in Iran are almost 3 times higher than in Eastern Mediterranean countries and 2 times higher than the global rate. Burn injuries lead to depression of immune potential, which may result in secondary infections [2,3].

Wounds are defined as a disruption of the normal structure and function of skin and underlying soft tissue. It is vital to maintain skin integrity, protect it against dehydration and bleeding, and prevent penetration of microorganisms into the skin. Skin wounds are caused by various physical, chemical, and biological factors and are divided into chronic and acute wounds according to type and duration of repair [4].

Nutritional deficiencies can have adverse effects on wound and trauma injury healing. In this regard, researchers who study tissue repair dynamics have shown that several nutritional factors (e.g. vitamins, minerals, and proteins) are effective in wound healing and repairing [5].

Topical antibiotics should be used to control infection at burned sites. Topical treatment helps to cleanse and close and open and dirty wounds. Three common topical antibiotics used to heal burns are silver sulfadiazine, silver nitrate, and Mafenide acetate. Silver with bactericidal and bacteriostatic activities has been used as an efficacious therapeutic agent for healing burn injuries over 50 years [6].

Epithelial tissue is an important and vital barrier to external factors. Damage to such a barrier can lead to loss of water and electrolytes as well as metabolic disturbances. Epithelial tissue has a great capacity for repair and restoration. This capability is dependent on the presence of epidermal stem cells in the basal layer and interfollicular epidermis. However, these cells are slow-cycling and have a longer cell cycle time than delay tissue repair. On the other hand, time is an important factor in extensive burns [7].

Vitamin C is a water-soluble micronutrient required for various biological functions and is essential for wound healing and resistance to infection. It is also a potent antioxidant effective in maintaining vascular integrity and tone [8.3].

Vitamin C infusion appears to be useful in the resuscitation of burn patients and minimizes fluid requirement. Oral Vitamin C is administered to burn patients younger than 13 years old (250-500mg/day) and older than 13 years old ( $\leq 1000$ mg/day) [9]. Topical vitamin C reduces inflammatory reactions. It can enhance the body resistance and immune system. [10].

Some studies on pigs have shown an increase in vitamin C levels in the skin by the administration of 10% vitamin C solution [11]. It is also acknowledged that different materials such as kiwi and jujube are effective in burn wound healing since they contain high levels of vitamin C (12.2) [12].

Silver sulfadiazine dressing may cause false scar since the dressing adheres firmly to the wound surface, has toxic effects on keratinocyte repair, and delays wound healing [13].

Many patients in the burn community have started using more high-dose vitamin C during complicated burn resuscitations[14]. The identification of the mechanisms regulating gene expression of oxidative stress markers, in the presence or absence of vitamin C, is important to understand the processes that influence the recovery of burn patients [3]. High-dose vitamin C therapy was associated with reduced in-hospital mortality in patients with severe burns under a minimum threshold of 10g within the first 2 days of admission [15].

Since a large body of evidence confirms the effects of oral vitamin C on the wound healing process and the effects of topical use of fruits containing vitamin C on burn wounds, the present study aimed to evaluate the effects of topical vitamin C solution on burn wound in second-degree burn patients.

## **Materials And Methods**

This clinical trial was conducted on 30 patients with second-degree burns (two or more organs/ extended limb burn) admitted in the burn unit. patients' wounds were divided randomly into two groups of intervention and control. Considering that multiple factors are involved in wound restoration and infection, this study was conducted on two parallel groups. This study was conducted on two symmetric body parts or an extended burn area in a patient using sulfadiazine ointment and combined sulfadiazine ointment and vitamin C, respectively. Upper-limb extended burn areas were treated with silver sulfadiazine, while lower-limb burn areas were treated with combined vitamin C and silver sulfadiazine. In

the initial examination and dressing, the patients were evaluated for the depth and amount of the wound surface (according to law nine). The participants were explained how to complete the consent form in case they consented to participate in the study. Before the study, the patients' wounds were evaluated based on the Bates-Jensen Wound Assessment Tool by an observer physician. In the control group, routine wound cleansing and debridement were performed with water and normal saline. The wound was dried with sterilized gas and dressed with 1% sulfadiazine ointment with 1.5mm thickness using sterile gloves. In the intervention group, routine cleansing and debridement were performed with water and normal saline. The wound was dried with sterilized gas and dressed with a 10% vitamin C solution. Vials containing 5cc vitamin C were used and sterile swabs were used to administer vitamin C on the wound surface (maximum area of 225cm was selected for each vial). Then, the wound was dressed with 1% silver sulfadiazine ointment with 1.5mm thickness using sterile gloves. Finally, the burned site was dressed with Vaseline gas and dry gas.

The maximum surface of the organ compared with the identical organ or the section of an organ compared with another section of that organ was equal to 20% and the minimum burned site at long surfaces was 6%. The depth of the burned site was compared. Wound healing rates were compared on 1<sup>st</sup>, 3<sup>rd</sup>, 7<sup>th</sup> and 14<sup>th</sup> day of treatment using a checklist administered by an observer physician.

## **Instrument**

Research instruments were a demographic questionnaire, Bates-Jensen Wound Assessment Tool, and a measuring tape. The wound assessment tool contained 15 items. Burned site and shape were not categorized but the other 13 items were scored based on a five-point Likert scale. The range of scores was between one and five. The lowest score (1) indicates the best healing rate and the highest score (6) indicates the worst healing rate.

The Bates-Jensen Wound Assessment Tool assesses wound size, depth, edges, undermining, necrotic tissue type, amount of necrotic, granulation and epithelialization tissue, exudate type and amount, surrounding skin color, edema, and induration. The wound healing process was evaluated according to obtained scores.

The scientific credibility of the Bates-Jensen Wound Assessment Tool was reviewed and confirmed by Harris *et al.* in 2010 [16]. Malek Hosseini *et al.* carried out a study in Arrack in 2010 and 2011 to determine the scientific validity of the instrument in Iran and measured the content validity of the instrument [13]. The content validity index was calculated as 89% in the former study.

Malek Hosseini *et al.* determined the scientific reliability of the instrument by studying 10 burn patients. The participants were observed separately by the researcher and his trained colleague as the subjects completed the Bates-Jensen Wound Assessment Tool. The correlation coefficient was calculated. Hosseini's study measured the reliability of the instrument and the Kappa coefficient for each item and confirmed the reliability of the instrument.

To determine the scientific credibility of the research instrument, 10 patients were selected and their wounds were separately examined by the physician and the researcher. The agreement coefficient was obtained as 95%.

## **Statistical Analysis**

The collected data was encoded and entered into the software. The data was monitored and the accuracy of saved data was confirmed. Data analysis was performed using SPSS v.16. Repeated measures ANOVA was used for data analysis.

## **Ethics**

This study was approved by the Graduate Council of Sabzevar College of Nursing and Midwifery with the code of IR.MEDSAB.REC.1394.60 and IRCT registration number of IRCT2015101224487N1. The researcher was given an introduction letter presented to the authorities of Vaseei Hospital and the Burn Center.

## **Results**

Repeated measures ANOVA was used to determine the effects of the topical vitamin C solution on the epithelization of second-degree burn wounds.

The results of repeated measures ANOVA showed that the mean score of epithelialization between two treatments was statistically significant ( $P = 0.047$ ). The healing rate significantly differed in the two groups and topical vitamin C had a significant effect on epithelialization of the wound (Table 1).

Regarding the intragroup effects, the effect of time on the mean score of epithelialization was statistically significant, and the mean score of epithelialization was significantly different on the 1<sup>st</sup>, 3<sup>rd</sup>, 7<sup>th</sup>, and 14<sup>th</sup> days of treatment ( $P = 0.000$ ,  $F = 141.324$ ). Different days or time was effective in tissue granulation.

The interactive effect of dressing type and time was studied. The results of repeated measures ANOVA showed that the epithelization score was significant in the two intervention and control groups on the 1<sup>st</sup>, 3<sup>rd</sup>, 7<sup>th</sup> and 14<sup>th</sup> day of treatment ( $P = 0.005$ ,  $F = 7.534$ ). Epithelization score was statistically significant in different days in both groups.

Partial Eta Squared explained changes in wound healing in this study. This index explained 70.9% of the time, 9% of the interactive effect of dressing type and time, and 6.7% of vitamin C of changes in wound healing.

**Table 1:** Comparison of the mean score of epithelialization (Based on the Likert scale) in intervention and control groups after dressing

Group		Intervention		Control	
Statistics		Mean	Standard deviation	Mean	Standard deviation
Epithelization score	1 <sup>st</sup> day	5.00	0.00	5.00	0.00
	3 <sup>rd</sup> day	4.76	0.67	4.76	0.62
	7 <sup>th</sup> day	3.70	1.11	4.23	1.00
	14 <sup>th</sup> day	2.40	1.10	3.20	1.18
Effect of time (intragroup effect)		F = 141.324	df = 1.936	P < 0.001	
Interactive effect dressing and time		F = 4.133	df = 1	P = 0.047	

### Bonferroni test

There was a significant difference in the mean score of epithelialization in different days in pairs comparison. The difference between the scores was significant except between the first and the third days. The mean score of epithelization increased from the first day to the fourteen-day. Burn wound was healed during the studied time (Table 2).

**Table 2:** Two-by-two comparison of mean scores of epithelization in studied days

Two-by-two comparison in studied days		Difference between means	Standard error	Significance level
<b>1</b>				
<b>1</b>	3	0.233	0.0840	0.080
	7	1.033	0.1370	<0.001
	14	2.200	0.1480	<0.001
<b>3</b>	1	-0.233	0.0840	0.008
	7	0.800	0.0980	<0.001
	14	1.967	0.1340	<0.001
<b>7</b>	1	-1.033	0.1370	<0.001
	3	-0.800	0.0980	<0.001
	14	1.167	0.0920	<0.001
<b>14</b>	1	-2.200	0.1480	<0.001
	3	-1.967	0.1340	<0.001
	7	-1.167	0.0920	<0.001

Figure 1 was drawn to determine the effects of topical vitamin C solution on the epithelization of second-degree burn wounds. The mean score of epithelization in both intervention and control groups was identical on the 1<sup>st</sup> and 3<sup>rd</sup> days of treatment but the slope of the graph increased on the 3<sup>rd</sup> day in the intervention group and peaked on the 14<sup>th</sup> day. This shows that topical vitamin C solution had a greater effect on the epithelization of the wound in the intervention group compared to control.

## Discussion

The study aimed to determine the effects of topical vitamin C solution on the epithelium of second-degree burn wounds. The rate of epithelization was significantly different in the two groups, vitamin C had a significant effect on epithelialization, and time was also effective in wound healing. The mean epithelization score increased on the third day and decreased from 3.20 in control to 2.40 in the

intervention group on the 14th day. Abbaspour and Khaksari studied the effect of kiwi on epithelialization of burned scars in mice. The results of the former study were consistent with the results of this study [2].

Lima *et al.* studied the effect of Vitamin C in healing skin scars in mice. They detected fewer symptoms of inflammation, more granulation tissues, a lower number of macrophages, and new vessels in the intervention group compared to control [17]. Wiesner and Gold studied the treatment of bedsore and chronic wounds with topical vitamin C and showed that vitamin C solution helps the formation of new tissues and abundant granulation tissues in patients with bedsore [18]. These results are consistent with the results of this study.

## **Conclusion**

This study showed that topical vitamin C solution can accelerate epithelialization and repairing of burn wounds.

## **LIMITATIONS**

Intervention and control groups were restricted to a certain patient and investigations were carried out on 30 samples collected from this patient. It is recommended to collect more samples with identical conditions in future studies. Although the effect of many intervening variables was eliminated by combining intervention and control, this combination is a significant advantage of this study.

## **Abbreviations**

**ANOVA:** Analysis of variance

**SPSS:** Statistical Package for the Social Sciences

## **Declarations**

### **Availability of data and materials**

Data were available upon request.

### **Acknowledgment**

We appreciate the help of the authorities of Sabzevar College of Nursing and Midwifery. We are also grateful to nurses and good personnel of the Burn Center of Vasei Hospital in Sabzevar, the patients and their families who helped us to carry out this project.

### **Funding**

There is no funding for the present study.



## Authors' Contributions

Study design and concept: MH and HRS, Ligature review: EH and DRS; performing the study: MH, HRS, and EJ; drafting: DRS. All authors approved the study.

## Ethics approval and consent to participate

This study was approved by the Graduate Council of Sabzevar College of Nursing and Midwifery with the ethics code of IR.MEDSAB.REC.1394.60. Patients signed written consent.

## Consent for publication

Not applicable.

## Competing interests

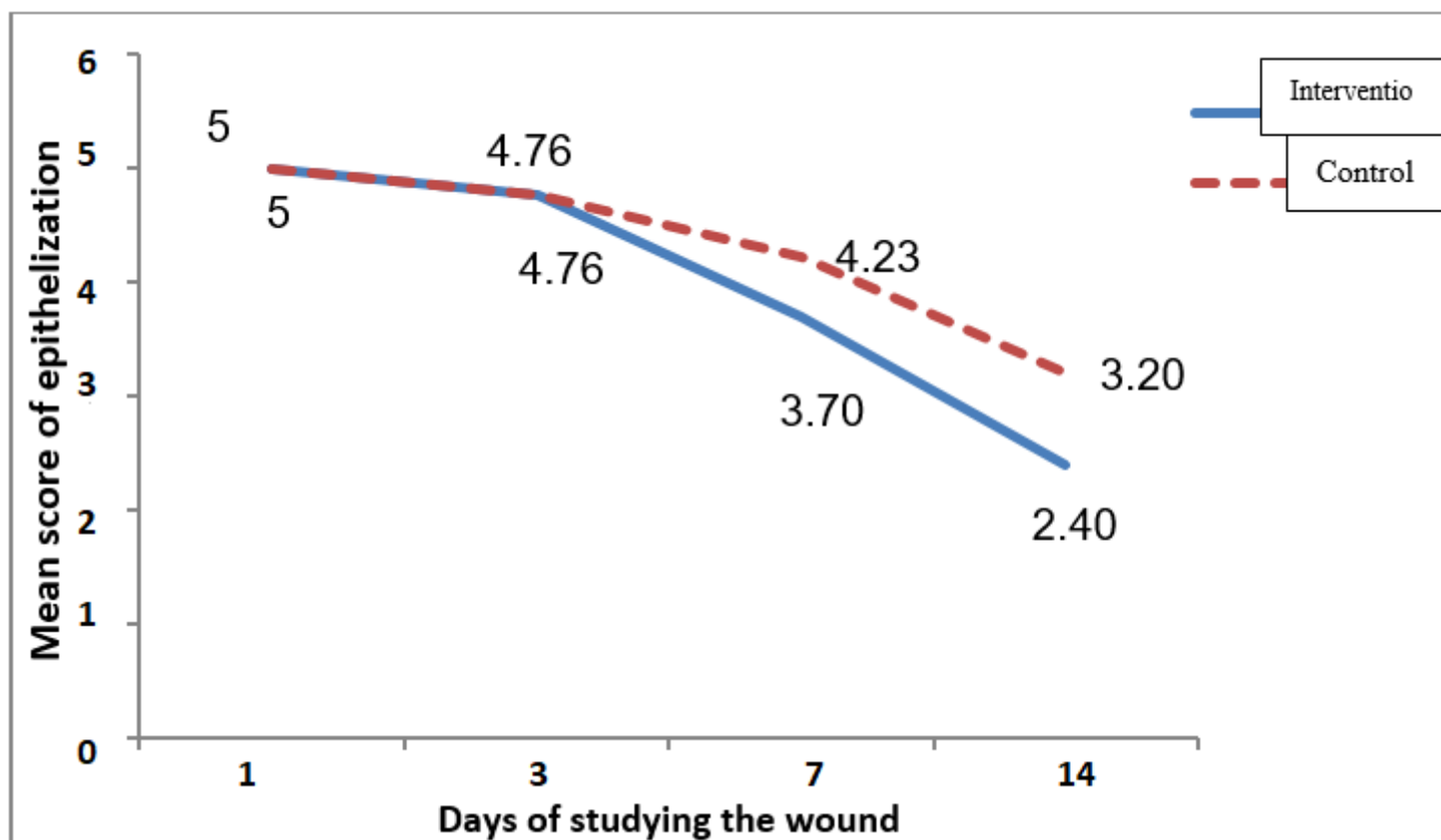
The authors declare that they have no competing interests.

## References

1. Darvishpour A, Lotfi M, Salehi F, Aghazadeh A, Hasani A, Ali N. Comparing Dressing With Silver Sulfadiazine and Nitrofurazone to the Pediatric Ward in Tabriz. *J of Guilan Univer of Med Science* 2006;15(60):42-6.
2. Abbaspour H, Khaksari M. Topical effectiveness of Kiwifruit on burn wound healing in male rats. 2013.
3. Bonucci J, Gragnani A, Trincado MM, Vincentin V, Correa SAA, Ferreira LM. The role of vitamin C in the gene expression of oxidative stress markers in fibroblasts from burn patients. *Acta Cir Bras*. 2018;33(8):703-712.
4. Jaffary F, Nilforoushzadeh MA, Sharifian H, Mollabashi Z. Wound healing in animal models. *Tehran University Medical Journal TUMS Publications* 2017;75(7):471-9.
5. Mahdavi-Shahri N, Baharara J, Tavassoli A, Rasti H, Shahabipour F, Saghiri N. Effect of All-Trans Retinoic Acid on Epithelialization of Blastema Tissue in vitro. *Journal of Rafsanjan University of Medical Sciences* 2012;11(5):471-80.
6. Smeltzer SC, Bare BG. *Brunner & Suddarth's textbook of medical-surgical nursing*: JB Lippincott Philadelphia; 1992.
7. Safari M, Ghahari L, Khoushvaghti A, Nasiri E. *Ulcert Repair by Spray of Epithelial Stem Cells*. 2008.
8. Abgoon M. *Iranian generic drugs*. 3rd ed. Tehran: Noore Danesh; 2000.
9. Herndon DN. *Total burn care*: Elsevier Health Sciences; 2007.
10. Lqbal K, Khan A, Khattak A. Biological Significance Ascorbic Acid (Vitamin C) in Human Health. *Pak J Nutr*. 2004;3(1):5-13
11. Draelos ZD. Nutrition and enhancing youthful-appearing skin. *Clin Dermatol*. 2010;28(4):400-8.

12. Ashrafi K, Esmaeli E, Shahinfard N, Ansari R, Parvin N, Namjoo A. The effect of hydroalcoholic extracts of *Zizipus vulgaris* L. on burn healing. *J Shahrekord Univ Med Sci* 2011; 12 (4): 78-82. Persian.
13. Ghaffar zadegan R, Alizadeh SA, Ghaffar zadegan R, Haji Ageai R, Ahmadlou M. Effect of aloe vera gel, compared to 1% silver sulfadiazine cream on second-degree burn wound healing. *Complementary Medicine Journal of faculty of Nursing & Midwifery* 2013;3(1):418-28.
14. Buehner M, Pamplin J, Studer L, Hughes RL, King BT, Graybill JC, et al. Oxalate Nephropathy After Continuous Infusion of High-Dose Vitamin C as an Adjunct to Burn Resuscitation. *Journal of Burn care & Research* Volume 37, Number 4; e379.
15. Nakajima M, Kojiro M, Aso S, Matsui H, Fushimi K, Kaita Y, et al. Effect of high-dose vitamin C therapy on severe burn patients: a nationwide cohort study. *Critical Care*(2019) 23:407.
16. Harris C, Bates-Jensen B, Parslow N, Raizman R, Singh M, Ketchen R. Bates-Jensen wound assessment tool: pictorial guide validation project. *J Wound Ostomy Continence Nurs* 2010;37(3):253-9.  
<http://dx.doi.org/10.1097/WON.0b013e3181d73aab>  
[www.ncbi.nlm.nih.gov/pubmed/20386331](http://www.ncbi.nlm.nih.gov/pubmed/20386331)
17. Lima C, Pereira A, Silva J, Oliveira L, Resck M, Grechi C, et al. Ascorbic acid for the healing of skin wounds in rats. *Brazilian Journal of Biology* 2009;69(4):1195-201.
18. Mester A. Treatment of bedsores and chronic ulcers with topical ascorbic acid. *Lancet* 1961;1:343-4.

## Figures



## Figure 1

Comparison of mean scores of epithelialization

## Supplementary Files

This is a list of supplementary files associated with this preprint. Click to download.

- [FigureS1.docx](#)
- [Supplement1.pdf](#)