

# Clinical Outcomes Following Total Ankle Arthroplasty without Concomitant Osteotomy in Ankles with Severe Preoperative Varus Deformity: Comparison to Ankles with Preoperative Neutral Alignment

**Takahiro Yamashita**

Department of Orthopaedic Surgery, Kobe University Graduate School of Medicine  
<https://orcid.org/0000-0002-4987-0440>

**Kanto Nagai**

Department of Orthopaedic Surgery, Kobe University Graduate School of Medicine

**Noriyuki Kanzaki** (✉ [kanzaki@med.kobe-u.ac.jp](mailto:kanzaki@med.kobe-u.ac.jp))

**Tetsuya Yamamoto**

Department of Orthopaedic Surgery, Kobe University Graduate School of Medicine

**Kazuyuki Ibaraki**

Department of Orthopaedic Surgery, Kobe University Graduate School of Medicine

**Daisuke Araki**

Department of Orthopaedic Surgery, Kobe University Graduate School of Medicine

**Yuichi Hoshino**

Department of Orthopaedic Surgery, Kobe University Graduate School of Medicine

**Takehiko Matsushita**

Department of Orthopaedic Surgery, Kobe University Graduate School of Medicine

**Ryosuke Kuroda**

Department of Orthopaedic Surgery, Kobe University Graduate School of Medicine

---

## Research

**Keywords:** Total ankle arthroplasty, varus deformity, outcomes, TNK ankle, osteoarthritis, rheumatoid arthritis

**Posted Date:** May 14th, 2020

**DOI:** <https://doi.org/10.21203/rs.3.rs-27974/v1>

**License:**  This work is licensed under a Creative Commons Attribution 4.0 International License.

[Read Full License](#)

---

# Abstract

**Background:** It remains controversial whether satisfactory outcomes can be obtained following total ankle arthroplasty (TAA) without osteotomy in patients with severe varus ankle deformities. The purpose of this study was to examine outcomes following TAA without concomitant osteotomies in patients with severe varus ankle alignment by comparing them with patients with neutral alignment.

**Methods:** Fifty-three ankles of 51 patients ( $71.4 \pm 5.6$  years old) who underwent TAA using an insert with a medial wall (TNK ankle prosthesis) were examined (mean follow-up:  $36.8 \pm 17.8$  months). The patients were allocated into two groups according to the preoperative talar tilt (TT) angle: the neutral group (preoperative TT angle  $< 9^\circ$ ;  $n=37$ ) and the varus group (preoperative TT angle  $> 10^\circ$ ;  $n=16$ ). Outcome measures, including the Japanese Society for Surgery of the Foot (JSSF) scale, Self-Administered Foot Evaluation Questionnaire (SAFE-Q), the ankle range of motion, and radiographic parameters, were assessed prior to the surgery and at the final follow-up.

**Results:** Significant improvements were observed in clinical and radiographical outcomes in both groups after surgery. The postoperative JSSF scale and the subscale scores of pain and shoes in the SAFE-Q were not significantly different between the groups, while subscale scores of function, social, and health in the SAFE-Q were greater in the varus group compared to the neutral group at the final follow-up ( $P < 0.05$ ). Radiographic parameters, including TT angle and tibial axis-medial malleolus (TMM) angle improved postoperatively and were not significantly different between the neutral group (TT angle,  $0.5 \pm 0.7^\circ$ ; TMM angle,  $16.0 \pm 4.6^\circ$ ) and the varus group (TT angle,  $0.4 \pm 0.7^\circ$ ; TMM angle,  $17.0 \pm 5.3^\circ$ ) at the final follow-up. To achieve neutral alignment, adjunctive procedures, such as deltoid ligament release, were required more often in the varus group, but no concomitant osteotomies were performed.

**Conclusions:** Outcomes after TAA using the TNK ankle prosthesis were favorable in patients with severe varus ankle alignment and in those with neutral ankle alignment without concomitant osteotomy. Satisfactory outcomes could be achieved in patients with severe varus ankle alignment after TAA using the TNK ankle prosthesis without concomitant osteotomy.

## Background

Modern total ankle arthroplasty (TAA) has been shown to have satisfactory outcomes with better function and equivalent pain relief compared to ankle arthrodesis in patients with ankle osteoarthritis (OA) or rheumatoid arthritis (RA) (1–4). This could be attributable to many factors, including improvement of prosthetic design, development of surgical technique, achievement of soft tissue balancing, careful patient selection, and severity of preoperative deformity (5, 6). However, experts are yet to arrive at a consensus on whether preoperative coronal deformity is associated with postoperative poor outcomes. Some authors reported that preoperative coronal malalignment was associated with poor outcomes (7, 8) and others reported no association between preoperative coronal varus deformity and

postoperative clinical outcomes (2, 9–12). As a limitation, most previous studies performed simultaneous osteotomy at the time of TAA for ankles with severe varus coronal deformity.

The TNK ankle prosthesis, which was originally developed by Takakura et al. (13), has a medial wall in its tibial insert (Fig. 1). This shape of the tibial insert is unique and this may stabilize the medial part of the ankle more than other prostheses; however, to date, only a few studies have reported the clinical outcomes following TAA using the TNK ankle prosthesis (13–15). Thus, it remains unclear whether preoperative coronal varus malalignment is associated with postoperative poor outcomes following TAA using the TNK ankle prosthesis. Therefore, the purpose of the present study was to investigate the postoperative outcomes following TAA using the TNK ankle prosthesis, and to compare the outcomes between a neutral group (preoperative coronal alignment  $< 9^\circ$ ) and a varus group (preoperative coronal alignment  $> 10^\circ$ ). It was hypothesized that both groups would show significant improvement following TAA, and that the neutral group would have better clinical outcomes than the varus group.

## Methods

The present study was a retrospective analysis of prospectively collected data of TAA performed in our institution. Fifty-three arthritis ankles of 51 patients (age at the surgery:  $71.4 \pm 5.6$  years; 16 males, 35 females) who underwent TAA were included in this study. The average follow-up period after the surgery was  $36.8 \pm 17.8$  months. This analysis included 48 ankles with osteoarthritis and 5 ankles with rheumatoid arthritis. Inclusion criteria were patients who underwent TAA from May 2012 to November 2018 by a single surgeon. Exclusion criteria were patients who received less than 1-year follow-up after the surgery.

The study was conducted in accordance with the Declaration of Helsinki and the Guidelines for Good Clinical Practice. The institutional review board approved this study (No.180053), and informed consent was obtained from all the patients. The ankles were allocated into two groups according to the preoperative talar tilt (TT) angle ( $^\circ$ ) (16): the control group ( $< 9^\circ$ ; 37 ankles) and the varus group ( $> 10^\circ$ ; 16 ankles). The demographic data of the two groups are shown in Table 1. Two patients underwent bilateral TAA at different times. One patient had neutral alignment in both sides of the ankles, and one patient had varus alignment of  $> 10^\circ$  in both sides. These 4 ankles were allocated to the control and varus groups accordingly and were evaluated independently.

Table 1  
Demographic data

	Neutral Group	Varus Group	P value
Patients	37	16	
Sex (M/F)	12/25	5/11	0.98
Age at surgery (years)	71.7 ± 4.5	70.7 ± 7.6	0.39
Follow-up (months)	40.0 ± 18.7	29.1 ± 12.3	0.04*
Preoperative diagnosis (OA/RA)	33/4	15/1	0.63
Preoperative talar tilt angle (°)	2.6 ± 3.6	13.9 ± 8.7	< 0.001*
Takakura OA classification (20,22)			
Stage 3a	4	0	
Stage 3b	13	15	
Stage 4	16	0	
OA: osteoarthritis, RA: rheumatoid arthritis			

## Surgical procedure

The third-generation TNK ankle prosthesis (Kyocera medical, Kyoto, Japan) was used for all patients. The TNK ankle was originally developed by Takakura et al (13, 14). The third-generation TNK ankle is made of alumina–ceramic and comprises tibial and talar components with a polyethylene insert, which has a medial wall (Fig. 1). This insert is attached to the tibial component; thus, the TNK ankle is so-called a “2-component type.”

All procedures were performed through an anterior approach between the extensor hallucis longus and tibialis anterior tendon to the ankle joint. Capsulectomy was performed and all osteophytes were removed piece by piece. In cases where the inner tightness was marked at the medial part of the ankle, the deep layer of the deltoid ligament was dissected and elongation of the superficial layer was performed. Thereafter, tibial cutting was performed based on the preoperative planning, following talar cutting. The talar component was fixed with cement, and the tibial component was fixed with a small cancellous screw (DePuy Synthes, West Chester, PA, USA). Small beads of cement were initially placed on the surface of the tibial component facing the tibia and bone marrow was placed on its surface after the application of a calcium phosphate paste to induce osseous bonding (HOYA, Tokyo, Japan). Simultaneous concomitant procedures during TAA were documented.

## Postoperative rehabilitation

The same postoperative rehabilitation protocol was utilized in both groups. The short leg splint was applied and weight-bearing was not permitted for the first 2 weeks after the surgery. Range of motion (ROM) exercises started 3 days after the surgery only during physical therapy. From 2 weeks after the surgery, a soft brace with a stay was applied, and full weight-bearing was allowed. ROM exercises were performed without limitations 2 weeks after the surgery. The stay of the brace was removed 6 weeks after the surgery and the brace was applied without the stay until 3 months after the surgery.

## Clinical outcomes

The Japanese Society for Surgery of the Foot (JSSF) ankle–hindfoot scale (17, 18) was used for objective evaluation, and the Self-Administered Foot Evaluation Questionnaire (SAFE-Q) (19) were used for subjective assessment prior to surgery and at the final follow-up. The dorsi-flexion and plantar-flexion angles of the ankle were measured using a goniometer prior to the surgery and at the final follow-up. Concomitant procedures and complications related to the surgery were documented.

## Radiographic evaluation

Prior to the surgery and at the final follow-up, the tibial anterior surface (TAS) angle, the tibial axis-medial malleolus (TMM) angle, the TT angle, and the tibial lateral surface (TLS) angle were measured using plain radiographs of the ankle under weight-bearing condition, as previously described (20).

## Statistical analysis

All measurements were expressed as mean  $\pm$  standard deviation (SD). Data analyses were performed using Excel Statistics version 7 (ESUMI Co., Ltd, Tokyo, Japan). A paired *t* test was performed to explore pre- and postoperative differences in clinical scores and radiographic parameters in each group. Mann–Whitney U test was performed to explore the differences in clinical scores and radiographic parameters between the neutral group and the varus group. Chi-square test was used to explore the differences in concomitant procedures and complications between the groups. Significance level was set as  $P < 0.05$ .

A prior power analysis showed that at least 31 cases and 15 cases were required to determine significant difference between two independent means with two-tails, an effect size of 0.9, a power of 0.80, and an alpha error of 0.5.

## Results

Postoperative JSSF and SAFE-Q scores were significantly greater than the preoperative scores in each group (Table 2, 3). In terms of the JSSF scale, there were no significant differences between the groups, except in preoperative alignment (Table 2). Regarding the SAFE-Q, there were no significant differences in subscale scores of pain, shoes, and preoperative health between the groups, while subscale scores of function, social, and postoperative health were greater in the varus group than in the neutral group (Table 3). No significant differences were noted in the improvement of these subscales between the groups.

Table 2  
Results of the Japanese Society for Surgery of the Foot  
(JSSF) ankle-hindfoot scale

	Neutral group	Varus group	P value
<b>Total</b>			
Preoperative	52.3 (13.8)	56.9 (5.5)	0.38
Last follow-up	88.7 (10.3)	94.3 (7.1)	0.07
P value	< 0.001*	< 0.001*	
<b>Pain</b>			
Preoperative	15.0 (9.1)	20.0 (0.0)	0.07
Last follow-up	33.4 (6.6)	36.3 (6.0)	0.13
P value	< 0.001*	< 0.001*	
<b>Function</b>			
Preoperative	30.5 (8.4)	31.9 (6.1)	0.57
Last follow-up	45.4 (6.4)	48.1 (3.2)	0.11
P value	< 0.001*	< 0.001*	
<b>Alignment</b>			
Preoperative	7.0 (3.4)	5.0 (1.9)	0.025*
Last follow-up	9.9 (0.8)	10.0 (0.0)	0.52
P value	< 0.001*	< 0.001*	
Values indicate mean (SD). *Significant difference.			

Table 3  
Results of the Self-Administered Foot Evaluation  
Questionnaire (SAFE-Q)

	Neutral group	Varus group	P value
<b>Pain</b>			
Preoperative	39.0 (17.5)	36.3 (19.1)	0.74
Last follow-up	75.7 (17.7)	82.3 (12.6)	0.17
P value	< 0.001*	< 0.001*	
<b>Function</b>			
Preoperative	36.0 (20.0)	46.8 (17.0)	0.023*
Last follow-up	69.5 (19.6)	79.1 (16.9)	0.049*
P value	< 0.001*	< 0.001*	
<b>Social</b>			
Preoperative	34.9 (29.0)	51.1 (30.1)	0.041*
Last follow-up	72.7 (30.0)	91.9 (13.4)	0.008*
P value	< 0.001*	< 0.001*	
<b>Shoes</b>			
Preoperative	47.8 (27.1)	41.7 (24.1)	0.91
Last follow-up	74.1 (20.8)	81.3 (18.3)	0.26
P value	< 0.001*	< 0.001*	
<b>Health</b>			
Preoperative	39.6 (24.6)	44.0 (21.1)	0.42
Last follow-up	74.1 (22.5)	90.1 (9.1)	0.01*
P value	< 0.001*	< 0.001*	
Values indicate mean (SD). *Significant difference.			

Regarding the ROM of the ankle, there were no significant differences in dorsal and plantar flexions between the groups pre- vs postoperatively (Table 4) Concerning the radiographic parameters, there were no significant differences between the groups at the final follow-up (Table 5).



Table 4  
Results of the ankle range of motion

	Neutral group	Varus group	P value
<b>Dorsiflexion (°)</b>			
Preoperative	9.6 (6.2)	9.4 (5.6)	0.98
Last follow-up	12.8 (5.1)	12.1 (4.7)	0.73
P value	< 0.001*	0.06	
<b>Plantarflexion (°)</b>			
Preoperative	33.9 (11.6)	28.1 (9.5)	0.07
Last follow-up	37.4 (11.8)	33.8 (8.0)	0.32
P value	0.09	0.10	
Values indicate mean (SD). *Significant difference.			

Table 5  
Results of the radiographic parameters

	Neutral group	Varus group	P value
<b>Tibial anterior surface (TAS) angle (°)</b>			
Preoperative	84.4 (3.7)	85.1 (4.0)	0.50
Last follow-up	88.8 (2.7)	88.4 (2.7)	0.93
P value	< 0.001*	0.022*	
<b>Tibial axis-medial malleolus (TMM) angle (°)</b>			
Preoperative	37.8 (10.2)	45.2 (12.2)	0.036*
Last follow-up	16.0 (4.6)	17.0 (5.3)	0.53
P value	< 0.001*	< 0.001*	
<b>Talar tilt (TT) angle (°)</b>			
Preoperative	2.6 (3.6)	13.9 (8.7)	< 0.001*
Last follow-up	0.5 (0.7)	0.4 (0.7)	0.28
P value	0.0019*	< 0.001*	
<b>Tibial lateral surface (TLS) angle (°)</b>			
Preoperative	79.0 (6.1)	78.9 (4.7)	0.85
Last follow-up	80.6 (6.8)	81.2 (6.5)	0.68
P value	0.13	0.27	
Values indicate mean (SD). *Significant difference.			

Concomitant procedures during TAA are shown in Table 6, and deltoid ligament release was more often performed in the varus group than in the neutral group. Complications are summarized in Table 7; no significant differences in the rate of complications were observed between the groups. Moderate talar component subsidence occurred in two ankles in each group, and total talar replacement was performed in those cases using total talar prostheses.

Table 6  
The number of concomitant procedures during the total ankle arthroplasty

Procedure	Neutral group	Varus group	P value*
Tendon transfer of flexor digitorum longus	2 (5.4%)	0 (0%)	0.34
Gastrocnemius fascia resection	3 (8.1%)	3 (18.8%)	0.26
Deltoid ligament release	3 (8.1%)	7 (43.8%)	0.023*

Table 7  
The summary of the complications following the surgery

Complications	Neutral group	Varus group	P value
Deep infection	1 (2.7%)	0 (0%)	0.51
Medial malleolus fracture	2 (5.4%)	2 (12.5%)	0.37
Lateral malleolus fracture	0 (0%)	1 (6.3%)	0.12
Talus fracture	1 (2.7%)	0 (0%)	0.51
Talar component subsidence	2 (5.4%)	2 (12.5%)	0.37
Delayed wound healing	5 (13.5%)	2 (12.5%)	0.92

## Discussion

The main findings of the present study were 1) significant improvements in clinical outcomes and radiographic outcomes occurred in each group following TAA using the TNK ankle prosthesis and 2) the outcomes in the varus group were similar to those of the neutral group. These findings suggest that the postoperative outcomes following TAA were favorable even in the patients who had preoperative varus coronal malalignment greater than 10°. Importantly, neutral coronal alignment was achieved only by performing soft tissue balancing without osteotomies even in the varus group. The tibial insert of the TNK ankle prosthesis has a medial wall and this could stabilize the mortise. Therefore, it could be assumed that the satisfactory outcomes with the TNK ankle prosthesis are partially attributable to this prosthetic design and proper soft tissue balancing. Thus, TAA using the TNK ankle prosthesis can be indicated for ankles with varus coronal malalignment.

Previous studies have shown that preoperative coronal malalignment is considered a risk factor for early prosthetic failure (6–8). Therefore, it is considered essential to establish a neutrally aligned ankle after TAA for successful long-term outcomes and to prevent complications (4, 11, 21). Recently, several studies have shown that satisfactory outcomes can be obtained following TAA even in ankles with substantial preoperative coronal deformity (4, 9–12). The key to achieving postoperative neutral alignment seems to be associated with additional procedures at the time of TAA. Similar to previous studies, in the present study, additional procedures were performed at the time of TAA to obtain appropriate soft tissue

balancing and neutral alignment, resulting in comparable outcomes with those in previous reports. The present findings support the suggestion that preoperative deformity does not diminish clinical outcomes if a well-aligned stable ankle is obtained after TAA (4, 11).

No concomitant osteotomies were performed in the present study even in the varus group; however, the postoperative TT and TMM angles were improved in both groups and were not significantly different between the neutral and coronal groups. This finding suggests that postoperative neutral coronal alignment was achieved by performing proper soft tissue balancing, such as deltoid ligament release, alone. The advantages of not performing concomitant osteotomy include less invasive surgery for patients and weight-bearing can be allowed soon after the surgery.

With regard to SAFE-Q, the varus group had slightly better postoperative outcomes in the subscales of social-functioning and health than the neutral group, contrary to the hypothesis (Table 3). However, the level of improvement was not significantly different between the groups. Additionally, other possible reasons may be that the number of patients was lower in the varus group than in the neutral group, and that the follow-up period was slightly shorter in the varus group.

Outcomes after TAA using the TNK ankle prosthesis have been shown to be satisfactory in several reports (13–15); however, these reports did not investigate the relationship between preoperative coronal deformity and postoperative outcomes. In 1990, Takakura et al. reported that postoperative outcomes were satisfactory in 67% of ceramic prostheses without cement (13). In 2004, they reported satisfactory outcomes with 70 ankles (39 OA ankles and 31 RA ankles) using the current third-generation TNK ankle prosthesis (14). The outcomes are in agreement with the report by Nagashima et al. (15) in which favorable outcomes were noted in 21 RA ankles using the same prosthesis. These previous studies support the present findings that outcomes following TAA using the TNK ankle prosthesis were satisfactory independent of preoperative coronal deformity.

Several limitations of the present study should be noted. First, the number of patients was relatively small; however, a prior power analysis showed that the number of patients in the present study could be powered to detect significant differences. Second, the follow-up period in the current study was an average of 3 years after the surgery, which is relatively short. Thus, long-term outcomes of the present cases should be investigated in the future.

## Conclusions

Outcomes after TAA using the TNK ankle prosthesis were favorable in patients with severe varus ankle alignment and in those with neutral ankle alignment without concomitant osteotomy. Satisfactory outcomes could be achieved in patients with severe varus ankle alignment after TAA using the TNK ankle prosthesis without concomitant osteotomy.

## Abbreviations

TAA  
Total ankle arthroplasty  
OA  
Osteoarthritis  
RA  
Rheumatoid arthritis  
TT  
Talar tilt  
ROM  
Range of motion  
JSSF  
Japanese Society for Surgery of the Foot  
SAFE-Q  
Self-Administered Foot Evaluation Questionnaire  
TAS  
Tibial anterior surface  
TMM  
Tibial axis-medial malleolus  
TLS  
Tibial lateral surface  
SD  
Standard deviation

## **Declarations**

## **Ethics approval and consent to participate**

The institutional review board of Kobe University Hospital approved this study (No.180053).

## **Consent for publication**

Informed consent was obtained from all the patients.

## **Availability of data and materials**

The datasets used and/or analyzed during the current study are available from the corresponding author on reasonable request.

## **Competing interests**

The authors declare no conflict of interest in association with the present study.

## Funding

We do not have any funding in association with the present study.

## Authors' contributions

The co-authors and I warrant that all authors have participated in this study. Detailed contributions are as follows; Takahiro Y, NK, TY, KI conceived of the study, and all authors participated in the design of the study. Takahiro Y, NK, Tetsuya Y, KI contributed to the acquisition of the data. Takahiro Y, KN, NK and TM performed data analysis, and all authors participated in the interpretation of the data. Takahiro Y and KN drafted the article, and NK and TM performed critical version of the manuscript for important intellectual content. All authors have read and approved the final manuscript.

## Acknowledgements

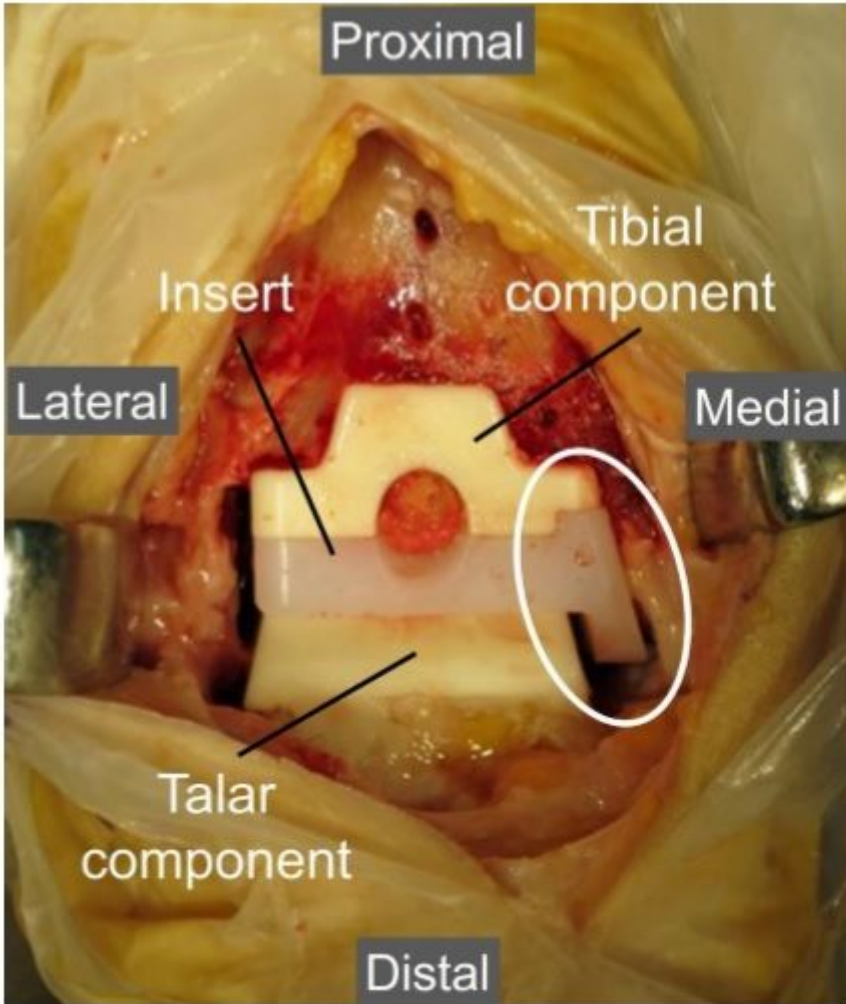
We would like to thank Editage ([www.editage.com](http://www.editage.com)) for English language editing.

## References

1. Saltzman CL, Kadoko RG, Suh JS. Treatment of isolated ankle osteoarthritis with arthrodesis or the total ankle replacement: A comparison of early outcomes. *Clin Orthop Surg*. 2010;2(1):1–7.
2. Kim BS, Choi WJ, Kim YS, et al. Total ankle replacement in moderate to severe varus deformity of the ankle. *J Bone Joint Surg Br*. 2009;91-B(9):1183–90.
3. Trajkovski T, Pinsker E, Cadden A, et al. Outcomes of Ankle Arthroplasty with Preoperative Coronal-Plane Varus Deformity of 10° or Greater. *J Bone Joint Surg Am*. 2013;95(15):1382–8.
4. Lee G-W, Wang S-H, Lee K-B. Comparison of Intermediate to Long-Term Outcomes of Total Ankle Arthroplasty in Ankles with Preoperative Varus, Valgus, and Neutral Alignment. *J Bone Joint Surg*. 2018;100(10):835–42.
5. Nunley JA, Caputo AM, Easley ME, et al. Intermediate to Long-Term Outcomes of the STAR Total Ankle Replacement: The Patient Perspective. *J Bone Joint Surg Am*. 2012;94(1):43–8.
6. Mann JA, Mann RA, Horton E. STAR™ Ankle: Long-Term Results. *Foot Ankle Int*. 2011;32(5):473–84.
7. Doets HC, Brand R, Nelissen RGHH. Total Ankle Arthroplasty in Inflammatory Joint Disease with Use of Two Mobile-Bearing Designs. *J Bone Joint Surg Am*. 2006;88(6):1272–84.
8. Wood PLR, Sutton C, Mishra V, et al. A randomised, controlled trial of two mobile-bearing total ankle replacements. *J Bone Joint Surg Br*. 2009;91-B(1):69–74.

9. Trincat S, Kouyoumdjian P, Asencio G. Total ankle arthroplasty and coronal plane deformities. *Orthop Traumatol Surg Res.* 2012;98(1):75–84.
10. Usuelli FG, Di Silvestri CA, D'Ambrosi R, et al. Total ankle replacement: is pre-operative varus deformity a predictor of poor survival rate and clinical and radiological outcomes? *Int Orthop.* 2019;43(1):243–9.
11. Queen RM, Adams SB, Viens NA, et al. Differences in Outcomes Following Total Ankle Replacement in Patients with Neutral Alignment Compared with Tibiotalar Joint Malalignment. *J Bone Joint Surg Am.* 2013;95(21):1927–34.
12. Lee G-W, Lee K-B. Outcomes of Total Ankle Arthroplasty in Ankles with > 20° of Coronal Plane Deformity. *J Bone Joint Surg.* 2019;101(24):2203–11.
13. Takakura Y, Tanaka Y, Sugimoto K, et al. Ankle arthroplasty. A comparative study of cemented metal and uncemented ceramic prostheses. *Clin Orthop Relat Res.* 1990;(252):209–16.
14. Takakura Y, Tanaka Y, Kumai T, et al. Ankle arthroplasty using three generations of metal and ceramic prostheses. *Clin Orthop Relat Res.* 2004;(424):130–6.
15. Nagashima M, Takahashi H, Kakumoto S, et al. Total ankle arthroplasty for deformity of the foot in patients with rheumatoid arthritis using the TNK ankle system: clinical results of 21 cases. *Mod Rheumatol.* 2004;14(1):48–53.
16. Zhao HM, Wen XD, Zhang Y, et al. Supramalleolar osteotomy with medial distraction arthroplasty for ankle osteoarthritis with talar tilt. *J Orthop Surg Res.* 2019;14(1):1–8.
17. Niki H, Aoki H, Inokuchi S, et al. Development and reliability of a standard rating system for outcome measurement of foot and ankle disorders II: Interclinician and intraclinician reliability and validity of the newly established standard rating scales and Japanese Orthopaedic Association. *J Orthop Sci.* 2005;10(5):466–74.
18. Niki H, Aoki H, Inokuchi S, et al. Development and reliability of a standard rating system for outcome measurement of foot and ankle disorders I: Development of standard rating system. *J Orthop Sci.* 2005;10(5):457–65.
19. Niki H, Tatsunami S, Haraguchi N, et al. Validity and reliability of a self-administered foot evaluation questionnaire (SAFE-Q). *J Orthop Sci.* 2013;18(2):298–320.
20. Takakura Y, Tanaka Y, Kumai T, et al. Low tibial osteotomy for osteoarthritis of the ankle. Results of a new operation in 18 patients. *J Bone Joint Surg Br.* 1995;77-B(1):50–4.
21. Hintermann B, Valderrabano V, Dereymaeker G, et al. The HINTEGRA ankle: Rationale and short-term results of 122 consecutive ankles. *Clin Orthop Relat Res.* 2004;(424):57–68.
22. Tanaka Y, Takakura Y, Hayashi K, et al. Low tibial osteotomy for varus-type osteoarthritis of the ankle. *J Bone Joint Surg Br.* 2006;88-B(7):909–13.

## Figures



**Figure 1**

The TNK ankle prosthesis. Total ankle arthroplasty using the TNK ankle prosthesis were performed via anterior approach. The insert has a medial wall (white circle).