

A case report of a severe neonatal systemic vasculitis on the first day of life

Stephanie Wong (✉ stephanie.ka.wong@gmail.com)

The University of British Columbia <https://orcid.org/0000-0002-3237-1725>

Erkan Demirkaya

Western University

Roberta Berard

Western University

Case Report

Keywords: Vasculitis, polyarthritis, pregnancy, neonate

Posted Date: March 31st, 2021

DOI: <https://doi.org/10.21203/rs.3.rs-278535/v1>

License: © ⓘ This work is licensed under a Creative Commons Attribution 4.0 International License.

[Read Full License](#)

Abstract

BACKGROUND: Transmission of autoantibodies across the placenta has been associated with neonatal cutaneous vasculitis and lupus syndromes. Here we report a novel association of a case of new-onset maternal seronegative inflammatory arthritis associated with a transient systemic vasculitis in a neonate.

CASE PRESENTATION: In the first 24 hours of life, a preterm baby boy was noted to have blue discoloration to all four extremities. A workup for sepsis and thrombosis were negative. Despite antibiotics, fresh frozen plasma and anticoagulation, the discoloration remained, particularly in the left index finger. This was associated with fever and a maximum C-reactive protein (CRP) of 148 mg/L. Two doses of intravenous immunoglobulin (IVIG) were given with short-term improvement. Echocardiogram was normal. The fever, elevated CRP and finger discoloration responded to high dose steroid administration. MRI angiography (MRA) of body and heart showed tortuosity of arteries in the upper and lower extremities with gadolinium uptake, suggestive of vasculitis. Autoantibody profile negative. Genetic panel for hereditary autoinflammatory diseases was negative as was whole exome sequencing performed on the trio. The baby was weaned off steroids by 5 months of age. A small distal autoamputation of the left index finger occurred.

He was born to a 28-year-old woman who developed new onset severe symmetrical polyarthritis at 8 weeks gestation. It was presumed this was reactive arthritis secondary to a dental infection. Infectious work up and autoantibodies were negative. She was treated with high dose prednisone for the remainder of her pregnancy.

The mother was weaned off prednisone and treated with hydroxychloroquine for 8 months post-partum and remains in remission. A repeat MRA done at 1 year old showed mild residual tortuosities of the arteries in the forearms. The remainder of the medium and large vessels were within normal limits with no gadolinium enhancement to suggest active disease. The child is now 4 years old with normal growth and development.

CONCLUSION: This is a unique case of new-onset seronegative presumed reactive arthritis in a mother with the rare development of a successfully treated medium vessel vasculitis in an infant.

Background

During pregnancy many changes occur in the immune system to allow tolerance to the fetus. A level of immunosuppression is required as the fetus expresses paternally inherited alloantigens which requires the mother to create a sense of tolerance. One mechanism of tolerance suggested is the switch from Th1 cytokine profile to the Th2 profile¹. Certain Th1 predominant autoimmune diseases such as rheumatoid arthritis tend to show improvement during pregnancy, while Th2 predominant diseases such as systemic lupus erythematosus tend to flare. Neonatal cutaneous vasculitis in infants born to mothers with systemic lupus erythematosus, Sjögren's syndrome and Bechet's disease have been described. Here we report the first case, to our knowledge, of a new onset of seronegative inflammatory arthritis in a

primiparous mother associated with the development of an effectively treated systemic vasculitis syndrome in the neonate.

Clinical Case

A male infant was born at 33 weeks and 4 days gestation via caesarian section, due to fetal tachycardia, following spontaneous premature rupture of membranes. APGAR scores were 9 at one minute and 9 at five minutes. Birth weight was 2920g (90th percentile), head circumference 34.5cm (>97th percentile), length of 44cm (40th percentile). There were no dysmorphic features. Within the first 24 hours of life, blue discoloration was noted to the distal left second finger which progressed to multiple fingers and toes in all four limbs. The infant was transferred to a tertiary care neonatal intensive care unit for evaluation.

The mother was a 28-year-old Caucasian woman who developed new onset symmetrical polyarthritis during her first trimester of pregnancy. Past history was significant for a previous miscarriage at 5 weeks gestation and a cholecystectomy. Family history was negative. There was no smoking, alcohol or drug use during pregnancy. Prenatal screening showed rubella titre indeterminant (7.4IU/ml) as well as hepatitis B, human immunodeficiency virus (HIV), syphilis negative. Parvovirus B19 immunoglobulin G (IgG) reactive, cytomegalovirus IgG non-reactive, toxoplasmosis IgG negative.

At 6 weeks' gestation, the mother underwent dental work complicated by an oral abscess requiring seven days of amoxicillin. Two days after initiation of amoxicillin, she developed severe myalgias, episodes of nausea, vomiting and diarrhea which resolved in a few days. No fever, rash, or urinary symptoms. At 8 weeks gestation she presented with severe polyarthritis affecting large and small joints with significant functional impairment. She was prescribed oral prednisone at 10 weeks' gestation for a presumed reactive arthritis. Blood work prior to treatment showed elevated inflammatory markers including C-reactive protein (CRP) of 210 mg/L (normal <3mg/L) and erythrocyte sedimentation rate (ESR) of 60mm/hr (0-20mm/hr normal). She was steroid dependent for the remainder of the pregnancy requiring high dose prednisone (25 mg orally twice daily) with failure to taper below this dose.

Additional infectious work up including Epstein Barr virus and Lyme serology were negative. Anti-nuclear antibody (ANA), extractable nuclear antigen antibodies (ENA), antiphospholipid antibodies (APLA), antineutrophilic cytoplasmic antibodies (ANCA), rheumatoid factor (RF), complement levels (C3, C4) were negative or within normal range. Fetal anatomy scan at 19 weeks was normal.

The neonate was transferred to a tertiary care neonatal intensive care unit (NICU) on day of life 3 and had a negative full septic work up including blood, urine and cerebrospinal fluid cultures. Despite treatment with antibiotics, fresh frozen plasma and topical vasodilators, the discoloration remained, particularly in the left hand (Figure 1). Stress dosing of hydrocortisone for possible adrenal insufficiency was given due to the long in-utero exposure to steroids in the mother. Heparin was given for potential inherited thrombophilia. On day of life 11, he was transferred to a second NICU. He was noted to have erythema of his hands and feet, which prompted initial consideration for neonatal Kawasaki disease (no other clinical criteria for Kawasaki disease). After two doses of intravenous immunoglobulin (IVIG) (2g/kg) short lived improvement was noted. An echocardiogram showed enlarged coronary arteries (maximum in left anterior descending artery (LAD), z-score 3.93). Two days after the second dose of IVIG he continued to have fever (up to 38.2 degrees Celsius), tachycardia and elevated CRP (maximum CRP of 172mg/L, normal <3mg/L) and intravenous methylprednisolone (2mg/kg) was initiated. Inflammatory markers, skin discoloration and tachycardia improved with steroid treatment. Repeat echocardiogram 1 week later demonstrated normal coronaries.

Full body magnetic resonance angiography (MRA) was significant for abnormalities in the upper limbs with tortuosity and gadolinium enhancement of the brachial as well as the distal axillary arteries. In the lower limbs, tortuosities and gadolinium enhancement involving distal femoral, popliteal, posterior and anterior tibialis arteries suggestive of vasculitis or vasculopathy (Figure 3). Aortic, pulmonary, renal and celiac trunk vessels were normal. Given the clinical syndrome, imaging findings and response to corticosteroid administration, vasculitis was favored.

The neonate's autoimmune work included a negative ANA, ENA, APLA, ANCA, RF, and anti-smooth muscle antibody (ASMA). Complement levels (C3, C4, CH50) and immunoglobulins (IgG, IgA, IgM) were normal. Thrombophilia workup including INR, PTT, fibrinogen, protein C, protein S, antithrombin, homocysteine level, Factor VIII level, lupus anticoagulant, prothrombin mutation were within normal limits or negative. Ophthalmology exam was normal, with no signs of retinal vasculitis. Newborn screen (Appendix 1) was negative and his metabolic work up including ammonia level, plasma amino acids, urine organic acids, total and free carnitine, acylcarnitine profile, methylmalonic acid level were normal. His DNA was screened with targeted sequencing for known hereditary autoinflammatory diseases however, we were not able to identify a causative mutation. Whole exome sequencing was conducted as a trio (both parents and the affected child sequenced simultaneously), which did not identify a pathogenic variant.

Oral prednisolone (2 mg/kg divided twice daily) was continued with improvement of the discoloration in the infant's hands and feet, however the left index finger discoloration persisted with progression to necrosis. A diagnostic biopsy was considered but was deferred due to the necrosis and likely low

diagnostic yield. The male infant was effectively weaned off steroids by 5 months of age and is now 4 years old with normal growth and development. A follow up image of the hand at 21 months old is shown in Figure 2. Repeat MRA at 17 months of age showed residual mild tortuosity of the upper extremity abnormalities with no gadolinium enhancement and the lower limbs arteries normal in appearance with normalization of prior tortuosities (Figure 4).

The mother was seen by an adult rheumatologist post-partum. She was weaned off prednisone with a slow taper of approximately 3 months and was treated with hydroxychloroquine for a total of 8 months. She remains in remission off therapy and has had no further pregnancies.

Discussion

Vasculitides are rarely seen in neonates, with the exception of reported neonatal vasculitis occurring in infants of mothers affected by systemic lupus erythematosus, Sjögren's syndrome, Behçet's disease, undifferentiated connective tissue disease or microscopic polyangiitis.

Stone et al. describes a pregnant 24-year-old Caucasian woman with a history of cutaneous polyarteritis nodosa (PAN) who had a flare during pregnancy and treated with prednisone². The newborn infant born at 36 weeks gestation had a "dusky" episode on day of life 1, then developed cyanosis of her left finger, left ear, nose, upper lip and several toes. She had prominent livedo reticularis on the proximal extremities and abdomen with development of dermal nodules on the trunk, extremities as well as the scalp. She was started on heparin and prednisone with improvement. Similar to our case, cyanosis improved but the infant suffered from autoamputation of parts of three toe digits. A skin nodule biopsy showed results consistent with medium sized vasculitis suggestive of polyarteritis nodosum². Both mother and baby were shown to be ANA, RF and ANCA negative. The authors propose the presentation was caused by a maternal factor crossing the placenta. In addition, the neonate was found to have high levels of fibrinogen, however low functioning, which could be secondary to an abnormal fibrinogen molecule or antibody interfering with functioning. The neonate we present had had fibrinogen levels within normal range (2.86-3.37g/L).

Bansal et. al. described a case of a 32-year-old woman with a history of polyarteritis nodosa, anti-myeloperoxidase (MPO) positive delivering a newborn female with pulmonary hemorrhage requiring ventilatory support in addition to proteinuria and hematuria³. Treatment included hydrocortisone (3mg/kg) and plasma exchange which led to improvement. Umbilical cord blood showed elevated anti-MPO antibody at 3.30U/mL (reference range 0.00-0.89U/mL) which normalized with therapy. Hydrocortisone was successfully tapered over 3 weeks. This case presenting with a mother with a known

history of polyarteritis nodosa causing a transient vasculitis syndrome in her newborn from a measured placentally transferred autoantibody.

The mother, in our case, presented at 8 weeks gestational age with polyarthritis requiring high dose steroids. Angiogenesis and vasculogenesis begins at approximately week 3 of pregnancy. Blood vessels continue to form in the embryo and placenta until approximately 10 weeks, when most organs are completely formed⁴. Our patient was extensively investigated for infectious, thrombophilia and genetic etiologies for a vasculitis syndrome which were negative. Given his prematurity, there is further reduction in function of the Vitamin K dependent coagulation factors and contact factors making thrombosis causing finger necrosis very unlikely^{4,5,6}.

During pregnancy, the hormonal profile causes immunomodulatory changes, with a shift from a Th1 to a Th2 lymphocyte predominant response¹. Newer research has suggested it may be a combination of other T cells and inflammatory markers including Th17, T regulatory cells, tumor necrosis factor as well as IL-2 allowing tolerance of the fetus that allows this⁷. Typically, rheumatoid arthritis improves in pregnancy (Th1 predominant disease) while certain diseases such as systemic lupus erythematosus (Th2 predominant disease) tend to flare. The presence of IgG isotype autoantibodies in maternal diseases can cross the placenta causing antibody-mediated damage in the neonate⁸. This includes neonatal lupus erythematosus (NLE), immune thrombocytopenic purpura and antiphospholipid syndrome. Most notably in NLE, noncardiac manifestations are transient, resolving with the disappearance of maternal autoantibodies.

Similar to our case, upon clearance of a suspected maternal antibody or factor, there was resolution of symptoms. SLE and Sjögren's syndrome are the most well described rheumatic diseases associated with pathogenic antibodies passing from the mother to the infant through anti-Ro/anti-La across the placenta⁹. Clearance of these passively transferred maternal antibodies occurs by 6 months of age. This timeline for clearance is consistent with our cases with successful discontinuation of steroids at 5 months of age.

Conclusion

This is a unique case of new onset seronegative presumed reactive arthritis in a mother with the rare development of a successfully treated medium vessel vasculitis in an infant. The etiology of the infant's symptoms is unknown but may be secondary to a transplacental transfer of an unidentified autoantibody, inflammatory protein or cytokines. This theory is supported with complete recovery

following treatment in the neonate by 6 months of age which coincides with timing for clearance of maternal factors.

List Of Abbreviations

ANA – anti-nuclear antibody

ANCA – antineutrophilic cytoplasmic antibodies

APGAR – appearance, pulse, grimace, activity and respiration

APLA – antiphospholipid antibodies

APS – antiphospholipid syndrome

ASMA – anti-smooth muscle antibody

CANDLE - Chronic atypical neutrophilic dermatosis with lipodystrophy and elevated temperature

CRP – C-reactive protein

DADA2 - Deficiency of Adenosine Deaminase 2

ENA – extractable nuclear antigen antibodies

ESR – erythrocyte sedimentation rate

HIV – human immunodeficiency virus

INR – international normalized ratio

IVIG – intravenous immunoglobulin

LAD – left anterior descending

LMCA – left main coronary artery

MCP – metacarpophalangeal

MPA – main pulmonary artery

MPO – anti-myeloperoxidase

MRA – magnetic resonance angiography

NICU - neonatal intensive care unit

NLE – neonatal lupus erythematosus

PAN – polyarteritis nodosa

PTT – partial thromboplastin time

RCA – right coronary artery

RF – rheumatoid factor

SAVI - STING-associated vasculopathy with infantile onset

Declarations

Ethics and consent to participate:

Not applicable.

Consent for publication:

Obtained.

Availability of supporting data:

Patient data used during this report are available from corresponding author on reasonable request.

Competing interests:

The authors declare that they have no competing interests.

Funding:

None.

Authors' contribution:

SW was main contributor to writing and editing of the manuscript. SW ensured data was accurate and reflects original work. SW certifies that all authors who deserve to be credited on manuscript are indeed identified, no authors are listed who do not deserve authorship credit, that author contributions are expressed accurately. RB ensured data was accurate and was a major contributor in editing the manuscript. ED also contributed to editing of manuscript. All authors read and approved the final manuscript.

Acknowledgements:

Not applicable.

Authors' information:

SW – Pediatric Rheumatology Fellow, BC Children's Hospital, Vancouver, Canada

ED – Pediatric Rheumatologist, London Health Sciences Center, London, Canada

RB – Pediatric Rheumatologist, London Health Sciences Center, London, Canada

References

1. **Wegmann TG**, Lin H, Guilbert L, Mosmann T.R. Bidirectional cytokine interactions in the maternal-fetal relationship: is successful pregnancy a Th2 phenomenon? *Immunology Today*. 1993;14:353–6.
2. Stone, M. S., Olson, R. R., Weismann, D. N., Giller, R. H., Goeken, J. A. Cutaneous vasculitis in the newborn of a mother with cutaneous polyarteritis nodosa. *Journal of the American Academy of Dermatology*. 1993;28(1):101-105.
3. Bansal, P.J., Tobin, M.C. Neonatal microscopic polyangiitis secondary to transfer of maternal myeloperoxidase-antineutrophil cytoplasmic antibody resulting in neonatal pulmonary hemorrhage and renal involvement. *Annals of Allergy, Asthma and Immunology*. 2004;93:398-401.
4. Artal-Mittelmark, R. Stages of Development of the Fetus, *Merck Manual*, Aug 2019.
<https://www.merckmanuals.com/en-ca/home/women-s-health-issues/normal-pregnancy/stages-of-development-of-the-fetus>. Accessed 14 Sept 2019.
5. Andrew, M., Paes, B., Milner, R., Johnston, M., Mitchell, L., Tollefesen, D.M., Powers, P. Development of the Human Coagulation System in the Full-Term Infant, *Blood Journal*. 1987;70(1):165-172.
6. Wu, Y. Contact pathway of coagulation and inflammation. *Thrombosis Journal*. 2015;13(17):1-9.
7. Forger, F., Villiger, P. M. Immunological adaptations in pregnancy that modulate rheumatoid arthritis disease activity, *Nature Reviews, Rheumatology*. 2020;16:113-122.
8. Motta, M., Tincani, A., Lojacono, A., Faden, D., Gorla, R., Airo, P., Neri, F., Gasparoni, A., Ciardelli, L., de Silvestri, A., Marconi, M., Chirico, G. Neonatal outcome in patients with rheumatic disease, *Lupus*. 2004;13(9): 718-23.
9. Gayed, M., Gordon, C. Pregnancy and rheumatic diseases. 2007;46(11):1634–1640.

Figures

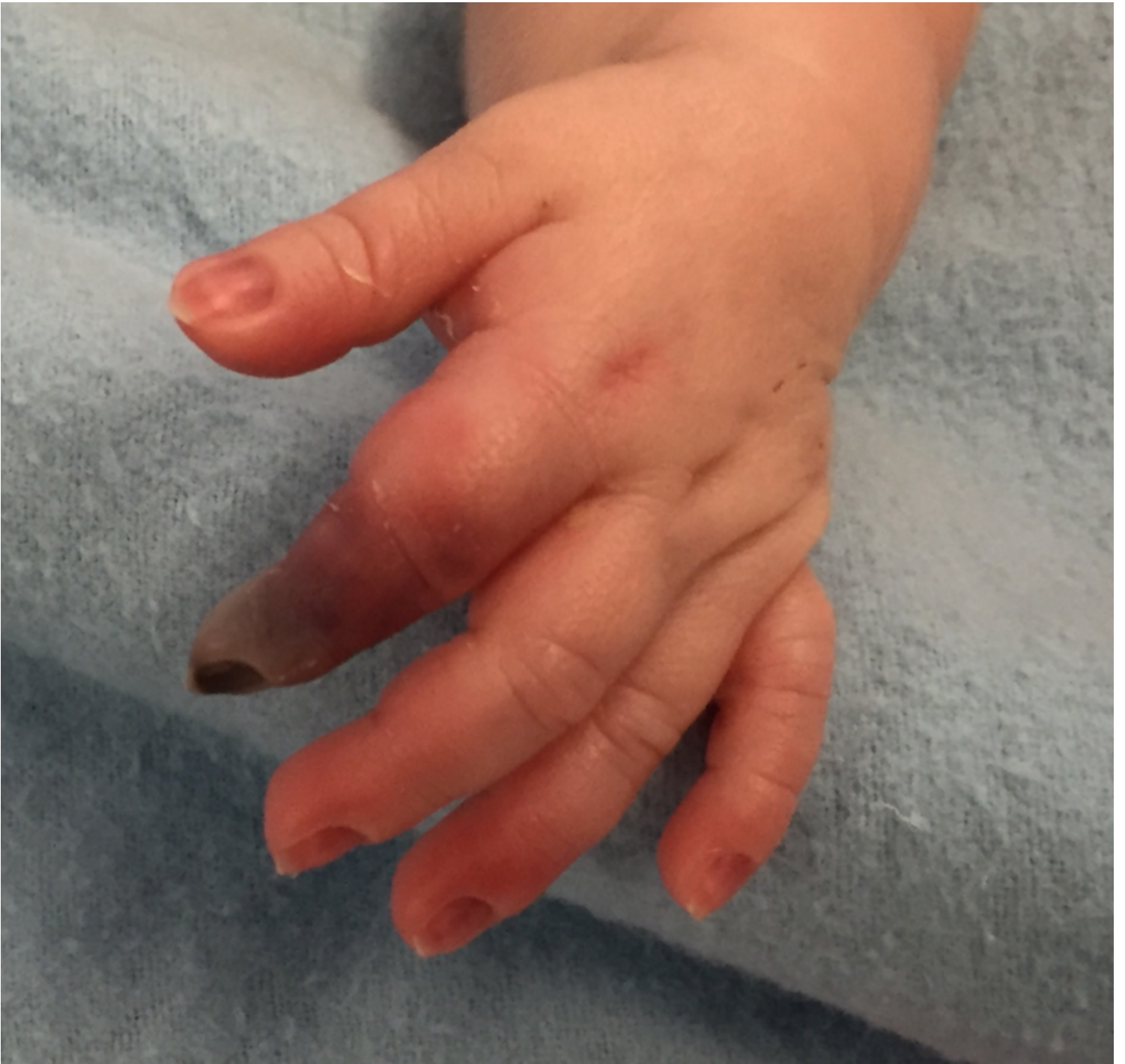

Figure 1

Left hand on fifth day of life

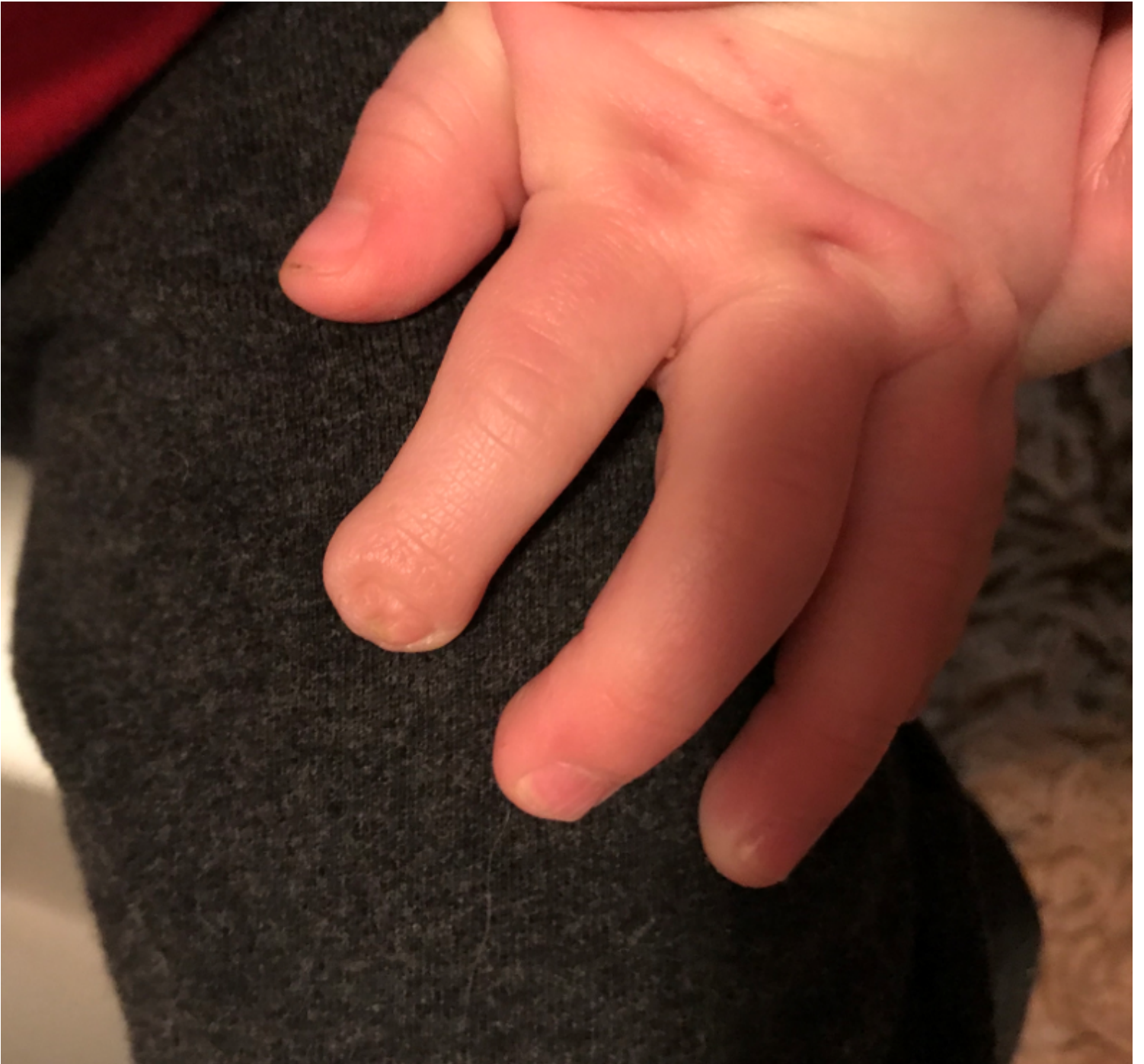

Figure 2

Left hand at 21 months of age

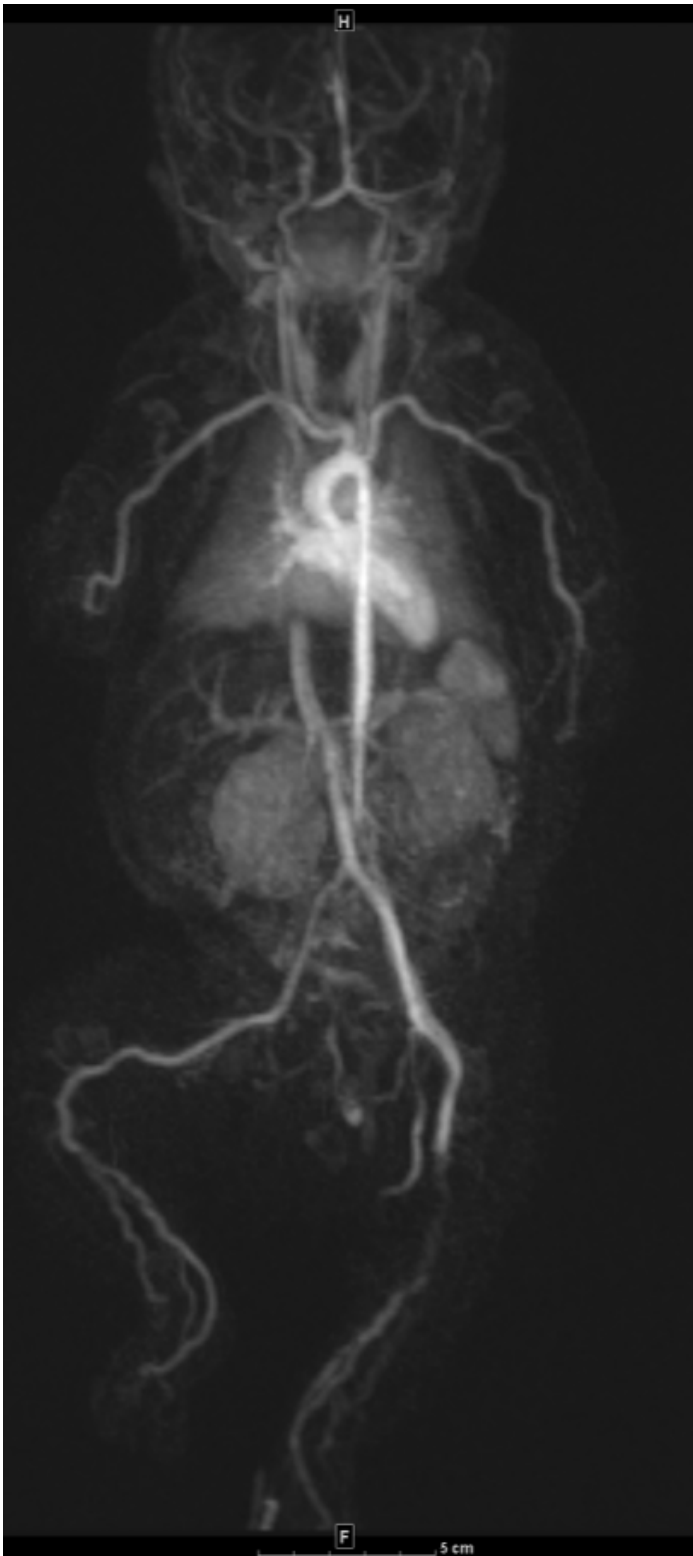


Figure 3

Magnetic resonance angiography at one month of age. Gadolinium enhancing irregular and tortuous appearing medium sized arteries bilaterally in the upper and lower extremities.

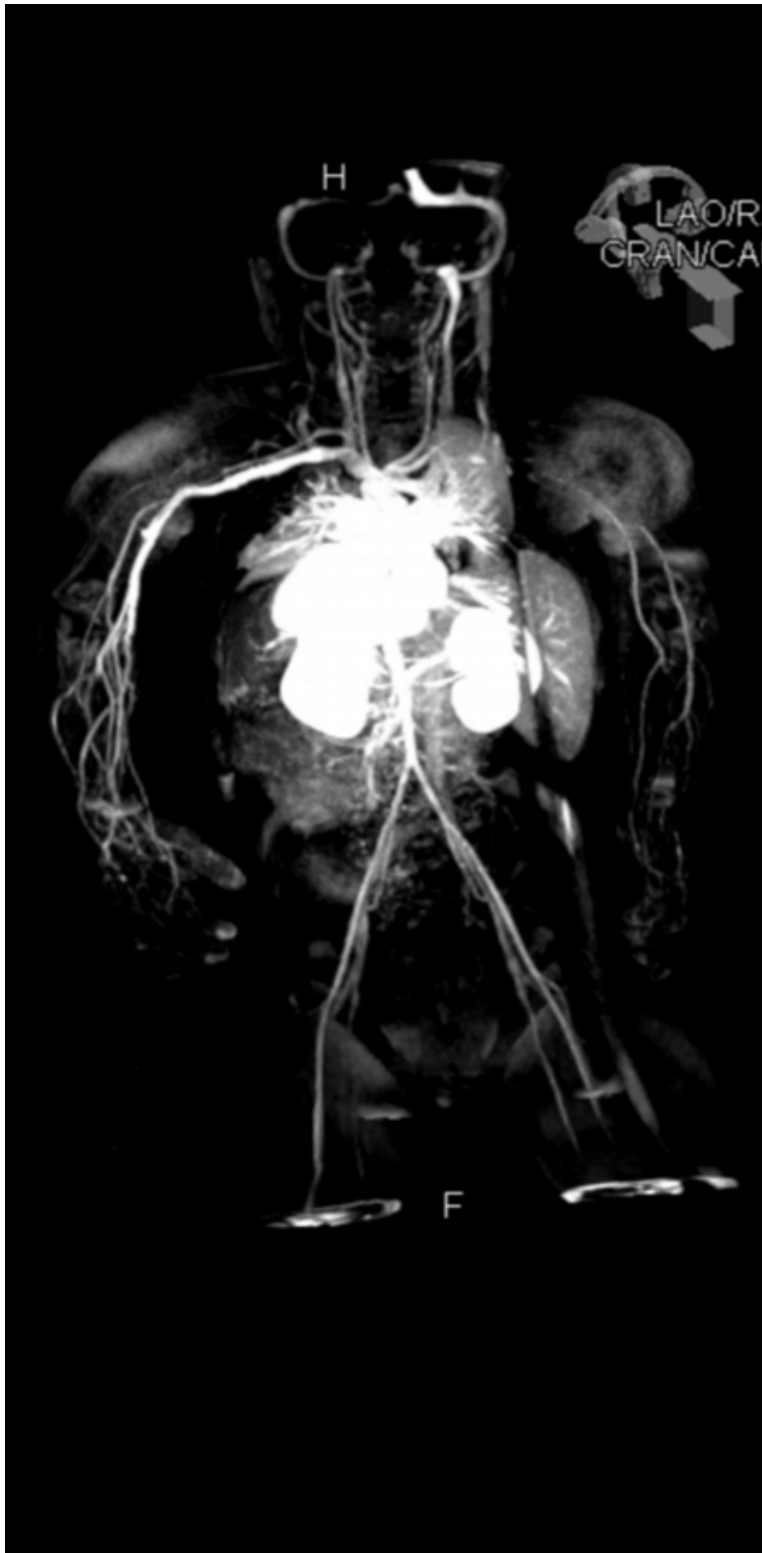

Figure 4

Follow-up magnetic resonance angiography at 17 months of age demonstrates residual tortuosity of forearm vessels with normalization of lower extremity abnormalities and no gadolinium enhancement.

Supplementary Files

This is a list of supplementary files associated with this preprint. Click to download.

- [PRvascAppendix1.docx](#)