

Clinical Features and Treatment of Inactive Proliferative Diabetic Retinopathy

Weiting An

Tianjin International Joint Research and Development Centre of Ophthalmology and Vision Science, Eye Institute and School of Optometry, Tianjin Medical University Eye Hospital

Qi Zhao

Tianjin International Joint Research and Development Centre of Ophthalmology and Vision Science, Eye Institute and School of Optometry, Tianjin Medical University Eye Hospital

Longli Zhang

Tianjin International Joint Research and Development Centre of Ophthalmology and Vision Science, Eye Institute and School of Optometry, Tianjin Medical University Eye Hospital

Jindong Han (✉ djindonghan@126.com)

Tianjin International Joint Research and Development Centre of Ophthalmology and Vision Science, Eye Institute and School of Optometry, Tianjin Medical University Eye Hospital

Research Article

Keywords: Inactive, Proliferative diabetic retinopathy, Vitrectomy

DOI: <https://doi.org/10.21203/rs.3.rs-278452/v1>

License:   This work is licensed under a Creative Commons Attribution 4.0 International License.

[Read Full License](#)

Abstract

Background To investigate the clinical features and results after vitrectomy for inactive proliferative diabetic retinopathy (IPDR).

Methods Retrospective review of 40 eyes of 21 IPDR patients who underwent 23G or 25G minimally invasive vitrectomy between January 2018 and December 2019 in Tianjin Medical University Eye Hospital.

The average follow-up period was 8.7 months. Outcome measures were best-corrected visual acuity (BCVA), clinical features and intraoperative findings of IPDR.

Results All eyes were performed with panretinal photocoagulation (PRP) for average 1.6 years before operation. Fundus examination showed the optic disc was pale, and a mass of yellowish-white fibroproliferative membrane was around the optic disc and vascular arcade. Thirty-three eyes (82.5%) were accompanied by tractional retinal detachment, and macula was involved in 9 eyes (22.5%). The vitreous adhered with the retina tightly. The mid-peripheral retina was thin. Thirty-one eyes (77.5%) were accompanied by small branch retinal artery and vein occlusion. Fourteen eyes (35.0%) occurred iatrogenic retinal break during vitrectomy. The median LogMAR of BCVA significantly improved from 1.0 (20/200) preoperatively to 0.92 (20/167) postoperatively ($P = 0.000$).

Conclusions The fundus manifestation of IPDR was quiet and special. Vitrectomy could improve patients' visual acuity, but the incidence of iatrogenic retinal break was high.

Vitrectomy could be performed by well-skilled vitreoretinal surgeons according to the minimum quantitative principle.

1. Background

Proliferative diabetic retinopathy (PDR) is more active, mainly manifested as repeated vitreous hemorrhage (VH), fibrovascular proliferation and tractional retinal detachment (TRD), which is the leading cause of blindness in diabetic patients[1–3]. Vitrectomy is seen as an effective method in treating PDR[4, 5]. Inactive proliferative diabetic retinopathy (IPDR) refers to PDR with "quiet" fundus performance. The clinical features of IPDR are different from traditional PDR, and the principles and efficacy of vitrectomy are also different from traditional PDR. In order to analyze the clinical features of IPDR and the efficacy of vitrectomy, we had included a group of clinical data of IPDR patients. Now the results were reported as following.

2. Materials And Methods

2.1. Patients

Retrospective review of 40 eyes of 21 IPDR patients who underwent 23G or 25G minimally invasive vitrectomy between January 2018 and December 2019 in Tianjin Medical University Eye Hospital. Inclusion criteria: (1) PDR patients according to the classification criteria of DR recommended by the International Academy of Ophthalmology in 2003[6]; (2) No fresh vitreous and retinal hemorrhage; (3) The fibroproliferative membrane is yellowish-white without active neovascularization; (4) All patients were treated with 23G or 25G minimally invasive vitrectomy.

Exclusion criteria: Patients with a clear diagnosis of retinal vascular occlusion, macular degeneration and optic neuropathy.

This study adhered to the tenets of the Helsinki Declaration and was approved by ethics committee of Tianjin Medical University Eye Hospital.

Written informed consent was obtained from all patients.

2.2. Synopsis of design

Preoperative data, including the patient's age (at operation), gender, and systemic diseases, including hypertension, cardiovascular disorders, cerebrovascular disorders and renal disorders with dialysis were collected. The blood glucose and HbA1C level measured on the day of admission for the operation were recorded. History of previous ocular procedure such as panretinal photocoagulation (PRP) was also recorded. Preoperative ocular examinations in both lesion eyes and fellow eyes included measurements of best-corrected visual acuity (BCVA), intraocular pressure, biomicroscopic examination of anterior and posterior segments, fundus examination with indirect ophthalmoscope, Bscan ultrasonography and optical coherence tomography (OCT). Funduscopy findings including the color of optic disc, the extent of TRD and the location and extension of fibroproliferative membrane were recorded.

A standard 3-port 23- or 25-gauge pars plana vitrectomy (PPV) was performed to all eyes by surgeons with more than 15 years of vitreoretinal surgery experience. The surgical procedures have been reported elsewhere[7, 8]. In short, during the standard vitrectomy procedure, anterior–posterior vitreoretinal traction was released as much as possible. Microscissors and cutter were used for segmentation and delamination of fibrovascular tissue. Proliferative tissue was removed to the greatest possible extent to the periphery, with the caution to avoid inducing iatrogenic break. Laser photocoagulation was only performed around the iatrogenic retinal break. Phacoemulsification combined with intraocular lens implantation was performed in patients with obvious lens opacity. Silicone oil or perfluoropropane (C3F8) infusion were indicated if there were multiple large retinal breaks or extensive retinectomy.

The average follow-up period was 8.7 months (6–12 months). Silicone oil removal surgery was performed for patients who had good retinal attachment at 3 months after PPV.

2.3. Statistical methods

The systemic, pre-, intra-, and post-operative data was analyzed. All visual acuity data were converted to the logarithm of minimal angle of resolution (logMAR) scale for analyses. The Wilcoxon signed-rank test was performed for non-normal continuous observations. Analyses were performed using SPSS 22.0, P values < 0.05 was considered statistically significant.

3. Results

There were 9 males (17 eyes) and 12 females (23 eyes), with an average age of 55.5 ± 9.9 years (41–73 years old). All patients were diagnosed with type 2 diabetes after examination by the department of endocrinology and met the diabetes diagnostic criteria by WHO in 1999[9]. The average diabetic duration was 12.4 ± 5.7 years (5–25 years), and HbA1C was $7.4 \pm 1.0\%$. The preoperative median LogMAR of BCVA was 1.0 (Snellen equivalent of 20/200). All eyes were treated with PRP 1.6 ± 1.1 years (0.5-4.0 years) before the operation under the guidance of fundus fluorescein angiography (FFA). Subject characteristics are summarized in Table 1.

Clinical features of IPDR: (1) IPDR was mostly bilateral. In this study, 19 patients (90.5%) were bilateral, only 2 (9.5%) patients were unilateral. Among them, the fellow eye had received vitrectomy due to PDR in one patient, the fellow eye lost sight due to unknown reason 4 years ago in another patient; (2) IPDR occurred after PRP treatment; (3) No fresh hemorrhage was observed in vitreous and retina; (4) The fibroproliferative membrane was yellowish-white in appearance without active neovascularization, mainly located on the surface of the optic disc and/or around the vascular arcade. The fibroproliferative membrane was distributed in a circular shape in some patients (Fig. 1); (5) OCT showed that the fibroproliferative membrane stretched the macula, resulting in macular edema (Fig. 2), and even macular detachment; (6) TRD was limited, mostly located around the vascular arcade. Thirty-three eyes (82.5%) were accompanied by limited TRD. Macula was involved in 9 eyes (22.5%); (7) The mid-peripheral retina was pale, and mostly accompanied by small branch artery and vein occlusion. Thirty-one eyes (77.5%) were accompanied by small branch retinal artery and vein occlusion.

Features of IPDR in vitrectomy: (1) The incidence of complete posterior vitreous detachment (PVD) was low. Partial PVD occurred in 28 eyes (70%), and the fibroproliferative membrane adhered closely to the posterior vitreous cortex and retina around the optic disc and vascular arcade. PVD was not occurred in 12 eyes (30%), and the fibroproliferative membrane was integrated with the posterior vitreous cortex, and adhered closely to the retina. (2) It was relatively difficult to completely remove the fibroproliferative membrane during the operation, and iatrogenic retinal break was extremely prone to occur. Fourteen eyes (35.0%) occurred iatrogenic retinal break during the operation. Silicone oil infusion was performed in 8 eyes. C3F8 infusion was performed in 6 eyes. (3) The optic disc was pale, and the mid-peripheral retina was thin. Clinical features of IPDR and intraoperative findings are depicted in Table 2.

Postoperative visual acuity in one patient worsened from the preoperative status, two patients were lost to follow-up and all others improved or were stable. The median LogMAR of BCVA was 0.92(Snellen equivalent of 20/167)at the end of follow-up, which was significantly improvement compared with preoperative BCVA ($Z=-3.782$, $P = 0.000$).

Table 1
Demographic Data and Clinical Characteristics in Study Patients

Clinical features	IPDR
Gender (female, %)	12(57.1%)
Mean age at surgery (years)	55.5 ± 9.9
Mean Diabetic duration (years)	12.4 ± 5.7
Mean preoperative PRP (years)	1.6 ± 1.1
HbA1C (%)	7.4 ± 1.0
Median BCVA, Log MAR (Snellen)	
Initial	1.0(20/200)
Final	0.92(20/167)
PRP: panretinal photocoagulation	

Table 2
Clinical features and intraoperative findings of IPDR

Clinical features and intraoperative findings	Total
Bilateral incidence	19(90.5%)
Small BRVO/BRAO	31(77.5%)
TRD	33(82.5%)
Macular detachment	9(22.5%)
PVD	28(70%)
Iatrogenic retinal breaks	14(35.0%)
Tamponade	
Silicone oil infusion	8
C3F8 infusion	6
BRVO: branch vein occlusion; BRAO: branch retinal artery occlusion; TRD: tractional retinal detachment; PVD□posterior vitreous detachment.	

4. Discussion

All patients in this study were diagnosed with type 2 diabetes by the department of endocrinology. The average diabetes duration was 12.7 years, and all the lesion eyes met the inclusion criteria to ensure reliable case diagnosis and credible observation results.

PDR mostly manifests as fresh vitreous and retinal hemorrhage, fibroproliferative membrane with active neovascularization and/or TRD clinically.

We found that a small number of PDR patients had relatively "quiet" fundus performance. In order to distinguish it from traditional PDR, we defined this type of PDR with "quiet" fundus as IPDR. Combined with the preoperative examination and intraoperative observation, we found it has the following characteristics:(1)All occurred after PRP treatment;(2)No fresh vitreous and retinal hemorrhage;(3)The fibroproliferative membrane was yellowish-white in appearance without active neovascularization, mainly located on the surface of the optic disc and/or around the vascular arcade;(4)TRD was limited, and mostly located around the optic disc and/or vascular arcade;(5)The optic disc was pale. The mid-peripheral retina was thin, and mostly accompanied by small branch artery and vein occlusion;(6)The incidence of PVD was low. The vitreous and retina adhered closely. It was relatively difficult to completely remove the fibroproliferative membrane during the operation, and iatrogenic retinal break was extremely prone to occur.

Non-proliferative diabetic retinopathy (NPDR) often develops slowly. However, PDR develops rapidly due to the formation of neovascularization. The fundus performance of PDR is active. But, the fundus performance of IPDR is relatively quiet. We consider the reasons as follows: (1) HbA_{1c} is proposed as a medium and long-term measure of average glycemia, and it is a serious risk factor for DR. Strict control of glycemia can delay the development of DR[10, 11].

Patients in this study had a relatively long history of diabetes and had rich experience in controlling glycemia.

The result of HbA_{1c} measurement showed that the patient's long-term glycemic control is relatively ideal. Therefore, the progress of IPDR was relatively slow; (2) Panretinal laser photocoagulation is an effective method for treating DR. Melanosomes located within the retinal pigment epithelium (RPE) absorb the laser energy that causes a thermal injury and coagulates the adjacent photoreceptors and RPE cells. As photoreceptors are metabolically the most active cells in the retina with high oxygen consumption, photocoagulation lowers the metabolic load and reduces the ischemia and ischemia-driven angiogenic substances[12]. Photocoagulation plays an important role in controlling or delaying the development of DR[13, 14]. In this study, all eyes were treated with PRP for an average of 1.6 years before surgery, which effectively alleviated the hypoxia and ischemia of the retina; (3) The occlusion of small branch arteries can cause ischemia and necrosis of retinal inner cells, and PRP can also make the neurosensory retina thin due to the damaged retinal cells including photoreceptors and ganglion cells [12]; These factors lead to thinning of the retinal tissue and reducing oxygen demand so that the oxygen demand and oxygen supply of the retina reach a relatively balance state. During the operation, we found that the retinal

tissues in the middle and periphery of the IPDR eyes were relatively thin, which further confirmed the hypothesis.

The vitreous adhered tightly to the retina in the eyes of IPDR, and the vitrectomy was relatively difficult, which easily induced iatrogenic retinal break. All patients in this study were performed by surgeons with more than 15 years of experience in vitreoretinal surgery, 14 eyes (35%) still occurred iatrogenic retinal break when the retinal fibroproliferative membrane was removed. Considering that the fundus performance of IPDR is relatively quiet, we suggest that vitrectomy for such patients should be performed in accordance with the principle of minimal quantification. During the operation, we just need to remove the opaque vitreous, cut off the proliferation cord and relieve the local traction, it is not necessary to completely remove the fibroproliferative membrane to minimize retinal damage and avoid iatrogenic retinal break; If iatrogenic retinal break occurs inadvertently during the operation, we should remove fully the fibroproliferative membrane, and select the tamponade (silicone oil or C3F8) according to the condition. Considering that all the eyes in this study had been treated with PRP before surgery, and the retina had no obvious ischemia and hypoxia, if there was no iatrogenic retinal break, retinal photocoagulation was not performed, but if it occurred, photocoagulation was performed only on the edge of the break to block it.

The BCVA at the end of follow-up after vitrectomy was improved compared with that before surgery. However, postoperative visual acuity in one patient worsened from the preoperative status, two patients were lost to follow-up and all others improved or were stable. The main reasons for no improvement of visual acuity after the vitrectomy in some patients are the atrophy and thinning of the retina of the lesion eyes and the long-term macular tractional detachment.

Due to the relative unsatisfactory prognosis of IPDR and the difficulty of surgery, surgeons with rich experience in vitreoretinal surgery can consider vitrectomy for patients after fully communicating with patients and obtaining the patients' consent.

The limitations of this study include its limited sample size and retrospective nature. Also, it lacks controlled observation results of long-term non-surgical treatment in IPDR. However, because of the limited previously published reports in this field, this study provides important observations and insights on the characteristics of IPDR and the efficacy of vitrectomy.

5. Conclusion

In summary, the fundus performance of IPDR is relatively "quiet" and characteristic. Vitrectomy can improve the vision of some patients, but the operation is relatively difficult. It can be performed by surgeons with rich experience in vitreoretinal surgery in accordance with the principle of minimal quantification. Future large-scale studies that include different treatment methods are necessary to further evaluate the progress and prognosis of IPDR.

Abbreviations

IPDR Inactive proliferative diabetic retinopathy

BCVA Best-corrected visual acuity

PRP Panretinal photocoagulation

VH Vitreous hemorrhage

TRD Tractional retinal detachment

OCT Optical coherence tomography

PPV Pars plana vitrectomy

LogMAR Logarithm of minimal angle of resolution

FFA Fundus fluorescein angiography

PVD posterior vitreous detachment

NPDR Non-proliferative diabetic retinopathy

RPE retinal pigment epithelium

Declarations

Ethics approval and consent to participate

This study adhered to the tenets of the Helsinki Declaration and was approved by ethics committee of Tianjin Medical University Eye Hospital. Written informed consent was obtained from all patients.

Consent for publication

Consent for publication has been obtained.

Availability of data and materials

The data used and analyzed during the current study are available from the corresponding author on reasonable request.

Competing interests

The authors declare that they have no competing interests.

Funding

This study was funded by the Science & Technology Development Fund of Tianjin Education Commission for Higher Education. (No. 2017KJ215)

Authors' contributions

AWT and ZQ participated in data collection/ analysis and drafted the manuscript. HJD and ZLL conceived the idea of the study, designed the study and revised the manuscript critically. All authors read and approved the final manuscript.

Acknowledgements

Not applicable.

References

1. Antonetti DA, Klein R, Gardner TW: Diabetic retinopathy. *The New England journal of medicine* 2012, 366(13):1227-1239.
2. Tamaki K, Usui-Ouchi A, Murakami A, Ebihara N: Fibrocytes and Fibrovascular Membrane Formation in Proliferative Diabetic Retinopathy. *Invest Ophthalmol Vis Sci* 2016, 57(11):4999-5005.
3. Belhassan S, Daoudi R: [Proliferative diabetic retinopathy: dreaded stage leading to blindness]. *The Pan African medical journal* 2014, 17:124.
4. Liao M, Wang X, Yu J, Meng X, Liu Y, Dong X et al: Characteristics and outcomes of vitrectomy for proliferative diabetic retinopathy in young versus senior patients. *BMC ophthalmology* 2020, 20(1):416.
5. Guthrie G, Magill H, Steel DH: 23-gauge versus 25-gauge vitrectomy for proliferative diabetic retinopathy: a comparison of surgical outcomes. *Ophthalmologica Journal international d'ophtalmologie International journal of ophthalmology Zeitschrift fur Augenheilkunde* 2015, 233(2):104-111.
6. Wilkinson CP, Ferris FL, 3rd, Klein RE, Lee PP, Agardh CD, Davis M et al: Proposed international clinical diabetic retinopathy and diabetic macular edema disease severity scales. *Ophthalmology* 2003, 110(9):1677-1682.
7. Hsu YJ, Hsieh YT, Yeh PT, Huang JY, Yang CM: Combined Tractional and Rhegmatogenous Retinal Detachment in Proliferative Diabetic Retinopathy in the Anti-VEGF Era. *J Ophthalmol* 2014, 2014:917375.
8. Shroff CM, Gupta C, Shroff D, Atri N, Gupta P, Dutta R: BIMANUAL MICROINCISION VITREOUS SURGERY FOR SEVERE PROLIFERATIVE DIABETIC RETINOPATHY: OUTCOME IN MORE THAN 300 EYES. *Retina (Philadelphia, Pa)* 2018, 38 Suppl 1:S134-s145.
9. Alberti KG, Zimmet PZ: Definition, diagnosis and classification of diabetes mellitus and its complications. Part 1: diagnosis and classification of diabetes mellitus provisional report of a WHO consultation. *Diabetic medicine : a journal of the British Diabetic Association* 1998, 15(7):539-553.

10. Nordwall M, Abrahamsson M, Dhir M, Fredrikson M, Ludvigsson J, Arnqvist HJ: Impact of HbA1c, followed from onset of type 1 diabetes, on the development of severe retinopathy and nephropathy: the VISS Study (Vascular Diabetic Complications in Southeast Sweden). *Diabetes Care* 2015, 38(2):308-315.
11. Kim YJ, Kim JG, Lee JY, Lee KS, Joe SG, Park JY et al: Development and progression of diabetic retinopathy and associated risk factors in Korean patients with type 2 diabetes: the experience of a tertiary center. *Journal of Korean medical science* 2014, 29(12):1699-1705.
12. Eren S, Ozturk T, Yaman A, Oner H, A OS: Retinal Nerve Fiber Layer Alterations After Photocoagulation: A Prospective Spectral-Domain OCT Study. *The open ophthalmology journal* 2014, 8:82-86.
13. Chhablani J, Mathai A, Rani P, Gupta V, Arevalo JF, Kozak I: Comparison of conventional pattern and novel navigated panretinal photocoagulation in proliferative diabetic retinopathy. *Invest Ophthalmol Vis Sci* 2014, 55(6):3432-3438.
14. Evans JR, Michelessi M, Virgili G: Laser photocoagulation for proliferative diabetic retinopathy. *The Cochrane database of systematic reviews* 2014, 2014(11):Cd011234.

Figures

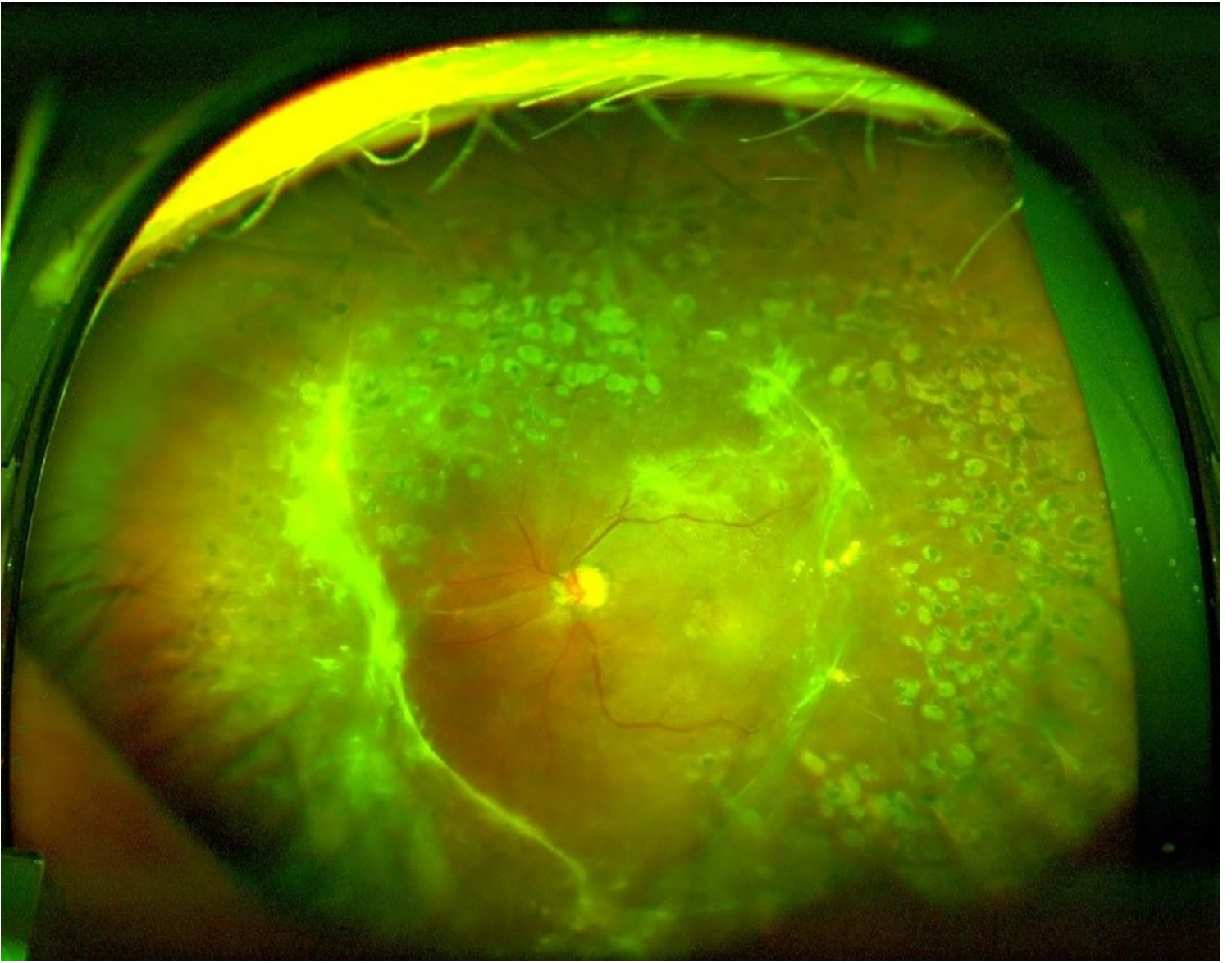


Figure 1

Fundus photograph of IPDR: the eye underwent panretinal photocoagulation, no fresh vitreous and retinal hemorrhage and active neovascularization; The fibroproliferative membrane was yellowish-white in appearance.

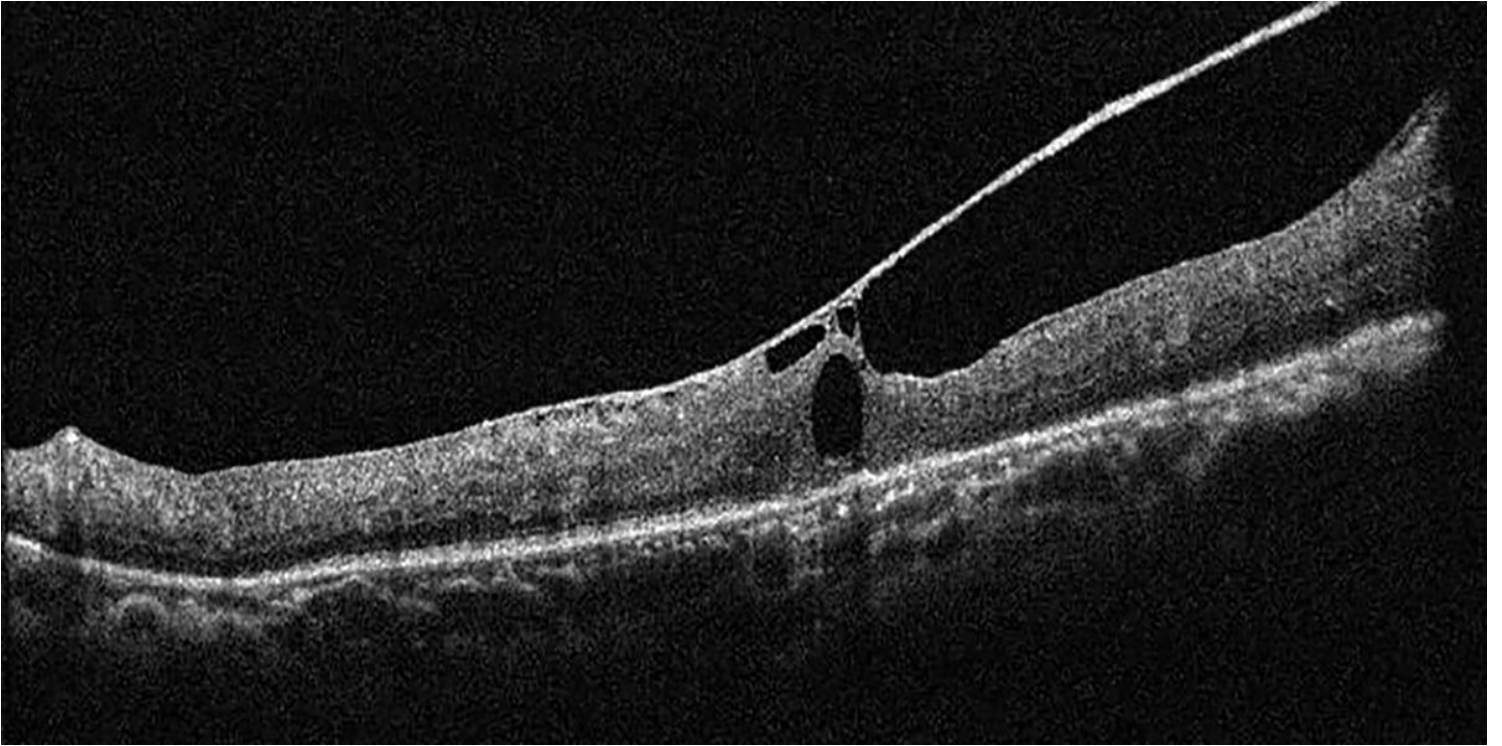


Figure 2

OCT image of IPDR: OCT showed that the fibroproliferative membrane stretched the macula, resulting in macular edema.