

# Reconstruction of mandible defect with folded free fibular flap

**Ning Gao**

First Affiliated Hospital of Zhengzhou University

**Kun Fu**

First Affiliated Hospital of Zhengzhou University

**Jinghua Cai**

First Affiliated Hospital of Zhengzhou University

**Hao Chen**

First Affiliated Hospital of Zhengzhou University

**Wei He** (✉ [heweizhengda@163.com](mailto:heweizhengda@163.com))

First Affiliated Hospital of Zhengzhou University

---

## Research Article

**Keywords:** Mandibular defects, free fibular flap, mandibular ameloblastoma, oral defects, Quality of Life

**Posted Date:** March 10th, 2021

**DOI:** <https://doi.org/10.21203/rs.3.rs-257681/v1>

**License:** © ⓘ This work is licensed under a Creative Commons Attribution 4.0 International License. [Read Full License](#)

---

# Abstract

Mandibular defects directly affect a patient's facial features, masticatory and articulation. This study has analyzed 41 patients with mandibular ameloblastoma who underwent a partial mandibulectomy and reconstruction by folding the free fibular flap. In the preoperative and postoperative (6 months and 24 months after surgery), the QOL of these patients was assessed by using the University of Washington Quality of Life Questionnaire (UW-QOL) and the medical outcome study short form-36 (SF-36) questionnaires. The sf-36 survey showed that body pain, general health, and health changes decreased significantly at 6 months after surgery, but the mean score at 24 months after surgery all exceeded that shown before surgery. The UW-QOL survey showed that chewing, speech and taste had significantly changed in the 6 months after the surgery, and the difference was statistically significant 24 months after the surgery. The total score of the patients almost recovered to the preoperative level at 24 months after the surgery. The folded free fibular flap is an ideal selection for the reconstruction of oral defects after cancer resection. In using this flap, the basic social need of patients after surgery can be satisfied. The folded free fibular flap can improve the patients' QOL.

## Introduction

The mandibular defects directly affect the facial features, masticatory and articulation functions of the patients. Since 1989, when Hidalgo first reported success in using the free fibular flap to repair mandibular defects, the clinical application of this surgical technique to repair damage associated with tumor removal has seen further improvement<sup>1</sup>. With the constant improvement of the microsurgical technique<sup>2</sup>, as well as 3D printing<sup>3</sup>, the upgrade of free fibular flap surgical technique offers increasingly extensive applications in the repair of the mandibular defects<sup>4</sup>. However, the biggest disadvantage the height of the reconstructed mandible cannot meet the needs of implant repair<sup>5</sup>, the mucosal scar on the surface of the single fibular is thick<sup>6</sup>, which not only increases the difficulty of imprinting<sup>7</sup>, but also easily produces peri-implant inflammation<sup>8</sup>. The folded fibular flap perfectly restores the height of the alveolar ridge, avoiding the imbalance of the coronal root ratio in implant repair.

With the transformation of the biomedical model into the bio-psycho-social medical model, the criteria for evaluating the effectiveness of tumor treatments are no longer restricted purely survival rate and biological indicators such as organ function reconstruction<sup>9</sup>, but now also encompass improvements made to the patients quality of life (QOL)<sup>10</sup>. In this study, The University of Washington Quality of Life (UW-QOL) and the Short Form (SF-36) questionnaires were used to evaluate and analyze the QOL of patients with tumor removal related tissue defect repaired with the folded fibular flap technique. This study provides a basis for the formulation of a comprehensive treatment plan, the selection of surgical methods and repair methods, the postoperative functional rehabilitation and the possible psychological interventions resulting from the use of the fibular flap in the reconstruction of maxillofacial defects.

## Results

All 41 cases undergoing this procedure survived. 39 patients healed in the first stage of healing, and two developed infection, which healed after antibiotic treatment and local dressing change. The shaping time for the fibular was 43 ~ 90min, with an average of  $(61 \pm 12)$  min, and the total operation time was 314 ~ 406min, with an average of  $(356 \pm 22)$  min. There were 40 cases of primary healing in the donor area and 1 case of scar healing after partial skin necrosis. There was no tenderness in the temporomandibular joint area and the degree of opening was 3.1-3.9cm in 39 patients. Implants were implanted 6 to 9 months after surgery, and the porcelain crown was repaired 3 to 4 months later. The implant bone was well combined, the occlusal relationship was restored, and the functions of speech, chewing and swallowing were returned to normal. All patients recovered the natural curvature, height and occlusal relationship of the defect area of the mandible, and no obvious abnormalities were found in the operative area. There were no obvious

complications in the donor area, the lower limbs could bear weight, walking was not affected, and the donor area of the legs had no obvious dysfunction. All 41 patients completed the survey, and the completion rate was 100%.The general situation is shown in Table 1.

Table 1  
Details of patients

Variables	Cases n(%)
Age(years)	
< 50	29(70.73)
50 and over	12(29.27)
Sex	
Male	26(63.41)
Female	15(36.59)
Primary sites of tumor	
Body	19(46.34)
Body, angle	12(29.27)
Body, angle, ramus	10(24.39)
Clinical type	
Solid	32(78.05)
Unicystic	9(21.95)
Radiographic appearance	
Unilocular	14(34.15)
Multilocular	27(65.85)
Repair range	
Unilateral body	10(24.39)
Unilateral body and ramus	28(68.29)
Bilateral body	3(7.32)
Recipient Artery	
Facial artery	37(90.24)
Superior thyroid artery	4(9.76)
Recipient vein	
Unidentified branch of internal jugular vein	32(78.05)
External jugular vein	9(21.95)

SF-36 survey results.

The specific score of sf-36 is shown in Table 2. The Physical role decreased significantly after the surgery. Although there was a significant improvement in the 24 months after the surgery compared with the 6 months after the surgery ( $t = -5.134$ ,  $p = 0.000$ ), it still could not return to the preoperative level ( $t = 11.685$ ,  $p = 0.003$ ). Body pain ( $54.54 \pm 8.10$ ), general health ( $55.27 \pm 7.54$ ), and health changes ( $58.29 \pm 9.60$ ) decreased significantly at 6 months after surgery, but the mean score at 24 months after surgery all exceeded that before surgery.

Table 2  
Means of scores of items and scales of SF-36 Questionnaire

Domains	Mean $\pm$ standard deviation			Comparison of t value (P value) at different time		
	Preoperative	6 mo	24 mo	Preoperative&6 mo	Preoperative&24 mo	6 mo&24 mo
physiological function	67.88 $\pm$ 5.77	48.34 $\pm$ 12.05	69.54 $\pm$ 7.29	9.365(0.000)	-9.635(0.002)	-1.142(0.282)
Physical role	80.05 $\pm$ 9.41	44.90 $\pm$ 16.98	59.41 $\pm$ 6.27	11.594(0.001)	11.685(0.003)	-5.134(0.000)
Body pain	72.00 $\pm$ 10.70	54.54 $\pm$ 8.10	82.44 $\pm$ 12.90	8.333(0.001)	-3.989(0.000)	-11.727(0.000)
General health	72.85.4 $\pm$ 9.50	55.27 $\pm$ 7.54	83.17 $\pm$ 12.07	9.285(0.018)	-4.300(0.053)	-12.554(0.000)
Vitality	82.44 $\pm$ 5.20	77.78 $\pm$ 6.60	80.41 $\pm$ 3.74	3.552(0.366)	2.024(0.163)	-2.224(0.036)
Social function	84.00 $\pm$ 5.19	76.07 $\pm$ 7.40	81.61 $\pm$ 4.07	5.616(0.066)	2.321(0.107)	-4.197(0.002)
Emotional role	82.78 $\pm$ 4.23	74.83 $\pm$ 6.66	82.39 $\pm$ 4.07	6.457(0.006)	0.426(0.998)	-6.204(0.005)
Psychological health	80.05 $\pm$ 4.01	72.15 $\pm$ 7.97	81.66 $\pm$ 4.37	5.674(0.000)	-1.738(0.415)	-6.701(0.000)
Health change	77.95 $\pm$ 3.81	58.29 $\pm$ 9.60	83.37 $\pm$ 4.83	12.188(0.000)	-5.637(0.037)	-14.939(0.002)
Total	700.00 $\pm$ 32.10	557.41 $\pm$ 49.24	704.00 $\pm$ 31.53	15.533(0.000)	-0.569(0.893)	-16.053(0.000)

At 24 months after the operation, vitality ( $80.41 \pm 3.74$ ), social function ( $81.61 \pm 4.07$ ), emotional role ( $82.39 \pm 4.07$ ), psychological health ( $81.66 \pm 4.37$ ) and total score ( $704.00 \pm 31.53$ ) all returned to the preoperative level, which was statistically significant compared with the 6 months after the operation, but there was no significant difference compared with the preoperative level.

#### UW-QOL survey results.

The specific score of UW-QOL is shown in Table 3. The items with significant changes after 6 months were chewing ( $56.68 \pm 7.23$ ), speech ( $54.54 \pm 7.7$ ) and taste ( $62.29 \pm 10.15$ ), which were significantly improved 24 months after the surgery and the difference was statistically significant. Saliva decreased slightly ( $80.76 \pm 3.35$ ) 6 months after surgery, but quickly returned to the preoperative level ( $81.59 \pm 4.06$ ).

Table 3  
Means of scores of items and scales of University of Washington quality of life questionnaire.

Domains	Mean $\pm$ standard deviation			Comparison of t value (P value) at different time		
	Preoperative	6 mo	24 mo	Preoperative&6 mo	Preoperative&24 mo	6 mo&24 mo
Chewing	66.17 $\pm$ 2.89	56.68 $\pm$ 7.23	66.34 $\pm$ 2.83	7.806(0.000)	-0.270(0.793)	-7.967(0.000)
Swallowing	64.17 $\pm$ 3.47	61.51 $\pm$ 3.61	64.78 $\pm$ 3.39	3.401(0.982)	-0.804(0.791)	-4.225(0.787)
Speech	63.76 $\pm$ 2.91	54.54 $\pm$ 7.7	63.9 $\pm$ 2.9	9.802(0.000)	-0.223(0.596)	-11.675(0.000)
Taste	81.92 $\pm$ 4.33	62.29 $\pm$ 10.15	74.66 $\pm$ 9.83	11.385(0.000)	4.331(0.001)	-5.601(0.693)
Saliva	81.46 $\pm$ 6.51	80.76 $\pm$ 3.35	81.59 $\pm$ 4.06	0.619(0.004)	-0.102(0.056)	-1.009(0.114)
Total	359.68 $\pm$ 10.39	315.78 $\pm$ 20.25	354.12 $\pm$ 11.75	12.354(0.000)	0.402(2.271)	-10.489(0.001)

There was no significant change in the swallowing function after the surgery, and the total score of the patients almost recovered to the preoperative level at 24 months after the surgery ( $t = 2.271$ ,  $p = 0.402$ ).

## Discussion

The mandibular defects directly affect the facial features, masticatory and articulation functions of the patients<sup>11</sup>. This damage also restricts the daily life and social activities of the patients to different degrees, and indirectly affects the psychological state and social activities of the patients<sup>12</sup>. Traditional indicators for the evaluation of oral diseases do not consider the impact of diseases on the quality of life of patients. With the change of medical model, it has become a goal that surgeons pursue to ensure patients receive better quality of life (QOL) while prolonging the survival of tumor patients through medical intervention<sup>13</sup>.

With the constant improvement of the microsurgical technique, as well as 3D printing, the upgrade of free fibular flap surgical technique offers increasingly extensive applications in the repair of the mandibular defects<sup>14</sup>. The fibular flap is a kind of compound flap, it has the advantage of being similar to the fibular flap, but also has advantages over the fibular skin flap. It can repair not only bone tissue defects, but also soft tissue defects. When looking to repair the upper and lower jaw and adjacent tissue defects it is the tissue flap of choice. However, the biggest disadvantage when using the fibular flap is that the height is only 1.3-1.5cm. Therefore, the height of the reconstructed mandible cannot meet the needs of implant repair. In addition, the mucosal scar on the surface of the single fibular is thick, which not only increases the difficulty of imprinting<sup>15</sup>, but also easily produces peri-implant inflammation (Fig. 1). Alternatively, the folded fibular flap perfectly restores the height of the alveolar ridge, avoiding the imbalance of the coronal root ratio in implant repair<sup>16</sup>. The thin crest mucosa reduces the incidence of peri-implant inflammation, which greatly improved the sample patient groups chewing function, language expression, and further increased the patient's confidence. All flaps of the selected cases in this group survived. This included the 2 patients presenting with flap crisis 12 to 24 hours after the operation due to blocked venous reflux due to poor drainage. The flap remained completely viable following efforts to improve drainage, which involved the removal of blood clots at the bottom of the mouth and microthrombus at the anastomosis<sup>17</sup>.

After fibular transplantation, more than 90% of the follow-up patients reported that the discomfort of lower limb pain, weakness, numbness and other discomfort gradually disappeared after 6 months, and the feeling and function of lower limb movement were basically normal, without affecting daily activities, which indicated that the flap resection of the donor area had almost no effect on the mobility of the patients.

The sf-36 results showed that: all functions of the patients recovered after the surgery, but the body still could not return to the preoperative level 24 months after the surgery, the patients still felt slight discomfort in the lower limbs, itching in the scar, and even some patients still could not fully accept the fact that the fibular flap was placed in the maxillofacial region. Body pain, general health and health changes decreased significantly after the surgery, which was related to the recovery of the lower limbs of the patients. With the further exercise of function and the restoration of implant teeth, the average score 24 months after the surgery was higher than that before the surgery, and the difference was statistically significant. (3) physiological function, vitality, social function, emotional role, mental health and the total score decreased significantly three months after the operation, which was significantly related to the surgical trauma and the self-discomfort of the patients, but recovered to the preoperative level 24 months after the operation.

UW-QOL results showed that: (1) with the passage of time, the oropharyngeal function of the patients after the operation was significantly improved, especially after the implant was used to repair the dentition defect, the chewing and language of the patients were substantially changed; (2) some patients received damage to the lingual nerve during the operation, postoperative tongue numbness and a decline in taste. This generally recovered three months following the operation; (3) since the submandibular gland of the affected side will be routinely removed during the operation, there will be a temporary decrease in the amount of saliva produced after the operation, but with the compensation of other glands, the patient's symptoms decreased significantly; Results from the survey indicate that the impact on swallowing as a result of this surgery is not significantly adverse.

Emotional factors are the most influential issues for cancer patients<sup>18</sup>. We found that while the patient recovered in terms of physiological function, social function and family status, the emotional status could not return to the normal level 6 months after the surgery<sup>19</sup>. The low scores of patients in mental and mental health are largely related to the psychological reality of patients' inability to accept jaw resection and their inability to adapt to changes in basic life functions such as speech and eating after surgery<sup>20</sup>. Patients are always worried about the recurrence of the tumor and the uncertainty of the future<sup>21</sup>, so they often experience symptoms such as irritability, fatigue, insomnia, pain, diarrhea and constipation<sup>22-25</sup>. This indicates that the emotional damage caused by the tumor to patients is more serious and long-lasting<sup>26</sup>. Patients think they are sicker than others and that their health is deteriorating<sup>27</sup>. Therefore, psychological and emotional rehabilitation treatment for patients is very important<sup>28</sup>.

## Conclusion

To sum up, folding the fibular flap can not only repair the defects of soft tissue and bone tissue<sup>29</sup>, but also restore the height of the alveolar ridge to, avoid the imbalance of crown and root ratio after implantation and reduce the occurrence of peri-implant inflammation, so that a true functional reconstruction can be realized. At the same time, when doctors choose treatment options for patients, they should not only consider the cure rate and survival rate of the tumor<sup>30</sup>, but also cannot avoid the patient's QOL. The number of cases in this study is small and the observation time is limited, so a long-term QOL evaluation is incomplete yet, and further research being needed.

## Materials And Methods

**Ethics approval.**

Informed consent was obtained from all patients and all procedures performed in the study involving human participants were in accordance with the ethical standards of the institutional and/or national research committee (The First Affiliated Hospital of Zhengzhou University Institutional review board; protocol 2012-KY-230) and with the 1964 Helsinki declaration and its later amendments or comparable ethical standards.

### **Patients.**

Forty-one cases with mandibular ameloblastoma underwent partial mandibulectomy and repair utilizing the fibular flap technique.

This was performed in the oral and maxillofacial surgery department of the first affiliated hospital of Zhengzhou university from October 2012 to July 2017.

There were 26 males and 15 females. The age ranged from 18 to 58 years old, with an average of 34.8 years old. The inclusion criteria were as follows: (1) preoperative design was carried out using 3D printing technology and digital technology, intraoperative resection of the diseased mandible was performed, and the fibular flap technique was used for reconstruction and repair at the same time. (2) No serious complications after the operation. (3) No recurrence of the primary disease. (4) Implant repair was performed at 6–9 months after surgery. The observation period was longer than 24 months.

### **Sequential treatment steps.**

Pre-bending preparation of reconstructed titanium plate was completed preoperatively using digital technology and 3D printing technology. The operation was carried out in two groups at the same time: one group received a partial mandibulectomy according to the lesion range, retaining the articular disc. The condyle was retained depending on the situation with work on the arteriovenous system carried out in the receiving area. In the other group, the Henry approach was adopted in the posterolateral part of the calf, and the fibular flap was made conventionally. Depending on the defect range, the skin island and fibular length of the free fibular composite flap and the required muscles were designed according to the preoperative digital design scheme. The fibular flap was fixed with a Swiss sinins AO 2.0 prefabricated titanium plate before the pedicle fracture. The branches of the peroneal artery and the external carotid artery were manually sutured with 8 – 0 Prolene line, and then the peroneal vein was anastomosed with the internal (external) jugular vein with a microvascular anastomosis device to reconstruct blood circulation. The Straumann implant system was used to implant 4.1 standard neck implants at the level of soft tissue through fixed points and stage by stage holes. The length was 10-14mm and the smooth neck was located at the top of the alveolar crest. Porcelain crown restoration was carried out 3 to 4 months after implantation (Fig. 2).

## **QUESTIONNAIRES AND COLLECTION**

SF-36 and UW-QOL was made available in Chinese and has been validated for a Chinese population.

(1) SF -36 is a widely used QOL measurement tool to assess the impact of overall health status on QOL. This questionnaire has been used by scholars to evaluate the QOL of cancer patients in China. It mainly includes 9 aspects of physiological function, body pain, physical role, general health, vitality, emotional role, social function, health change and psychological health. The maximum score of each item is 100. The higher the score is, the better the status is.

(2) UW-QOL: UW-QOL is a self-administered questionnaire that designed for patients with head and neck cancer. Internationally it is one of the most commonly used head and neck cancers quality of life questionnaires in use. It includes pain, appearance, activity, entertainment, swallowing, chewing, language, mouth opening, taste, saliva, mood, anxiety, and overall well-being. The domains are scored on a scale ranging from 0 (worst) to 100 (best).

Chewing, swallowing, speech, taste and saliva can be used to assess the patient's oral function.

### Assessment methods

SF-36 and UW-QOL questionnaires were used in the survey, and a combination of doctor's examinations and questionnaire was adopted in the methodology. Before the operation, the survey (utilizing both types of assessment questionnaires) was explained to the patients in full detail. The patients were then instructed to fill in the first questionnaire pre op, with the second and third surveys to be filled in at 6 and 24 month post op respectively. A scoring manual provided by the designer of the questionnaire was used for scoring patient symptoms.

## Statistical analysis.

SPSS 20.0 statistical software was used to conduct statistical analysis on the base data of the two groups of patients. Independent sample *t* test was conducted for sf-36 and UW-QOL scores at two time points in each group.

## Declarations

## Competing interests

The authors declare no competing interests.

## Author Contributions

N.G. was involved in the conception, design, and drafting the article. J.H.C., K.F. and H.C. were involved in the analysis and interpretation of data. W.H. was involved in revising the article critically for important intellectual content.

## References

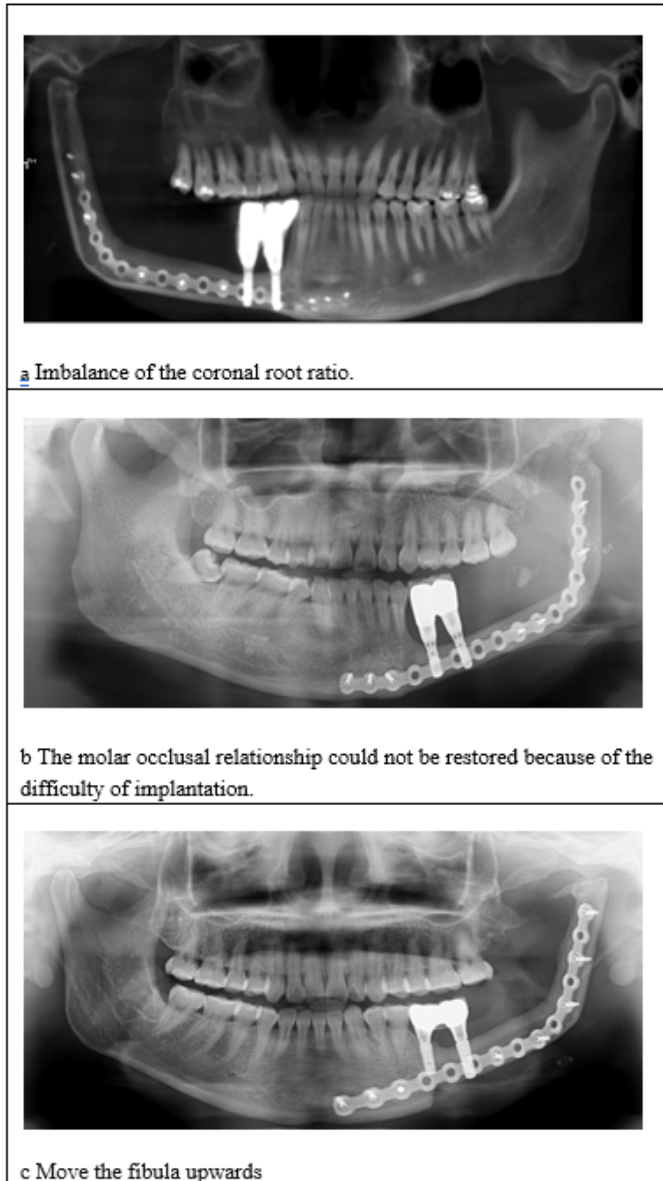
1. Yao, Y. *et al.* Regeneration of the neocondyle after free fibular flap reconstruction of the mandibular condyle. *J Oral Maxil Surg.* **78**, 479–487 (2020).
2. Seruya, M., Fisher, M. & Rodriguez, E. D. Computer-assisted versus conventional free fibular flap technique for craniofacial reconstruction: an outcomes comparison. *Plast Reconstr Surg.* **132**, 1219–1228 (2013).
3. Davey, M., McInerney, N. M., Barry, T., Hussey, A. & Potter, S. Virtual surgical planning computer-aided design-guided osteocutaneous fibular free flap for craniofacial reconstruction: a novel surgical approach. *Cureus.* **11**, e6256(2019).
4. Qu, X. *et al.* Occlusion Guided Double-Barreled Fibular Osteoseptocutaneous Free Flap for Refined Mandibular Reconstruction Aided by Virtual Surgical Planning. *J Craniofac Surg.* **28**, 1472–1476 (2017).
5. Shokri, T., Stahl, L. E., Kanekar, S. G. & Goyal, N. Osseous changes over time in free fibular flap reconstruction. *Laryngoscope.* **129**, 1113–1116 (2019).
6. Pauchet, D., Pigot, J. L., Chabolle, F. & Bach, C. A. Prefabricated fibula free flap with dental implants for mandibular reconstruction. *Eur Ann Otorhinolaryngol Head Neck Dis.* **135**, 279–282 (2018).
7. Barber, B. R. *et al.* Bone-impacted fibular free flap: long-term dental implant success and complications compared to traditional fibular free flap tissue transfer. *Head Neck.* **38**, E1783–7 (2016).
8. Chang, Y. M. *et al.* Outcome of osseointegrated dental implants in double-barrel and vertically distracted fibular osteoseptocutaneous free flaps for segmental mandibular defect reconstruction. *Plast Reconstr Surg.* **134**, 1033–1043 (2014).



9. Vu, D. D. & Schmidt, B. L. Quality of life evaluation for patients receiving vascularized versus nonvascularized bone graft reconstruction of segmental mandibular defects. *J Oral Maxillofac Surg.* **66**, 1856–1863 (2008).
10. Löfstrand, J. *et al.* Quality of Life After Free Fibula Flap Reconstruction of Segmental Mandibular Defects. *J Reconstr Microsurg.* **34**, 108–120 (2018).
11. Barla, M. *et al.* Free vascularised fibular flap harvesting in children: an analysis of donor-site morbidity. *Orthop Traumatol Surg Res.* **103**, 1109–1113 (2017).
12. Halim, A. S. *et al.* Long-term outcome of free fibular osteocutaneous flap and massive allograft in the reconstruction of long bone defect. *J Plast Reconstr Aesthet Surg.* **68**, 1755–1762 (2015).
13. Laraway, D. C. & Rogers, S. N. A structured review of journal articles reporting outcomes using the University of Washington Quality of Life Scale. *Br J Oral Maxillofac Surg.* **50**, 122–131 (2012).
14. Salvatore, B. *et al.* Computer-assisted surgery for reconstruction of complex mandibular defects using osteomyocutaneous microvascular fibular free flaps: Use of a skin paddle-outlining guide for soft-tissue reconstruction. A technical report. *J Cranio Maxill Surg.* **47**, 293–299(2019).
15. Patel, A., Harrison, P., Cheng, A., Bray, B. & Bell, R. B. Fibular reconstruction of the maxilla and mandible with immediate implant-supported prosthetic rehabilitation: jaw in a day. *Oral Maxillofac Surg Clin North Am.* **31**, 369–386 (2019).
16. Chana, J. S. *et al.* Segmental mandibulectomy and immediate free fibular osteoseptocutaneous flap reconstruction with endosteal implants: an ideal treatment method for mandibular ameloblastoma. *Plast Reconstr Surg.* **113**, 80–87 (2004).
17. Wu, H. X. *et al.* Identification of independent risk factors for complications: A retrospective analysis of 163 fibular free flaps for mandibulofacial reconstruction. *J Oral Maxil Surg.* **76**, 1571–1577 (2018).
18. Halim, A. S. *et al.* Long-term outcome of free fibular osteocutaneous flap and massive allograft in the reconstruction of long bone defect. *J Plast Reconstr Aesthet Surg.* **68**, 1755–1762 (2015).
19. Murphy, B. A., Ridner, S., Wells, N. & Dietrich, M. Quality of life research in head and neck cancer: A review of the current state of the science. *Crit Rev Oncol Hematol.* **62**, 251–267 (2007).
20. Cousins, N., MacAulay, F., Lang, H., MacGillivray, S. & Wells, M. A systematic review of interventions for eating and drinking problems following treatment for head and neck cancer suggests a need to look beyond swallowing and trismus. *Oral Oncol.* **49**, 387–400 (2013).
21. Mücke, T. *et al.* Quality of life after different oncologic interventions in head and neck cancer patients. *J Craniomaxillofac Surg.* **43**, 1895–1898 (2015).
22. Li, H. *et al.* Mandibular lingual release versus mandibular lip-split approach for expanded resection of middlelate tongue cancer: A case-control study. *J Craniomaxillofac Surg.* **43**, 1054–1058 (2015).
23. Wang, Y. L., Peng, X. & Luo, Y. Quality-of-life outcomes of the patients with tongue cancer following reconstruction with free forearm flap. *Chin J Stomatol.* **46**, 27–30 (2011).
24. Zhang, X. *et al.* Free Fibula Flap: Assessment of quality of life of patients with head and neck cancer who have had defects reconstructed. *J Craniofac Surg.* **24**, 2010–2013 (2013).
25. Baron, S. *et al.* Fibula free flap in the treatment of mandibular osteoradionecrosis. *Eur Ann Otorhinolaryngol Head Neck Dis.* **133**, 7–11 (2016).
26. Li, X., Zhu, K., Liu, F. & Li, H. Assessment of quality of life in giant ameloblastoma adolescent patients who have had mandible defects reconstructed with a free fibula flap. *World J Surg Oncol.* **12**, 201 (2014).
27. Jarefors, E. & Hansson, T. Functional outcome in 17 patients whose mandibles were reconstructed with free fibular flaps. *J Plast Surg Hand Surg.* **51**, 178–181 (2017).

28. Petrovic, I. *et al.* A Systematic Review of Validated Tools Assessing Functional and Aesthetic Outcomes Following Fibula Free Flap Reconstruction of the Mandible. *Head Neck.* **41**, 248–255 (2019).
29. Yoshimura, H. *et al.* Stereolithographic model-assisted reconstruction of the mandibular condyle with a vascularized fibular flap following hemimandibulectomy: Evaluation of morphological and functional outcomes. *Oncol Lett.* **14**, 5471–5483 (2017).
30. Gemert, J. V. *et al.* Health-related quality of life after segmental resection of the lateral mandible: free fibula flap versus plate reconstruction. *J Craniomaxillofac Surg.* **43**, 658–662 (2015).

## Figures



**Figure 1**

(a) The height of the reconstructed mandible cannot meet the needs of implant repair. (b) The mucosal scar on the surface of the single fibular is thick, which not only increases the difficulty of implanting and imprinting, but also easily

produces peri-implant inflammation. (c) We can move the fibula upwards, but this may result in maxillofacial asymmetry.

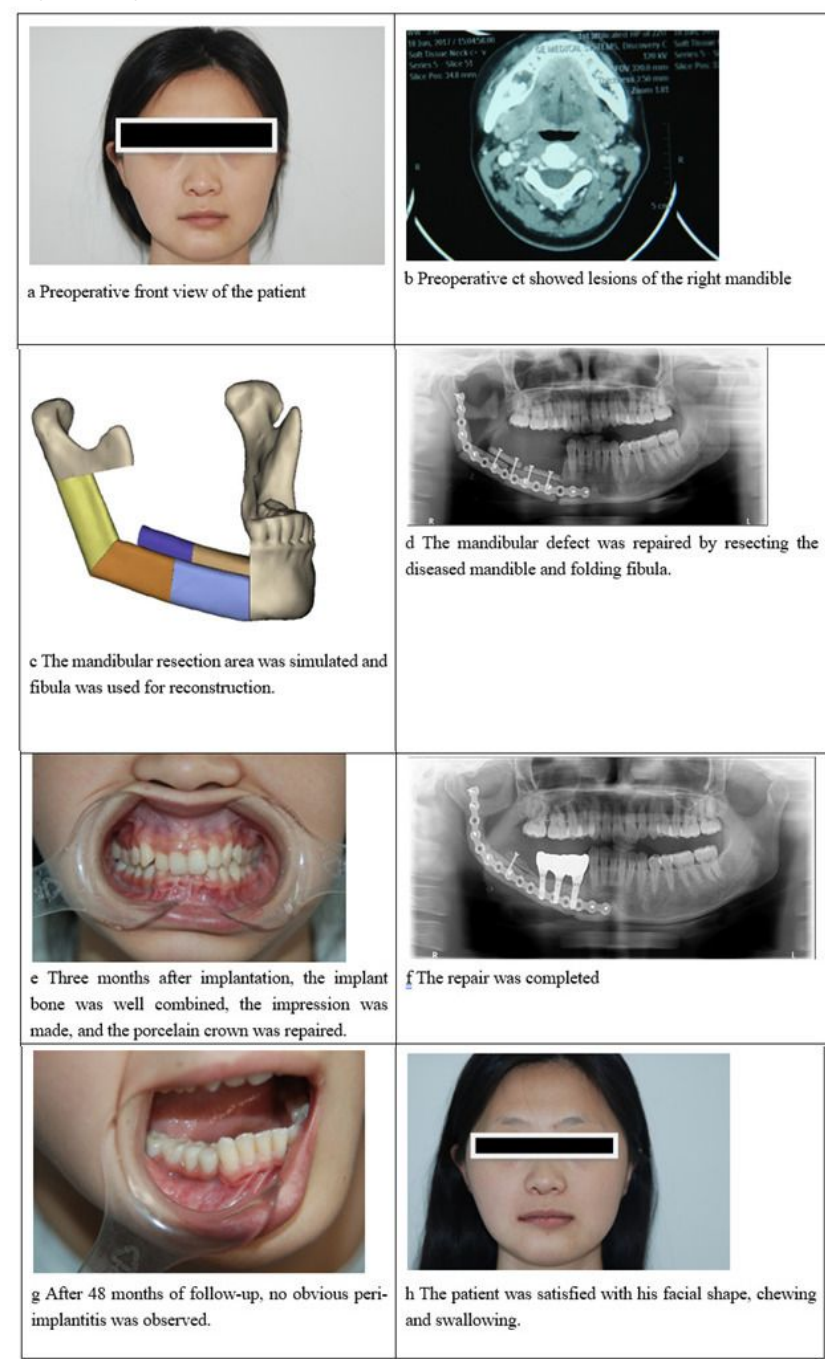


Figure 2

(a) Preoperative front view of the patient. (b) Preoperative CT showed lesions of the right mandible. (c) The mandibular resection area was simulated and fibula was used for reconstruction. (d) The mandibular defect was repaired by resecting the diseased mandible and folding fibula. (e) Three months after implantation, the implant bone was well combined, the impression was made, and the porcelain crown was repaired. (f) The repair was completed (g) After 48 months of follow-up, no obvious peri-implantitis was observed. (h) The patient was satisfied with his facial shape, chewing and swallowing.