

The Spatial Weaving Screw Technique Combined With Minimally Invasive Treatment of Calcaneal Fracture

Yong Zhang

Tongji Hospital, Tongji University School of Medicine

Qiuyan Weng

The Affiliated Hospital of Medical School of Ningbo University

Jianming Chen

Ningbo No.6 Hospital

Yunfeng Yang (✉ dryyfsn@163.com)

Tongji Hospital, Tongji University School of Medicine

Research Article

Keywords: Calcaneus fracture, minimally invasive, 3D printing, screw

Posted Date: March 1st, 2021

DOI: <https://doi.org/10.21203/rs.3.rs-244666/v1>

License: © ⓘ This work is licensed under a Creative Commons Attribution 4.0 International License. [Read Full License](#)

Abstract

Background: The conventional surgical method for calcaneal fractures is the extensile lateral approach to reduce and fix fractures using plates and screws. Unfortunately, this method has been associated with high rates of wound and steel plate complications. Similarly, it is still difficult for minimally invasive surgical methods to achieve effective reduction and internal fixation. Therefore, this article proposes a new method of lateral minimally invasive incision combined with percutaneous, screw-only fixation and the screws are individually knitted according to the type of fracture.

Methods: Between October 2015 and October 2019, 31 patients who underwent the spatial weaving screw technique combined with minimally invasive were recruited. Any operative complication was recorded. The clinical results were evaluated based on pre-operative X-rays (axial and lateral calcaneus), CT and three-dimensional reconstruction, AOFAS, VAS during follow-up.

Results: Bone healing was achieved in all patients, with an average healing time of 7.3 ± 4.2 ml weeks. No serious complications occurred after operation, no case of reduction failure or screw displacement were found. The evaluation of the posterior subtalar and calcaneocuboid articular surface respectively showed 80.6% and 90.3% cases got excellent and good reduction. The average AOFAS score was 89.5 at the end of 1 year after the operation, the mean VAS in our series was 2.4 at the last follow-up.

Conclusion: Combined with minimally invasive screw spatial weaving technique, displaced Sanders type II and III can be successfully treated displaced Sanders type II and III fractures. The method allows for adequate reduction and effective fixation by screws. It also clearly avoids the major wound complication problems, improve the accuracy of reduction and implantation, simplify surgical procedure.

Background

The calcaneus plays an important role in the body's weight bearing and walking. The mechanism of calcaneal fracture is usually high energy axial load injury caused by a fall from a height or a road traffic accident, 65-70% of calcaneal fractures involve displacement of the subtalar articular surface [1]. The mainstream treatment of the calcaneal fractures involving the displacement of articular surface is surgical intervention [2]. Currently, there is still no standard procedure for surgical treatment of the calcaneus [3]. The surgical treatment of calcaneal fractures is still a challenge to orthopedist [4].

In the past 2 decades, operative treatment using an extensile lateral open approach has grown in popularity. This approach provides excellent exposure of the fracture to reduce by separate the lateral skin flap, it has some advantages in the reduction and fixation of the calcaneus [5]. Nonetheless, the incidence of soft tissue complications is high including skin necrosis, infection, wound dehiscence, and delayed wound healing [6]. In addition, the stress concentration around the steel plate causes internal fixation failure and osteoporosis around the steel plate [7]. Therefore, minimally invasive method is more and more popular for the treatment of calcaneal fracture nowadays [8]. A variety of minimally invasive techniques can reduce the above complications, but there are also some controversies [9,10]. There are three main disadvantages of minimally invasive surgery: 1. Difficulty in achieving accurate reduction of fractures. 2. Difficulty in internal fixation implantation, and inaccurate implant position. 3. The internal fixation of minimally invasive implants cannot provide effective stable fixation. Ebrahimpour A. et al [11]. believed that for treatment of various types of calcaneal fracture percutaneous reduction and screw fixation obtain satisfactory clinical results. Smerek J P et.al [12]. demonstrated that screw fixation of calcaneal fractures had similar strength comparing to that of the standard perimeter plating technique in a cadaver model. However, few scholars have proposed systematic and accurate studies on the theory that whether screws alone can provide enough mechanical strength for calcaneal growth. Therefore, this study attempts to look into the problems by using minimally invasive, 3D printing and spatial weaving screw (SWS) technology.

The purpose of this research: 1. To design a new minimally invasive incision which reduces the injury of important lateral calcaneal structures; 2. To improve the accuracy of minimally invasive incision reduction using 3D technology. 3. To design a percutaneous wove screw internal fixation based on the type of fracture in which the mutually supported structure can provide enough the mechanically stability for the calcaneal fracture healing.

The procedure of the current study: 1. The spatial weaving screw fixation were divided into three categories according to the fixation method. SWS structure should be designed according to the type of fracture and combined with preoperative 3D printing technology preoperative, to improve the accuracy of screw placement. 2. The minimally invasive incision on the lateral calcaneus was performed according to the pre-operative protocol. The screws were implanted percutaneously forming a SWS structure to improve the firmness of screw fixation. 3. Clinical follow up—the clinical outcomes were evaluated, including incision-related complications—the quality of reduction and the stability of internal fixation. the patient's the American Orthopedic Foot and Ankle Society (AOFAS) score and visual analog scale (VAS) score were evaluated.

Methods

This research was reviewed and approved by the Ethics Committee of the Ningbo No. 6 Hospital (No.2018-006). All patients signed the informed consent form, reviewed the written surgical plan and alternative regimen before the procedure.

Inclusion criteria ☐ Unilateral closed calcaneal fracture. ☐ Sander types II and III. ☐ Intra-articular step-off ≥ 2 mm and Depression of the posterior facet of the calcaneus. ☐ Age 18-65.

Exclusion criteria ☐ accompanied by serious injury of other important organs. ☐ The time interval between fracture and operation is more than 4 weeks and it is difficult to fracture reduction. ☐ severe medical diseases cannot tolerate surgery. ☐ Infected or grossly contaminated soft tissue.

Operative technique of SWS fixation

Preoperative CT value data of the calcaneus were imported into MIMICS15.0 software (Materialise Co. Leuven, Belgium) for 3D modeling of the calcaneus, which was used for subsequent surgical simulation and 3D model printing (Fig.2). The virtual 3D model of the calcaneus was reconstructed by MIMICS software. In this model, the displacement of the fracture fragment is measured and virtual reduction is performed to establish the reduction sequence. In addition, according to the direction of fracture line extends, SWS fixation was designed to simulate treating calcaneal fracture. SWS are 3.5mm full-thread screws. The screws are divided into three categories: Sustentacular screw(SS)☐Long axis screw of calcaneal (LAS)☐High axis screw of calcaneal (HAS)☐

Screw method: 1. SS☐The fracture was fixed with 2-3 screws perpendicular to the fracture line, A well-restored lateral subtalar joint was fixed on sustentaculum tali medially which is the relatively stable position (constant fragment)☐ According to the trends of fracture line running, 1-2 screw insert interfragmentary perpendicular to fracture line, the aim is achieved interfragmentary between calcaneal medial and lateral fracture fragment compression and a good stability of fixation. the other 1-2 screws insert on the center of the sustentaculum tali through the lateral wall, where the bone density was relatively high. Several SS screws not only fixed the fracture fragment but also played the role of anti-rotation maintaining the integrity of the subtalar articular surface. 2. LAS☐ LAS fix lateral reduced fracture fragment from posterior calcaneal tuberosity portion to the calcaneocuboid joint, It passes through the bottom of the lateral fragment to avoid it collapse again. 1-2 LAS also can maintain the length of the calcaneus after reduction. 3. HAS☐ HAS implant into the calcaneus from the inferior to superior tuberosity of the posterior calcaneus along the posterior side of the calcaneus trabecula orientation. It is inserted into the lateral fragment to support and strengthen stabilize the subtalar articular surface, while maintaining the height of the calcaneus after reduction. In total, the three types of screws form a mutually staggered structure in space, evenly distribute the stress and achieve a firm fixation of the calcaneal fracture☐Fig.1 ☐.

Minimally invasive, traction reduction technology

The minimally invasive technique was used to reduce the displaced calcaneal fracture. All patients were carried out with in the lateral decubitus position to permit access to the lateral aspect of the hindfoot. A nonsterile tourniquet is applied on the affected extremity at the level of the thigh to reduce intraoperative bleeding. A rolled-up sterile towel be placed under malleolus medialis to suspended the foot parallel to operating table. This position is facilitated to reduce fracture intraoperative. (Fig.2d-e)

Intraoperative procedure☐In the first, the three-point distraction approaches applied to reduce fracture [13]. 4.0 Schanz pins were placed on the posterior tuberosity of calcaneus, which is used as a handle for traction. During traction, the front, middle foot and distal leg were fixed with hand. Through three-point distraction, ligamentotaxis technique restore the length, width and height of calcaneus and correct the varus/valgus alignment as well as the width of the calcaneal tuberosity. If the displacement of the medial calcaneus column cannot be corrected, a medial side 2-4cm arc-shaped incision should be assisted to restore. After a satisfactory reduction of the calcaneal fracture, continuous traction is still needed to maintain, the reduced fracture block is fixed by Kirschner wire inserting into the subtalar joint temporarily.

The second step is semi-open reduction☐Fig.2a-c☐, An transverse arc-shaped incision was made laterally, which approximately 3-6 cm and about 2-3cm below the tip of the fibula in length. The small lateral approach was carried below to calcaneofibular ligament and avoid exposure of important lateral structures, lateral calcaneal artery, lateral calcaneal cutaneous nerve, calcaneofibular, the sheath of the peroneal tendons. Once the sural nerve and the lateral calcaneal artery were identified and retracted. Corticotomy of the broken lateral wall of the calcaneus is done keeping the soft tissue attaches to the lateral wall, and avoid separation by dissection, then the lateral wall of the calcaneus was opened like a window to allow access to reduce the articular fragment (Fig.2f). The lateral posterior fragment was exposed and restored by opening the window with a thin osteotome or periosteal elevator. The quality of the reduction was evaluated by intraoperative imaging or ankle arthroscopy. The depressed fracture fragment is reduced and fixed using 2.0 K-wires temporarily. After obtaining a satisfactory reduction, the screw can be implant into calcaneus according to the technique of SWS.

Postoperative treatment and functional rehabilitation

The incision was routinely cleaned every other day postoperatively, the affected limb was elevated through the lower extremity cushion. gentle strengthening exercises for the muscles controlling the foot and ankle were started. Initiating active range of motion exercises is encouraged after anesthesia recovery. Rehabilitation exercises as early as possible is critical in restoring motion. As long as the patient can tolerate, it is encouraged to do the activity training of flexion, extension of toes, ankle, knee and hip joint. The sutures were removed about 14 days after surgery, patient was routinely followed up every month for over two years. At 6 weeks after surgery, the patient was allowed to walk with partial weightbearing with crutches when the fracture had healed radiographically, and the weight-bearing was increased gradually. Thereafter After 8 weeks, the full

weightbearing without support and gait training was gradually resumed. According to the imaging result in the outpatient follow-up, the intensity of the rehabilitation exercise was adjusted.

Postoperative evaluation

The Bohler's angle, the Gissane's angle, and the calcaneus width and height were measured in the lateral and axial view of the heel after and before surgery. The condition was evaluated to reduction of the articular surface of the posterior subtalar and calcaneocuboid after 1 year followed up by CT scan (Philips Brilliance 64 CT, Philips Medical Systems, The Netherlands). The articular surface was evaluated according to the displacement, the degree of defect, the degree of angulation. Table 1. CT was used to evaluate the degree of arthritis on the subtalar posterior articular and the calcaneocuboid surface. Osteoarthritis was graded as follows: grade 0 - a normal joint space, with no evidence of degenerative cysts or subchondral sclerosis; grade 1 - subchondral sclerosis, osteophytes, and cyst formation, without narrowing of the joint space; grade 2 - narrowing of the joint space, with sclerosis and cyst formation; and grade 3 - complete loss of the joint space. CT scan also observes the internal fixation to determine whether the internal fixation is displaced or broken. (Table 2)

Clinical follow-up

Monthly outpatient follow-up within 3 months after operation, and once a year thereafter. Incision-related complications were recorded, including surface, deep infection, wound dehiscence, and necrosis. Additionally, a physical examination was carefully checked to identify local sensitivity, such as wound irritation, tenderness, and sensory neurological deficit. The American Orthopaedic Foot and Ankle Society (AOFAS) hindfoot score was applied to evaluation of function 1 year after operation. Scoring criteria were graded excellent for >90 points, good for >80, fair for >70, and poor when ≤70. Pain was assessed by a visual analog scale (VAS), ranging from 0 (no pain) to 10 (maximum pain). The ability of patient returning to work was also assessed.

Statistical analysis

Statistical data analysis was performed with SPSS 19.0 statistical software (version 19.0 SPSS Inc., Chicago, IL USA). The measurement data were recorded with "Mean ± SD". A P value of <0.005 was considered to be statistically significant. Independent t-test was used to compare the difference between Preoperative and postoperative Bohler Angle (B), Gissane's Angle (G), calcaneal width (W), height (H).

Results

31 patients received the proposed procedure from October 2015 to October 2019. Sanders type-II fractures 17, Sanders type-III fractures 14. 7 cases involved medial column fractures, 24 involved lateral wall fractures, and 6 involved calcaneal joint fractures, all patients had the displacement of subtalar articular fracture more than 2mm. The average preoperative waiting time was 2.8±2.4 days (range 0-12 days), Mean hospital stay 3.6±1.0 days (range 2-6 days), 11 patients had the medial and lateral fractures, among which 9 patients had reduction after traction during operation. 2 cases were found that the closed reduction of the medial column could not achieve satisfactory reduction during operation, and then the medial incision reduction was assisted. 4 patients with severe osteoporosis were treated with autologous iliac bone graft to fill the void of lateral compression. Mean operating time, 39.8 ± 12.8 min (range 20-71 min). Average blood loss, 31.8 ± 14.0 ml (range 10-55 ml). Bone healing was achieved in all patients, with an average healing time of 7.3 ± 4.2 ml weeks (range 6-12 weeks). Recurrence collapse of subtalar articular surface was not founded at the final follow-up. Slightly superficial skin necrosis around the wound occurred in 1 case (3.2%), which resolved with a regular wound care. 1 patient (3.2%) had paresthesia around the incision after surgery, and sural cutaneous neuritis was considered. Anatomical or approximate anatomical reduction was obtained in the rest cases. 21 cases (67.7%) backed to their formerly work normally, while 8 cases (9.7%) returned to the same job but with little restriction, and 2 (6.4%) cases changed their job for limited foot function. The 2 cases had a type III severe fracture types, associated with severe osteoporosis, which had the relatively low score results of functional postoperatively.

The average AOFAS score was 91.1 (range, 76-96) at the end of 1 year after the operation, 21 cases were excellent (67.4%), 6 cases were good (19.4%), 3 cases were normal (9.7%), and 1 case was poor (3.2%). The mean VAS in our series was 1.97 (range, 0-4). Patients with Preoperative, postoperative and 1-year follow-up: Bohler Angle (B), Gissane's Angle (G), calcaneal width (W), and height (H) were included. (Table 3)

The evaluation of the posterior subtalar articular surface reduction showed excellent restore in 15 patients (48.4%), good in 10 cases (32.3%), fair in 5 cases (16.1%), and poor in 2 cases (6.5%). The excellent and good reduction rate was 80.6%. The reduction of the articular surface of the calcaneus cuboid: Excellent 18 cases (58.1%), Good 10 cases (32.3%), Fair 2 cases (6.5%), Poor 1 case (3.2%). The excellent and good reduction rate was 90.3%. CT evaluation of the degree of articular arthritis of the posterior subtalar surface were 19 cases of grade 0, 9 cases of grade 1, 2 cases of grade 2, and 1 case of grade 3. CT assessment of the degree of articular arthritis of the calcaneus cuboid surface were 21 cases were grade 0, 9 cases were grade 1, 1 case was grade 2, 0 cases were grade 3. (Figure 3).

Discussion

The main trend has developed toward open reduction and internal fixation with an extensile L-shaped approach and plate for displaced intra-articular calcaneus fractures. It affords excellent exposure, allowing obtain to operate and fix the fracture fragments [14]. yet controversy still exists on this surgical procedure for approach and plate [6,14]. The important structures of the lateral calcaneus are extensively damaged which can lead to the soft tissue-related complication such as the infection and necrosis of the lateral incision in this surgical method. the calcaneal plate can lead to rejection reaction. In addition, the plate is eccentrically fixed and may lack effective fixation on the opposite side from the aspect of biomechanics.

Therefore, many had tried to develop minimally invasive methods attempts to avoid this method related complications throughout the history of calcaneal fracture treatments, and some have become more popular for selected fracture patterns over the others. Bremer et.al [15]. reported that the 240 consecutive patients that had been used a lateral subtalar approach and screw fixation treating for a displaced intra-articular calcaneal fracture were followed for more than 24 months. The presented approach has remained unmodified for 16 years and resulted in consistently good functional results. Ebrahim pour A et.al [16]. believed that for treatment of various types of calcaneal fracture compared with ORIF the percutaneous reduction and screw fixation may lead to better clinic outcome Fractures of the calcaneus with involvement of the subtalar joint should be treated by anatomical reduction, absolute stable fixation, and early mobilization like any other intra-articular fractures. Minimally invasive method usually cannot achieve good reduction and stable fixation. The biomechanical stability of internal fixation is limited by minimally invasive treatment. Khurana et.al [17]. note minimally invasive surgery methods minimized soft tissue complications and achieved comparable radiological reductions but clinical outcomes were poorer, with percutaneous methods having the worst outcomes. Currently, few studies show how to fix percutaneous screws to achieve stable structure. In this study, 3 category SWS fixation was designed according to the fracture line characteristics of Sanders II-III and combined with preoperative 3D printing technology preoperatively. Intraoperative manipulation can be carried out according to the preoperative plan. SS screws fix the lateral collapsed fracture fragment on the medial sustentaculum tali, compressing the fractures to promote fracture healing; LAS prevents to collapse again of the reduced articular surface while maintains the length of the calcaneus. HAS supports for the lateral fragment furtherly, maintaining the height of the calcaneus. The three types of screws build an interlocking weaving structure in space, which mechanically supports each other to form an effective rigid fixation. CT examination showed that only 1 case (3.7%) underwent a postoperative less than 4mm collapse of subtalar articular surface, and others were not found articular surface collapse, calcaneal valgus deformity, calcaneal deformity obviously after more than 1year follow-up. In addition, the percutaneous screw implantation method can also avoid problems such as screw tract infection and the difficulty of wound care caused by exposure of implantation.

Calcaneal fractures are usually high-energy mechanism and associated with soft tissue injuries. Soft tissue protection is an important role in calcaneal recovery after operation [18]. The extensile lateral approach has been the most frequently used surgical approach for the last 3 decades [19]. However, the soft tissue-related complication rate is high such as wound dehiscence necrosis, infection, plate exposure, etc. For this reason, there has been increase interest in small-incision operation try to change for calcaneal fractures. Ragab A.H et al [20]. reported they treated displaced intra-articular calcaneal fractures by the trans-osseous limited lateral approach and achieved satisfactory results. In addition, minimally invasive to reduction have become popular because of the lower incidence of wound complications. Among these, sinus tarsi incisions are currently popular [21]. The calcaneus can be restored the fracture of subtalar articular surface on direct vision. However, this approach can damage important lateral structures of calcaneus, Niall A. et al [22]. suggested that the extensile lateral approach to the calcaneus (ELA) and the sinus tarsi approach (STA) could cause lateral sural nerve injury, calcaneofibular ligament, which can result in impaired lateral stability and subtalar articular surface arthritis. Based above all, this study via a small incision below the fracture line and "open the window" from lateral wall. It protects the calcaneofibular ligaments that are attached to the lateral wall and exposes the bottom of the collapsed lateral subtalar articular directly. The depressed subtalar joint fragment can be directly to restore through this approach to avoid the damage of the lateral important structures. The calcaneofibular ligament and the sheath of the peroneal tendons are protected. There were 1 case (3.2%) of peroneal tendon irritation for incomplete reduction of the lateral wall at 1year follow-up. The height of the posterior talocalcaneal joint, the width of the calcaneal tuberosity and the varus/valgus malalignment were restored by ligamentotaxis distraction indirectly. Important structures attached to the lateral wall is prevented from being exposed. Meanwhile, percutaneous reduction and implantation with screws only decreases the risk of the irritation and injury soft tissues. Therefore, it is also not limited to the timing of surgery, even if accompanied by severe soft-tissue trauma, early surgical intervention can be permitted, decrease hospitalization days.

It is essential to anatomical reduction of the subtalar articular surface and restore calcaneal alignment. The surgeon must have integrally spatially accurately understanding of the fracture in order to manipulate anatomic reduction by minimally invasive approach. Computer-aided technology has been widely used in orthopedics, which is of great significance for preoperative planning and intraoperative decision-making [24]. The duration of operation time is also considered to be a high-risk factor for postoperative complications of calcaneal surgery [25]. In this study, the surgical method was designed on the virtual reconstructed 3D model in MIMICS. To each individual, the fracture model was dragged and separated in MIMICS to further check the injury mechanism and type of fracture types, the sequence of reduction and fixation of calcaneal fractures was firstly established in the virtual software. The simulated operation was performed on the real-size 3D printed model and the operation procedure and screw fixation structure were designed for different types of calcaneal fractures individually. Full understanding of the fracture feature are essential prerequisites preoperatively. The 3D technique could give surgeons a better understanding of fractures morphology and sufficient preparation preoperatively. In actual operation, it could expand the possibility of improving surgical proficiency precision and decreasing both the operative

duration, intraoperative exposure and the difficulty of operation. In this study, the rate of reduction was 81.4% (22/27) to anatomical or approximate anatomical reduction, and the success rate of the operation was significantly increased.

A study published by Baca Emre et al [26]. demonstrated that 114 displaced calcaneal fractures were fixed by kirschner wire, followed up for 42.33 ± 18.33 months, AOFAS Score was 80.4 (Range, 47 to 92) Sanders II 81.25, Sanders III. Veltman's et al [27]. found that the average AOFAS score for percutaneous treatment was 86.4 through statistical analysis of literature review involving 1730 calcaneal fractures. Cong et al [28]. applied MIPO technology to treat 29 displaced calcaneal fractures, and AOFAS score was 84.4 ± 4.9 points at end of followed up 1 year postoperatively. Postoperative AOFAS scores in this study were higher than those minimally invasive surgery in the literature.

Conclusions

The minimally invasive approach and opened "window" to the lateral wall was reduced the depressed articular surface, which avoid damage to the important structure of the lateral calcaneus. And then through three-point distraction, ligamentotaxis technique restore the length, width and height of calcaneus and correct the varus/valgus alignment. According to 3D printing technology, percutaneous weaving structure implantation was carried out, evenly distribute the stress and achieve a firm fixation providing mechanical support for calcaneal fracture healing. Despite the sample size is limited in this study, the methods can be proved to be an effective, simple and safe strategy for the displaced calcaneal fractures.

Abbreviations

CT: Computed Tomography

AOFAS: the American Orthopedic Foot and Ankle Society;

VAS: visual analog scale;

SWS: the spatial weaving screw;

SS: Sustentacular screw;

LAS: Long axis screw of calcaneal;

HAS: High axis screw of calcaneal

Declarations

Ethics approval and consent to participate

The study was approved by the Ethics Committee of the Ningbo No 6 Hospital (No.2018-006). Informed written consent was obtained from all the patients. All procedures were performed in accordance with relevant guidelines.

Consent for publication

A written informed consent was obtained from the patient for publication of this report and any accompanying images.

Availability of data and materials

The datasets used and/or analysed during the current study are available from the corresponding author on reasonable request.

Competing interests

The authors declare no conflict of interest.

Funding

This study was supported by the Medical and Health Technology Project of Zhejiang Province (No.2019PY073 No.2021PY072); Science and technology research on public welfare project of Ningbo, Zhejiang Province (No. 2019C50050); The Scientific Technology project of Agriculture and Social development of Yingzhou, Ningbo, Zhejiang Province (No. 20180137, No. 20200132). The funding sources had no involvement in the study design; collection, analysis, and interpretation of data; writing of the manuscript; nor the decision to submit for publication.

Authors' contributions

YongZhang provided the clinical data included in the text. YongZhang and Yunfeng Yang participated in the treatment decisions. YongZhang wrote the manuscript draft. QiuyanWeng and Jianming Chen revised it critically and approved the modified text. YongZhang approved the final version of

the manuscript. All the authors read and approved the final manuscript.

Acknowledgements

Not applicable.

References

1. Benson E, Conroy C, Hoyt DB, et al. Calcaneal fractures in occupants involved in severe frontal motor vehicle crashes. *Accident Analysis & Prevention* 2007; 39(4): 794-799.
2. Sharr PJ, Mangupli MM, Winson IG, et al. Current management options for displaced intra-articular calcaneal fractures: Non-operative, ORIF, minimally invasive reduction and fixation or primary ORIF and subtalar arthrodesis. A contemporary review. *Foot Ankle Surg* 2016; 22(1): 1-8.
3. Schmal H, Larsen AH, Froberg L, et al. The effect of a heel-unloading orthosis in short-term treatment of calcaneus fractures on physical function, quality of life and return to work - study protocol for a randomized controlled trial. *Trials* 2019; 20(1): 324.
4. Brewster O, Clement ND, Duckworth AD, et al. Long-term mortality after internal fixation of calcaneal fractures: a retrospective study. *Eur J Orthop Surg Traumatol* 2020; 30: 157-162.
5. Cao L, Weng W, Song S, et al. Surgical treatment of calcaneal fractures of Sanders type II and III by a minimally invasive technique using a locking plate. *J Foot Ankle Surg* 2015; 54(1): 76-81.
6. Gotha HE, Zide JR. Current Controversies in Management of Calcaneus Fractures. *Orthop Clin North Am* 2017; 48(1): 91-103.
7. Waris E, Konttinen YT, Ashammakhi N, et al. Bioabsorbable fixation devices in trauma and bone surgery: current clinical standing. *Expert Rev Med Devices* 2004; 1(2): 229-240.
8. Bai L, Hou YL, Lin GH, et al. Sinus tarsi approach (STA) versus extensile lateral approach (ELA) for treatment of closed displaced intra-articular calcaneal fractures (DIACF): A meta-analysis. *Orthop Traumatol Surg Res* 2018; 104(2): 239-244.
9. Wang XJ, Su YX, Li L, et al. Percutaneous poking reduction and fixation versus open reduction and fixation in the treatment of displaced calcaneal fractures for Chinese patients: A systematic review and meta-analysis. *Chin J Traumatol* 2016; 19(6): 362-367.
10. Wu J, Zhou F, Yang L, et al. Percutaneous Reduction and Fixation with Kirschner Wires versus Open Reduction Internal Fixation for the Management of Calcaneal Fractures: A Meta-Analysis. *Sci Rep* 2016; 6: 30480.
11. A E, MHC K, M S, et al. Percutaneous reduction and screw fixation for all types of intra-articular calcaneal fractures. *Musculoskeletal surgery*, 2020.
12. Smerek JP, Kadakia A, Belkoff SM, et al. Percutaneous Screw Configuration Versus Perimeter Plating of Calcaneus Fractures: A Cadaver Study. *Foot & Ankle International* 2008; 29(8): 931-935.
13. Schepers T, Patka P. Treatment of displaced intra-articular calcaneal fractures by ligamentotaxis: current concepts' review. *Arch Orthop Trauma Surg* 2009; 129(12): 1677-1683.
14. Razik A, Harris M, Trompeter A. Calcaneal fractures: Where are we now? *Strategies in Trauma & Limb Reconstruction* 2017; 13(1): 1-11.
15. Bremer AK, Kraler L, Frauchiger L, et al. Limited Open Reduction and Internal Fixation of Calcaneal Fractures. *Foot Ankle Int* 2020; 41(1): 57-62.
16. Ebrahimpour A, Kord MHC, Sadighi M, et al. Percutaneous reduction and screw fixation for all types of intra-articular calcaneal fractures. *Musculoskelet Surg*, 2020; (9).
17. Khurana A, Dhillon MS, Prabhakar S, et al. Outcome evaluation of minimally invasive surgery versus extensile lateral approach in management of displaced intra-articular calcaneal fractures: A randomised control trial. *Foot (Edinb)* 2017; 31: 23-30.
18. Seat A, Seat C. Lateral Extensile Approach Versus Minimal Incision Approach for Open Reduction and Internal Fixation of Displaced Intra-articular Calcaneal Fractures: A Meta-analysis. *The Journal of Foot and Ankle Surgery* 2020; 59(2):356-366.
19. J A, TY K, TW K, et al. Learning Curve for Open Reduction and Internal Fixation of Displaced Intra-articular Calcaneal Fracture by Extensile Lateral Approach Using the Cumulative Summation Control Chart. *Foot & ankle international* 2019; 40(9): 1052-1059.
20. Ragab AH, Mubark IM, Nagi AM, et al. Treatment of Subtalar Calcanean Fractures Using Trans-Osseous Limited Lateral Approach. *Ortopedia Traumatologia Rehabilitacja* 2014;16(6): 629-638.
21. Schepers T. Sinus Tarsi Approach with Screws-Only Fixation for Displaced Intra-Articular Calcaneal Fractures. *Clin Podiatr Med Surg* 2019; 36(2): 211-224.
22. NA S, EC Z, LT B, et al. Surgical approaches to the calcaneus and the sural nerve: There is no safe zone. *Foot and ankle surgery: official journal of the European Society of Foot and Ankle Surgeons* 2018; 24(6): 517-520.
23. Letournel E. Open treatment of acute calcaneal fractures. *Clinical Orthopaedics & Related Research* 1993; 290(290): 60-67.
24. Qiang M, Zhang K, Chen Y, et al. Computer-assisted virtual surgical technology in pre-operative design for the reconstruction of calcaneal fracture malunion. *International Orthopaedics. Int Orthop* 2019; 43: 1669-1677.

25. Ding L, He Z, Xiao H, et al. Risk Factors for Postoperative Wound Complications of Calcaneal Fractures Following Plate Fixation. *Foot & Ankle International*,2013; 34(9): 1238-1244.
26. Baca Emre, Koluman Alican, Modified percutaneous fixation for displaced intra-articular calcaneal fractures. *Eklemler Hastalik Cerrahisi* 2019; 30: 168-74.
27. Veltman ES, Doornberg JN, Stufkens SAS, et al. Long-Term Outcomes of 1,730 Calcaneal Fractures: Systematic Review of the Literature. *Journal of Foot & Ankle Surgery* 2013;52(4).
28. Jin C, Weng D, Yang W, et al. Minimally invasive percutaneous osteosynthesis versus ORIF for Sanders type II and III calcaneal fractures: a prospective, randomized intervention trial. *Journal of Orthopaedic Surgery & Research* 2017;12(1): 10.

Tables

Table 1: Patient demographic data.

Case	age/Sex	Injury cause	Sanders Classification	Preoperative preparation (day)	Operation time (minutes)	Intraoperative blood loss (milliliter)	Hospital stays (day)	Follow-up (month)	Postoperative complications
1	42/M	car accident	III	1	30	20	3	24	
2	33/F	falling down	II	0	45	15	4	18	
3	37/M	falling down	II	1	30	30	3	19	
4	45/F	sprain	III	2	50	50	4	21	
5	30/M	falling down	III	2	55	40	5	22	
6	53/F	car accident	II	2	45	30	2	16	
7	35/M	falling down	II	1	32	25	3	16	
8	22/M	falling down	II	0	35	30	4	17	
9	36/M	E-Bicycle	III	4	46	50	3	16	
10	41/M	falling down	II	1	35	10	5	24	
11	44/M	E-Bicycle	II	3	35	20	3	17	
12	47/M	falling down	II	4	47	30	4	18	yes
13	34/M	falling down	II	2	20	20	6	18	
14	19/M	E-Bicycle	III	2	38	60	3	21	
15	46/F	sprain	III	3	30	20	3	24	
16	37/M	falling down	II	3	60	50	4	24	
17	57/M	falling down	II	7	71	40	4	19	
18	66/M	falling down	III	3	25	50	3	16	
19	35/M	car accident	II	12	35	30	2	24	
20	68/M	falling down	III	2	40	10	4	22	
21	31/M	falling down	III	1	50	20	3	19	
22	67/M	E-Bicycle	III	3	27	30	5	16	yes
23	22/M	falling down	III	4	24	40	2	24	
24	37/M	falling down	II	8	46	55	3	21	
25	68/M	E-Bicycle	III	3	68	30	4	19	
26	31/M	E-Bicycle	II	3	25	50	4	16	
27	67/F	falling down	II	3	40	40	4	18	
28	18/M	falling down	II	2	49	30	3	19	

29	18/M	falling down	III	2	30	10	3	23
30	24/M	E-Bicycle	II	2	45	20	4	24
31	21/M	car accident	III	1	26	30	5	19

Table 2: CT Evaluation of Reduction

	Step(mm)	Defect(mm)	Angulation(degree)
Posterior facet			
Excellent	None	None	None
Good	≤1	≤5	≤5
Fair	1 to 3	5 to 10	5 to 15
Poor	3	10	15
Calcaneocuboid joint			
Good	None	None	None
Fair	≤1	≤5	≤5
Poor	1	5	5

Table 3: Mean value (SD) of calcaneus height, width, and length, Bohler angle, Gissane's angle (1 year)

	Hight(mm)	Length(mm)	Width(mm)	Bohler angle(°)	Gissane's angle(°)
Preoperation	29.58(4.72)	60.32(6.14)	36.55(4.31)	13.07(6.90)	94.84(8.3)
Postoperation	37.13(3.30)	64.48(4.67)	33.1(3.07)	30.53(2.84)	125.9(6.51)
follow-up	36.45(3.10)	63.9(4.83)	32.81(3.27)	30.02(3.37)	124(6.91)

Figures

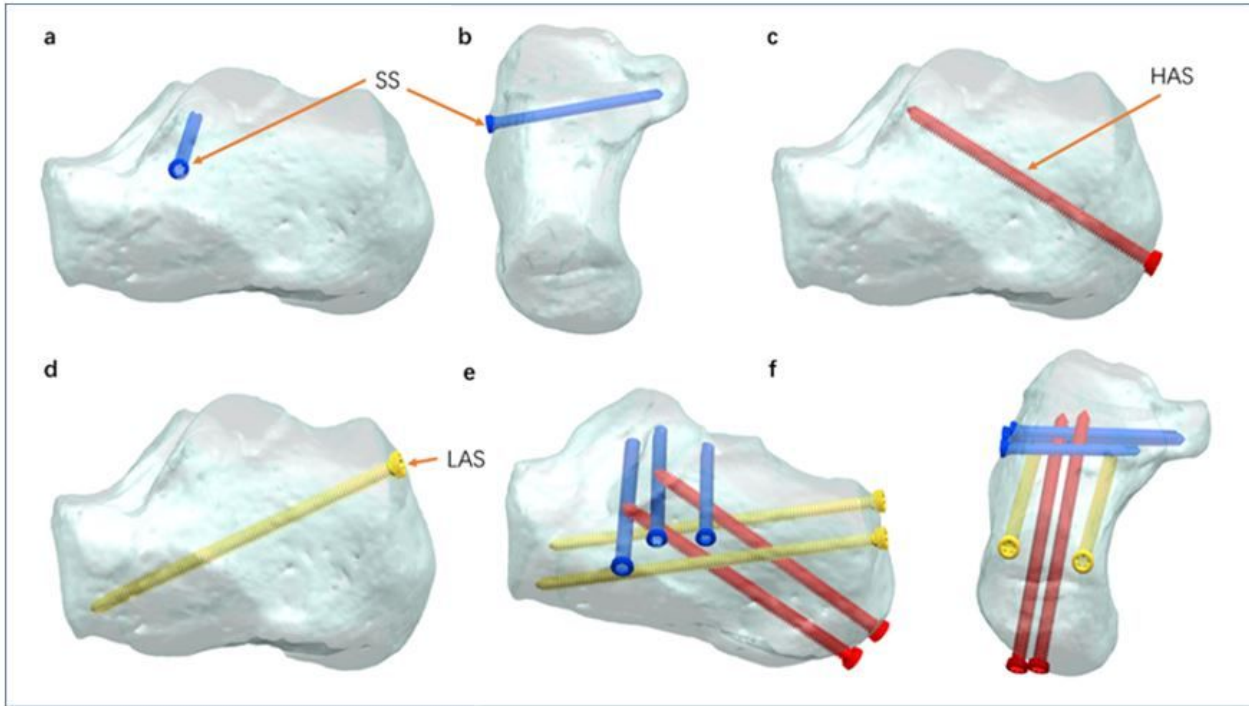


Figure 1
 The design of the screw trajectory using the 3D model. (a- b) SS stabilize the subtalar joint surface. (c) The HAS screws maintain the height of the calcaneus. (d) LAS maintains the length of the calcaneus (e- f) The three types of screw form a "the spatial weaving " stable supporting structure in the calcaneal body.

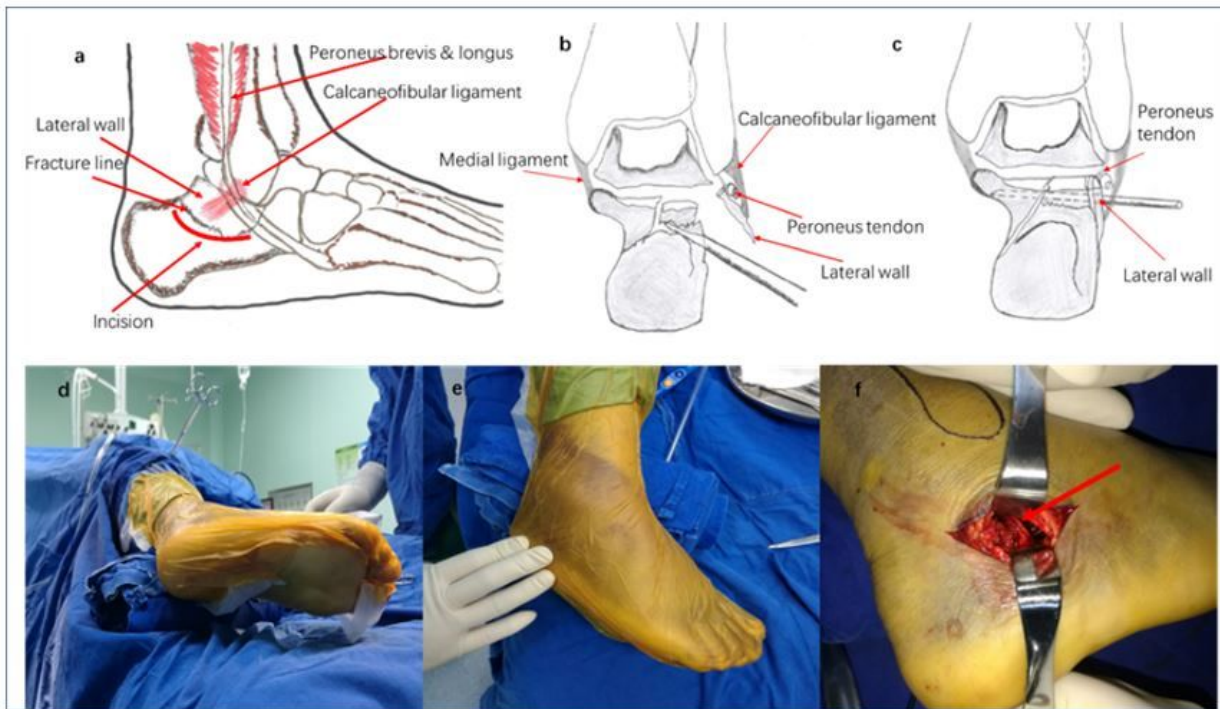


Figure 2
 (a) Diagram of minimally invasive approach incision in calcaneus and anatomical structures and relationship to the adjacent structures. (b) The technique of open window can protect the lateral structure of the calcaneus. (c) The collapsed fracture fragment was reduced through the lateral window, after the reduced articular surface, the window was closed. (d) Photograph of limb position and approach: A patient in the lateral

decubitus position with the affected foot uppermost and a wrapped towels underneath the ankle; (e) Press the distal end of the calcaneus to expose the subtalar articular surface. (f) the collapsed subtalar posterior articular facet.

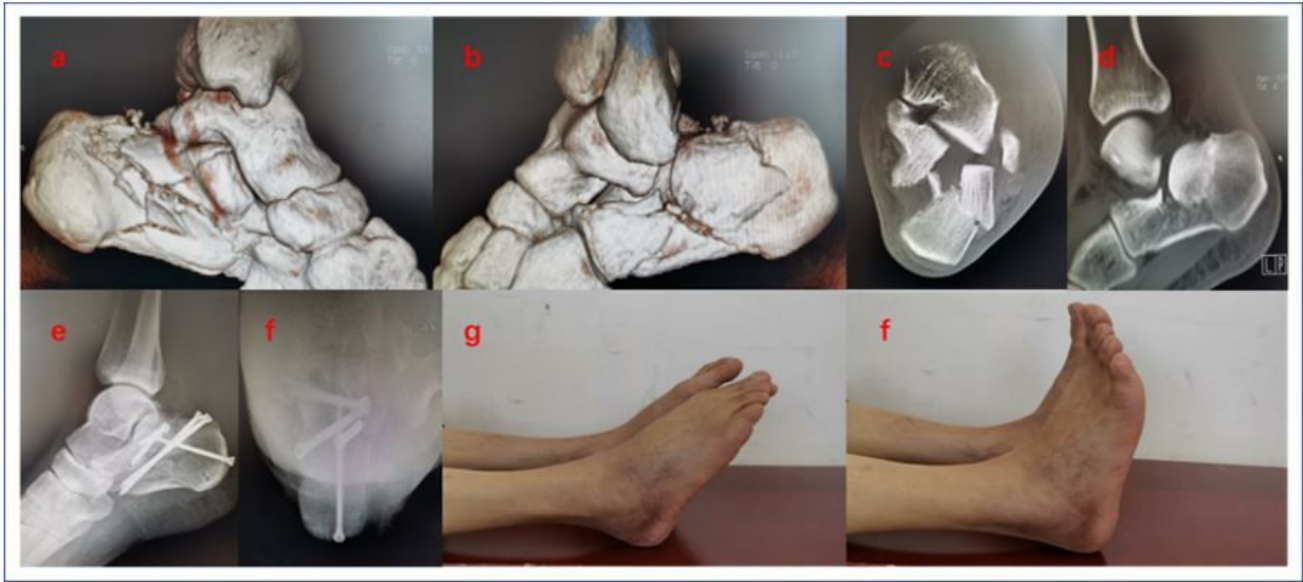


Figure 3

Typical case of Sanders type-II calcaneal fractures. (a-b) Preoperative CT scan and three-dimensional reconstruction of calcaneal bone. (c-d) Coronal and sagittal CT plane showed that the fracture was mainly the collapse of the lateral subtalar articular fragment. (e-f) Postoperative axial and lateral calcaneal radiograph showed a satisfactory reduction of each articular surface and accurate spatial weaving screw. (g-f) Physical examination showed the incision healed well and the function recovered well.