

The research of the relationships between patent foramen ovale and ischemic stroke in elderly patients

Xu Chao Sun

Shandong University Qilu Hospital

Wenjing Jiang (✉ jwj05@sina.com)

Shandong University Qilu Hospital <https://orcid.org/0000-0003-0646-9101>

Yan Zhao

Shandong University Qilu Hospital

Lin Ma

Shandong University Qilu Hospital

Yan Lin

Shandong University Qilu Hospital

Jun Ma

Shandong University Qilu Hospital

Research article

Keywords: patent foramen ovale, ischemic stroke, cryptogenic stroke

Posted Date: April 29th, 2020

DOI: <https://doi.org/10.21203/rs.3.rs-23628/v1>

License: © ⓘ This work is licensed under a Creative Commons Attribution 4.0 International License.

[Read Full License](#)

Abstract

Background Research indicates that abnormal embolism caused by patent foramen ovale (PFO) may play an important role in cryptogenic stroke (CS). However, most researches has focused on young patients, and whether abnormal embolism caused by PFO also plays an important role in elderly CS is uncertain. The purpose of this study is to analyze the clinical characteristics of elderly patients with PFO, and to explore the correlation between elderly PFO and ischemic stroke.

Methods 62 elderly patients diagnosed with ischemic stroke admitted to Qilu Hospital of Shandong University from April 2014 to April 2019 were selected as the Test Group. 62 non-stroke patients in our hospital's physical examination center and outpatient clinic were selected as the Control Group. Collect clinical data of patients for retrospective analysis.

Results The incidence of PFO in the Test Group was significantly higher than that in the Control Group, the difference was statistically significant ($p < 0.05$). The proportion of large and medium shunt patients in the Test Group was significantly higher than that in the Control Group ($p < 0.05$). The proportion of patients with migraine in the PFO (+) group in the Test Group was significantly higher than the stroke patients in the PFO (-) group ($p < 0.05$).

Conclusions The shunt volume of the PFO is related to ischemic stroke and may be a risk factor for ischemic stroke.

Background

Stroke is an extremely serious disease that threatens human health worldwide. Stroke has caused a serious economic burden due to its high case fatality rate and disability rate. Stroke is divided into ischemic stroke and hemorrhagic stroke ^[1, 2]. Among them, ischemic stroke is the most common type of stroke, accounting for about 60% -80% of all strokes. Ischemic stroke refers to local cerebral tissue ischemia and hypoxia due to various reasons, resulting in corresponding neurological deficits ^[3, 4].

Common risk factors for ischemic stroke include hypertension, diabetes, atrial fibrillation, dyslipidemia, smoking, drinking, obesity, unreasonable diet and nutrition ^[5]. However, in recent years, many researches has shown that patent foramen ovale (PFO) is closely related to ischemic stroke, which may be its underlying cause. The foramen ovale is the normal physiological channel between the left and right atria in the fetal period, and also the life channel of the fetus ^[6]. Umbilical vein blood from the mother enters the left heart of the fetus through this channel and supplies the oxygen and nutrients needed by the fetus for development. The foramen oval will generally gradually reach anatomical closure 5–7 months after the birth of the fetus. If it is not closed for more than 36 months, we call it PFO. According to statistics, 1 out of 4 people in the general population may have PFO, with an incidence rate of about 25% ^[7]. Studies have shown that the incidence of PFO in patients with ischemic stroke is significantly increased, up to 30% -40% ^[8]. Abnormal embolism is currently considered to be the main pathogenesis of PFO leading to

ischemic stroke, that is, because the right atrium pressure is higher than the left atrium, the venous system and right heart embolism enter the left atrium and systemic circulation through the abnormal right-to-left shunt pathway. This in turn causes ischemic stroke. Studies have shown that abnormal embolism caused by PFO may play an important role in cryptogenic stroke (CS) ^[9]. However, the specific relationship between PFO and ischemic stroke is still unclear. The diagnostic methods of PFO include transesophageal echocardiography, transthoracic echocardiography, transcranial Doppler ultrasound foam test, etc. Among them, transesophageal echocardiography has always been regarded as the gold standard for PFO examination, with high sensitivity and specificity. In recent years, the transcranial Doppler ultrasound foam test has been widely used in clinic because of its advantages of non-invasive, safe, simple operation and convenience. A number of recent studies suggest that transcranial Doppler ultrasound foam testing has higher sensitivity than transesophageal echocardiography ^[10].

At present, most studies are focused on young patients ^[11]. Whether abnormal embolism caused by PFO also plays an important role in elderly CS, and whether it also increases the risk of stroke in patients with atherosclerosis remains to be explored. This study aims to analyze the relationship between PFO and ischemic stroke by comparing the incidence and shunt of PFO in the stroke group and the Control Group. Explore the effect of PFO flow rate on the severity and prognosis of ischemic stroke. Improve people's understanding of ischemic stroke, oval foramen and their connection, and provide help for clinical diagnosis and treatment.

Methods

Study population

62 elderly patients diagnosed with ischemic stroke admitted to Qilu Hospital of Shandong University from April 2014 to April 2019 were selected as the Test Group. 62 non-stroke people in our hospital's physical examination center and outpatient clinic were selected as the Control Group. The diagnosis of the Test Group were accorded the diagnostic criteria, and head CT was used to exclude cerebral hemorrhage. All patients in the group underwent head CT, head MRI, neck vascular ultrasound, heart ultrasound, TCD foam test, electrocardiogram or dynamic electrocardiogram and blood routine, liver and kidney function, full blood glucose, blood clotting routine, and homocysteine level. The patients in the Test Group were treated with anti-platelet aggregation according to the diagnosis and treatment guidelines. And exclude according to the following criteria: (1) Those who complicated with severe liver, kidney and other medical and surgical diseases. (2) Those who cannot cooperate with various inspections and complete follow-up. (3) Those who do not want to be examined. (4) Patients with severe stenosis or occlusion of middle cerebral artery. The study protocol was reviewed and approved by the Qilu Hospital of Shandong University Ethical Committee. Patients gave informed consent prior to study participation.

Clinical assessment

Collected the clinical history of each patient, including age, gender, age, hospitalization number and risk factors for cerebrovascular diseases such as hypertension, diabetes, hyperlipidemia, hyperhomocysteinemia, atrial fibrillation, smoking history, and drinking history. Physical and neurological examinations were performed by two different neurologists.

Evaluation of neurological deficit and prognosis

The National Institutes of Health Stroke Scale (NIHSS) was used to assess the degree of neurological deficit in patients with ischemic stroke within 24 hours of admission and discharge, including consciousness, gaze, visual field, facial paralysis, limb movement, ataxia, sensation, language, dysarthria, and neglect. A higher NIHSS score indicates a greater degree of neurological deficit, and a lower score indicates a lower degree of neurological deficit^[12].

PFO assessment

Used the EMS-9A TCD diagnostic instrument (Delical, Guangdong, China), in the embolic monitoring mode, the probe with a fixed frequency of 2 MHz was used to monitor the unilateral middle cerebral artery and displayed the blood flow velocity change curve at the same time. The operator was an experienced professional TCD doctor who taught the patient how to perform the standard Valsalva action before the examination, that is, blew the gas to the pipe connected to the mercury pressure gauge for 10s, required the mercury to be blown up to 40 mm Hg. Opened venous access in arm and connect tee. Took a 10ml syringe that has drawn 9ml of normal saline, connected it to the tee, and drew back 1-2 drops of blood. Took another 10 ml syringe that sucks 1 ml of air and connected it to the tee. Adjusted the tee, and pushed back the two syringes quickly 20 times, so that the physiological saline, blood, and air were evenly mixed to make a mixed blood to activate physiological saline. Quickly pushed the mixed blood activated saline into the elbow vein, used transcranial Doppler, placed the probe on the patient's temporal window (or eye window) for examination. Observed and recorded the changes of the frequency spectrum signals, and compared them during normal and smooth breathing and during Valsalva maneuver. A typical bubble embolic signal was recorded on either side of the middle cerebral artery TCD within 20s of mixed saline-activated saline injection, that is, TCD diagnosis was positive for PFO^[13, 14].

Statistical analysis

The data are expressed as the means \pm standard deviations (SDs). An independent sample *t*-test was used to compare the differences between two groups of data satisfying normal distribution. The significance of differences among groups was evaluated by analysis of variance (ANOVA) followed by

Tukey's test. The statistical analyses were performed using GraphPad 7.0 (GraphPad Software, Inc., La Jolla, CA, USA). Statistical significance was accepted at $p < 0.05$.

Results

Clinical feature

In the primary analysis, the clinical characteristics of the patients were shown in Table 1. In this study, retrospective analysis was carried out by collecting clinical data of patients. Of the 62 patients in the Test Group, 31 were male and 31 were female. The age of Test Group was 67.42 ± 5.73 years old. Of the 62 patients in the Control Group, 32 were male and 30 were female, aged 68.01 ± 4.89 years. There was no statistically significant difference in demographic characteristics between the two groups.

Table 1. Comparison of demographic characteristics of between Control Group and Test Group.

	All	Control Group	Test Group	<i>p</i> value
Female:male	63:61	32:30	31:31	>0.05
Age (mean \pm SEM)	67.68 ± 4.91	68.01 ± 4.89	67.42 ± 5.73	>0.05
Hypertension (n, %)	58[46.77]	30[48.39]	28[45.16]	>0.05
Diabetes	19[15.32]	10[16.13]	9[14.52]	>0.05
Smoking	35[28.23]	20[32.26]	15[24.19]	>0.05
Alcohol intake	24[19.35]	10[16.13]	14[22.58]	>0.05
History of migraine	3[2.42]	1[1.61]	2[3.23]	>0.05
History of stroke/TIA	16[12.90]	6[9.68]	10[16.13]	>0.05

Occurrence of PFO in patients in Test Group and Control Group

We found that among the 62 patients in the Test Group, there were 17 patients with PFO (+), and the incidence of PFO was 27.42%. In Control Group, there were 4 patients with PFO (+), and the incidence of PFO was 6.45%. And the difference in the incidence of PFO between the Test Group and the Control Group was statistically significant ($p < 0.01$) (Figure 1). Then, used PFO as the independent variable, logistic regression analysis was used to determine whether the subject had ischemic stroke as the dependent variable. We found that the PFO was closely related to ischemic stroke and was one of the risk factors for ischemic stroke ($p < 0.01$, OR=2.259, 95% CI: 1.14-4.31).

The degree of shunting of PFO in the Test Group and the Control Group

In the Test Group, there were 2 patients (11.76%) with a large number of PFO shunts, 2 patients with a moderate shunt (11.76%), 4 patients with a small shunt (23.53%), and 9 patients with no shunt (52.94%). In the Control Group, 1 patient (25.0%) had small shunt, and 3 patients (75.0%) had no shunt. Compared the shunt degree of the two groups of patients, the difference was statistically significant ($p < 0.01$) (Figure 2).

Comparison of the severity of neurological deficits in patients

We first divided the stroke patients in the Test Group into PFO (+) group and PFO (-) group, compared the admission NIHSS scores of the two groups of patients, and found that there was no statistical significance ($p > 0.05$). Then, according to the PFO shunt, stroke patients in the PFO (+) group were divided into a small shunt group, a middle shunt group, and a large number of shunt groups, and the severity of neurological deficits in different shunt groups was compared. However, we found that it was no statistical significance ($p > 0.05$).

Comparison of risk factors of cerebrovascular disease

We found that in the Test Group, there were 10 male patients and 7 female patients in the PFO (+) group, aged (67.52 ± 3.15) years, including 8 cases of hypertension, 2 cases of diabetes, 5 cases of smoking, 4 cases of alcohol intake, 2 cases of history of migraine, and 3 cases of history of stroke / TIA. In the PFO (+) group, there were 21 males and 24 females, aged (68.04 ± 4.87) years. There were 20 cases of hypertension, 7 cases of diabetes, 10 cases of smoking, 10 cases of alcohol intake, 0 cases of history of migraine, and 7 cases of history of stroke / TIA. After comparison, the proportion of PFO (+) combined with migraine was higher than that of PFO (-) group, the difference was statistically significant ($p < 0.05$), and the other groups had no statistical difference ($p > 0.05$) (Table 2).

Table 2. Comparison of risk factors of cerebrovascular disease between PFO(-) Group and PFO(+) Group.

	PFO(-)	PFO(+)	<i>p</i> value
Female:male	21:24	10:7	>0.05
Age (mean \pm SEM)	68.04 \pm 4.87	67.52 \pm 3.15	>0.05
Hypertension (n, %)	20/44.44%	8/47.06%	>0.05
Diabetes	7/15.16%	2/11.76%	>0.05
Smoking	10/22.22%	5/29.41%	>0.05
Alcohol intake	10/22.22%	4/23.53%	>0.05
History of migraine	0/0%	2/11.76%	<0.05
History of stroke/TIA	7/15.56%	3/17.65%	>0.05

Discussion

The foramen ovale is a physiological channel during the fetal period, which allows the blood in the right atrium to flow into the left atrium and maintain the blood circulation of the fetus ^[15]. After the fetus is born, with the establishment of its own pulmonary circulation, most will gradually close 5–7 months after birth. But some people will not be completely closed, leaving a gap-like defect, called PFO. Studies have shown that the incidence of PFO in the normal population is approximately 25%–30% ^[16]. But for a long time, the foramen oval is not considered to cause serious clinical consequences. In recent years, more and more studies have shown that the foramen ovale can lead to the occurrence of ischemic stroke ^[17]. The research on the foramen ovale and ischemic stroke has become a hot spot. Studies have shown that the incidence of PFO in patients with ischemic stroke is increased, the incidence of PFO in normal adults is 17–35%, and the incidence of stroke patients is as high as 40–45% ^[18]. A related meta-analysis found that the prevalence of PFO was 6 times higher in patients with cryptogenic stroke < 55 years of age than those with a clear etiology of the same age ^[19]. A summary of the meta-analysis of 29 cohort studies from 1988 to 2008 showed that 27 of them confirmed the correlation between PFO and cryptogenic stroke ^[20]. The results of Cabanes et al. ^[21] also showed that the relative risk of thromboembolic events in PFO was four times that of the normal control group, indicating that PFO was positively correlated with the risk of ischemic stroke. Kent et al. ^[22] used the Risk of Paradoxical Embolism (RoPE) scale to analyze the correlation between stroke and PFO. The scale includes risk factors such as cortical stroke, diabetes, hypertension, smoking, previous stroke or transient ischemic attack, and age. Calculate the score to determine whether PFO is the cause of stroke. If the RoPE score is high, it is more likely to consider PFO-related stroke. It also indicates that the fewer patients have traditional cerebrovascular risk factors, the more likely PFO is the cause of stroke. However, researches on elderly patients is still lacking.

This study focuses on elderly patients with ischemic stroke. In this study, there were 62 stroke patients in the Test Group and 62 patients in the Control Group. There was no statistical difference in age and gender between the two groups. Among them, there were 17 stroke patients with PFO in the Test Group,

and the incidence of PFO was 27.42%, the number of people with PFO in the Control Group was 4 and the incidence of PFO was 6.45%. The incidence of PFO in the Test Group was significantly higher than that in the Control Group, suggested that the PFO was closely related to stroke. Further regression analysis of the risk factors of ischemic stroke in the two groups showed that PFO was a risk factor for ischemic stroke.

The mechanism of the PFO leading to ischemic stroke is currently unclear. However, there are the following mechanisms for the ischemic stroke caused by the PFO, and the most likely mechanism is considered to be abnormal embolism. That is, when the right heart pressure increases, such as pulmonary hypertension, cough, Valsalva action, the venous system or right heart embolism enters the systemic circulation, resulting in the abnormal right-to-left shunt channel formed by PFO, resulting in the occurrence of ischemic stroke. Some studies proposed that the diagnostic criteria for abnormal embolism include deep vein thrombosis and pulmonary embolism, there is an abnormal channel between the left and right hearts, and there is a pressure gradient from right to left shunt in the heart, with imaging or pathology ^[23, 24]. However, it has been found in clinical work that only a few patients with PFO-related ischemic stroke can find venous thrombosis. At the same time, many patients do not have pulmonary hypertension or do not perform Valsalva maneuvers at the time of onset. Therefore, there is no source of emboli or incentives to increase the pressure of the right heart, which does not support the theory of abnormal embolism ^[25]. However, some scholars have pointed out that the emboli that cause PFO-related ischemic stroke are mostly from the deep veins and are asymptomatic. Studies have found that the incidence of pelvic deep vein thrombosis in stroke patients with unclear etiology is significantly higher than that of stroke with clear etiology patients (20% vs 4%) ^[26]. However, the sensitivity of current auxiliary examination methods is too low, and ultrasound examination cannot detect pelvic deep vein thrombosis, and even the detection rate of deep vein thrombosis of the lower extremities is also low. High conditions also limit the clinical traceability of the source of emboli. Eaggars et al. ^[27] believe that the mechanism of abnormal embolism of PFO without venous thrombosis may be related to the hypercoagulable state caused by transient platelet activation induced by the load state, causing transient thrombosis, and thus the occurrence of embolism. In situ thrombosis caused by PFO is also considered to be one of the mechanisms. PFO is a structure similar to a pipe, in which blood may accumulate, theoretically causing the generation of local eddy currents and forming thrombus. However, no case report of PFO thrombosis in situ has been found. Other mechanisms include arrhythmias such as paroxysmal atrial fibrillation, abnormal coagulation functions such as S protein dysfunction, abnormal protein C activation, and prothrombin gene mutations such as G20210AF2, leading to thrombosis ^[27, 28].

Several studies have found that embolism caused by PFO is related to the size and shunt volume of PFO ^[29, 30]. The larger the diameter of PFO, the greater the shunt volume, and the higher the probability of cerebral embolism ^[31]. In this study, there were 4 patients with large and moderate PFO in the Test Group, accounting for 23.53%. A large number of shunt patients were not found in the Control Group. The Test Group was significantly higher than the Control Group, suggesting that medium and large shunts may be a high-risk factor for ischemic stroke, and also suggested that abnormal embolism may be the mechanism of stroke.

Common risk factors for ischemic stroke include hypertension, diabetes, coronary heart disease, hyperlipidemia, and carotid atherosclerosis^[32, 33]. However, the risk factors for ischemic stroke with PFO have their own characteristics. Josep et al.^[34] compared the risk factors of stroke patients with PFO and stroke patients without PFO and found that stroke patients with PFO were younger and had fewer traditional vascular risk factors such as hypertension, dyslipidemia and smoke, etc^[35]. In this study, we compared the common risk factors of stroke patients in PFO (+) group and PFO (-) group to explore the characteristics of risk factors of patients with ischemic stroke combined with PFO. We found that the proportion of patients with migraine in the PFO (+) group was significantly higher than those in the PFO (-) group, suggesting that stroke patients with PFO were more likely to have migraine. And related research shows that PFO is closely related to migraine, especially with migraine with aura^[36].

Conclusions

In summary, shunt volume of the PFO is related to ischemic stroke and may be a risk factor for ischemic stroke.

Abbreviations

CS: cryptogenic stroke; PFO: patent foramen ovale.

Declarations

Acknowledgments and Funding

Funding: This study was supported by National Natural Science Foundation of China (81100972 to WJJ) .

Availability of data and materials

The datasets during and analysed during the current study available from the corresponding author on reasonable request.

Authors' contributions

XCS and WJJ conceived and coordinated the study, designed, performed and

analyzed the experiments, wrote the paper. YZ, LM, YL, JM carried out the data collection, data analysis, and revised the paper. All authors reviewed the results and approved the final version of the manuscript.

Ethics approval and consent to participate

The study protocol was reviewed and approved by the Qilu Hospital of Shandong University Ethical Committee. Patients gave informed consent prior to study participation.

Consent for publication

No personal information is included in this study.

Author disclosure statement

The authors declare no competing financial interests.

References

1. Di Stefano V, Di Fulvio M, Di Liberato L, et al. Paradoxical embolism through a patent foramen ovale from central venous catheter thrombosis: A potential cause of stroke. *J Neurol Sci*. 2020;414:116820.
2. Sagris D, Georgiopoulos G, Perlepe K, et al. Antithrombotic Treatment in Cryptogenic Stroke Patients With Patent Foramen Ovale: Systematic Review and Meta-Analysis. *Stroke*. 2019;50(11):3135–40.
3. Vaduganathan M, Qamar A, Gupta A, et al. Patent Foramen Ovale Closure for Secondary Prevention of Cryptogenic Stroke: Updated Meta-Analysis of Randomized Clinical Trials. *Am J Med*. 2018;131(5):575–7.
4. Lattanzi S, Brigo F, Cagnetti C, et al. Patent Foramen Ovale and Cryptogenic Stroke or Transient Ischemic Attack: To Close or Not to Close A Systematic Review and Meta-Analysis. *Cerebrovasc. Dis*. 2018, 45.
5. Kasner SE, Thomassen L, Søndergaard L, et al. Patent foramen ovale closure with GORE HELEX or CARDIOFORM Septal Occluder vs. antiplatelet therapy for reduction of recurrent stroke or new brain infarct in patients with prior cryptogenic stroke: Design of the randomized Gore REDUCE Clinical Study. *Int J Stroke*. 2017;12(9):998–1004.
6. Ntaios G, Papavasileiou V, Sagris D, et al. Closure of Patent Foramen Ovale Versus Medical Therapy in Patients With Cryptogenic Stroke or Transient Ischemic Attack: Updated Systematic Review and Meta-Analysis. *Stroke*. 2018;49(2):e210.
7. Lee PH, Song JK, Kim JS, et al. Cryptogenic Stroke and High-Risk Patent Foramen Ovale: The DEFENSE-PFO Trial. *J Am Coll Cardiol*. 2018;71(20):2335–42.

8. Agboola KM, Lee JM, Liu X, et al. Interaction of cardiac implantable electronic device and patent foramen ovale in ischemic stroke: A case-only study. *Pacing Clin Electrophysiol*. 2019;42(3):341–8.
9. Wiktor DM, Carroll JD. The Case for Selective Patent Foramen Ovale Closure After Cryptogenic Stroke. *Circ Cardiovasc Interv*. 2018;11(3):e004152.
10. Vidale S, Russo F, Campana C, et al. Patent Foramen Ovale Closure Versus Medical Therapy in Cryptogenic Strokes and Transient Ischemic Attacks: A Meta-Analysis of Randomized Trials. *Angiology*. 2019;70(4):325–31.
11. Elmariah S, Furlan AJ, Reisman M, et al. Predictors of recurrent events in patients with cryptogenic stroke and patent foramen ovale within the CLOSURE I (Evaluation of the STARFlex Septal Closure System in Patients With a Stroke and/or Transient Ischemic Attack Due to Presumed Paradoxical Embolism Through a Patent Foramen Ovale) trial. *JACC Cardiovasc Interv*. 2014;7(8):913–20.
12. Niu X, Ou-Yang G, Yan PF, et al. Closure of patent foramen ovale for cryptogenic stroke patients: an updated systematic review and meta-analysis of randomized trials. *J Neurol*. 2018;265(6):1259–68.
13. Saver JL, Carroll JD, Thaler DE, et al. Long-Term Outcomes of Patent Foramen Ovale Closure or Medical Therapy after Stroke. *N. Engl. J. Med*. 2017, 377(11).
14. Zhang XL, Kang LN, Wang L, et al. Percutaneous closure versus medical therapy for stroke with patent foramen Ovale: a systematic review and meta-analysis. *BMC Cardiovasc Disord*. 2018;18(1):45.
15. Kim M, Kim S, Moon J, et al. Effect of patent foramen ovale closure for prevention on recurrent stroke or transient ischemic attack in selected patients with cryptogenic stroke. *J Interv Cardiol*. 2018;31(3):368–74.
16. Pasceri V, Pelliccia F, Bressi E, et al. Net clinical benefit of patent foramen ovale closure in patients with cryptogenic stroke: Meta-analysis and meta-regression of randomized trials. *Int J Cardiol*. 2018;266:75–80.
17. Mirzada N, Ladenvall P, Hansson PO, et al. Quality of life after percutaneous closure of patent foramen ovale in patients after cryptogenic stroke compared to a normative sample. *Int J Cardiol*. 2018;257:46–9.
18. Hagen PT, Scholz DG, Edwards WD. Incidence and size of patent foramen ovale during the first 10 decades of life: An autopsy study of 965 normal hearts. *Mayo Clin Proc*. 1984;59(1):17–20.
19. Overell JR, Bone I, Lees KR. Interatrial septal abnormalities and stroke: A meta-analysis of case-control studies. *Neurology*. 2000;55(8):1172–9.
20. Mattle HP, Meier B, Nedeltchev K. Prevention of stroke in patients with patent foramen ovale. *Int J Stroke*. 2010;5(2):92–102.
21. Cabanes L, Mas JL, Cohen A, et al. Atrial septal aneurysm and patent foramen ovale as risk factors for cryptogenic stroke in patients less than 55 years of age. *Stroke*. 1993;24(12):1865–73.
22. Kent DM, Dahabreh IJ, Ruthazer R, et al. Anticoagulant vs. antiplatelet therapy in patients with cryptogenic stroke and patent foramen ovale: An individual participant data meta-analysis. *Eur Heart J*. 2015;36(35):2381–9.

23. Kheiri B, Abdalla A, Osman M, et al. Patent foramen ovale closure versus medical therapy after cryptogenic stroke: An updated meta-analysis of all randomized clinical trials. *Cardiol J*. 2019;26(1):47–55.
24. Han Y, Zhang X, Zhang F. Patent foramen ovale closure by using transesophageal echocardiography for cryptogenic stroke: single center experience in 132 consecutive patients. *J Cardiothorac Surg*. 2020;15(1):11.
25. Carroll AM, Carroll JD. Device Closure of Patent Foramen Ovale for Cryptogenic Stroke: Patient Selection and Outcomes According to New Randomized Trials. *Curr Cardiol Rep*. 2019;21(6):48.
26. Vukadinović D, Schirmer SH, Vukadinović AN, et al. Interventional closure vs. medical therapy of patent foramen ovale for secondary prevention of stroke: updated meta-analysis. *Clin Res Cardiol*. 2019;108(2):157–66.
27. Eggers AE. A new theory of cryptogenic stroke and its relationship to patent foramen ovale; or, the puzzle of the missing extra risk. *Med Hypotheses*. 2006;67(5):1072–5.
28. Botto N, Spadoni I, Giusti S, et al. Prothrombotic mutations as risk factors for cryptogenic ischemic cerebrovascular events in young subjects with patent foramen ovale. *Stroke*. 2007;38(7):2070–3.
29. Goliszek S, Wiśniewska M, Kurnicka K, et al. Patent foramen ovale increases the risk of acute ischemic stroke in patients with acute pulmonary embolism leading to right ventricular dysfunction. *Thromb Res*. 2014;134(5):1052–6.
30. Volpi JJ, Ridge JR, Nakum M, et al. Cost-effectiveness of percutaneous closure of a patent foramen ovale compared with medical management in patients with a cryptogenic stroke: from the US payer perspective. *J Med Econ*. 2019;22(9):883–90.
31. Kim YD, Song D, Nam HS, et al. D-dimer for prediction of long-term outcome in cryptogenic stroke patients with patent foramen ovale. *Thromb Haemost*. 2015;114(3):614–22.
32. Lim ST, Murphy SJX, Smith DR, et al. Clinical outcomes and a high prevalence of abnormalities on comprehensive arterial and venous thrombophilia screening in TIA or ischaemic stroke patients with a patent foramen ovale, an inter-atrial septal aneurysm or both. *J Neurol Sci*. 2017;377:227–33.
33. Odunukan OW, Price MJ. Current Dataset for Patent Foramen Ovale Closure in Cryptogenic Stroke: Randomized Clinical Trials and Observational Studies. *Interv Cardiol Clin*. 2017;6(4):525–38.
34. Rodés-Cabau J, Noël M, Marrero A, et al. Atherosclerotic burden findings in young cryptogenic stroke patients with and without a patent foramen ovale. *Stroke*. 2009;40(2):419–25:419 – 25.
35. Jaffre A, Guidolin B, Ruidavets JB, et al. Non-obstructive carotid atherosclerosis and patent foramen ovale in young adults with cryptogenic stroke. *Eur J Neurol*. 2017;24(5):663–6.
36. Xu HB, Zhang H, Qin Y, et al. Patent foramen ovale closure versus medical therapy for cryptogenic stroke: An updated meta-analysis. *J Neurol Sci*. 2018;390:139–49.

Figures

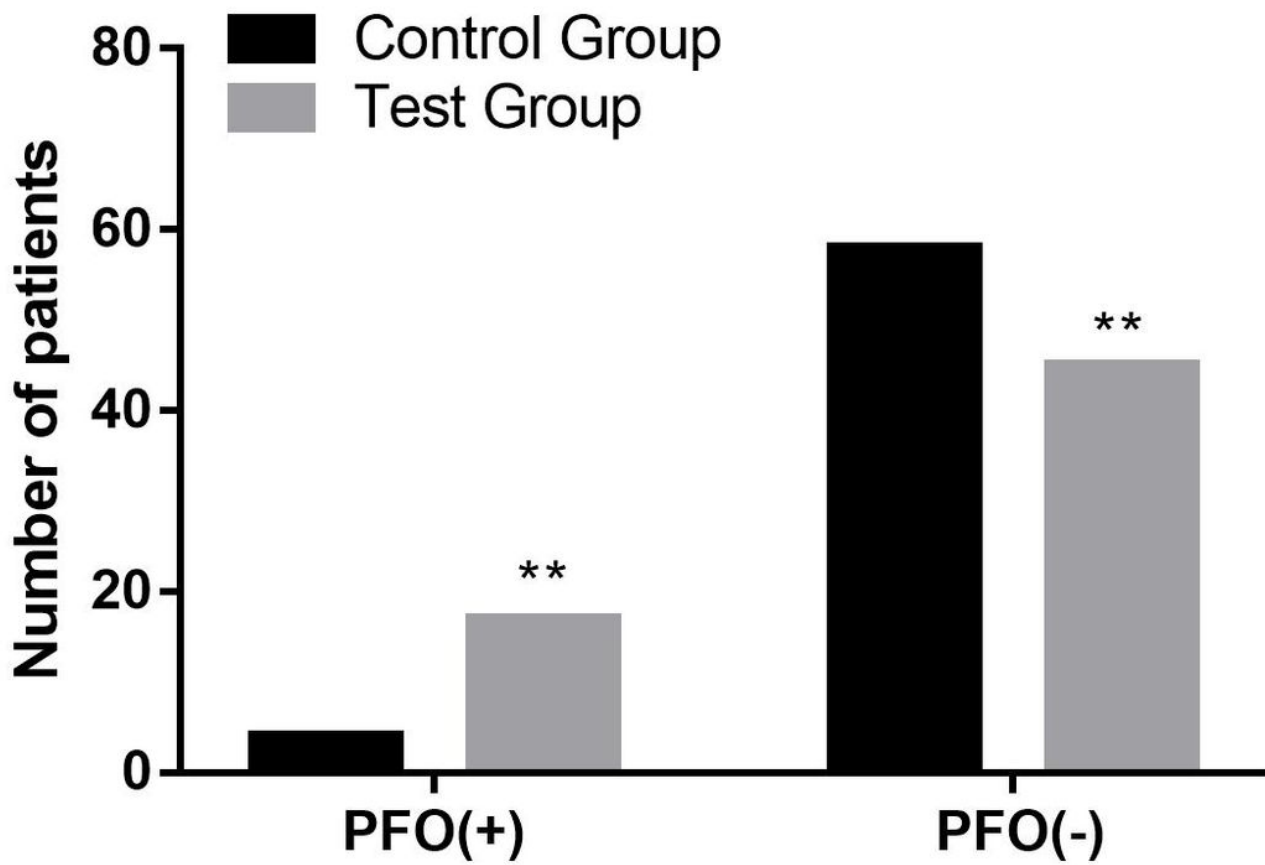


Figure 1

The occurrence of PFO in Test Group and Control Group. Test Group vs. Control Group: **p < 0.01.

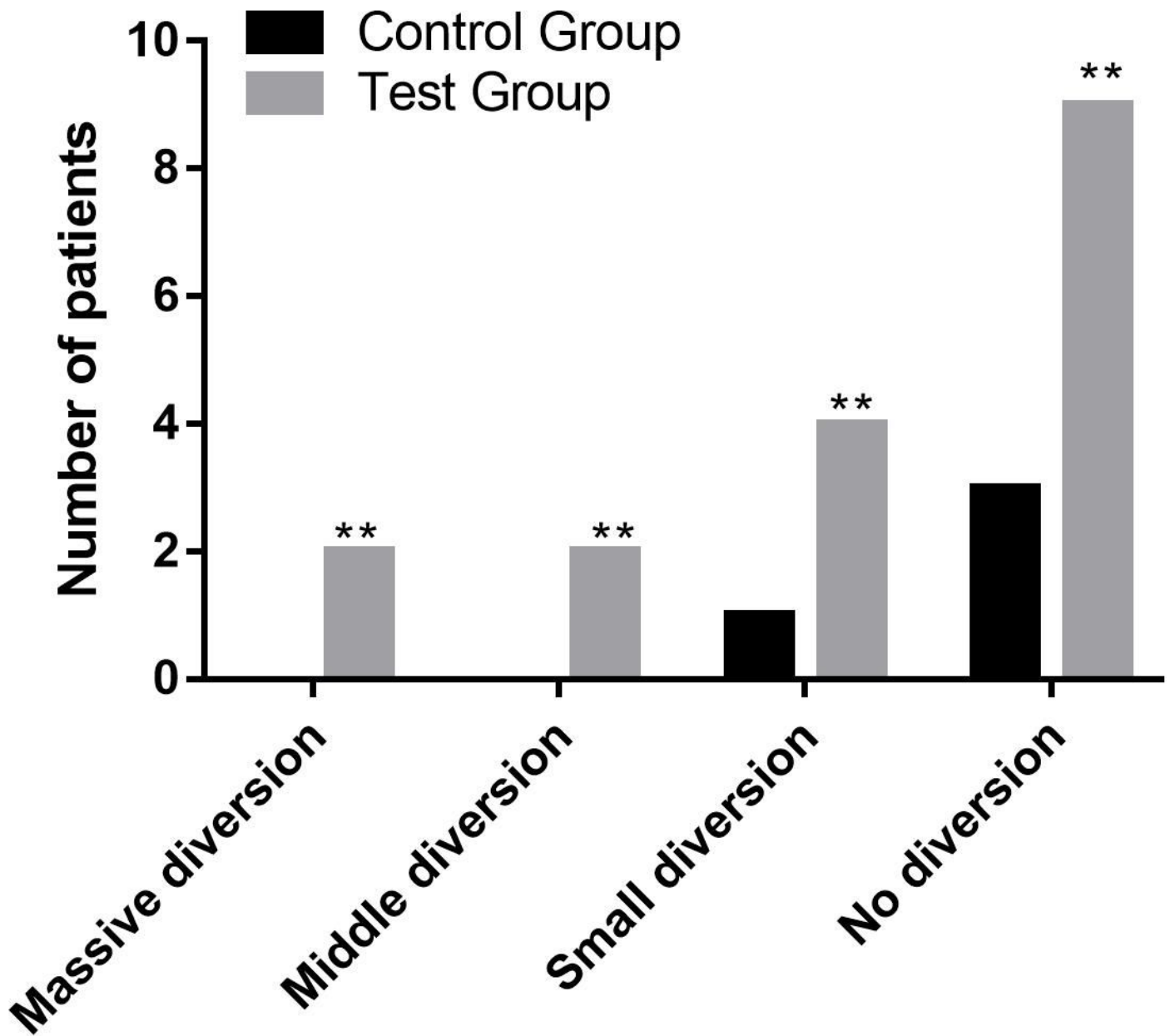


Figure 2

The shunt degree of PFO in Test Group and Control Group. Test Group vs. Control Group: ** $p < 0.01$.