

Currarino Syndrome in a China children's health institute: on diagnosis and surgical treatment

Wenbo Pang

General surgery department, Beijing Children's Hospital, Capital Medical University, National Center for Children's Health

Yajun Chen (✉ chenyajun@bch.com.cn)

General surgery department, Beijing Children's Hospital, National Center for Children's Health

<https://orcid.org/0000-0003-4711-7030>

Chunhui Peng

General surgery department, Beijing Children's Hospital, Capital Medical University, National Center for Children's Health

Kai Wang

General surgery department, Beijing Children's Hospital, Capital Medical University, National Center for Children's Health

Xiang Qi

Neurosurgery department, Beijing Children's Hospital, Capital Medical University, National Center for Children's Health

Zengmeng Wang

General surgery department, Beijing Children's Hospital, Capital Medical University, National Center for Children's Health

Dongyang Wu

General surgery department, Beijing Children's Hospital, Capital Medical University, National Center for Children's Health

Dan Zhang

General surgery department, Beijing Children's Hospital, Capital Medical University, National Center for Children's Health

Qiulong Shen

General surgery department, Beijing Children's Hospital, Capital Medical University, National Center for Children's Health

Research

Keywords: Currarino syndrome, Diagnosis, Operative, Treatment

Posted Date: April 21st, 2020

DOI: <https://doi.org/10.21203/rs.3.rs-23350/v1>

License:  This work is licensed under a Creative Commons Attribution 4.0 International License.

[Read Full License](#)

Abstract

Background Currarino syndrome is a rare disease which needs multidisciplinary management. Misdiagnosis with mal-management is common in children. This study was to summarize the clinical features of children diagnosed with Currarino syndrome in a China institute, with an emphasis on diagnosis and surgical treatment, in order to aid in the diagnosis and determination of the optimal operative treatment.

Results From 2016 to 2018, seven patients were diagnosed with Currarino syndrome in our department. One patient was male and six were female, with an admission age of 27.00(16.00, 44.00) months. In four patients, diagnosis of the presacral masses had been missed. Ultrasonography, plain sacral radiographs, contrast enemas and magnetic resonance imaging are necessary for the prompt diagnosis of this syndrome. The initial treatment involved a sagittal anorectoplasty and resection of the mass, followed by a defunctioning ostomy and closure of the stoma in a staged multidisciplinary approach. A limited sagittal route was chosen for the surgical treatment in this group. After closure of the ileostomy or colostomy, bowel function was satisfactory in all children.

Conclusion Improved knowledge of the different clinical signs and symptoms of Currarino syndrome will result in appropriate imaging and prompt diagnosis. A protocol with rational timing of multidisciplinary surgical procedures may help to avoid undesirable outcomes. The limited sagittal route is available for effective operative treatment.

Background

Currarino syndrome is a rare triad that consists of sacral dysgenesis, presacral masses and anorectal malformation (ARM). It was first described by Currarino et al. [1] in 1981. The expressivity of Currarino syndrome is variable. It can present as an imperforate anus at birth, as intractable constipation due to anorectal stenosis or extrinsic compression from a presacral mass, or as an acute or recurrent meningitis [2]. To date, few reports on surgical treatment and clinical outcomes have been published. In Asia, such patients are more common than in Europe or America. However, the misdiagnosis and inappropriate treatment of this disorder are not uncommon.

This study was conducted in a large health center for children in Asia. We describe the different clinical presentations and imaging findings, especially related to the surgical management and clinical outcomes of children diagnosed with Currarino syndrome in our department. Special attention was focused on excluding missed diagnoses and selecting the proper operative management. This report may provide useful information to aid in the rapid diagnosis and determination of the optimal operative treatment.

Methods

This study aimed to aid in the diagnosis and determination of the optimal operative treatment of Currarino syndrome. A retrospectively study was designed to summarize the clinical features of children

diagnosed with Currarino syndrome in our institute, with an emphasis on diagnosis and surgical treatment.

The clinical materials of children diagnosed with Currarino syndrome from 2016 to 2018 were retrospectively evaluated. Clinical data were extracted from the case records. The case history, clinical manifestations, imaging findings, surgical treatment, pathology and clinical outcomes were summarized. All patients were followed up through telephone contact and the outpatient service. Bowel and urinary function were recorded during follow-up. Presacral ultrasound (US) was conducted routinely to exclude recurrence of the presacral mass.

All the data were analyzed using SPSS for Windows version 18.0. Normally distributed data were presented as the mean \pm standard deviation. Nonnormally distributed data were presented as the median (first quartile, third quartile). Categorical variables were presented as frequencies and percentages.

Results

The medical records of the seven patients included were reviewed, and the main clinical characteristics are listed (Table 1). One patient was male and six were female, with an admission age of 27.00(16.00, 44.00) months (ranging from six to 47 months). Four patients complained of intractable constipation, and two of them(case one and five) had undergone one operation for an ARM in other institutes before they visited our hospital. The set of twins included in this study(case two and three) were first treated in the neonatal surgery department for intestinal obstruction due to an ARM after birth, after which colostomy and anoplasty were conducted. Then, case two was treated in our department following unsatisfactory anoplasty results, and case three underwent resection of a presacral mass. There was another patient(case seven) came to our hospital to remove the presacral mass after an anoplasty in a local hospital. After resection of the presacral teratoma, severe CNS infection and CSF leakage occurred due to iatrogenic injury to the rectum, and a colostomy was done then. However, a buttock sinus tract from rectum to presacral area was left and discharged pus through anus. Besides the complaint described, case one had urinary retention before admission, case four suffered from urinary tract infection when admission, and case five had rectovaginal fistula due to perineal infection before the first anoplasty.

Sacral X-ray, colostogram, presacral US, urinary US, echocardiography (ECHO) and magnetic resonance imaging (MRI) were routinely conducted in all patients, and urodynamic testing was performed in three patients suspected to have urinary abnormalities. X-ray analysis of the sacrum, barium/urografin enema, presacral US, urinary US and ECHO were performed as regular preoperative examinations to exclude accompanied anomalies in patients with ARM. Sacral anomalies were found in all patients. Colostogram suggested dilated colon in case one and case five. Six patients were suspected of having a presacral mass by presacral US, and MRI of the pelvis and spine was then performed to make a definite diagnosis. Only one patient (case five) was not diagnosed with a presacral mass till a digital rectal examination (DRE) indicated the mass immediately before the anoplasty, and MRI was then performed. Urinary US

examination was normal for all patients except the male patient with residual urine of 88ml. The ECHO results were normal for all patients in this group.

In addition to these imaging examinations, a urodynamic examination was also performed in patients suspected to have urodynamic dysfunction. Cases one and four presented with urinary retention and infection respectively before the operation, and MRI analysis confirmed a tethered spinal cord as well as anterior meningocele in case one and a micturating cystourethrogram (MCU) confirmed left vesicoureteral reflux (VUR) in case four. Both patients underwent urodynamic examinations, which showed decreased bladder compliance only in case one. Five patients in this group had tethered cords as detected by MRI.

Case one to six underwent surgical treatment through a limited sagittal route (Figure one). With the patient in the lithotomy position, a sagittal incision was made for mobilization of the anorectum and exploration of the presacral space. We started by dissection of the fascia around the posterior and the lateral aspects of the rectum. After mobilization of the anorectum, a retrorectal cyst was found and excised. The anterior sacral meningocele was repaired by a neurosurgeon through the same approach. Then, the steps of pull-through of megacolon(case one and five) and after that anoplasty were completed by reconstruction of the levator ani and striated muscle complex around the neorectum. A colostomy or ileostomy was also performed to prevent wound infection and intracranial infection. For case seven, the excision of presacral mass was firstly carried on without colostomy. After CNS infection happened, colostomy was done. Two years later, the third operation was suggested. And a posterior sagittal incision was made to expose the buttock sinus tract from the posterior wall of rectum to dura mater, then the sinus tract was excised with help of a neurosurgeon and anorectoplasty was completed successively. Closure of the stoma was carried on three to six month later for all patients with stoma. The pesacral mass of case four had no connection with spinal canal and there was no failed operation before, so we chose to spare her from ostomy.

Pathological examinations of the seven patients resulted in three being diagnosed with meningoceles accompanied with benign teratomas, and the other four patients were diagnosed with benign teratomas.

All patients are thriving with excellent cosmetic and functional results at follow-up apart from case one-catheterization was needed for urinary incontinence. Further urologic and neurologic counseling has been suggested for this patient.

Discussion

In this article, the case history, clinical presentations, imaging findings, surgical management, pathology and clinical outcome of Currarino syndrome were described for seven pediatric patients.

The expressivity of this triad is variable, and the clinical manifestations comprise a complex spectrum. As reported in other countries, patients with Currarino syndrome present with an ARM, which is usually in the form of an anorectal stenosis [3]. In this study, a perineal fistula without an anus was the most prevalent

presentation. Constipation is the most commonly reported symptom [4]. The syndrome can present as an imperforate anus at birth and intractable constipation due to anorectal stenosis or extrinsic compression by a presacral mass. The presacral mass can result in urinary incontinence, sacral anesthesia, paraesthesia of the lower extremities, disturbance of anal sphincter control, headache when exercising, or acute or recurrent meningitis [5,6]. Other symptoms include recurrent urinary tract infections, nausea, lumbar pain, and chronic anal fistula [7]. Among our seven cases, the twin patients presented with urgent intestinal obstruction due to an imperforate anus with a perineal fistula at birth. Four of the other five patients suffered from constipation even after anoplasty, including one patient (case one) with symptoms of urinary retention and constipation and another patient (case four) who suffered from urinary infection due to left VUR.

Currarino syndrome is related to mutation of the MNX1 gene, previously called the HLXB9 gene. Mutations in the coding sequence of the MNX1 gene have been reported in nearly all familial cases and in approximately 30% of sporadic cases [8]. The identical twin patients in this study and their parents underwent genetic testing and initial pedigree screening. No genetic mutations of MNX1 or any other defective genes were found. The other five patients did not undergo genetic testing.

The routine and necessary imaging approach includes a radiograph of the sacrum, presacral US and spinal MRI. Patients with an ARM must undergo multiple radiologic examinations, including vertebral radiographs, to evaluate vertebral anomalies, abdominal and pelvic US to evaluate urogenital abnormalities, an MRI of the pelvis and spine to evaluate the complexity of the malformation, and a colostogram to observe the colon and underlying fistulous tract from the rectum to either the bladder or urethra [9]. In addition to these imaging examinations, a urodynamic examination is necessary in patients with urodynamic dysfunction [10].

Among neural tube defects (NTD), a tethered cord is commonly found to be associated with an anterior meningocele [11]. All patients with anterior meningoceles in this group presented with a tethered cord, as confirmed by MRI. Urologic involvement may be characterized by a duplex ureter, horseshoe or duplex kidney, VUR, dysplastic kidneys, or hypospadias. Therefore, the urinary tract should be examined in all patients with Currarino syndrome by US, and in cases of radiologic or clinical suspicions of VUR, an MCU should be performed [12]. Gynecologic malformations, including a bicornuate uterus, septate vagina, and bifid clitoris, were also noted [13,14]. Three girls (50%) had gynecologic malformations. Other associations of Currarino syndrome with Hirschsprung's disease (HD), Down's syndrome, and cranial and central nervous anomalies have been described [13,15]. One of the twin patients (case three) in our study was diagnosed with hydrocephalus and received a ventriculoperitoneal shunt at four months of age in a local institute. In the case of constipation, a rectal suction biopsy has been suggested to exclude HD or other dysganglionoses [12]. Two patients (cases one and five) suffered from intractable constipation and were diagnosed with a dilated colon after anoplasty; HD was excluded by operative pathology.

The management of Currarino syndrome generally consists of treatment of ARMs and the presacral mass. A presacral mass may be approached surgically through a posterior sagittal approach attained by

an incision from the sacrum to the anus [16]. The prone position is the standard approach for posterior sagittal anorectoplasty (PSARP) in males; however, in females, the supine position can be used as an alternative [17]. Meanwhile, the supine lithotomy position provided better access to explore the presacral space. In this study, a limited sagittal route was performed. The patient was put in lithotomy position, and the mass was attained by an incision from the anus to the point large enough to explore, which usually in front of the sacrum. This route allowed for the excision of the presacral mass with a smaller incision, followed by dural closure and anoplasty. In cases one and five, after the removal of the presacral mass and the closure of the meningocele pedicle, the dilated descending colon and rectum were excised due to myofibrosis and hypoperistalsis, followed by anastomosis of the remaining colon and anus. The patients in cases one, two and five underwent insufficient treatment before they came to our department; therefore, excision of the presacral mass and repeat anoplasty were performed. The patient in case three came to remove the presacral mass after an anoplasty elsewhere. The patient in case seven came for severe postoperative complication— a buttock sinus tract was found and excised then. For patients with anoplasty failure, the limited sagittal route allows for a good cosmetic result with a minimal incision and a favorable resolution of the coexisting problems. In this group, anal dilation for 3 to 6 m was conducted after anoplasty to prevent stenosis.

Palliative surgery is initially performed in infants born with an ARM to divert the colon and allow the patient to mature before definitive surgery. The initial palliative surgery of an imperforate anus includes a colostomy to allow the enteric contents to evacuate while an additional stoma is created for the distal colon [18]. Cases two and three underwent colostomy after birth for intestinal obstruction due to an imperforate anus. Four of the other patients received ileostomy in our department after removal of the presacral mass and anoplasty to prevent CNS infection and ensure healing of the incision. We prefer to use the terminal ileum for the stoma because it is easier to perform without disturbing the pelvic cavity. Meanwhile, it is also easier to be closed after healing of the incision.

Pathologically, the presacral mass that accompanies Currarino syndrome may consist of a teratoma, a hamartoma, a neurenteric cyst, an anterior meningocele or a combination of these four entities. Dermoid cysts, lipomas, leiomyosarcomas, yolk sac tumors and carcinoid tumors have been described as well. Currarino syndrome may be occasionally associated with epidermoid cysts. However, the most frequent pathologies described are anterior sacral meningoceles and teratomas [16]. Presacral meningoceles are the most common entity (60% of patients) [9]. Mature presacral teratomas were the prevalent presentations in these seven cases, and five of them had connection with the spinal canal. That is also the reason a neurosurgery expert should be included in the multidisciplinary team. No malignant mass was recorded in this group. However, an oncologist is always needed to make proper protocol especially when malignancy is supposed there.

During follow-up, particular attention should be paid to bowel and bladder function, and constipation, if present, should be treated [12]. All patients are thriving with excellent cosmetic and functional results at follow-up apart from urinary incontinence in one patient with a neurogenic bladder. The patient with VUR

received antibiotic prophylaxis. If surgical treatment of VUR is indicated, it should be performed last. For such patients, further urologic and neurologic counseling are necessary.

A delayed or missed diagnosis of a presacral mass is common when there is no or limited experience in detecting and treating these cases. A lack of proper imaging leads to misdiagnoses and insufficient repair, requiring reoperation. Four patients in this study presented with unfavorable ARM operation results and an undiagnosed presacral mass. One of the twins included in this study was diagnosed in the neonatal department of our institution but did not receive treatment for the presacral mass when the ARM was treated due to a lack of experience. Case seven suffered from severe CNS infection due to iatrogenic injury to the rectum and lack of colostomy during removal of the mass in the oncology department. For such patients, the presacral mass is adherent to the posterior wall of rectum and usually has a connection with the spinal canal, a diverting colostomy or ileostomy is necessary. Regarding the complains and rough courses of most of the patients in this study, a multidisciplinary team of general surgy, neurosurgery, oncology and urology is necessary for optimal treatment of children with Currarino syndrome.

Conclusions

Improved knowledge of the different clinical signs and symptoms of Currarino syndrome can result in appropriate imaging and prompt diagnosis of this condition. When congenital ARMs and sacral defects are present, presacral US and MRI should be performed to determine the presence of a presacral mass. A protocol with rational timing of multidisciplinary surgical procedures may help to avoid undesirable outcomes. The limited sagittal route is available for effective operative treatment.

Abbreviations

ARM: anorectal malformation

US: ultrasound

CNS: central nervous system

CSF: cerebral spinal fluid

ECHO: echocardiography

MRI: magnetic resonance imaging

DRE: digital rectal examination

MCU: micturating cystourethrogram

VUR: vesicoureteral reflux

NTD: neural tube defects

HD: Hirschsprung's disease

PSARP: posterior sagittal anorectoplasty

Declarations

Ethics approval and consent to participate

All procedures performed in studies involving human participants were in accordance with the ethical standards and approved by the Medical Ethics Committee of Beijing Children's Hospital. We retrospectively reported the data without providing any individual details.

Consent for publication

Not applicable.

Availability of data and material

All data generated or analysed during this study are included in this published article.

Competing interests

The authors declare that they have no competing interests.

Funding

No funding was obtained for this study.

Authors' contributions

WBP and YJC designed the study, drafted the initial manuscript, and reviewed and revised the manuscript. CHP, KW, XQ, ZMW, DYW, DZ and QLS coordinated and supervised data collection, and critically reviewed the manuscript for important content. All authors have read and approved the manuscript, and ensure that this is the case.

Acknowledgment

Not applicable.

References

[1]Currarino G, Coln D, Votteler T.Triad of anorectal, sacral, and presacral anomalies. AJR Am J Roentgenol.1981;137:395-8.

- [2]Caro-Domínguez P, Bass J, Hurteau-Miller J. Currarino Syndrome in a Fetus, Infant, Child, and Adolescent: Spectrum of Clinical Presentations and Imaging Findings. *Can Assoc Radiol J.* 2017;68:90-5.
- [3]Patel RV, De Coppi P, Kiely E, et al. Currarino's syndrome in twins presenting as neonatal intestinal obstruction. *BMJ Case Rep.* 2014 Sep 8;2014.
- [4]Arora P, Purai N, Rajpurkar M, et al. A missed case of Currarino syndrome. *Clin Pediatr (Phila).* 2010;49:183-5.
- [5]Versteegh HP, Feitz WF, van Lindert EJ, et al. "This bicycle gives me a headache", a congenital anomaly. *BMC Res Notes.* 2013; 6:412.
- [6]Morgenstern Isaak A, Bach Faig A, Martínez S, et al. Recurrent meningitis due to anatomical defects: The bacteria indicates its origin. *An Pediatr (Barc).* 2015;82:388-96.
- [7]Kassir R, Kaczmarek D. A late-recognized Currarino syndrome in an adult revealed by an anal fistula. *Int J Surg Case Rep.* 2014;5:240-2.
- [8]Merello E, De Marco P, Ravegnani M, et al. Novel MNX1 mutations and clinical analysis of familial and sporadic Currarino cases. *Eur J Med Genet.* 2013;56: 648-54.
- [9]Lee JK, Towbin AJ. Currarino Syndrome and the Effect of a Large Anterior Sacral Meningocele on Distal Colostogram in an Anorectal Malformation. *J Radiol Case Rep.* 2016; 10:16-21.
- [10]Pio L, Piatelli G, Rossi A, et al. Urological outcome in patients with Currarino syndrome. *J Pediatr Surg.* 2014;49: 1643-6.
- [11]Gudinchet F, Maeder P, Laurent T, et al. Magnetic resonance detection of myelodysplasia in children with Currarino triad. *Pediatr Radiol.* 1997;27:903-7.
- [12]Martucciello G, Torre M, Belloni E, et al. Currarino Syndrome: Proposal of a Diagnostic and Therapeutic Protocol. *J Pediatr Surg.* 2004;39:1305-11.
- [13]Belloni E, Martucciello G, Verderio D, et al. Involvement of the HLXB9 Homeobox gene in Currarino syndrome. *Am J Hum Genet.* 2000;66:312-9.
- [14]Lynch SA, Yiming W, Strachan T, et al. Autosomal dominant sacral agenesis: Currarino syndrome. *J Med Genet.* 2000;37:561-6.
- [15]Hofmann AD, Puri P. Association of Hirschsprung's disease and anorectal malformation: a systematic review. *Pediatr Surg Int.* 2013;29:913-7.
- [16]Kansal R, Mahore A, Dange N, et al. Epidermoid Cyst Inside Anterior Sacral Meningocele in an Adult Patient of Currarino Syndrome Manifesting with Meningitis. *Turk Neuro surg.* 2012;22:659-61.

[17]AbouZeid AA, Mohammad SA, Seada M, et al. Currarino Triad: Importance of Preoperative Magnetic Resonance Imaging. *European J Pediatr Surg Rep.* 2019;7:e86-e89.

[18]Levitt MA, Peña A. Anorectal Malformations. *Orphanet J Rare Dis.*2007;2:33.

Table

Table 1 Characteristics of Patients with Currarino Syndrome

No.	Sex	Age	Complaint	Family	ARM	Presacral Mass	Previous Operation	Surgery	Other Associated Anomalies
1	M	47m	Constipation	-	PF	M+BT	AP	Soave+RM+AP+I	TC+neurogenic bladder
2	F	6m	AP failure	-	PF	M+BT	AP+C	RM+AP	TC+didelphia
3	F	23m	Presacral mass	-	PF	BT	AP+C	RM+AP	TC+didelphia+hydrocephalus
4	F	16m	Constipation	-	PF	BT	-	RM+AP+I	VUR+bicornuate uterus
5	F	34m	Constipation	-	PF	BT	AP	Soave+RM+AP+I	TC+double vagina
6	F	27m	Constipation	-	PF	M+BT	-	RM+AP+I	TC
7	F	44m	BST	-	PF	BT	AP, RM	EST+AP+I	-

Abbreviations: ARM, anorectal malformation; PF, perineal fistula; M, meningocele; BT, benign teratoma; RM, resection of mass; AP, anoplasty; C, colostomy; I, ileostomy; TC, tethered cord; BST, buttock sinus tract; EST, excision of sinus tract.

Figures

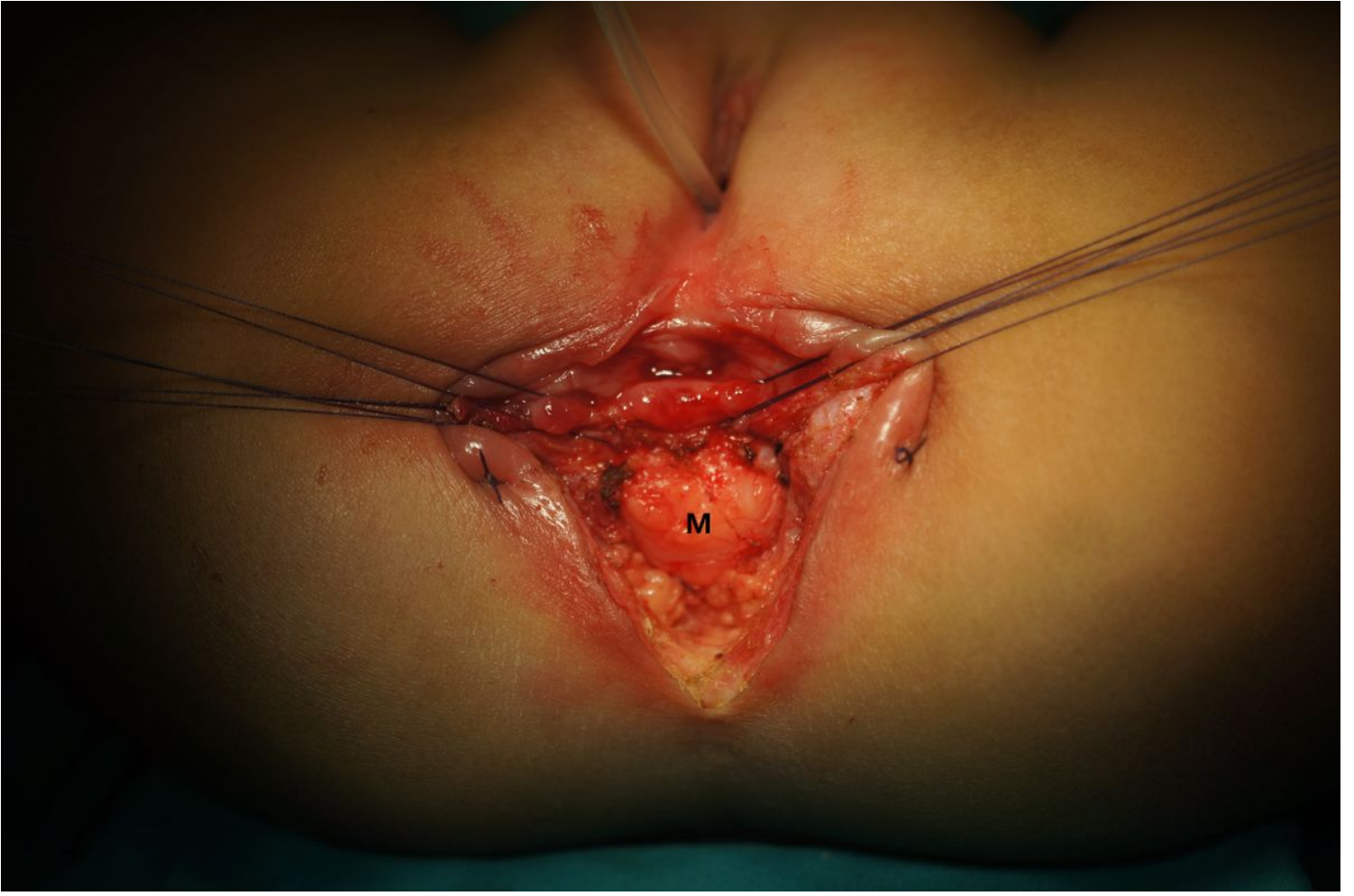


Figure 1

surgical treatment through a limited sagittal route M presacral mass