

The functional limits of the aneurysmal aortic root. A unique pressure testing apparatus.

Timothy Luke Surman (✉ timothy.surman@gmail.com)

Royal Adelaide Hospital <https://orcid.org/0000-0001-5460-8431>

John Matthew Abrahams

Royal Adelaide Hospital

Dermot O'Rourke

Flinders University

Karen Reynolds

Flinders University

James Edwards

Royal Adelaide Hospital

Michael George Worthington

Royal Adelaide Hospital

John Beltrame

The Queen Elizabeth Hospital

Research article

Keywords: Ascending aorta aneurysms, Ascending aortic dissection, aortic root, thoracic aorta, inflation testing

Posted Date: April 22nd, 2020

DOI: <https://doi.org/10.21203/rs.3.rs-23318/v1>

License:   This work is licensed under a Creative Commons Attribution 4.0 International License.

[Read Full License](#)

Version of Record: A version of this preprint was published on September 17th, 2020. See the published version at <https://doi.org/10.1186/s13019-020-01288-8>.

Abstract

Background The aortic root has unique embryological development and is a highly sophisticated and complex structure. In studies that report on the biomechanical characteristics of the thoracic aorta, distinction between the aortic root and ascending aorta regions is nonexistent. Our objective is to determine the maximal pressures at which dissection occurs or tissue failure occurs in the aortic root compared to that of the ascending aorta in the presence of aortic aneurysms. This may help guide preoperative monitoring, diagnosis and the decision for operative intervention for aortic root aneurysms in the normal and susceptible populations.

Methods We developed a simple aortic root and ascending aorta pressure testing unit in series. Ten fresh porcine hearts were obtained from the local abattoir (n=5 aortic root and n=5 ascending aorta for comparison). Using a saline filled needle and syringe, artificial fluid-filled aneurysms were created between the intima and medial layers of the aortic root. The aorta lumen was then progressively filled with saline solution. Pressure measurement was taken at time of loss of tissue integrity, obvious tissue dissection or aneurysm rupture, and the tissue structure was then visually examined.

Results In the aortic root, mean maximal pressure (mmHg) at tissue failure was 208mmHg. Macroscopic examination revealed luminal tears around the coronary ostia in 2/5 specimens, and in all specimens, there was propagation of the dissection in the aortic root in a circumferential direction. In all ascending aorta specimens, the maximal aortic pressures exceeded 300mmHg without tissue failure or dissection, and eventual apparatus failure.

Conclusion Our results indicate that the aneurysmal aortic root tissues are at greater risk of rupture and dissection propagation at lower aortic pressure. With further analysis, this could guide clinical and surgical management.

Background

Ascending aortic dissection is the most common catastrophe of the aorta; it is two to three times more common than rupture of the abdominal aorta (Saliba, Sia et al. 2015). Mortality rate of untreated acute dissection involving the ascending aorta is about 1–2% per hour during the first 48 hours (Hebballi and Swanevelder 2009) The first documented case was King George II in 1760 (Hebballi and Swanevelder 2009). Constant exposure to high pulsatile pressure and shear stress leads to a weakening of the aortic wall in susceptible patients resulting in an intimal tear (Zeng, Shi et al. 2018) Most of these tears take place in the ascending aorta, usually in the right lateral wall where the greatest shear force on the aorta occurs (Levy et al. 2018).

Aneurysms of the aortic root arise relatively deep within the heart and because of frequently associated complications, such as aortic insufficiency, present a more complicated problem than the more distal aneurysms of the ascending aorta (Najafi et al. 1966). The aortic root has unique embryological development and is a highly sophisticated and complex structure. Its optimal structure ensures dynamic

behavior in flow characteristics, coronary perfusion and left ventricular function. In studies that report on the biomechanical characteristics of the thoracic aorta, distinction between the aortic root and ascending aorta regions is nonexistent. Aortic root replacement is associated with high mortality and morbidity and is therefore frequently avoided in cases of acute aortic dissection for fear of increased surgical risk. Approximation of the aortic wall layers within the dissected sinuses of Valsalva with a biological glue and subsequent supracoronary aortic replacement offers a simple and efficient method of preserving the native valve and abolishing the aortic insufficiency when it is caused by the distortion of root anatomy. However, non-curative root repair can result in late development of several pathologies, which, especially after use of glue, necessitate challenging redo surgeries (Urbanski et al. 2016).

The initial decision regarding the management of the aortic root in type A aortic dissection (TAAD) is whether to repair or replace the dissected sinus segments (Leshnower et al. 2016). The standard indications for aortic root replacement (ARR) in the setting TAAD are extensive tissue destruction, the presence of a concomitant aortic root aneurysm ≥ 4.5 cm, or a known connective tissue disorder. The most common pathology observed is a primary intimal tear located in the ascending aorta with extension of the dissection flap into the noncoronary cusp, and relative preservation of the left and right coronary sinuses. Rarely are the aortic valve cusps or annulus impacted by the dissection process (Leshnower et al. 2016).

A meta-analysis of aortic valve-preserving surgery in acute type A aortic dissection containing 2402 patients from 19 observational studies revealed that, in 95% of the patients, the surgery consisted of conservative root management and supracoronary aortic replacement, while only 5% underwent a curative root repair by valve-sparing root replacement (VSRR) (reimplantation or remodeling). In a large aortic dissection repair centre, 10% of the patients with aortic root dissection, a non-curative root repair using tissue glue was performed at the surgeon's discretion (Urbanski et al. 2016).

Coady et al studied 370 patients with thoracic aneurysms (201 ascending aortic aneurysms), during a mean follow-up of 29.4 months, the incidence of acute dissection or rupture was 8.8% for aneurysms less than 4 cm, 9.5% for aneurysms of 4 to 4.9 cm, 17.8% for 5 to 5.9 cm, and 27.9% for those greater than 6 cm. In this study, the median size of the ascending aortic aneurysm at the time of dissection or rupture was 59 mm. The growth rate ranged from 0.08 cm/yr. for small (4 cm) aneurysms to 0.16 cm/yr. for large (8 cm) aneurysms (David 2010).

The risk of aortic dissection and rupture is often related to the transverse diameter of the aortic sinuses. It is rare with diameters less than 50 mm except in cases of family history of dissection or inpatients with Loya-Dietz syndrome. Surgery is usually recommended when the diameter of the aortic root reaches 50 mm. Patients with family history of aortic dissection or the diagnosis of Loya-Dietz syndrome should be operated on when the transverse diameter exceeds 40 mm (David 2010).

Our objective is to determine the maximal pressures at which dissection occurs or tissue failure occurs in the aortic root compared to that of the ascending aorta in the presence of aortic aneurysms. This may

help guide preoperative monitoring, diagnosis and the decision for operative intervention for aortic root aneurysms in the normal and susceptible populations.

Methods

We developed a simple aortic root and ascending aorta pressure testing unit in series (Fig. 1). This apparatus consisted of an aortic root and ascending aorta porcine specimen, a pressure transducer measuring in mmHg (National instruments Pty Ltd, Austin, TX), two large vessel clamps, and a 50 ml syringe filled with saline solution with a 21-gauge needle.

Porcine hearts ($n = 5$) were obtained fresh from local abattoirs which included the heart and ascending aorta attached to the brachiocephalic trunk on the right side. In addition, porcine hearts ($n = 5$) were obtained for testing on the ascending aorta alone (excluding the aortic root). Animal ethics approval was not required according to local South Australian Health and Medical Research Institute (SAHMRI) and Preclinical, Imaging, and Research Laboratories (PIRL) protocols.

The aorta was dissected proximally to the left ventricle to include the entire aortic root. The dissection then extended distally to the distal ascending aorta. The proximal limits were the left ventricle and distal limits was the brachiocephalic trunk.

Large vessel clamps were applied to the proximal and distal limits of the aorta (Figs. 2 and 3). The most distal region was limited by the branches of the aortic arch. The most proximal region limited by the left ventricle. Using a size 11 scalpel blade, a small incision was made in the proximal ascending aorta distal to the aortic root, and the pressure transducer inserted within the ascending aorta lumen. A purse string suture was placed circumferentially around the incision to prevent dislodgement of the transducer during pressurization. The pressure transducer was connected to a laptop computer and pressure measurements taken in real time using LabVIEW (National Instruments Pty Ltd, Austin TX). Saline solution was aspirated into a 50 ml syringe and 21-gauge needle applied. The needle was then inserted between the intimal and medial layers at the level of the coronary ostia to create an aneurysm in the aortic root testing and in the region of the proximal aorta during the ascending aorta testing. Saline solution was administered until a visible aneurysm was created identifying disruption to the tissue layers. Using this same syringe and needle, saline solution was administered into the lumen of the ascending aorta between to distal and proximal clamps until the lumen was filled and pressurized. Concurrent pressure measurements (mmHg) were taken and recorded during filling (Fig. 4). Pressure measurements was taken at time of loss of tissue integrity, obvious tissue dissection or aneurysm rupture. The pressure measurement was determined to be the maximal pressure at time of loss of aortic root tissue integrity. The aortic root and ascending aorta was then opened, and the tissue microstructure was examined visually.

A limitation of this method of creating an aneurysm does not completely mirror the normal, chronic changes of aortic aneurysm formation including the thinning of the tissues, weakening of the connective

tissues, and local stress points related to atherosclerosis (penetrating aortic ulcers) which could contribute to the development of aortic dissection.

Results

Pressure measurements were conducted on 5 porcine aortic root specimens, and maximal pressure determined at the time of loss of tissue integrity. The mean maximal pressure (mmHg) at tissue failure was 208 mmHg (see Table 1). Macroscopic examination revealed luminal tears around the coronary ostia in 2/5 specimens (Figs. 6 and 7), and in all specimens, there was propagation of the dissection in the aortic root in a circumferential direction.

Pressure measurements were conducted on 5 porcine ascending aorta specimens (excluding the aortic root), and maximal pressures recorded at the time of loss of tissue integrity or apparatus failure (Fig. 5). In all specimens, the maximal aortic pressures exceeded 300 mmHg without tissue failure or dissection, and eventual apparatus failure (see Table 1). Macroscopic examination revealed no luminal tissue dissection or tearing. There was no evidence of aneurysms dissection (Fig. 8).

Table 1
Porcine pressure measurements of the aortic root and ascending aorta

Porcine specimen aortic root	Maximal pressure (mmHg)	Macroscopic characteristics	Porcine specimen ascending aorta only	Maximal pressure (mmHg)	Macroscopic characteristics
1	180	<ul style="list-style-type: none"> • Tissue dissection at site of pressure transducer • Circumferential spread of dissection 	1	300+	<ul style="list-style-type: none"> • No loss of tissue integrity • Apparatus failure
2	200	<ul style="list-style-type: none"> • Tissue dissection at site of pressure transducer • Luminal tear at coronary ostia • Circumferential spread of dissection 	2	300+	<ul style="list-style-type: none"> • No loss of tissue integrity • Apparatus failure
3	220	<ul style="list-style-type: none"> • Tissue dissection at site of pressure transducer • Luminal tear at coronary ostia • Circumferential spread of dissection 	3	300+	<ul style="list-style-type: none"> • No loss of tissue integrity • Apparatus failure
4	200	<ul style="list-style-type: none"> • Tissue dissection at site of pressure transducer • Circumferential spread of dissection 	4	300+	<ul style="list-style-type: none"> • No loss of tissue integrity • Apparatus failure
5	240	<ul style="list-style-type: none"> • Tissue dissection at site of pressure transducer • Circumferential spread of dissection 	5	300+	<ul style="list-style-type: none"> • No loss of tissue integrity • Apparatus failure

Discussion

The aortic root is a unique embryological, anatomical and physiological structure that should be distinguished from the ascending aorta in its diagnosis and surgical management of aortic root aneurysms. Diagnosis and subsequent management are determined by aneurysm size, progression of size and predisposing factors such as valvular pathology and genetic conditions such as Marfans syndrome and Loeys-Dietz syndrome. There are no reported studies comparing the macroscopic integrity

of the aortic root in times of aneurysm pathology and its propensity to rupture at certain aortic pressures. All studies to date have looked at the aortic root and ascending aorta in section and not as a complete structure reducing its accuracy when compared to physiological conditions.

It has been reported that many dissection patients do not seem to have markedly dilated aortas at the time of presentation (Pape, Tsai et al. 2007). On review of the International Registry of Aortic Dissections (IRAD) data, of 591 patients reviewed, almost 60% had diameters < 5.5 cm and 40% had aortic diameters < 5 cm. Suggestions have been made for utilization of genetic markers, biomarkers and functional studies to better predict susceptible patients to aortic dissection. If the aortic root represents a unique structure with a predisposition to rupture than the ascending aorta, then do we need even more aggressive monitoring, management and consideration for intervention in aneurysmal proximal ascending aorta and aortic root pathology?

We have looked at 10 porcine specimens comparing the aortic root and ascending aorta aneurysm rupture maximal pressures and rupture pattern. Our results indicate that the aneurysmal aortic root tissues are at greater risk of rupture and dissection propagation at lower aortic pressure. Further testing of greater tissue numbers is needed to confirm these findings, but consideration should be for much closer monitoring of aortic root aneurysms, strict blood pressure control of patients with known aortic root aneurysms and earlier intervention of aortic root aneurysms.

Conclusion

The aortic root is a unique embryological, anatomical, and physiological structure that is shown to have specific development and progression of aneurysms, and as a result surgical management is different to that of the ascending aorta. No studies to date have tested the limitations of the weakened aortic root tissue. Knowledge in the pressure and structural limitations of the aneurysmal aortic root could guide clinical management of patients with known aneurysms, monitoring of progression and growth of aneurysms and ultimately surgical repair and replacement.

Declarations

Ethics approval and consent to participate – porcine tissue obtained from abattoir. No human specimens or live animal specimens used in analysis.

Consent for publication – All co-authors consented for publication. No patient involvement in study requiring consent.

Availability of data and materials – All data incorporated into manuscript.

Competing interests – Nil competing interests from listed authors.

Funding – No specific funding provided for this study.

Authors' contributions – Equal contribution from TL Surman, JM Abrahams and D O'Rourke in the laboratory testing and ,manuscript preparation. Equal contribution from JE Edwards, MG Worthington and K Reynolds in manuscript review and guidance on final submission.

Acknowledgements – Acknowledge all the co-authors involved in the study

References

Saliba E, Sia Y (2015). The ascending aortic aneurysm: When to intervene. *International Journal Cardiology Heart Vascular*; 6: 91-100.

Heabballi R, Swanevelder J (2009). Diagnosis and Management of aortic dissection. *Continuing Education in Anaesthesia Critical Care and Pain*; 9: 14-18.

David T (2010). Surgical treatment of ascending aorta and aortic root aneurysms. *Progress in Cardiovascular Diseases*; 52: 438-444.

Najafi H (1966). Aortic root aneurysm: Diagnosis and Treatment. *Journal of American Medical Association*; 197: 133-134.

Pape, L, Tsai, T, Isselbacher, E, Oh, J, O'Gara, P, Evangelista, A, Fattori, R, Meinhardt, G, Trimarchi, S, Bossone, E, Suzuki, T, Cooper, J, Froehlich, J, Nienaber, C, Eagle, K (2015). Aortic diameter ≥ 5.5 cm is not a good predictor of type A aortic dissection: Observations from the International Registry of Acute Aortic Dissection (IRAD). *Circulation Journal*; 116: 1120-1127.

Romo A, Badel P, Duprey A, Favre JP, Avril S (2014). In vitro analysis of localized aneurysm rupture. *Journal of Biomechanics*; 47: 607-616.

Takagi H, Mitta S, Ando T (2018). Long-term survival after transcatheter versus surgical aortic valve replacement for aortic stenosis: A meta-analysis of observational comparative studies with a propensity-score analysis. *Catheterization and Cardiovascular Interventions*; 2: 419-430.

Zeng T, Shi L., Ji Q, Shi Y, Huang Y., Liu Y, Gan J, Yuan, J, Lu, Z, Xue, Y, Hu, H, Liu, L, Lin Y (2018). Cytokines in aortic dissection. *Clinica Chimica Acta*; 486: 177-182.

Leshnower B, Chen E (2016). When and how to replace the aortic root in type A aortic dissection. *Annals of Cardiothoracic Surgery*; 5: 377-382

Urbanski P, Lenos A, Irimie V, Bougioukakis P, Zacher M, Diegeler A (2016). Acute aortic dissection involving the root: operative and long-term outcome after curative proximal repair. *Interactive*

Cardiovascular Thoracic Surgery; 22: 620-626.

Coady M, Davies R, Roberts M (1999). Familial patterns of thoracic aortic aneurysms. Archives of Surgery; 134: 361-367.

Matalanis G (2004). Valve sparing aortic root repairs – an anatomical approach. Heart Lung and Circulation; 13S: S13-S18

Charitos E, Sievers H (2013). Anatomy of the aortic root: implications for valve sparing surgery. Annals of Cardiothoracic surgery; 2(1): 53-56

Reiter C, Grund M, Nahler A, Steinwender C, Lambert T (2017). Rupture of the aortic root: A rare but life-threatening complication of transcatheter aortic valve replacement. Wein Klin Wochenschr; 129: 906-909.

Nataf P, Lansac E (2006). Dilation of the thoracic aorta: medical and surgical management; 92(9): 1345-1352.

Avanzini A, Battini D, Bagozzi L, Bisleri G (2014). Biomechanical evaluation of ascending aortic aneurysms. Biomedical Research International; 2014: 820385

Martin C, Sun W, Pham T, Elefteriades J (2013). Predictive biomechanical analysis of ascending aortic aneurysm rupture potential. Acta Biomaterials; 9: 10.1016.

Witzenburg C, Dhume R, Shah S, Korenczuk C, Wagner H, Alford P, Barocas V (2017). Failure of the porcine ascending aorta: multidirectional experiments and a unifying microstructural model

Adham M, Gournier J, Favre J, De L Roche E, Ducerf C, Baulieux J, Barral X, Pouyet M (1996). Mechanical characteristics of fresh and frozen human descending aorta. Journal of Surgical Research; 64: 32-34.

Choudhury N, Bouchot O, Rouleau L, Tremblay D, Cartier J, Butany J, Mongrain R, Leask R (2008). Local mechanical and structural properties of healthy and diseased human ascending aorta tissue. Cardiovascular pathology; 18: 83-91.

Marra S, Kennedy F, Kinkaid J, Fillinger M (2006). Elastic and rupture properties of porcine aortic tissue measured using inflation testing. Cardiovascular engineering; 6: 123-131.

Peterson L, Jenesen R, Parnell J (1960). Mechanical properties of arteries in vivo. Circulation Research; 8: 622-639.

Sommer G, Gasser T, Regitnig P, Auer M, Holzapfel G (2008). Dissection properties of the human aortic media: an experimental study. Journal of Biomechanical Engineering; 130: 1-12.

Vorp D, Schiro B, Ehrlich M, Juvonen T, Ergin M, Griffith B (2003). Effect of aneurysm on the tensile strength and biomechanical behavior of the ascending thoracic aorta. Annals of thoracic surgery; 75: 1210-1214.

Figures

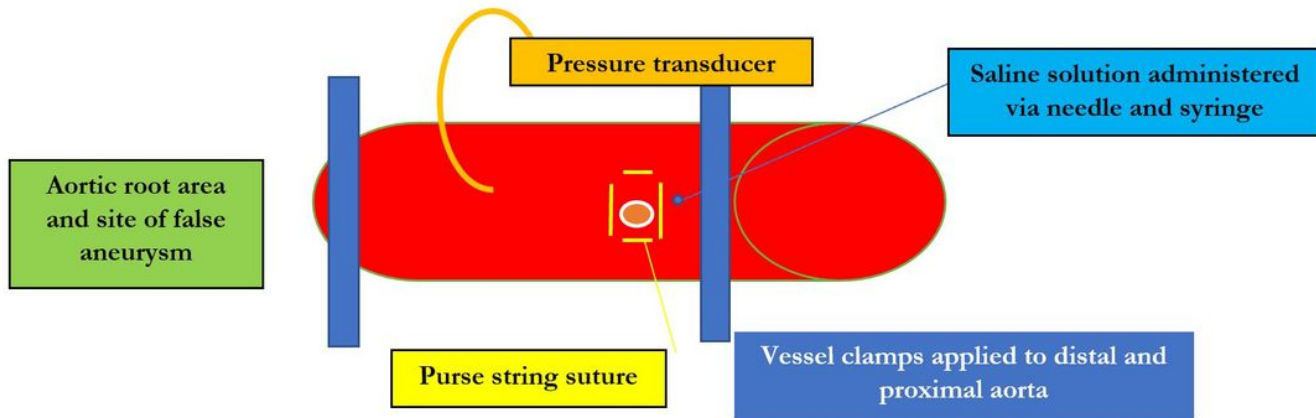


Figure 1

Ascending aorta pressure measurement apparatus diagram

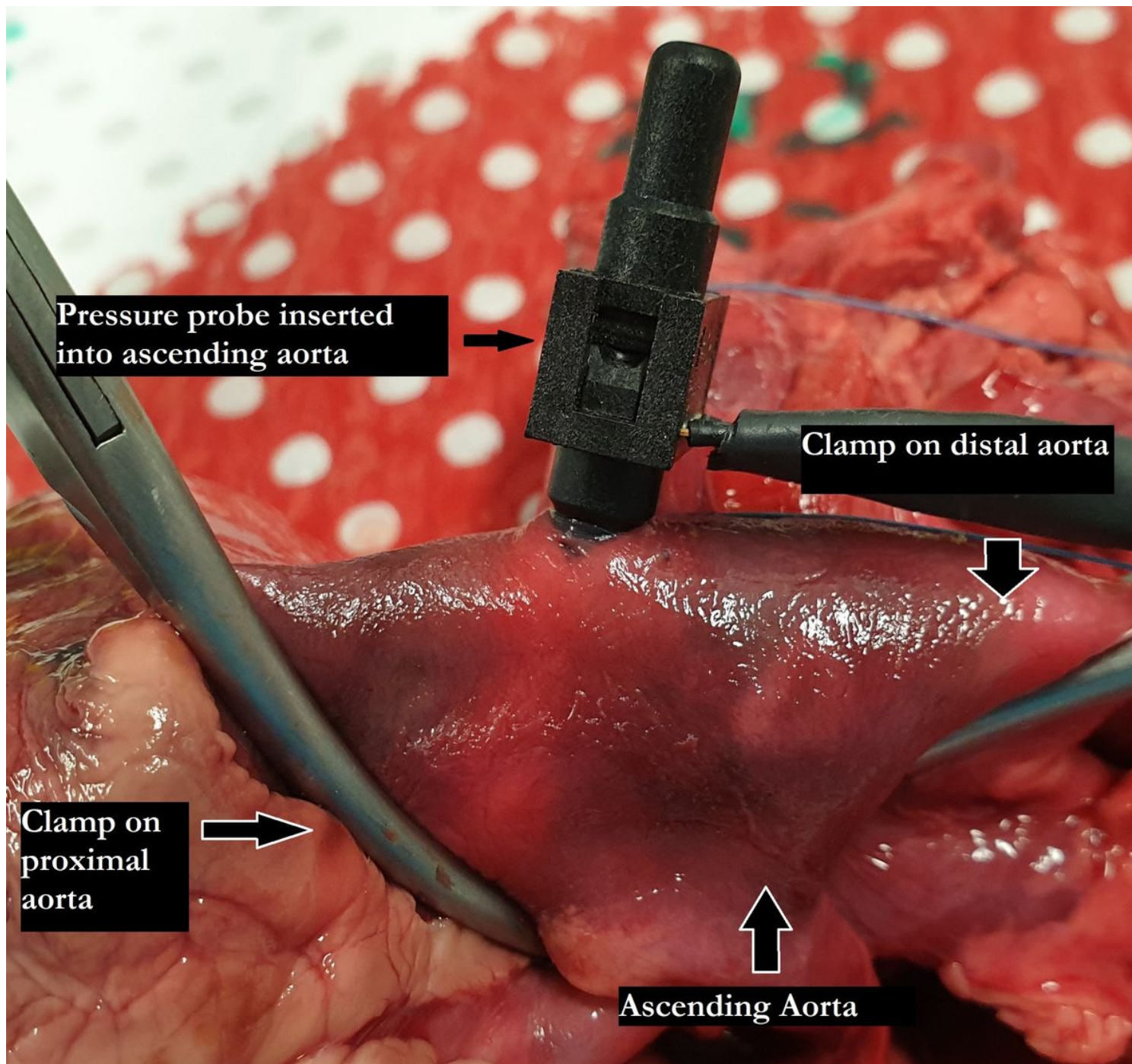


Figure 2

Aortic apparatus in full with labels

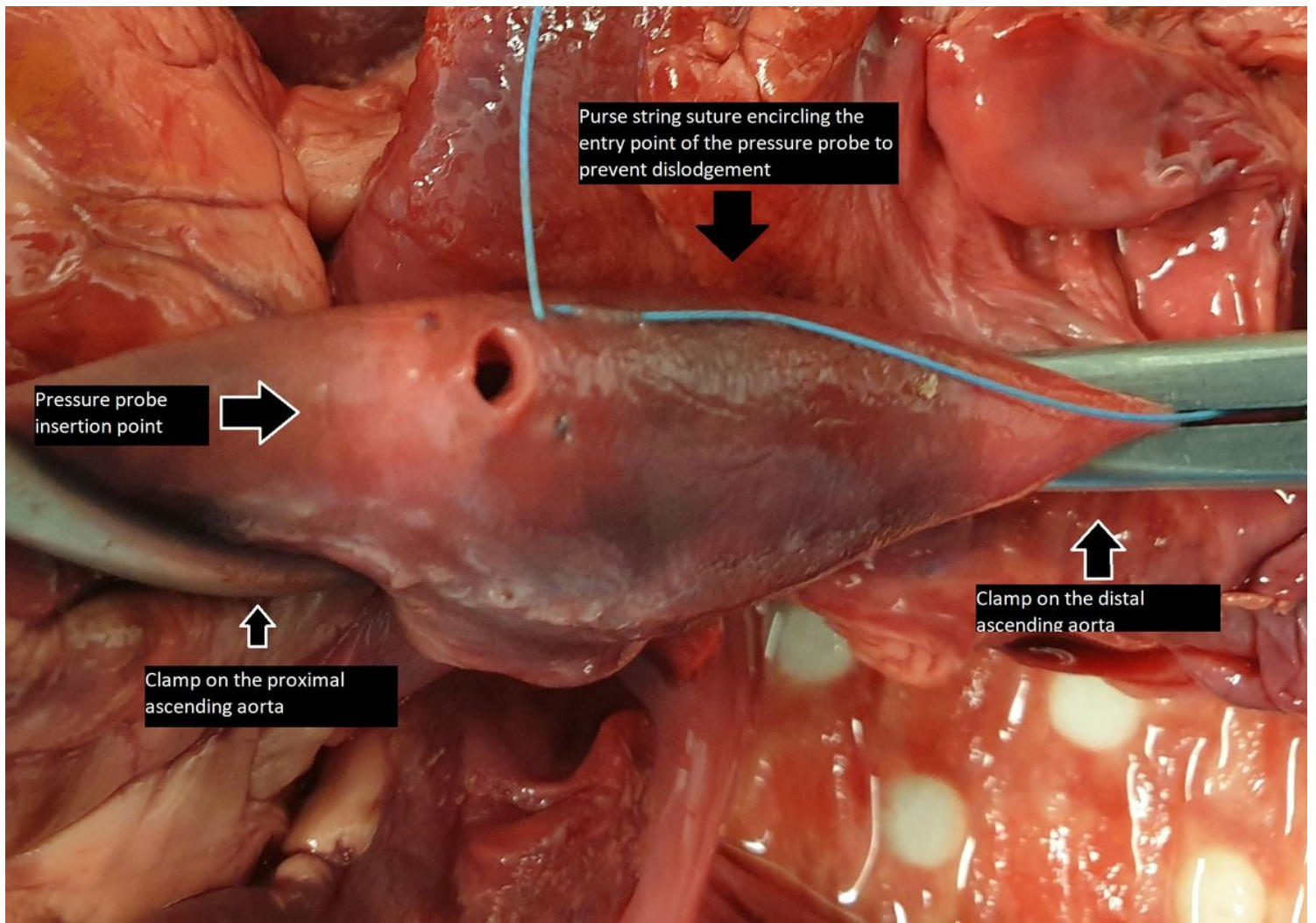


Figure 3

Aortic apparatus purse string suture with labels

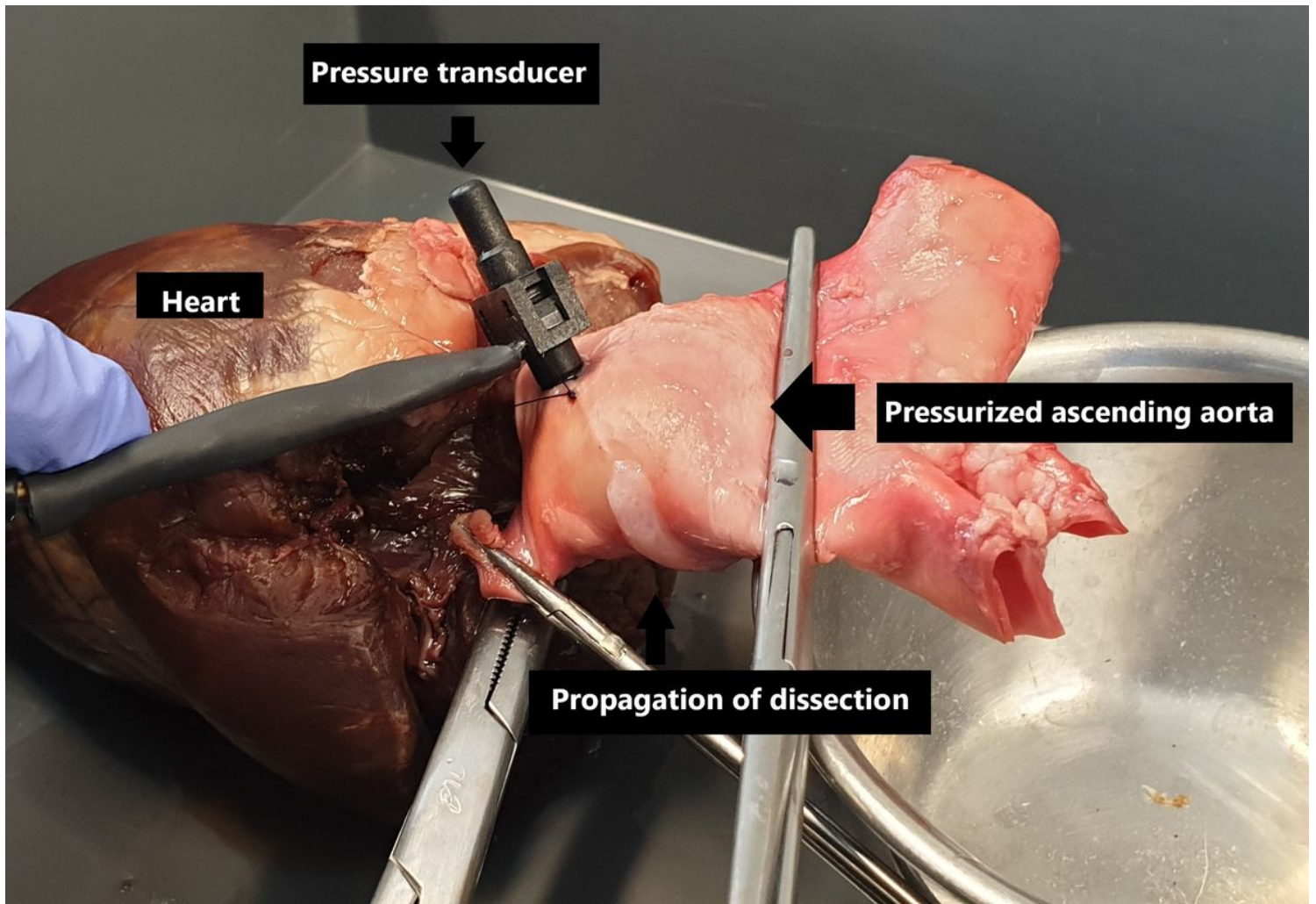


Figure 4

Pressurized Aortic aneurysm model during testing

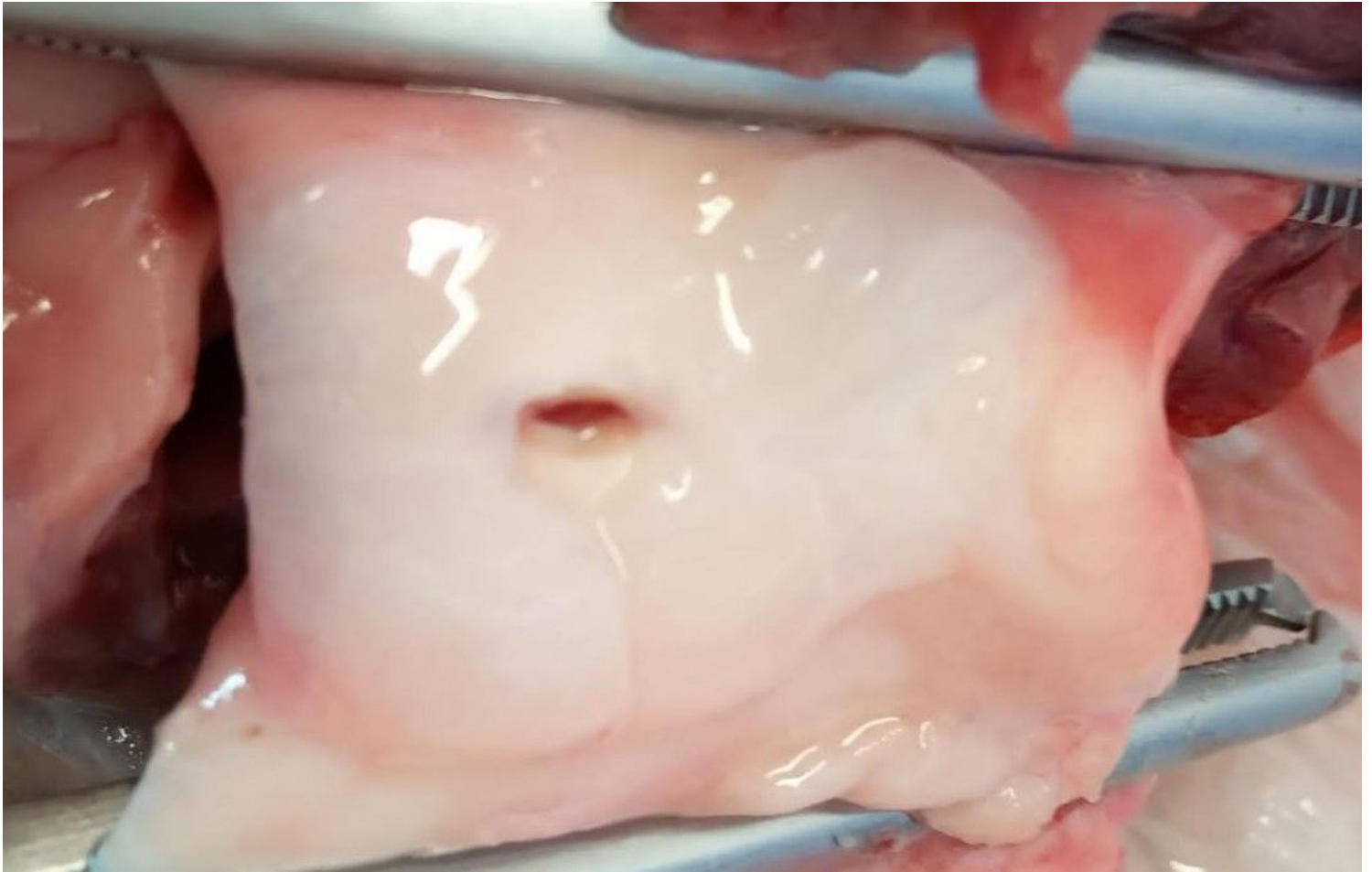


Figure 5

Circumferential propagation of the dissection in the aortic root

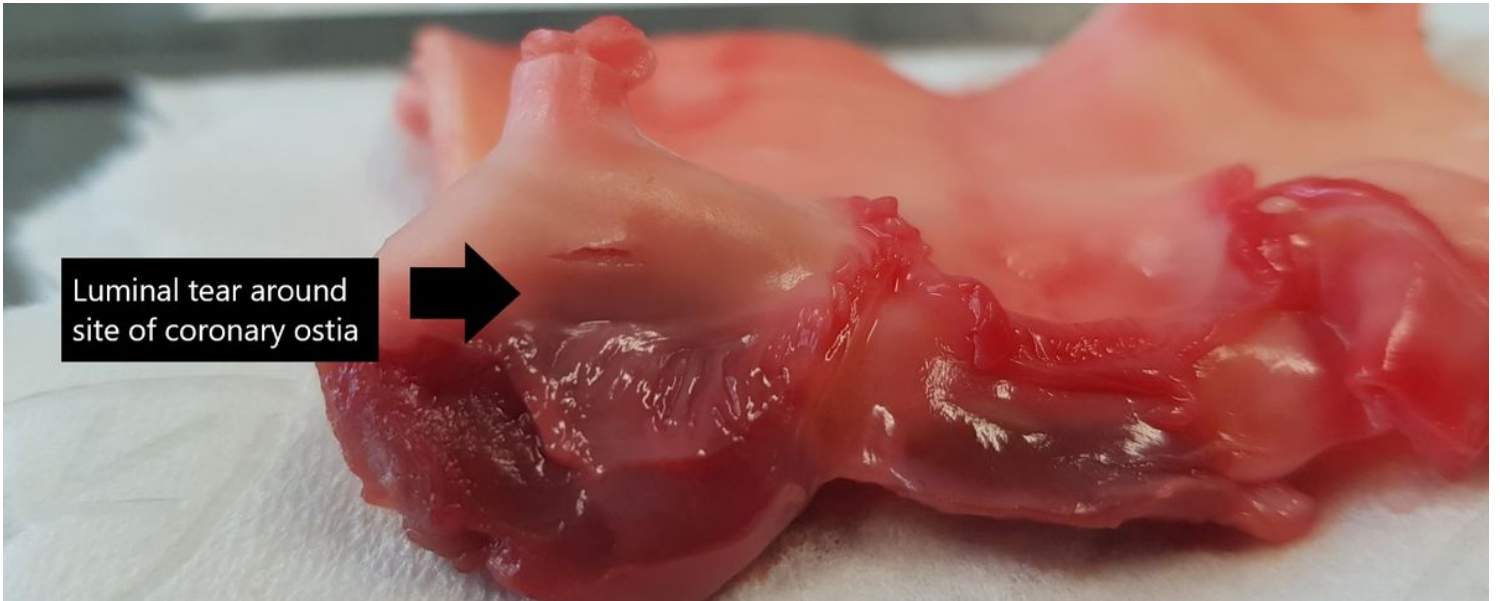


Figure 6

Macroscopic examination revealing tearing around the coronary ostia (arrows)

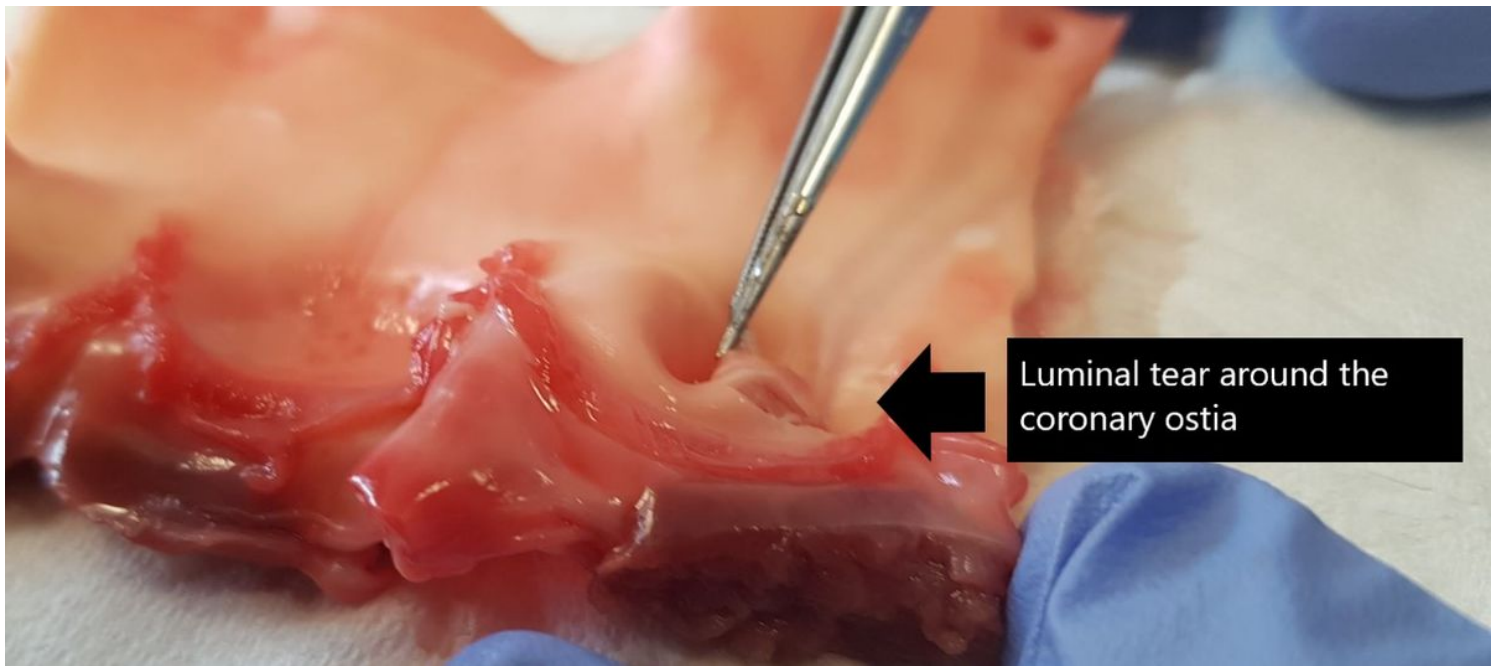


Figure 7

Macroscopic examination revealing tearing around the coronary ostia (arrows)

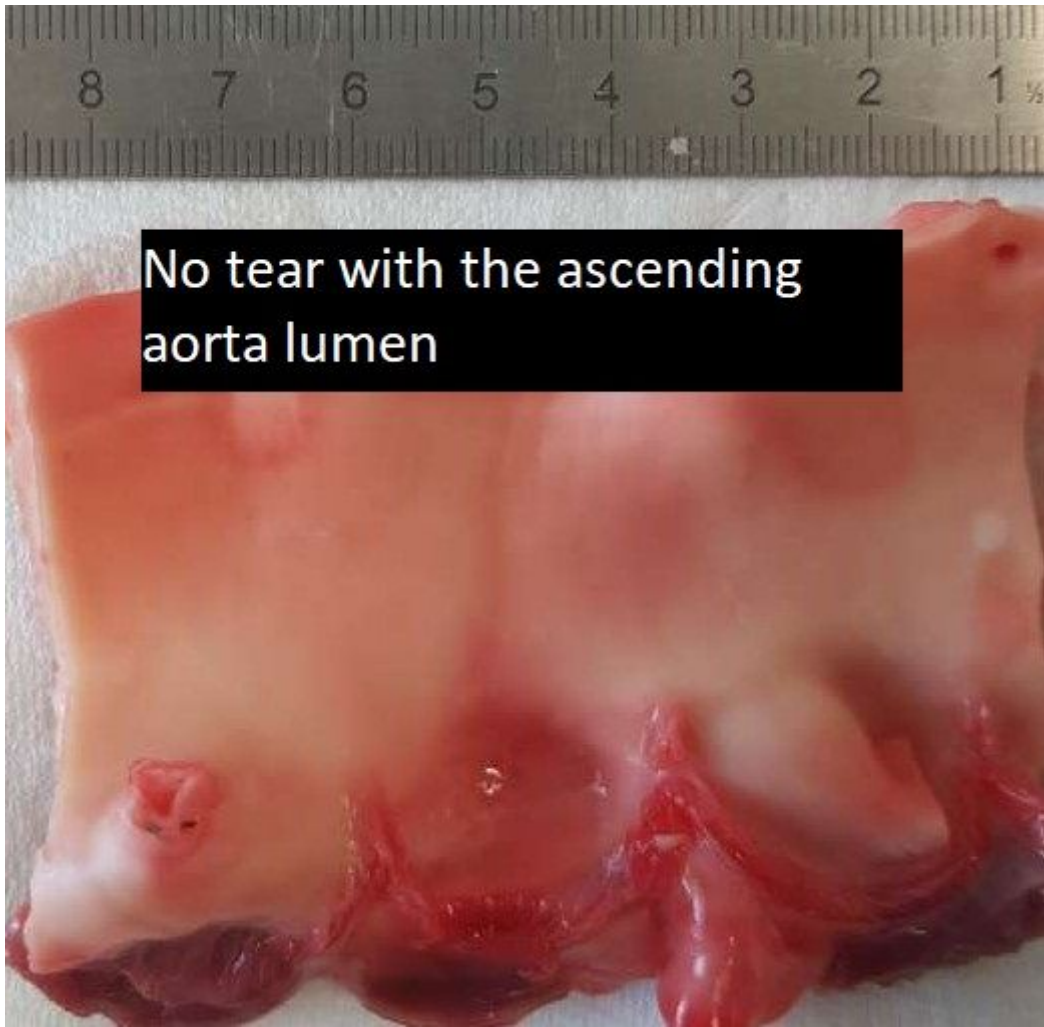

Figure 8

Intact luminal architecture of the aortic root in 3/5 specimens

Supplementary Files

This is a list of supplementary files associated with this preprint. Click to download.

- [Aorticrootresultstable.JPG](#)
- [Aorticrootresultstable.JPG](#)