

Analysis of compliance and efficacy of integrated management of whole process in the choice of percutaneous full-endoscopic surgery for patients with cervical disc herniation

Zhongyan Jiang

The affiliated hospital of zunyi medical university

Ansu Wang

The affiliated hospital of zunyi medical university

Chong Wang

The affiliated hospital of zunyi medical university

Weijun Kong (✉ kong0526@sina.com)

The second affiliated hospital of zunyi medical university

Research article

Keywords: cervical disc herniation, integrated management mode , whole course , percutaneous endoscopy, discectomy, compliance

Posted Date: April 21st, 2020

DOI: <https://doi.org/10.21203/rs.3.rs-22183/v1>

License: © ⓘ This work is licensed under a Creative Commons Attribution 4.0 International License.

[Read Full License](#)

Abstract

Background : Percutaneous spinal endoscopy technique is a new type of surgery for the treatment of cervical disc herniation. It can avoid the complications of classic ACDF approach and the risk of adjacent spondylosis. How to effectively improve patients' awareness of spinal endoscopy and choose to receive endoscopic techniques? **Objective:** To analyze the compliance and clinical effect of the integrated management of whole process in the choice of percutaneous full-endoscopic surgery for patients with cervical disc herniation.

Methods: Retrospective analysis of 72 patients with cervical disc herniation undergoing surgery in our hospital in August 2015~ August 2017, all of them carried out the whole process integrated management mode, 36 patients in the experimental group were treated by percutaneous full-endoscopic cervical discectomy, and 36 patients in the control group were treated by anterior cervical discectomy and fusion(ACDF). The postoperative feeding time, time to get out of bed, length of hospital stay, compliance, clinical efficacy, and recurrence rate of neck pain were observed. And changes in pain visual analogue score (VAS) and neurological function JOA score of preoperative and postoperative.

Results: The postoperative feeding time in the experimental group was 8.319 ± 1.374 hours, the postoperative bedtime was 16.64 ± 3.728 hours, and the hospitalization time was 6.403 ± 0.735 days; The clinical excellent and good rate was 91.67%, the compliance rate was 88.89%, and the neck pain recurrence rate was 5.56%. The postoperative feeding time in the control group was 26.56 ± 9.512 hours, the postoperative bedtime was 45.06 ± 9.027 hours, and the length of hospital stay was 8.208 ± 0.865 days; The excellent and good rate was 88.89%, the compliance rate was 69.4%, and the neck pain recurrence rate was 8.33%. There was no significant difference between the two groups in the excellent treatment rate and the recurrence rate of neck pain, $p > 0.05$; The compliance rate of the experimental group was better than the control group, and the difference was statistically significant, $p < 0.05$; the hospitalization time of the experimental group was significantly lower than that of the control group, the difference was statistically significant, $p < 0.05$. The postoperative VAS scores and JOA scores of the two groups were significantly improved compared with preoperative, the difference was statistically significant, $p < 0.05$; and there was no significant difference between the two groups, $p > 0.05$.

Conclusion : The integrated management mode of the whole course can effectively improve the compliance of patients with cervical disc herniation receiving endoscopic treatment, obtain the same treatment effect as the classic operation, shorten the hospitalization time, speed up the turnover of hospital beds, improve the satisfaction of medical quality, and be worthy of clinical application.

Background

Cervical disc herniation (CDH) is a group of diseases based on cervical disc degeneration. The spinal cord and nerve roots are compressed by the protruding intervertebral disc due to a slight external force or no definite inducement, which causes neck and shoulder pain with upper limb radiation pain as the main

clinical symptoms^[1]. Symptoms can be relieved in most patients after conservative treatment, but some patients still need surgical treatment to relieve symptoms. The unhealthy postoperative living or work habits of some patients result in the recurrence of symptoms and place a substantial economic burden on the patient^[2]. Therefore, maintenance of postoperative efficacy and prevention of the recurrence of symptoms are the focus of clinical treatment and follow-up^[3]. Anterior cervical discectomy and fusion (ACDF) is the standard surgical procedure for the treatment of CDH, but may cause postoperative complications such as swallowing discomfort, foreign body sensation in the pharynx, and degeneration of adjacent cervical segments^[4]. To reduce the incidence of surgical trauma and related iatrogenic complications, minimally invasive percutaneous endoscopic techniques have gradually evolved in spinal surgery. Spinal full-endoscopic techniques appear to be more advanced than ACDF due to their clear visualization, minimal trauma, accurate resection of the herniated lesions, and cosmetic appearance of the incisions^[5-7]. According to the different position of the herniated disc, we utilized either an percutaneous anterior or posterior approach for the full-endoscopic resection of herniated intervertebral discs. The posterior percutaneous endoscopic technique can only be used for posterolateral or foraminal disc herniation based on spinal anatomy^[8, 9]. In terms of the surgical approach for central or paracentral cervical disc herniation, we performed an anterior percutaneous transcorporeal full-endoscopic nucleus pulpotomy of the cervical disc to maximally preserve the function of the cervical spine^[10, 11]. In order to investigate the effect of the integrated management of whole course model on the compliance and curative effect of CDH patients undergoing full-endoscopic treatment, this study retrospectively collected 72 CDH patients undergoing surgical treatment in our hospital and analyzed their efficacy, compliance and recurrence rate of neck pain.

1. Information And Methods

1.1 Inclusion criteria ☐ For patients with single-segment CDH, the symptoms and signs of the patients are consistent with MRI examination; ☐ The patient received systematic conservative treatment for more than 1 month, and the patient's symptoms did not improve significantly or repeatedly; ☐ Patients volunteered to participate in clinical research, informed choice of surgical plan, and willing to cooperate with clinical follow-up.

1.2 Exclusion criteria ☐ Previous history of cervical spine surgery; ☐ Cervical deformity; ☐ Severe osteoporosis; ☐ Complicated with cervical tumor, tuberculosis, infectious disease; ☐ Coagulation dysfunction; ☐ Patients with goiter and cervical lymph node hyperplasia; ☐ Patients with neuropsychiatric disorders ; ☐ Those with other diseases who cannot tolerate surgery.

1.3 General data: A total of 72 patients with cervical disc herniation who underwent surgery in our department from August 2015 to August 2017 were collected. Experimental group (36 cases): percutaneous full-endoscopic technique treatment; Control group (36 cases): ACDF treatment. General information of the two groups of patients is shown in Table 1, there was no statistically significant difference between the groups, $P \geq 0.05$.

Table 1
General patient data

	Number	Gender		Age (Y)	Course (M)	Educational level	
		Man	Woman			High school or above	Junior school and below
EG	36	23	13	59.89 ± 9.077	6.806 ± 3.8641	32	4
CG	36	21	15	61.14 ± 9.859	7.903 ± 4.332	28	8
t		Z=-0.512		0.5358	1.235	Z=-1.500	
p		0.608		0.5955	0.2250	0.134	
Note: EP:Experimental group; CG:Control group; Y:Years; M:Months.							

1.4 Methods

After the patient was admitted to the hospital, the resident physician completed medical history collection, physical examination, medical record writing, perfecting related laboratory and imaging and other auxiliary examinations, and the nurse completed the relevant nursing evaluation and informed notification of hospitalization. The establishment of a integrated management team of whole course: under the guidance of the head of the department, Carry out a joint ward round of the attending doctor and responsible nurse, and a integrated follow-up system after discharge from the hospital^[12,13]. The executive team implements CDH fixed bed management, and provides basic knowledge about the disease according to the patient's cognition: onset factors, treatment methods, surgical methods, treatment procedures, daily habits, prevention and health care methods^[14,15].The focus is to make patients aware that spinal minimally invasive technology is the inevitable development direction of contemporary surgical technology. It is an inevitable product of the new developments in science and technology such as channel technology, optical technology, visual imaging technology, and surgical technology. Which is a new surgical method to maintain the physiological health of patients to the greatest extent. Make the patient realize that compared with the classic ACDF operation method, the percutaneous full-endoscopic technique has the advantages of less trauma, faster recovery, no internal plant fixation, less cost, and better retention of cervical biomechanical stability, which establishes a positive for the patient rehabilitation confidence^[16-18]. integratedly evaluate the risks of surgery and anesthesia before surgery, eliminate the contraindications for surgery, perform the three-level physician rounding system and pre-operative discussion system, fully communicate with patients and their families, explain the pros and cons of the two surgical options, and determine the surgical plan based on the patient's informed understanding and willingness. In the experimental group, patients were treated

with percutaneous full-endoscopic techniques. The surgical protocol included percutaneous anterior full-endoscopic transcorporeal discectomy and spinal cord decompression (Figure 1) or posterior percutaneous full-endoscopic discectomy and nerve root decompression (Figure 2). In the control group, perform cervical discectomy, spinal cord decompression, interbody fusion and internal fixation underwent (Figure 3). After the operation, the patient's symptom improvement, normal eating situation, time to get out of bed and hospitalization time were closely observed, and the patient was scientifically instructed to get out of bed with cervical collar. On the morning of discharge, the attending doctor and the responsible nurse explained the precautions for discharge to the patient, emphasizing that postoperative recovery of CDH is a long-term process, and it is necessary to develop good living and working habits, and develop a follow-up plan for discharge health education. Focus on patients with poor compliance and require their family members to actively monitor and cooperate^[13,15]. At 3, 6, 12, and 24 months after discharge, the patients were followed up by telephone or regularly reviewed in outpatient clinics to understand the patient's health status, compliance with functional exercise, and evaluation of the clinical effect of percutaneous full-endoscopic treatment of CDH.

1.5 Observation indicators

Observe the postoperative food intake time, postoperative bed walking time, and hospitalization time; patient compliance, clinical efficacy, and neck pain recurrence rate, and compare the visual analog score (VAS) of pain and Japan Orthopaedic Association Treatment Score (JOA) between the two groups preoperative and postoperative. Evaluation of efficacy: According to JOA score to evaluate the clinical treatment effect^[19]. The calculation formula of JOA improvement rate is: $\text{postoperative score} - \text{preoperative score} / (17 - \text{preoperative score}) \times 100\%$; JOA score improvement rate of more than 75% is excellent; 50% to 74% is good; 25% to 49% is acceptable ; Less than 25% is poor.

1.6 Statistical methods

Using SPSS22.0 statistical software, measurement data was expressed as mean \pm standard deviation ($\bar{x} \pm s$), and comparison between groups was performed by independent sample t test; count data was tested by χ^2 test, and $P < 0.05$ was considered statistically significant.

2. Results

2.1 The time of eating, moving out of bed ,hospitalization,compliance,clinical efficacy

All the patients successfully completed the operation,and their pain symptoms and nerve function were significantly improved after operation. The time of eating, moving out of bed and hospitalization in the experimental group were significantly lower than those in the control group ($P < 0.05$)(see table 2). There was no significant difference in the rate of excellent and good treatment and recurrence of neck pain between the two groups ($P > 0.05$), and the compliance rate of the experimental group was better than that of the control group ($P < 0.05$)(see Table 3).

Table 2

Comparison of the time of eating,moving out of bed and hospitalization ($x \pm s$, n=36)

	Eat time after operation (H)	Get out of bed after surgery (H)	Duration of stay (D)
EG	8.319 \pm 1.374	16.64 \pm 3.728	6.403 \pm 0.735
CG	26.56 \pm 9.512	45.06 \pm 9.027	8.208 \pm 0.865
t	11.02	17.34	10.59
P	< 0.0001	< 0.0001	< 0.0001
Note: EG, Experimental group; CG,Control group; H,hours; D,days.			

Table 3

Comparison of excellent rate,compliance rate and recurrence rate of neck pain ($x \pm s$, n=36)

	Excellent rate (%)	Compliance rate (%)	Recurrence rate of neck pain (%)
EG	91.67(33/36)	88.89(32/36)	5.56(2/36)
CG	88.89(32/36)	69.4(25/36)	8.33(3/36)
z	-0.397	-2.291	-1.025
P	0.691	0.022	0.306
Note: EG, Experimental group; CG,Control group.			

2.2 VAS and JOA Score

After operation, the symptoms of neck pain and upper limb radiation pain were significantly improved, and there was no significant difference between the two groups at each time node, $P > 0.05$ (see Table 4). The postoperative neurological symptoms were significantly improved and returned to normal, and there was no significant difference in JOA scores at each time node between the groups, $P > 0.05$ (see table 5). The improvement rates JOA of groups were excellent, greater than 75%. there was no significant difference between the groups, $P > 0.05$ (see table 5).

Table 4
Preoperative and postoperative VAS scores($\bar{x} \pm s$, n=36)

	Preoperative	1 week after operation	6 months after operation	24 months after surgery
EG	6.264 \pm 0.6812	1.319 \pm 0.5994 ^a	0.5694 \pm 0.4653 ^b	0.4861 \pm 0.4223 ^c
CG	6.306 \pm 0.7298	1.125 \pm 0.8051 ^a	0.6806 \pm 0.5231 ^b	0.6250 \pm 0.4532 ^c
t	0.2504	1.162	0.9523	1.345
p	0.8030	0.2491	0.3442	0.1829
Note: There was no significant difference between the groups, $P > 0.05$; "a" means compared with preoperative, $P < 0.05$; "b" means compared with 1week postoperatively, $P < 0.05$; "c" means compared with 6months postoperatively, $P > 0.05$. EG: Experimental group; CG:Control group.				

Table 5
Preoperative and postoperative JOA scores ($\bar{x} \pm s$, n=36)

	Pre-operative	1 week postoperative	6 months postoperative	24 months postoperative	JOA improvement rate(%)
EG	8.417 \pm 0.9599	15.36 \pm 1.217 ^a	16.24 \pm 0.7120 ^b	16.44 \pm 0.6412 ^c	93.54
CG	8.345 \pm 0.9321	15.24 \pm 1.137 ^a	16.33 \pm 0.7071 ^b	16.39 \pm 0.5492 ^c	92.82
t	0.3114	0.4504	0.5813	0.3948	0.4465
p	0.7564	0.6538	0.5629	0.6942	0.6566
Note: There was no significant difference between the groups, $P > 0.05$; "a" means compared with preoperative, $P < 0.05$; "b" means compared with 1week postoperatively, $P < 0.05$; "c" means compared with 6months postoperatively, $P > 0.05$. EG: Experimental group; CG:Control group.					

3. Discussion

In the era of rapid information development, people are dependent on computers and mobile phones for life, entertainment, and work. Currently, the onset of CDH is seriously increasing in the younger population. Changes in the morphological structure of the cervical spine are closely related to body posture in daily life and work. Head, neck, and shoulder activities directly affect the physiological function and morphological degeneration of each cervical segment^[20, 21]. Clinical studies have shown that the incidence of CDH is closely related to the internal and external imbalance of the cervical spine. Therefore,

the restoration of the dynamic and static balance of the cervical spine is the key to effective treatment and prevention of CDH^[22]. During hospitalization and after discharge, the guiding interventions regarding the patient's functional exercise of the cervical spine can help to achieve a significant clinical effectiveness^[21, 23]. After discharge, the patient's compliance decreased or disappeared, and the relief of early symptoms made the patient forget that good work or lifestyle was the basic to maintain the normal function of the cervical spine^[24]. Some patients slowly neglect good behavior habits and maintain cervical functional exercise, leading to the recurrence of disease symptoms or adjacent segment disc herniation. This study aimed at patients with cervical disc herniation, through the whole process of integrated management of follow-up evaluation guidance, achieved an ideal clinical management effect.

The conventional nursing management mode leads to the asymmetry of information between medical care, doctor-patient and nurse-patient, and there are a few contradictory and inconsistent aspects^[25]. Causes the patient to distrust the doctor and the nurse, even does not cooperate the treatment situation. The whole course integrated management mode is a new type of treatment and rehabilitation management mode which breaks the traditional nursing mode.^[12,15] This new model breaks down the previously conservative "subordination model" between medical care, doctor-patient care and nurse-patient care. Management teams are formed by doctors in charge and responsible nurses to participate in the whole process of patients' recovery and nursing during the perioperative period and after discharge^[13-15]. As a result, many hospitals have developed a new type of nursing mode, continuous treatment mode, family doctor management mode and participation mode using modern information platform (such as QQ group, WeChat group, etc.) to form a new situation of seamless docking and three-dimensional integration between doctors, nurses and patients^[26,27]. The classic procedure for CDH is cervical discectomy, bone graft fusion and internal fixation. However, the long-term clinical follow-up found that the associated complications of approach and the acceleration of degeneration of adjacent segments were the clinical concerned, and the related symptoms and signs of cervical spondylosis appeared again^[5-7]. The development of spinal full-endoscopy not only avoided the deficiency of open surgery, but also fully preserve the biomechanical stability of the spine^[28,29]. However, patients and non-specialists have little knowledge of modern spine full-endoscopic techniques, they are reluctant to undergo full-endoscopic treatment at an early stage. The patients of CDH who need surgical treatment, due to local disc herniation resulting in limited compression of the spinal cord, percutaneous full-endoscopic surgery not only achieved the purpose of percutaneous targeted removal of disc tissue and spinal decompression, but also reflected the cosmetic effect, reduce the associated open surgical approach complications, better maintain the biomechanical stability of the spine, avoided the acceleration of degeneration in adjacent segments^[30,31]. Through the integrated management model, doctors, nurses and patients have a consistent understanding on percutaneous spinal full-endoscopic procedure. Especially through the physician's explanation of the etiology, mechanism, operation, spinal cord nerve function recovery and cervical biomechanical stability. Then, the responsible nurses fully understand and cooperate with the doctor's orders, actively carry out health education and psychological care to the

patients, so that the patients from worry,fear to recognize,understand,and voluntary choiced, willing to accept percutaneous full-endoscopic treatment and building confidence.

The results showed that there was no significant difference between the two groups, $p > 0.05$, indicating that the newly developed percutaneous spinal full-endoscopy was effective and feasible. The compliance rate of the experimental group was better than that of the control group. The VAS, JOA scores of postoperative were significantly better than preoperative, $p < 0.05$. There was no statistically significant difference in JOA and VAS scores between the two groups, $p > 0.05$. integrated management model of the whole course enables CDH patients to receive percutaneous endoscopic treatment and obtained consistent effect with classical surgical procedure, avoided or significantly reduce the complications associated with the approach, improve the patient compliance rate, significantly reduce the length of hospital stay, while reducing the recurrence rate of symptoms^[32-34]. Through the integrated management of the whole course,we can promote the consistency of medical and health education,improve the compliance of CDH patients to actively cooperate with treatment,cultivate and maintain good living and working posture, and strengthened awareness of maintaining the health of the cervical spine.[3,14,24]. The establishment of this new health education model of medical cooperation strengthens the sense of responsibility,makes the personnel of each management group attach great importance to and actively participate,ensures the safety of medical treatment and nursing,avoids the occurrence of medical errors and accidents,and improves the satisfaction of clinicians and patients with nursing work[25,26]. It also promotes the development of new medical technology,effectively reduces the average length of hospital stay and speeds up the turnover rate of hospital beds. At the same time,it is beneficial to actively carry out the training and examination of medical staff,promote doctors and nurses to pay attention to the frontier knowledge of specialty,achieve common progress and enhance the construction of subject talents[25,32].

The whole process integrated management model, as a new type of clinical medical cooperation mode, has achieved good clinical results in a certain professional environment. It is restricted by the degree of cooperation and harmony between medical and nursing staff, the training and assessment of medical and nursing staff, the understanding of leadership and the degree of support^[32,34]. There is still a longer time to explore the wide application in clinic. At the same time,with the rehabilitation needs of different diseases,for some special patients,the whole process integrated management model can also be extended to cooperate with dietitians,rehabilitators,pharmacists and other multi-professional personnel to discuss and optimize the management plan for the rehabilitation of patients during hospitalization and after discharge^[33-35].

4 Conclusions

In summary, Through the implementation of a integrated management model for CDH patients, it has promoted the collaboration and cooperation between physicians, nurses, and patients, improved the compliance of patients with endoscopic treatment and rehabilitation exercises, and obtained the same therapeutic effect as classic surgery. This program is conducive to shortening the length of hospital stay,

speeding up the turnover of hospital beds, and improving the satisfaction of medical quality control, which is worthy of clinical application.

Abbreviations

ACDF: Anterior cervical discectomy and fusion; CDH: Cervical disc herniation; JOA: Japanese Orthopaedic Association scores; VAS: Visual analog scale

Declarations

Acknowledgements

Not applicable.

Authors' contributions

ZYJ was responsible for the design and writing of the manuscript. ASW was responsible for the collection of data and images. ASW and CW were responsible for the statistics and analysis of the data. WJK was responsible for the design and the revision of the article. All authors read and approved the manuscript.

Funding

This data collection was funded in part by Guizhou Provincial Science and Technology Department joint fund. Its contents are solely the responsibility of the authors and do not reflect the views of Guizhou provincial science and technology department nor the authors' institutions of affiliation.

Availability of data and materials

The data generated or analyzed during this study are included in this published article [and its supplementary information files].

Ethics approval and consent to participate

This study was approved by the local Ethics Committee of The Affiliated Hospital of Zunyi Medical University. Written consent was obtained from all participants.

Consent for publication

We have obtained written consent to publish from the participant to report individual patient data.

Competing interests

The authors declare that they have no competing interests.

References

1. Christine Hammera;Joshua Hellerb;Christopher Keplera. Epidemiology and pathophysiology of cervical disc herniation.Seminars. in Spine Surgery. 2016;28(2):64–7.
2. Samini F, Mashhadinejad H, Ehsaei M;et al. Comparison of Surgical and Medical Treatments for Cervical Spondylosis: A Prospective Study. Neurosurgery quarterly. 2014;24(1):18–21.
3. Zhou J, Yin Y;Li M. Perioperative nursing care of patients with cervical spondylotic myelopathy [Chinese]. Chinese Nursing Research.2009,23(5B):1272–1273.
4. June Ho Lee;Sang-Ho Lee. Clinical and Radiographic Changes After Percutaneous Endoscopic Cervical Discectomy: A Long-Term Follow-Up. Photomedicine and Laser Surgery.201432(12):663–668.
5. Jianwei Chen;Zude Liu;Guibin Zhong;et al.Surgical treatment for cervical spondylotic myelopathy in elderly patients: a retrospective study.Clinical Neurology and Neurosurgery.2015;132:47–51.
6. Göçmez Cüneyt;Koc, Tucer RK. Bulent;et al. Prognostic Factors in Cervical Spondylotic Myelopathy: A Clinical Prospective Study. Neurosurg Q. 2015;25(1):34–40.
7. Oliver Tannous;Ehsan. Jazini;Steven C.Anterior surgical treatment for cervical spondylotic myelopathy. Seminars in Spine Surgery. 2014;26(2):73–80.
8. Wen HQ, Wang X, Liao* WB, et al. Effective Range of Percutaneous Posterior Full-Endoscopic Paramedian Cervical Disc Herniation Discectomy and Indications for Patient Selection.[J]. BioMed Research International,2017, 2017: Article ID 3610385.
9. Ye ZY, Kong WJ, Liao* WB. ZJ xin,et ,Clinical Observation of Posterior Percutaneous Full-Endoscopic Cervical Foraminotomy as a Treatment for Osseous Foraminal Stenosis [J]. World Neurosurgery. 2017;106:945–52.
10. Qian Du MD, Xin Wang MD, Jian-Pu Qin PhD, Friis MD,T, Wei-Jun Kong PhD, Yu-Qiang Cai MD, Jun Ao MD, Xu MD,H, Wen-Bo MD, Liao* MDPercutaneous Full-endoscopic Anterior Transcorporeal Procedure for Cervical Disc Herniation: A Novel Procedure and Early Follow-up Study[J]. World Neurosurgery. .
11. Choi G, Lee SH, Bhanot A,et al. Modified transcorporeal anterior cervical microforaminotomy for cervical radiculopathy: a technical note and early results. Eur Spine J. 2007;16(9):1387–93.
12. C.J. Tang Candidate Bachelor of Science (Nursing) (Honour) program Student;S.W. Chan PhD in Nursing Professor;W.T. Zhou Advanced Practice Nurse, Master in Nursing Lecturer;S.Y. Liaw Registered Nurse, PhD in Medical Education Assistant Professor*. Collaboration between hospital physicians and nurses: An integrated literature review. Int Nurs Rev.2013,60(3):291–302.
13. Refatti C. Bevilacqua A.The integration between doctors and nurses in medical wards: the results of a survey. Assistenza Infermieristica E Ricerca. 2007;26(1):32–7.
14. Jue Lia;Jiliang Huangb;Jun Zhangc;Yajie Lid.A home-based, nurse-led health program for postoperative patients with early-stage cervical cancer: A randomized controlled trial.European Journal of Oncology Nursing.2016,21:174–180.

15. Jose Yanez;Beatriz Mariscal;Jose Yanez.A New Model of Attention in Nursing Home and Long Term. Care (NH/LTC) in México (Asylum): Includes Caregiver, Nurse and Physician Support and Use of Telemedicine in an a Tele Office or Residents Bedside. J Am Med Dir Assoc. 2017;18(3):B11.
16. Ruetten S, Komp M, Merk H,et al. Full-endoscopic anterior decompression versus conventional anterior decompression and fusion in cervical disc herniations[J]. Int Orthop. 2009;33(6):1677–82.
17. Tzaan W-C, MD*. Anterior Percutaneous Endoscopic Cervical Discectomy for Cervical Intervertebral Disc Herniation: Outcome, Complications, and Technique. Clinical Spine Surgery. 2011;24(7):421–31.
18. Ruetten S, Komp M, Merk H,et al.Full-endoscopic cervical posterior foraminotomy for the operation of lateral disc herniations using 5.9-mm endoscopes:a prospective,randomized,controlled study[J].Spine (Phila Pa 1976),2008,33(9):940–948.
19. Ce Zhu;Xi Yang;Lei Wang;Bo-wen Hu;Li-min Liu;Lin-nan Wang;Hao Liu;Yue-ming Songã. Comparison of dynamic. cervical implant versus anterior cervical discectomy and fusion for the treatment of single-level cervical degenerative disc disease: A five-year follow-up. Clin Neurol Neurosurg. 2018;64:103–7.
20. Tian Q, Zhang Y. Clinical features of cervical spondylopathy in surgeons: an analysis of 338 cases. Zhonghua Lao Dong Wei Sheng Zhi Ye Bing Za Zhi. 2015;33(2):131–2.
21. Liu Fu-shui, Zhang Y, Zhong. Ding-wen;Guo, Chang-qing. Symbol Meta-analysis of acupotomology versus acupuncture for cervical spondylopathy. Journal of Clinical Rehabilitative Tissue Engineering Research.2012,16(9): 1622–1625.
22. Gaber Saad Abd Elateef;Mahmoud Mohamad Hassan MD;Mohamad Abd Al Hady Abo Almakarem;Hossam Aldeen Mohamad Hassan.Outcome of conservative treatment of spondylotic cervical myelopathy and the predictive value of the magnetic resonance imaging findings. The Egyptian Orthopaedic Journal.2015,50(4):263–267.
23. Ghogawala Z, Benzel EC;Riew KD;Bisson EF;Heary RF.Surgery vs Conservative Care for Cervical Spondylotic Myelopathy: Surgery Is Appropriate for Progressive Myelopathy. Neurosurgery,2015,62(Suppl 1):56–61.
24. Madhavan K, Chieng LO, Foong H, Wang MY. Surgical outcomes of elderly patients with cervical spondylotic myelopathy: a meta-analysis of studies reporting on 2868 patients. Neurosurg Focus. 2016;40(6):E13.
25. Massey RL. Return of bowel sounds indicating an end of postoperative ileus: is it time to cease this long-standing nursing tradition? MEDSURG Nursing. 2012;21(3):146–50.
26. Burroughs. Jon1 jburroughs@burroughshealthcare.com;Bartholomew. New ways for physicians and nurses to work together. Phys Exec. 2014;40(3):60–2,64.
27. Hurley J, Graham Iain;Van, Vorst S, Cashin. Andrew.New ways to enhance mental health nursing: collaboration between academy and practice. Australian Nursing Midwifery Journal. 2014;21(11):43–4.
28. Lee JH, Lee SH. Clinical and radiographic changes after percutaneous endoscopic cervical discectomy:a long-term follow-up[J].Photomed Laser Surg,2014,32(12):663–668.

29. El-Zuway S, Farrokhyar F, Kachur E. Myelopathic signs and functional outcome following cervical decompression surgery: a proposed myelopathy scale. *J Neurosurg Spine*. 2016;24(6):871–7.
30. Hiroshi Nakagawa;Toshiyuki Okazaki;Koji Saito. Surgical Strategies in Management of Cervical Spondylotic Myelopathy. *World Neurosurgery*. 2015;84(2):220–1.
31. Toshinori, Sakai. Shinsuke Katoh,Koichi Sairyo,et al.Anterior Transvertebral Herniotomy for Cervical Disc Herniation..[J]. *J Spinal Disord Tech*. 2009;22:408–11.
32. Nagle LM. Yetman L.Moving to a culture of nurse as knowledge worker and a new way of knowing in nursing. *Studies In Health Technology Informatics*. 2009;146:467–72.
33. Harborne,Giles.Supplementary prescribing: A new way of working for psychiatrists and nurses. *Psychiatric Bulletin*.2008,32(4):136–139.
34. Peter Anderson;Marc D, Halley. A New Approach t o Making Your Doctor-Nurse Team More Productive. *Family Practice Management*.2008,15(7):35–40.
35. McInnes S, Peters K;Bonney A;Halcomb E.An integrative review of facilitators and barriers influencing collaboration and teamwork between general practitioners and nurses working in general practice. *Journal of Advanced Nursing*,2015,71(9):1973–1985.

Figures

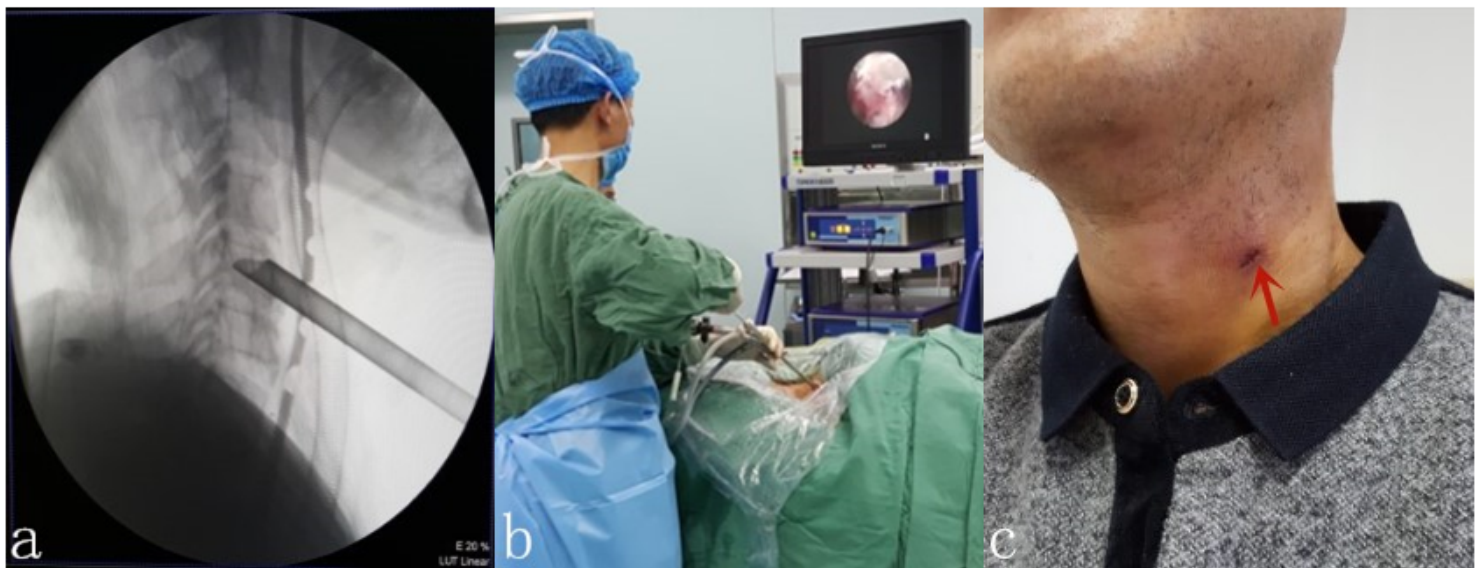

Figure 1

Percutaneous anterior full-endoscopic transcorporeal discectomy and spinal cord decompression: a. Intraoperative radiography; b. Intraoperative view; c. Minimally invasive incision scar on the neck after surgery.

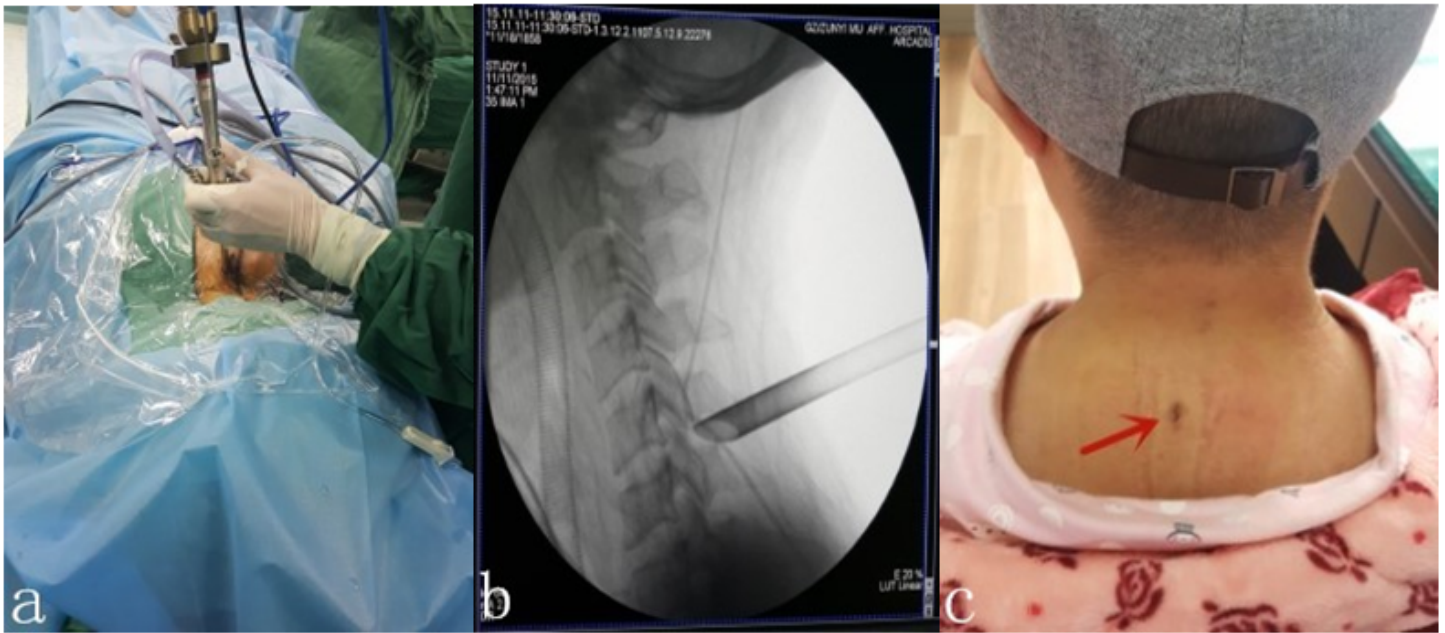


Figure 2

Percutaneous posterior full-endoscopic discectomy and nerve root decompression: a. Intraoperative view; b. Intraoperative radiography; c. The red arrow indicates the incision.

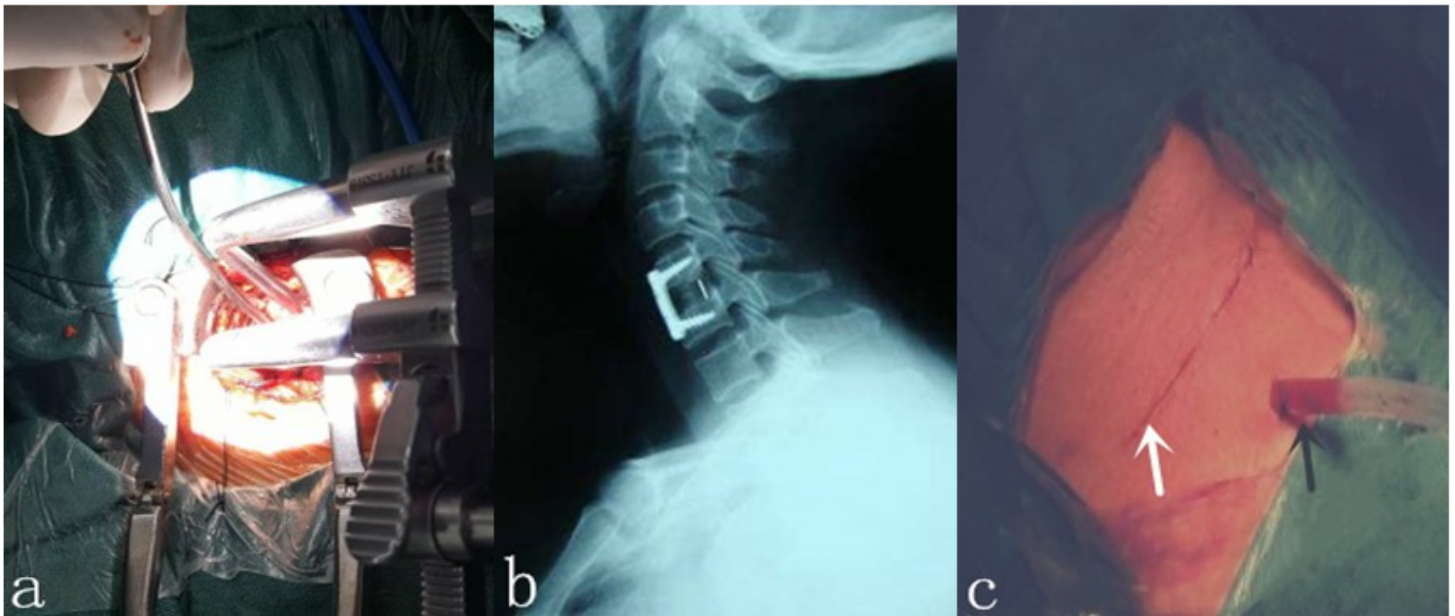


Figure 3

Anterior cervical discectomy and fusion: a. Intraoperative view; b. Radiograph showing of the internal fixation device; c. The white arrow indicates the incision and the black arrow indicates the drainage tube.