

# Comparison of Laparoscopic Orchiopexy and Traditional Inguinal Incision Orchidopexy for Palpable Undescended Testes in Cryptorchidism

Shaodong Gu (✉ [gushaodong369@outlook.com](mailto:gushaodong369@outlook.com))

The First People's Hospital of Lianyungang <https://orcid.org/0000-0002-8071-8105>

Hong Luo

Lianyungang No 1 People's Hospital

Yingxun wang

Lianyungang No 1 People's Hospital

---

## Research article

**Keywords:** Laparoscopic, orchiopexy, Palpable, undescended testes, Cryptorchidism

**Posted Date:** April 28th, 2020

**DOI:** <https://doi.org/10.21203/rs.3.rs-21664/v1>

**License:**   This work is licensed under a Creative Commons Attribution 4.0 International License.

[Read Full License](#)

---

**Version of Record:** A version of this preprint was published on February 15th, 2021. See the published version at <https://doi.org/10.1089/lap.2020.0832>.

# Abstract

**Background** Laparoscopic orchidopexy (LO) has become a standard procedure for the treatment of nonpalpable undescended testes. LO for palpable undescended testes is still controversial. The aim of this study is to explore the method and effect of laparoscopic orchiopexy procedure for palpable undescended testes in children suffering from cryptorchidism.

**Methods** A retrospective study was performed for LO and traditional inguinal incision orchidopexy(TIIO) for palpable undescended testes. Totally 220 children age ranged from 9 months to 96 months with both palpable inguinal canicular testes were included. 170 patients received LO and 50 patients received TIIO. Patient age, operative time and clinical outcomes were reviewed. Independent t test and Fisher's exact test were performed by SPSS 25.0 software.

**Results** The mean operative time ( $30.77 \pm 6.02$  vs  $44.76 \pm 6.70$  min), postoperative normal activity time ( $1.25 \pm 0.43$  vs  $2.48 \pm 0.68$  day) of LO was significantly shorter than TIO group. ( $P < 0.05$ ). 47 of 49 cases (95.9%) within 1-year-old were successfully achieved LO.

**Conclusion** LO is an appropriate choice for palpable undescended testes, especially in younger children within one-year-old. The successful percentage of LO decreased with age growing.

## Background

Cryptorchidism or undescended testes are a common genital malformation in boys. In similar studies performed in different countries, the prevalence of cryptorchidism has varied from 2.1 to 8.4% [1]. The incidence of undescended testes of birth to premature and/or birth weight ( $< 2500$  g) infants varies from 1.1–45.3% and bilateral presentation was 50–75% [2]. Traditional inguinal incision orchiopexy (TIIO) is recommended after 6 months of age [3]. Laparoscopic orchidopexy (LO) is a standard procedure for the treatment of nonpalpable undescended testes [4]. LO for palpable undescended testes is still controversial. This study has compared LO with TIIO in children with palpable undescended testes.

## Materials/methods

This study was approved by the Ethics Committee of The First People's Hospital of Lianyungang. Signed written informed consent was obtained from all participants before the study. From August 2014 to August 2019, a retrospective study of LO and TIIO was conducted. Totally 220 children with both palpable inguinal canicular testes were included(Table 1). LO was performed on 170 patients ages ranged from 9 months to 4 years (mean  $16.62 \pm 8.43$  months), 74 on the left side and 96 on the right. 50 patients ages ranged from 9 months to 96 months (mean  $18.37 \pm 15.35$  months) received TIIO, 23 of them on the left side and 27 on the right. All patients had unilateral palpable undescended testes and the testicles cannot be drawn into the scrotum in the physical examination. Patient age, operative time, the proportion of closure of internal inguinal ring (IIR) and clinical outcomes were reviewed. Follow-up visits were performed to assess the postoperative testes.

Table 1  
Patient general data

	LO	TIO	<i>P value</i>
total(N)	170	50	
Left side(N)	74	23	
Right side(N)	96	27	0.479
Age(months)	16.62 ± 8.43	18.37 ± 15.35	0.372

The patient was treated with general anesthesia, then a supine position was placed. Tilt the operating table to 15–20 degrees with the head low and feet high. A 5-mm umbilical incision was made along the superior border of umbilicus. First, a 5-mm trocar was inserted into the umbilical incision. CO<sub>2</sub> pneumoperitoneum was established routinely. The lens (30 degrees), was placed into the abdominal cavities to explore the IIR. If the IIR was closed, transfer to the inguinal incisions. If the IIR was unclosed, the other two 5-mm trocars were placed at the subcostal midclavicular line of the next procedure. Alternately using two grab clamps to pull the testes from the inguinal canal into the abdominal cavity. If the testicle can be pulled into the abdominal cavity, laparoscopic dissection and orchiopexy were performed. The gubernaculum testis (GT) was cut off in the abdominal cavity, then after adequate testicular mobilization, the testicle was retracted to the scrotum for orchiopexy. If the testicle cannot be pulled into the abdominal cavity, transfer to the inguinal incisions.

In TIO group, the GT was cut off through an inguinal incision. The testicles were brought down into the scrotum by a clamp inserted into the scrotum incision. The operations of both groups were done by some surgeons in the same period.

Independent t test and Fisher's exact test were performed by SPSS 25.0 software.

## Results

Among 170 patients that underwent laparoscopic exploration, 137 patients (80.5%) achieved LO without transfer to the inguinal incisions. Among them, 49 cases under 1-year-old, 48 cases (98.0%) IIR were unclosed, and 47 cases (95.9%) were successfully achieved LO, which took an average time of  $30.77 \pm 6.02$  minutes. Among the 86 patients aged 1–2 years, 83 cases (96.5%) IIR were unclosed, and 80 cases (93.0%) were successfully achieved LO. Among the 22 patients aged 2–3 years, 13 cases (59.1%) had unclosed IIR, and 9 cases (40.9%) successfully achieved LO. Among thirteen patients older than 3 years old, 3 patients (23.1%) had unclosed IIR and only 1 patient (7.7%) was successfully achieved LO. In all cases, the testicles were placed at the middle or bottom of the scrotum. 33 cases transferred to inguinal incisions for the IIR were closed. 10 cases transferred to the inguinal incision due to the testicle cannot be pulled into the abdominal cavity although the IIR was unclosed. (Fig. 1)

Mean operative time ( $30.77 \pm 6.02$  vs  $44.76 \pm 6.70$  min), postoperative normal activity time ( $1.25 \pm 0.43$  vs  $2.48 \pm 0.68$  day) of LO was significantly shorter than TIO group. ( $P < 0.05$ ). (Table 2).

Table 2  
Comparison of postoperative outcomes between LO and TIO within one-year-old

	LO	TIO	<i>P</i> -value
Cases(N)	48	50	
Operative time in minutes (mean $\pm$ std dev)	$30.77 \pm 6.02$	$44.76 \pm 6.70$	$< 0.001^*$
Normal activity time in days (mean $\pm$ std dev)	$1.25 \pm 0.43$	$2.48 \pm 0.68$	$< 0.001^*$
Testis atrophy(N)	1	2	$1.000^\ddagger$
Hernia recurrence(N)	0	0	
Value indicates <i>P</i> -value $< 0.05$ which was considered statistically significant			
*Independent samples t-test was performed			
$\ddagger$ Fisher's exact test was performed			

## Discussion

Cryptorchidism or undescended testes is a common congenital disease in children. Nearly 80 percent of undescended testes are palpable [5].

In 1995, Docimo et al. [6] first reported LO treatment of the palpable undescended testes and then Riquelme et al. summarized that LO is a safe procedure for patients with palpable undescended testes, no more complications were found. Of his 192 patients, only one case was converted to TIO [7, 8].

In recent years, LO has been mostly applied to the treatment of nonpalpable undescended testes and peeping testicles. The results show that laparoscopic surgery was more efficient and more sufficient in the aspect of testicular dissection than traditional surgery. Laparoscopic surgery had become a gold standard for nonpalpable undescended testes [5, 9]. However, the application of LO for palpable undescended testes was still controversial.

As far as we knew about the etiology of cryptorchidism, testicular descent occurs in two morphologically distinct phases, the second phase called inguinoscrotal phase which occurs between 25 and 35 weeks of gestation [10]. Testicular descent into scrotum relies on a ligament called gubernaculum testis (GT). The main ingredient of GT is primitive mesenchymal cells, which respond to hormonal cues and differentiate into cremaster muscle, then the testicular extend into scrotum. Many uncertain reasons prevented the differentiation and remain the testicle in the abdomen or groin in Cryptorchidism [11]. Meanwhile, the GT remained as ligament which leads the testicular could not extend into scrotum.

Surgery of orchidopexy needs to cut off the dysplastic GT as the main procedure to make adequate mobilization of testicles. In LO for palpable undescended testes surgery, if the testicles can be pulled back into the abdominal cavity, the laparoscopic way is more conveniently to cut off the dysplastic GT compared to the traditional way. The subsequent mobilization of testicles would be sufficient and efficient. So, whether the testicles can be pulled back into the abdominal cavity is a key procedure.

In 1975, the American Academy of Pediatrics recommended the optimal age for Orchidopexy was 4–6 years old [12]. Subsequent studies are shown that histopathological changes already become apparent in the first few months of life. In 1996, the American Academy of Pediatrics recommended that Orchidopexy should be performed at or near 1 year of age [13]. From 2008, AWMF of Europe recommended that surgery should be performed before the child's first birthday to minimize the risk of impaired fertility [14].

According to relevant literature reports, the incidence of cryptorchidism associated with an inguinal hernia was 56% [15]. More than 92% of patients with unilateral palpable undescended testes had an ipsilateral IIR unclosed at a median age of 14.9 months [16]. Our study found that 98.0% of children under 1-year-old, the IIR was unclosed. 97.9% of the testicles could be pulled into the abdominal cavity easily to accomplish the LO procedure.

Our study shows that palpable undescended testes associated with an ipsilateral unclosed IIR confirmed during the laparoscopy was more than 90% (91.7) even within 2 years of age. It's seemed that LO is not suitable for the majority of those elder children, especially over two years old. If IIR was closed, the LO surgery would be very hard to achieve, for testicles might be cannot be pulled back into the abdominal cavity in those patients. We have tried to reopen the closed IIR, then we found that it was still hard to pull back the testicles and increased the risk of damage to vas deferens and spermatic vessels. From this study, we found that opening IIR does not necessarily mean hernia. The open IIR is generally exists in cryptorchidism. The proportion of unclosed IIR decreased gradually with the increasing of age.

With regards to the closure of the peritoneal defect after the testicle has been mobilized during LO. When no ligature or suture was contemplated, the operative time decreased significantly. Rafiei et al. [17] carried out a randomized controlled trial to evaluate the no ligation method for children. He concluded that herniotomy without sac ligation in children saved many times and also prevented many other possible complications such as nerve damage, spermatic cord injury. Riquelme's literature shows that there was no need for closure of the internal inguinal ring during LO [18]. In his study of the staged treatment of LO, they found the peritoneum of the unsutured IIR in the first stage of the operation was completely closed during the second stage of the operation. Khairi et al. [19]. Carried out a prospective study to compare the difference between the IIR conventional suture group and IIR without closure group during LO. They concluded that the closing the peritoneum over the IIR can be omitted in LO, saving operative time and effort, no risk of recurrent inguinal hernia [20, 21].

The controversy of LO still focuses on abdominal interference and anesthesia with tracheal intubation, which may cause more risks to patients. No additional complications of LO were observed in our study.

Further studies are needed in the future. Accompany with the advance of technique, incisions of Laparoscopic surgery are becoming smaller and smaller which gives more cosmetic effects. Additionally, LO imitates the natural descent procedure of testes more similar.

## Conclusions

LO is an appropriate choice for palpable undescended testes, especially in younger children within one-year-old. The successful percentage of LO decreased with age growing.

## Abbreviations

LO  
Laparoscopic orchidopexy  
TIIO  
traditional inguinal incision orchidopexy  
GT  
gubernaculum testis  
IIR  
internal inguinal ring

## Declarations

### Ethics approval and consent to participate

The research has been performed in accordance with the declaration of Helsinki. Our study was approved by the Ethics Committee of the The First People's Hospital of Lianyungang. All parents for children who participate in the study provided written informed consent.

### Consent for publication

Not Applicable.

### The author confirms:

- that the work described has not been published before;
- that it is not under consideration for publication elsewhere;
- that its publication has been approved by all co-authors, if any;
- that its publication has been approved (tacitly or explicitly) by the responsible authorities at the institution where the work is carried out.

The author agrees to publish in the Journal indicated below and also in English by BMC surgery journal.

Names of ALL contributing authors: Shaodong Gu, Hong Luo, Yingxun Wang

### **Availability of data and materials**

The datasets used and/or analysed during the current study are available from the corresponding author on reasonable request.

### **Competing interests**

The authors declare no competing interests.

### **Funding**

This research did not receive any specific grant from funding agencies in the public, commercial, or not-for-profit sectors.

### **Authors' contributions**

GSD design the study; GSD and WYX collected the data;

GSD wrote the manuscript; WYX and LH revised the manuscript; all the

authors read and approved the final manuscript.

### **Acknowledgements**

The authors gratefully acknowledge the trust and support given by staff of our pediatric surgery

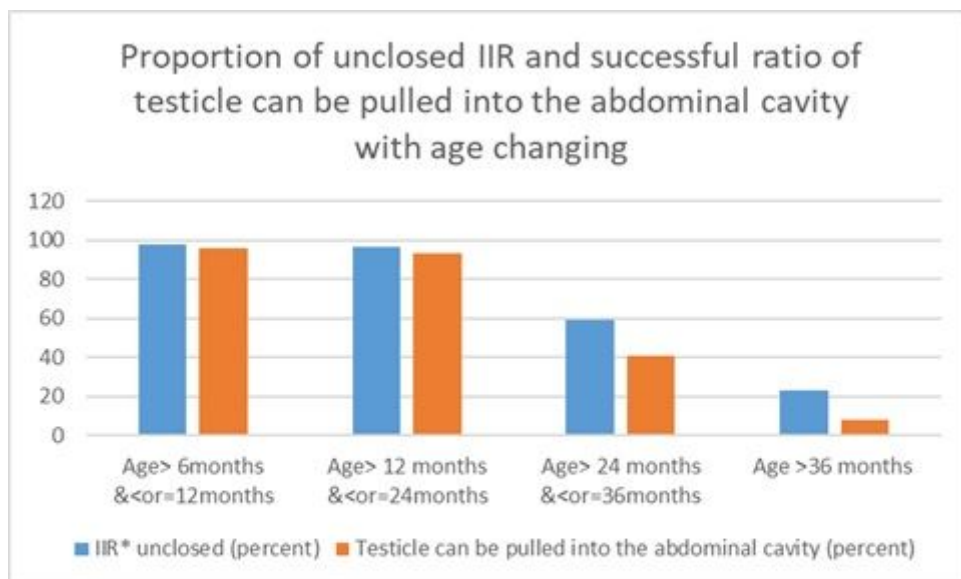
## **References**

1. Virtanen HE, Toppaari J. Epidemiology and pathogenesis of cryptorchidism. Hum Reprod Update. 2008;14(1):49–58.
2. Barthold JS, Gonzalez R. The epidemiology of congenital cryptorchidism, testicular ascent and orchiopexy. J Urol. 2003;170(6 Pt 1):2396–401.
3. Kolon TF, Herndon CD, Baker LA, Baskin LS, Baxter CG, Cheng EY, Diaz M, Lee PA, Seashore CJ, Tasian GE, et al. Evaluation and treatment of cryptorchidism: AUA guideline. J Urol. 2014;192(2):337–45.
4. Dar SA, Bali RS, Zahoor Y, Rashid Kema A, Bhardwaj R: Undescended Testes and Laparoscopy: Experience from the Developing World. Adv Urol 2018, 2018:1620470.
5. Niedzielski JK, Oszukowska E, Slowikowska-Hilczer J. Undescended testis - current trends and guidelines: a review of the literature. Arch Med Sci. 2016;12(3):667–77.
6. Docimo SG, Moore RG, Adams J, Kavoussi LR. Laparoscopic orchiopexy for the high palpable undescended testis: preliminary experience. J Urol. 1995;154(4):1513–5.

7. Riquelme M, Aranda A, Rodriguez C, Villalvazo H, Alvarez G. Laparoscopic orchiopexy for palpable undescended testes: a five-year experience. *J Laparoendosc Adv Surg Tech A*. 2006;16(3):321–4.
8. Riquelme M, Elizondo RA, Aranda A. Palpable Undescended Testes: 15 Years of Experience and Outcome in Laparoscopic Orchiopexy. *J Endourol*. 2015;29(9):978–82.
9. Elderwy AA, Kurkar A, Abdel-Kader MS, Abolyosr A, Al-Hazmi H, Neel KF, Hammouda HM, Elanany FG. Laparoscopic versus open orchiopexy in the management of peeping testis: a multi-institutional prospective randomized study. *J Pediatr Urol*. 2014;10(4):605–9.
10. Hutson JM, Li R, Southwell BR, Newgreen D, Cousinery M. Regulation of testicular descent. *Pediatr Surg Int*. 2015;31(4):317–25.
11. Szarek M, Li R, Vikraman J, Southwell B, Hutson JM. Molecular signals governing cremaster muscle development: clues for cryptorchidism. *J Pediatr Surg*. 2014;49(2):312–6. discussion 316.
12. The timing of elective surgery on. the genitalia of male children with particular reference to undescended testes and hypospadias. *Pediatrics*. 1975;56(3):479–83.
13. Timing of elective surgery on. the genitalia of male children with particular reference to the risks, benefits, and psychological effects of surgery and anesthesia. *American Academy of Pediatrics. Pediatrics* 1996, 97(4):590–594.
14. Mathers MJ, Sperling H, Rubben H, Roth S. The undescended testis: diagnosis, treatment and long-term consequences. *Dtsch Arztebl Int*. 2009;106(33):527–32.
15. Barthold JS, Wintner A, Hagerty JA, Rogers KJ, Hossain MJ. Cryptorchidism in Boys With Cerebral Palsy Is Associated With the Severity of Disease and With Co-Occurrence of Other Congenital Anomalies. *Front Endocrinol (Lausanne)*. 2018;9:151.
16. Aggarwal H, Kogan BA, Feustel PJ. One third of patients with a unilateral palpable undescended testis have a contralateral patent processus. *J Pediatr Surg*. 2012;47(9):1711–5.
17. Rafiei MH, Jazini A. Is the ligation of hernial sac necessary in herniotomy for children? A randomized controlled trial of evaluating surgical complications and duration. *Adv Biomed Res*. 2015;4:97.
18. Riquelme M, Aranda A, Rodriguez C, Cortinas J, Carmona G, Riquelme QM. Incidence and management of the inguinal hernia during laparoscopic orchiopexy in palpable cryptorchidism: preliminary report. *Pediatr Surg Int*. 2007;23(4):301–4.
19. Khairi A, Shehata S, El-Kholi N. Is it necessary to close the peritoneum over the deep inguinal ring during laparoscopic orchidopexy? *J Pediatr Urol*. 2013;9(2):157–60.
20. Mohta A, Jain N, Irniraya KP, Saluja SS, Sharma S, Gupta A. Non-ligation of the hernial sac during herniotomy: a prospective study. *Pediatr Surg Int*. 2003;19(6):451–2.
21. Narayanan SK, Puthenvariath JN, Somnath P, Mohanan A. Does the internal inguinal ring need closure during laparoscopic orchiopexy with Prentiss manoeuvre? *Int Urol Nephrol*. 2017;49(1):13–5.

## Figures





\* Internal inguinal ring

**Figure 1**

Proportion of unclosed IIR and successful raTIIO of testicle can be pulled into the abdominal cavity with age changing.