

# A rare symptom of olfactory dysfunction in coronavirus disease 2019: report of three cases

**ChenChen**

Nanjing Infectious Disease Center, the Second Hospital of Nanjing, Nanjing University of Chinese Medicine

**Moxian Chen**

Nanjing Infectious Disease Center, the Second Hospital of Nanjing, Nanjing University of Chinese Medicine

**Cong Cheng**

Nanjing Infectious Disease Center, the Second Hospital of Nanjing, Nanjing University of Chinese Medicine

**Yun Chi**

Nanjing Infectious Disease Center, the Second Hospital of Nanjing, Nanjing University of Chinese Medicine

**Zhiliang Hu**

Nanjing Infectious Disease Center, the Second Hospital of Nanjing, Nanjing University of Chinese Medicine

**Yuan Liu**

Nanjing Infectious Disease Center, the Second Hospital of Nanjing, Nanjing University of Chinese Medicine

**Shan Huang**

Nanjing Infectious Disease Center, the Second Hospital of Nanjing, Nanjing University of Chinese Medicine

**Yanling Lv**

Nanjing Infectious Disease Center, the Second Hospital of Nanjing, Nanjing University of Chinese Medicine

**Chongfeng Liang**

Nanjing Infectious Disease Center, the Second Hospital of Nanjing, Nanjing University of Chinese Medicine

**Damin Jiao**

Nanjing Infectious Disease Center, the Second Hospital of Nanjing, Nanjing University of Chinese Medicine

**Yongxiang Yi**

Nanjing Infectious Disease Center, the Second Hospital of Nanjing, Nanjing University of Chinese Medicine

**Xia Zhang**

Nanjing Infectious Disease Center, the Second Hospital of Nanjing, Nanjing University of Chinese Medicine

**Wenkui Sun** (✉ [sunwenkui@njmu.edu.cn](mailto:sunwenkui@njmu.edu.cn))

The First Affiliated Hospital of Nanjing Medical University

**Hongxia Wei** (✉ [wghongxia@sina.com](mailto:wghongxia@sina.com))

Nanjing Infectious Disease Center, the Second Hospital of Nanjing, Nanjing University of Chinese Medicine

---

**Case Report**

**Keywords:** COVID-19, Olfactory dysfunction, Rare symptom

**Posted Date:** April 9th, 2020

**DOI:** <https://doi.org/10.21203/rs.3.rs-21599/v1>

**License:**  This work is licensed under a Creative Commons Attribution 4.0 International License.

[Read Full License](#)

---

# Abstract

Three patients of coronavirus disease (COVID-19) showed the symptoms of olfactory dysfunction. Clinical characteristics and treatment were retrospective analyzed. Olfactory disorders are uncommon symptoms of COVID-19. Early diagnosis and intervention are key to the recovery of olfactory disorders. Particular attention should be devoted to rare symptoms of COVID-19.

## Introduction

Since December 2019, when the first patient with a confirmed case of COVID-19 was reported in Wuhan, China, over 100,000 patients with confirmed cases have been reported worldwide. It has been reported that the most common symptoms include fever, fatigue, dry cough, anorexia, myalgia and dyspnea. Meanwhile, less common symptoms are nasal congestion, headache, runny nose, sore throat and diarrhea (Wang et al, 2020). However, clinical cases with rare symptoms such as olfactory dysfunction have not been reported so far in China or abroad. We report 3 cases of new coronavirus pneumonia with olfactory dysfunction, two of which were accompanied by taste disorders. These cases will improve awareness of the symptoms and the treatment of the disease.

## Case Reports

Case 1. Female, age 18, with a fever and dry cough since 1 February 2020. The symptoms quickly disappeared after being admitted to the hospital on 3 February for antiviral treatment with darunavir/cobicistat and arbidol. Since 10 February she noted complete anosmia. Due to no awareness, it is hard to know when this symptom appears. Subsequently, oral methylcobalamin tablets were administered. As of 21 February, the patient can smell irritating odors, such as alcohol, but the olfactory function has not yet returned to normal (Fig. 1a).

Case 2. Female, age 26, with a sore throat and dry cough from 7 February 2020, was placed in an isolation room the next day. The antiviral therapy was arbidol and ribavirin. She recovered from these symptoms 5 days later. On 9 February, the patient reported a sudden loss of sense of smell and taste simultaneously, accompanied by severe double-sided nasal congestion, runny nose and severe headache, which were relieved after 2 days. But the anosmia and taste disorder did not improve. Methylcobalamin tablets were applied from 14 February, and on 15 February, a temporary intravenous drip of methylprednisolone 40 mg was applied. The next day, the smell and taste improved and were restored to usual on 24 February.

Case 3. Male, age 27, with muscle aches, fever and dry cough since 31 January 2020, was admitted to an isolation room on 8 February for antiviral treatment with lopinavir/ritonavir and arbidol. The patient had completely lost the sense of smell and taste on 3 February, accompanied by slight nasal obstruction and mucus. Because he did not pay attention to the symptoms, he could not smell anything 10 days later. The

doctor added a dose of methylcobalamin tablets to his treatment starting on 14 February. His olfaction and gustation had returned to normal on 24 February.

## Discussion

All 3 cases were young people. Olfactory dysfunction occurred, on average, 6 days after the onset of the first symptom related to COVID-19 and [aggravated](#) rapidly. The qRT-PCR tests showed positive detection to throat swab and negative to nasal mucosa swab. Specifically, all patients recovered rapidly from common symptoms of COVID-19. However, the median recovery time of olfactory dysfunction was 20 days reflecting the slow recovery of neurological function. Neither hematology examination nor cranial CT showed any significant abnormality (Fig. 1b), which excluded olfactory/taste disorders caused by innate diseases, drugs, trauma, intracranial occupancy, influenza and para-flu viral infections.

Studies have shown that severe acute respiratory syndrome coronavirus 2 (SARS-CoV-2) has the typical characteristics of Coronaviridae and shares approximately 85% homology with severe acute respiratory syndrome coronavirus (SARS-CoV) (Gralinski and Menachery, 2020). Moreover, coronavirus has neuropathic effects. There have been reports of human severe acute respiratory syndrome (SARS) with concomitant peripheral neuropathy in all four limbs or acute olfactory neuropath (Tsai et al, 2005; Hwang, 2006). Cases 2 and 3 were accompanied by nasal obstruction and recovered rapidly. Inflammatory edema of the mucous membrane may be the main mechanism. However, the slow relief on olfactory dysfunction may be related to damage to the olfactory central or peripheral nervous system.

Angiotensin-converting enzyme 2 (ACE2) is thought to be the main host cell receptor of SARS-CoV-2. The expression pattern of ACE2 in different organs indicates the potential high risk for SARS-CoV-2 infection and may be closely related to clinical manifestations (Zou et al, 2020). In particular, a high level of ACE2 expression was identified in numerous cell types, including esophageal upper and stratified epithelial cells, type II alveolar cells of lung, myocardial cells, absorptive enterocytes of the ileum and colon, cholangiocytes, kidney proximal tubule cells and bladder urothelial cells (Zou et al, 2020). For example, high expression of ACE2 in the genitourinary system in patients with COVID-19 causes rare symptoms of orchitis. Thus, the accompanying taste disorders in these two cases may be also related to the expression level of ACE2 in the epithelial cells of the oral mucosa (Xu et al, 2020). The aforementioned examples provided a potential link between SARS-CoV-2 infection and olfactory disorders. However, the underlying mechanism requires further study. In addition, all three patients in this report were young people and whether the expression level of ACE2 is related to age is currently unknown.

COVID-19 could be a special neuropathy that can cause permanent damage on human health. Additionally, intensive consultation and further detection are required in these cases according to the ignorance of rare symptoms, such as symptoms of neurological injury. Furthermore, there is no clinical evidence to show an effective clinical intervention, despite the use of corticosteroids or [neurotrophic drugs](#) (Harless and Liang, 2016). Based on these three cases, early diagnosis and intervention would be the key to the recovery of olfactory dysfunction, particularly for young people.

# Declarations

**Acknowledgements** We gratefully acknowledge all those who contributed to this work, in particular, Nanjing Infectious Disease Center staff for their contributions to the clinical care of the patients.

**Funding** This work was supported by the National Science Foundation of China (NSFC 81770009).

**Conflicts of interest** The authors declare that they have no conflict of interest. All authors meet the ICMJE authorship criteria.

**Ethics approval** Compliance with ethical standards.

**Ethics approval** :This case series was approved by the Institutional Ethics Board of the Second Hospital of Nanjing (No. 2020-L-S-ky003).

These patients were contacted by telephone to obtain verbal informed consent.

**Authors' contributions** Data collection were performed by Yuan Liu, Shan Huang, Yanling Lv, Chongfeng Liang, Damin Jiao and Chen Chen. The first draft of the manuscript was written by Chen Chen and Moxian Chen. All authors commented on previous versions of the manuscript. Critical revision of the manuscript was performed by Wenkui Sun and Hongxia Wei. All authors read and approved the final manuscript.

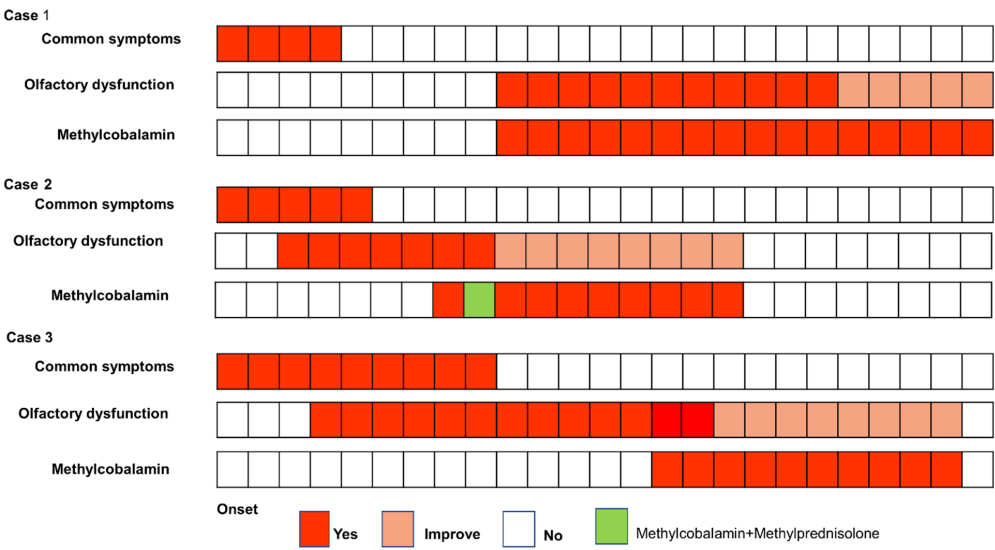
# References

1. Gralinski LE, Menachery VD (2020). Return of the Coronavirus: 2019-nCoV. *Viruses* 12: E135.
2. Harless L, Liang J (2016). Pharmacologic treatment for postviral olfactory dysfunction: a systematic review. *Int Forum Allergy Rhinol* 6: 760-7.
3. Hwang CS (2006). Olfactory Neuropathy in Severe Acute Respiratory Syndrome: Report of a Case. *Acta Neurol Taiwan* 15: 26-28.
4. Miwa T, Ikeda K, Ishibashi T, Kobayashi M, Kondo K, Matsuwaki Y, Ogawa T, Shiga H, Suzuki M, Tsuzuki K, Furuta A, Motoo Y, Fujieda S, Kurono Y (2019). Clinical practice guidelines for the management of olfactory dysfunction — Secondary publication. *Auris Nasus Larynx* 46: 653-662.
5. Tsai LK, Hsieh ST, Chao CC, Chen YC, Lin YH, Chang SC, Chang YC (2005). Neuromuscular Disorders in Severe Acute Respiratory Syndrome. 61: 1669.
6. Wang D, Hu B, Hu C, Zhu F, Liu X, Zhang J, Wang B, Xiang H, Cheng Z, Xiong Y, Zhao Y, Li Y, Wang X, Peng Z (2020). Clinical Characteristics of 138 Hospitalized Patients With 2019 Novel Coronavirus-Infected Pneumonia in Wuhan, China. *JAMA*: 10.1001/jama.2020.1585.
7. Xu H, Zhong L, Deng J, Peng J, Dan H, Zeng X, Li T, Chen Q (2020). High expression of ACE2 receptor of 2019-nCoV on the epithelial cells of oral mucosa. *Int J Oral Sci* 12: 8.

8. Zou X, Chen K, Zou J, Han P, Hao J, Han Z (2020). Single-cell RNA-seq data analysis on the receptor ACE2 expression reveals the potential risk of different human organs vulnerable to 2019-nCoV infection. Front Med.

Figures

(a)



(b)

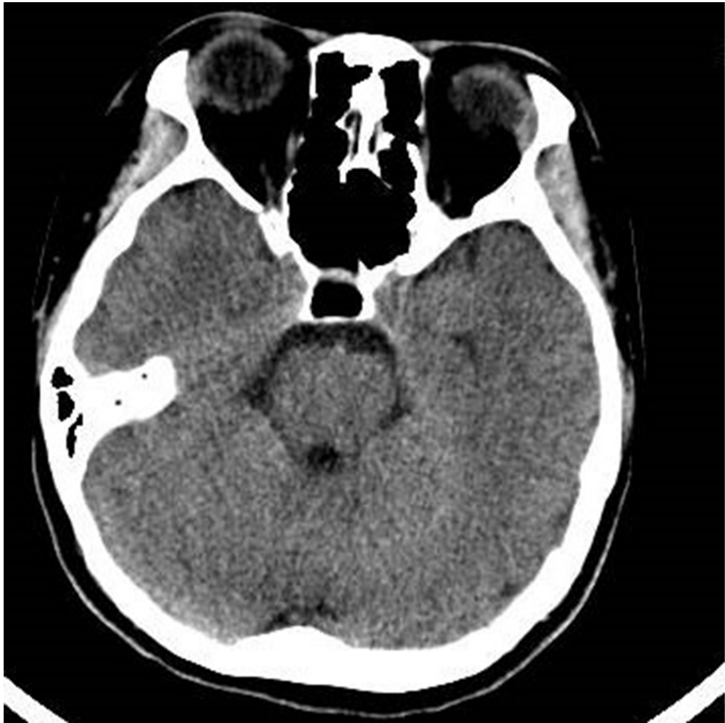

Figure 1

a: The course of symptoms and treatments. b: CT examination shows no definite lesion in both brain and nasopharynx.