

# Treatment of fresh thoracolumbar vertebral burst fracture based on intraoperative CT scan

yuwei li (✉ [ccccreation@163.com](mailto:ccccreation@163.com))

Spine Surgery

wei cui

Luohe Medical College

Peng Zhou

Luohe Medical College

Cheng Li

Luohe Medical College

Wei Xiao

Luohe Medical College

Yan Wen

Luohe Medical College

---

## Research article

**Keywords:** Spinal fractures, Spinal cord injuries, Posterior ligamentous complex, Decompression

**Posted Date:** May 12th, 2020

**DOI:** <https://doi.org/10.21203/rs.3.rs-21232/v1>

**License:** © ⓘ This work is licensed under a Creative Commons Attribution 4.0 International License.

[Read Full License](#)

---

# Abstract

## Objective

To evaluate the value of intraoperative CT scanning in the treatment of fresh thoracolumbar burst fractures .

## Method

The data of patients with thoracolumbar fractures from January 2008 to January 2015 were analyzed retrospectively, 79 cases were treatment group which were treated with intraoperative CT scan and decompression mode was determined according to CT scan results during the period from October 2012 to January 2015; 82 patients as the observation group were treated without intraoperative CT scan and direct laminectomy were performed during the period from January 2008 to October 2012. In the treatment group, it is no further decompression of the spinal canal when the CT showed a reduction of the fracture block into the spinal canal, If the intraoperative CT showed that the fractures still occupied the spinal dura mater according to the three-dimensional CT information, The position and the size of the fracture of the spinal canal were determined, and the unilateral laminectomy was performed corresponding to the position of the lamina and intervertebral ligamentum flavum. The operative time, bleeding volume, neurological function, height of the anterior vertebral compression and Cobb angle were compared between the two groups.

## Result

In the treatment group, CT scan showed 48 cases (60.8%) entered the spinal canal fracture completely or basically reset .31 cases (39.2%) still occupied the spinal canal compression spinal dura mater. There were significant differences in the operation time and bleeding volume between the two groups. The treatment group was less than the control group. There was no infection, secondary spinal cord injury, loose fixation and other complications. There was no difference in the ASIA classification before and after operation. The anterior vertebral height and COBB angle of the two groups were significantly improved compared with those before operation. There was no significant difference between the two groups in the postoperative height and COBB angle, but after 2 years the difference was statistically significant between the two groups, to retain the rear ligament complex treatment group was significantly better than the control group.

## Conclusion

Patients of thoracolumbar vertebral fracture in hyperextension position combined with internal fixation can achieve good correction effect. Orthopedic postoperative CT scan and according to the results of the scan precision treatment can simplify the operation, there was no difference in clinical efficacy compared with total laminectomy, but some patients avoid the spinal canal decompression and part were treated by small fenestration laminectomy decompression, which is conducive to the protection of spinous ligament complex integrity.

# Background

With the increase of transportation tools, the number of spine fractures caused by various kinds of injuries is increasing. The thoracolumbar segment of the spine is in the relatively fixed region of transformation between posterior convexity and anterior convex. The vertebral body fracture in this area can easily cause spinal nerve injury and needs surgical treatment<sup>[1-3]</sup>. Posterior pedicle fixation, orthopaedic is a common surgical method, for burst fractures with spinal canal invasion, laminectomy and spinal canal exploration are often performed simultaneously with posterior pedicle fixation, which will destroy the posterior ligament complex (PLC) of the spine and affect the stability of the spine<sup>[4-7]</sup>. In the mid-1990 s, with the technical innovation of CT hardware, its mobility was significantly improved, on which mobile CT was born and began to be widely used in clinical surgery<sup>[8]</sup>. Rapid intraoperative CT scanning and accurate corresponding treatment were used according to the intraoperative CT information to achieve good clinical efficacy.

## Materials And Methods

The study protocol was approved by the Institutional Review Boards and the Ethics Committees of Luohe Medical College. Before operation, informed consents were signed by all the patients after detailed explanation of the therapeutic procedure to the patients.

This study is a multi-center case series which was conducted in 3 hospitals specialized in the management of spinal cord diseases. The study is conducted according to the guideline for case series.

### Samples

The data of patients with thoracolumbar fracture treated in 3 affiliated hospitals from January 2008 to January 2015 were retrospectively analyzed. A total of 161 cases were included. The patients were divided into two groups according to whether to use intraoperative CT scanning or not. 79 patients who used intraoperative CT scanning and decided to decompression according to the CT scanning results were in the treatment group. 82 patients who received vertebroplasty and decompression without intraoperative CT scanning were in the observation group.

Inclusion criteria: ①single segment fresh fracture of thoracolumbar vertebral body of the herniated thoracolumbar vertebra, A3 fracture in AO classification, complete or partial crushing of vertebral body, backward protrusion of vertebral posterior wall fracture plate into vertebral canal; ②The involvement of the spinal canal was greater than or equal to 40%, with or without nerve damage; ③The height of the anterior edge of the vertebral body was lost or greater than 40%. ④The posterior ligament of the vertebral column is intact.

Exclusion criteria: ①anterior posterior thoracolumbar ligament or bone structure injury; ②Patients with type B and C fractures with dislocation in the AIAO classification. ③Patients with previous neurological

diseases; ☐To be associated with spinal infection, tumor, metabolic bone disease and other diseases of bone damage; ☐loss of visitors.

During the research period all patients were assessed for suitability according to the inclusion and exclusion criteria. The study protocol was approved by the local ethnic board, and informed consent was obtained from all the patients in the study.

There were 43 males and 36 females in the treatment group. The average age was  $45.2 \pm 13.8$  years. Among them, there were 3 cases of T10, 8 cases of T11, 18 cases of T12, 21 cases of L1, 20 cases of L2 and 9 cases of L3, all of which were single segment fresh vertebral fractures (course < 2 weeks). Causes of injury: 37 cases of high fall injuries, 23 cases of traffic accident injuries, 19 cases of heavy object injuries. According to the American Spinal Injury Association (ASIA), neurological function is graded [7] : 0 cases of grade A, 9 cases of grade B, 18 cases of grade C, 16 cases of grade D and 36 cases of grade E. There were 45 males and 37 females in the observation group. Age 19 ~ 69, average  $44.9 \pm 12.9$  years. There were 2 cases of T10, T11, T12, L1, 22 cases of L2 and 8 cases of L3, all of which were single segment fresh vertebral fractures. Causes of injury: 39 cases of high fall injuries, 21 cases of traffic accident injuries, 22 cases of heavy object injuries. Neuro-functional ASIA was classified into 0 cases of grade A, 10 cases of grade B, 18 cases of grade C, 19 cases of grade D and 35 cases of grade E. The comparison of general data was shown in table 1. There were no statistically significant differences between the two groups in gender, age, fracture segments, high compression ratio of the anterior margin of the injured vertebra, Cobb Angle of the injured vertebra, and neurological function ASIA grading ( $P > 0.05$ ).

## Procedures

After admission to the hospital, To illustrate the extent of the fracture and to determine the adequate surgical procedure, all the patients received both anteroposterior and lateral X-rays as well as a computed tomography (CT) and magnetic resonance imaging (MRI) according to standard protocol.

After evaluation, ensure that eligible patients undergo surgery in accordance with established guidelines and regulations to reconstruct spinal sequence and stability.

1 Treatment group: With general anesthesia in the prone position, the part of the spine fracture is placed at the folding line of the foldable surgical bed. The posterior median approach was adopted. Peeling off the paravertebral muscles, revealing the lower edge of the superior articular process of the upper and lower vertebral bodies of the injured vertebrae, placing pedicle screws with the method of articular process and transverse process positioning, placing the pre-bent connecting rod, folding the operating table to make the spine hyperextension. The pedicle screw was pricked and tightened under the extremely overstretched position to restore the height of the injured vertebra and restore the fracture block [8]. After the vertebral height was restored by fluoroscopy, the intraoperative bedside CT (German Siemens 3d imaging c-arm machine) was performed for rapid examination to understand the reduction of the fracture block at the posterior margin of the injured vertebra. If the fragment has been repositioned or basically

repositioned, the spinal canal will not be decompressed; if the fragment still occupies the spinal canal and compresses the dura mater, according to the intraoperative three-dimensional CT information, the position and size of the fragment protruding into the spinal canal will be positioned. Unilateral lamina fenestration will be performed according to the position of the corresponding lamina and ligamentum flavum intervertebralis applied. A proton dissector or L-knife (Fig. 1a) is used to explore the posterior wall of the spinal canal (Fig. 1b) around the lateral dura mater, and to hold the fragment against it. The hammer is tapped gently until the fragment is reduced and the posterior edge of the vertebral body is smooth (Fig. 1c ~ d). Rinse the incision, place negative pressure drainage, close the incision. After 12 ~ 18 months, internal fixation was taken out.

2. Observation group: Posture, anesthesia, exposure, pedicle screw placement were the same as above, without rapid intraoperative CT scan, total laminectomy and spinal canal decompression were performed directly, and then posterolateral bone fixation, drainage tube placement, closure of the incision.

## Statistical Analysis

All statistical analyses were performed with the use of SPSS software, version 12 (SPSS Inc, Chicago, IL). The results were expressed as average  $\pm$  SD. Dunnett method was used to compare different time in groups. The counting data is indicated by percentage and chi-square test is adopted. Check level was set at both sides = 0.05.

Evaluation criteria of clinical efficacy

Neurological function was assessed by the American Spinal Cord Injury Association (ASIA) scoring standard [9].

Evaluation standard of orthopedic effect

1. The height compression ratio of the injured anterior vertebra [10] was measured on the standard lateral radiographs of the spine. The height of the injured anterior vertebra was measured on the lateral radiographs before operation, the third day after operation and 24 months after operation. The normal height of the anterior edge of the injured vertebrae was divided by the sum of the height of the anterior edge of the upper and lower vertebrae divided by 2. The measured value of the anterior edge of the injured vertebra was divided by the proposed normal height and multiplied by 100% to obtain the compression ratio of the anterior edge of the injured vertebra.
2. Cobb angle kyphosis: The Cobb angle on the lateral radiographs of the spine was measured preoperatively, 3 days postoperatively and 24 months postoperatively.

## Results:

1 surgical results.

In the treatment group, 48 of the 79 patients did not undergo spinal decompression surgery according to on intraoperative CT scans. 31 cases showed that the fragment still occupied the spinal canal and compressed the dura mater, and unilateral laminectomy was performed. The operation time was 41 ~ 93 min, with an average of  $67 + 17.8$  min, and the bleeding volume was 50 ~ 390 ml, with an average of  $187 + 30.1$  ml. Control group: operation time 65 ~ 127 min, average  $86 + 11.5$  min; bleeding volume 172 ~ 570 ml, average  $296 + 51.2$  ml. There was significant difference in operative time and bleeding volume between the two groups, and the treatment group was significantly lower than the control group.

## 2 Complications

There were no infection, secondary spinal nerve injury, internal fixation fracture and other complications in both groups.

## 3. Clinical effect evaluation

Two groups of postoperative neurological function ASIA classification comparison is shown in Table 2, there is no significant difference between the two groups.

## 4. Imaging evaluation

The comparison of the height compression ratio and kyphotic COBB Angle of the anterior edge of vertebral injury between the two groups is shown in Table 3.

The height of anterior vertebral injury and Cobb Angle of the two groups were significantly recovered compared with that before the operation ( $P < 0.01$ ). There was no statistically significant difference ( $P > 0.05$ ) in the height of anterior vertebral injury and Cobb Angle between the two groups 3 days after surgery, but there was statistically significant difference ( $P < 0.01$ ) in the comparison between the two groups 2 years after surgery. Typical cases are shown in Figs. 2 and 3.

# Discussions

Compression, displacement and kyphosis occur when thoracolumbar vertebral fractures occur. Spinal cord is stretched, sheared, or even transected. Secondary injuries such as spinal cord edema, ischemia and cell injury caused by free radical oxidizing cells occur. Surgical decompression for thoracolumbar fractures with spinal cord compression has the potential to reduce intradural pressure and increase spinal cord blood supply, reduce spinal cord ischemia and prevent secondary spinal cord injury.

Dendrinios[11] believes that the improvement of Cobb angle of spinal cord above 5 degrees is also conducive to nerve recovery. At the same time, the kyphosis deformity after thoracolumbar vertebra fracture makes the spine lose balance, leading to the long-term development of lumbago and the acceleration of degeneration. Therefore, the better the recovery of vertebral height and kyphosis deformity, the lower the incidence of long-term lumbago [12]. There are two methods for reduction of injured vertebrae: postural reduction and internal fixation instrumentation. These two methods were

combined in operation. The principle of overextension position combined with pedicle screw fixation for correction of vertebral height and kyphosis is that the vertebral body of thoracolumbar fractures is mostly compressed in axial direction, so the anterior longitudinal ligament, posterior longitudinal ligament and fascial soft tissue of the vertebral body remain intact, and the reduction is precisely based on the intact soft tissue of the ligament. Prerequisite, by making the local fracture vertebral body open, spinal protrusion, anterior longitudinal ligament, posterior longitudinal ligament and fascial soft tissue tension, tension, so that fracture vertebral body height recovery, into the vertebral canal fracture reduction, but for the inverted fracture block (has been removed from the posterior longitudinal ligament) invalid [9]

Watson-Jones[13] first noticed the concept of Posterior ligamentous complex (PLC) and its importance to maintain spinal stability. Denis[14] put forward the three-column theory of the spine, which has been widely accepted. The posterior column structure includes vertebral plate, spinous process, interspinous ligament, etc., especially emphasizing the importance of PLC. Vaccaro et al[15]. guided the selection of treatment program according to the mechanical characteristics of injury, the integrity of PLC and the state of neurological function. Therefore, the PLC formed by the structures of supraspinal ligaments, interspinous ligaments, spinous processes, and lamina plays a very important role in maintaining the stability of the spine. No damage to PLC type A3 thoracolumbar fractures patients, in order to avoid because of the need of the spinal canal decompression and man-made destruction of PLC, group adopts comprehensive skills in orthopaedic surgery after CT scan quickly, understand the vertebral height restoration after spinal canal fracture block reset, and then make a decision according to the fracture block restoration situation accurate treatment plan, as much as possible to maintain the stability of spine rear, retained the rear ligament complex. Group found that 60.8% of the patients with hyperextension position after reset and nail stick open orthopaedic spinal canal fracture block has been reset, there is no need for any spinal canal decompression, only 39.8% of patients need decompression, analysis the indirect reduction and the cause of the failure injury time is too long after adhesion, fracture hematoma fibrosis after the flip, fracture blocks from longitudinal ligaments and other reasons, led to into vertebral canal fracture piece of reduction and incomplete or inadequate [16–21]. According to the CT information of intraoperative three-dimensional reconstruction, the position and size of the fracture lumps in the inboards were located precisely. According to this, unilateral lamina decompression was performed at the positions of the lamina and the intervertebral yellow ligament without damaging the PLC structure. In contrast to the direct total laminar decompression group, which had not been performed in previous operations, the long-term vertebral height was not significantly lost, indicating the importance of preserving the PLC structure.

## Conclusion

In combination with the above, the hyperextension position combined with internal fixation is adopted for the patients with thoracolumbar vertebral burst fracture, which can achieve good orthopaedic effect. After the orthopaedic procedure, CT scan was performed during operation. According to the scanning results, precise treatment was made to decide whether to decompress or not. In this way, some patients can avoid intravertebral decompression, and some patients adopt lamina small window decompression, which is

conducive to protecting the integrity of the posterior ligament complex and preventing the high long-term loss of vertebral body. It is a better method to treat fresh thoracolumbar vertebral fracture

## Abbreviations

PLC

posterior ligament complex

MRI

magnetic resonance imaging

CT

computed tomography

ASIA

American Spinal Cord Injury Association

## Declarations

### 1 Ethics approval and consent to participate

The study protocol was approved by the Institutional Review Boards and the Ethics Committees of Luohe Medical College. Before operation, informed consents were signed by all the patients after detailed explanation of the therapeutic procedure to the patients. The study is conducted according to the guideline for case series.

### 2 Consent for publication

Written informed consent for publication was obtained from all participants.

### 3 Availability of data and material

All data generated or analysed during this study are included in this published article

### 4 Competing interests

The authors declare that they have no competing interests

### 5 Funding:

This work was financed by grants from National Health and Family Planning Commission of the People's Republic of China (W2014ZT096) and Henan provincial health and family planning commission (201504092)

### 6 Authors' contributions



All authors contributed to data collection and wrote the manuscript. Wei Cui and Yuwei Li drafted the study protocol. Peng Zhou and Cheng Li performed literature review. Wei Xiao and Yan Wen collected data. Peng Zhou performed the analyses. Yuwei Li, Wei Cui and Haijiao Wang drafted the paper. All authors critically reviewed the paper. Yuwei Li and Wei Cui had full access to all the data in the study and takes responsibility for the integrity of the data and the accuracy of the data analysis. Yuwei Li and Wei Cui are the guarantors of the paper. All authors approved the current manuscript to be published, attested that they contributed substantially to the current work, and disclosed that there was no writing assistance.

## 7 Acknowledgements

First of all, I would like to extend my sincere gratitude to Professor Wang Haijiao, for his instructive advice and useful suggestions on my thesis. I am deeply grateful of his help in the completion of this thesis. High tribute shall be paid to Mr. wang haoran, whose profound knowledge of English triggers my love for this beautiful language and whose earnest attitude tells me how to learn English. I am also deeply indebted to all the other tutors and teachers in Translation Studies for their direct and indirect help to me. Special thanks should go to my friends who have put considerable time and effort into their comments on the draft. Finally, I am indebted to my parents for their continuous support and encouragement.

## References

1. Alpantaki K, Dohm M, Korovessis P. **et al**. Surgical options for osteoporotic vertebral compression fractures complicated with spinal deformity and neurologic deficit. *Injury* 2017 ;Nov 12. pii: S0020-1383(17)30785-4.
2. Kumar S, Kumar S, Arya RK, Kumar A. **et al**. Thoracolumbar Vertebral Injuries with Neurological Deficit Treated with Posterior Decompression, Short Segment Pedicle Screw Fixation, and Interlaminar Fusion. *Asian Spine J* 2017 Dec;11(6):951–958.
3. Li S, Li Z, Hua W, Wang K, Li S, Zhang Y, **et al**. Clinical outcome and surgical strategies for late post-traumatic kyphosis after failed thoracolumbar fracture operation: Case report and literature review. *Medicine (Baltimore)* 2017 Dec;96(49):e8770.
4. Yunrong Z, Jianfeng F, Yunqing Z, **et al**. Medium-term efficacy of short-segment pedicle screw fixation for thoracolumbar fractures. *Chinese Journal of Traumatic Orthopedics* 2015; 17 (12): 1053–7.
5. Tian yun, zhou fangji, hong quan, et al. Treatment of thoracolumbar burst fractures of invaded thoracolumbar vertebral canal with decompression combined with pedicle fixation. *Chinese journal of trauma* 2014;30(10): 978–981.
6. Wang chun, Yang mingxing, weng wei, et al. Effect evaluation of CYL internal fixation for thoracolumbar burst fractures. *Chinese journal of surgery* 2012;50(1): 19–22.

7. Luo peng, xu liangfeng, ni wenfei, et al. Effects and complications of percutaneous pedicle fixation for thoracolumbar fractures. Chinese journal of surgery 2011; 49(2): 130–134.
8. Liu kun, zhao rugang, zhang qiang. Application of computer-aided navigation system in spinal surgery [J]. Chinese medical journal 2015;95(3): 237–240.
9. Peng zhan, Chen liang, gu yong, et al. Surgical efficacy analysis of thoracolumbar burst fractures with incomplete spinal cord injury. Chinese journal of trauma 2015;31(11): 972–976.
10. Yuwei L, Haijiao W, Yisheng W, et al. Treatment of fresh thoracolumbar vertebral fractures with orthodontic overextension combined with intravertebral bone grafting. Chinese Journal of Modern Medicine. 2015;25 (34): 101–4.
11. Dendrinios GK, Halikias JG, Krallis PN, et al. Factors influencing neurological recovery in burst thoracolumbar fractures. Acta Orthop Belg 1995; 61(3):226–234.
12. Verlaan JJ, Diekerhof CH, Buskens E, et al. Surgical treatment of traumatic fractures of the thoracic and lumbar spine: a systematic review of the literature on techniques, complications, and outcome. Spine 2004;29(7):803–814.
13. Watson-Jones R, et al. Fractures and joint injuries [M]. 3rd ed. Edinburgh, NY: E.&S. Livingstone Ltd. 1955, 43: 107–112.
14. Denis F, et al. The three column spine and its significance in the classification of acute thoracolumbar spinal injuries. Spine 1983; 8(8):817–831.
15. Vaccaro AR, Zeiller SC, Hulbert RJ, et al. The thoracolumbar injury severity score: a proposed treatment algorithm. J Spinal Disord Tech 2005;18(3):209–215.
16. Eck JC, Hodges SD, et al. Timing of surgery for thoracolumbar spine trauma. Curr Orthop Pract 2014;25(1): 14–16.
17. Kato S, Murray JC, Kwon BK, Schroeder GD, Vaccaro AR. et al. Does Surgical Intervention or Timing of Surgery Have an Effect on Neurological Recovery in the Setting of a Thoracolumbar Burst Fracture? J Orthop Trauma 2017 Sep;31 Suppl 4:S38-S43.
18. El Sawaf AM, et al. Outcome of Percutaneous Versus Open Posterior Spinal Fixation in 330 Thoracolumbar Fractures. Neurosurgery 2016 Aug;63 Suppl 1:196.
19. Cui H, Guo J, Yang L, Guo Y, et al. Comparison of therapeutic effects of anterior decompression and posterior decompression on thoracolumbar spine fracture complicated with spinal nerve injury. Pak J Med Sci. 2015; Mar-Apr;31(2):346 – 50.
20. Gandhoke GS, Tempel ZJ, Bonfield CM, Madhok R, et al. Technical nuances of the minimally invasive extreme lateral approach to treat thoracolumbar burst fractures. Eur Spine J. 2015 Apr;24 Suppl 3:353 – 60.
21. Sandquist L, Paris A, Fahim DK et al. Definitive single-stage posterior surgical correction of complete traumatic spondyloptosis at the thoracolumbar junction. J Neurosurg Spine. 2015 Jun;22(6):653-7.

## Tables

Due to technical limitations, Tables 1-3 are provided in the Supplementary Files section.

# Figures

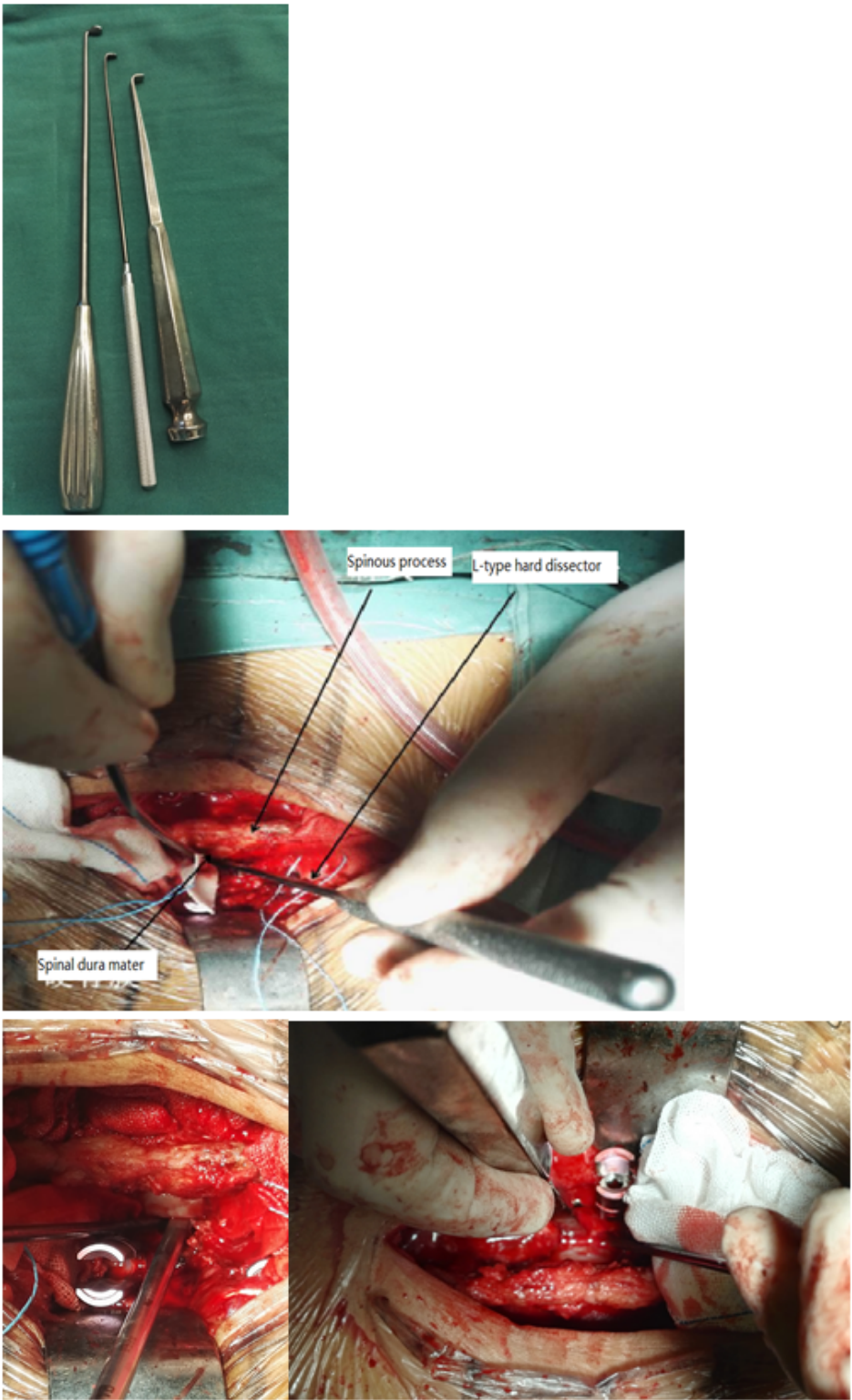
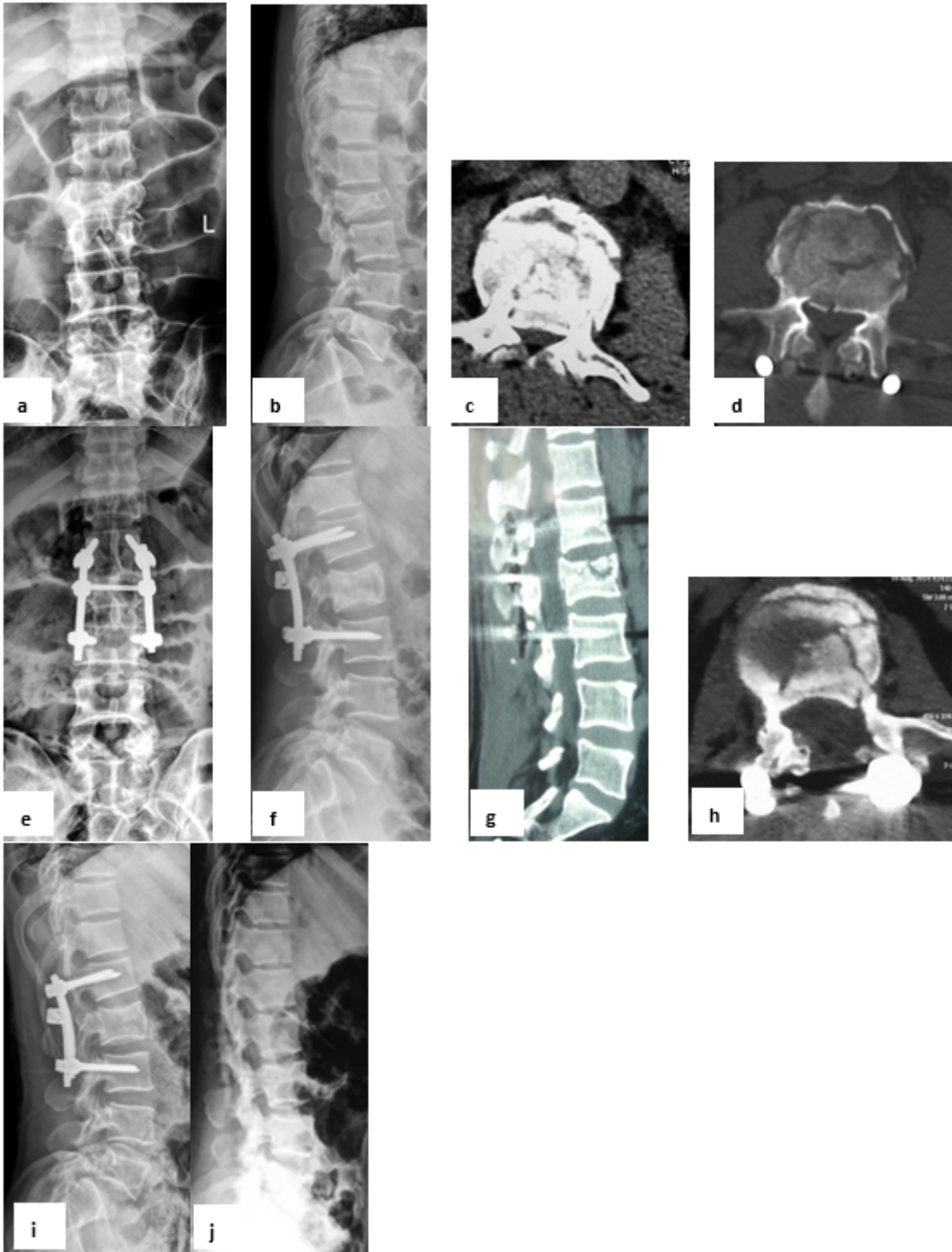


Figure 1

1 L-type hard dissector and L-type small bone knife used in operation; 2. After laminectomy, L-type hard dissector was used to detect the compression of the anterior dura mater and to reposition the fractured piece; 3. 4. L-type small bone knife was placed in front of the dura mater and hammered to reposition the fractured piece.



**Figure 2**

Female, 51years old,Lumbar 2 vertebral fracture a b Preoperative lumbar lateral X-ray: lumbar 2 vertebral body 3 degree compression fracture with kyphosis deformity, anterior compression ratio of injured

vertebrae 48.6%, local Cobb angle of injured vertebrae - 11.2 degree; c Preoperative CT: fracture block entered the spinal canal more than 50%, and the spinal dura mater was compressed. d transverse section CT during operation: after reduction, the fracture block occupied more than 40% of the vertebral canal. e f Third days after operation, the lateral radiograph of lumbar vertebrae: 2 lumbar height recovery and kyphosis completely corrected. g Both spinous processes and lamina are present, and the fracture lumps entering the spinal canal are replaced h CT transverse section 3 days after operation: the left lamina was fenestrated,, the fracture mass entering the spinal canal had been restored, and the dural compression was relieved i Lumbar lateral radiographs taken 12 months after operation j Lumbar lateral films taken 24 months after operation and 12 months after operation.

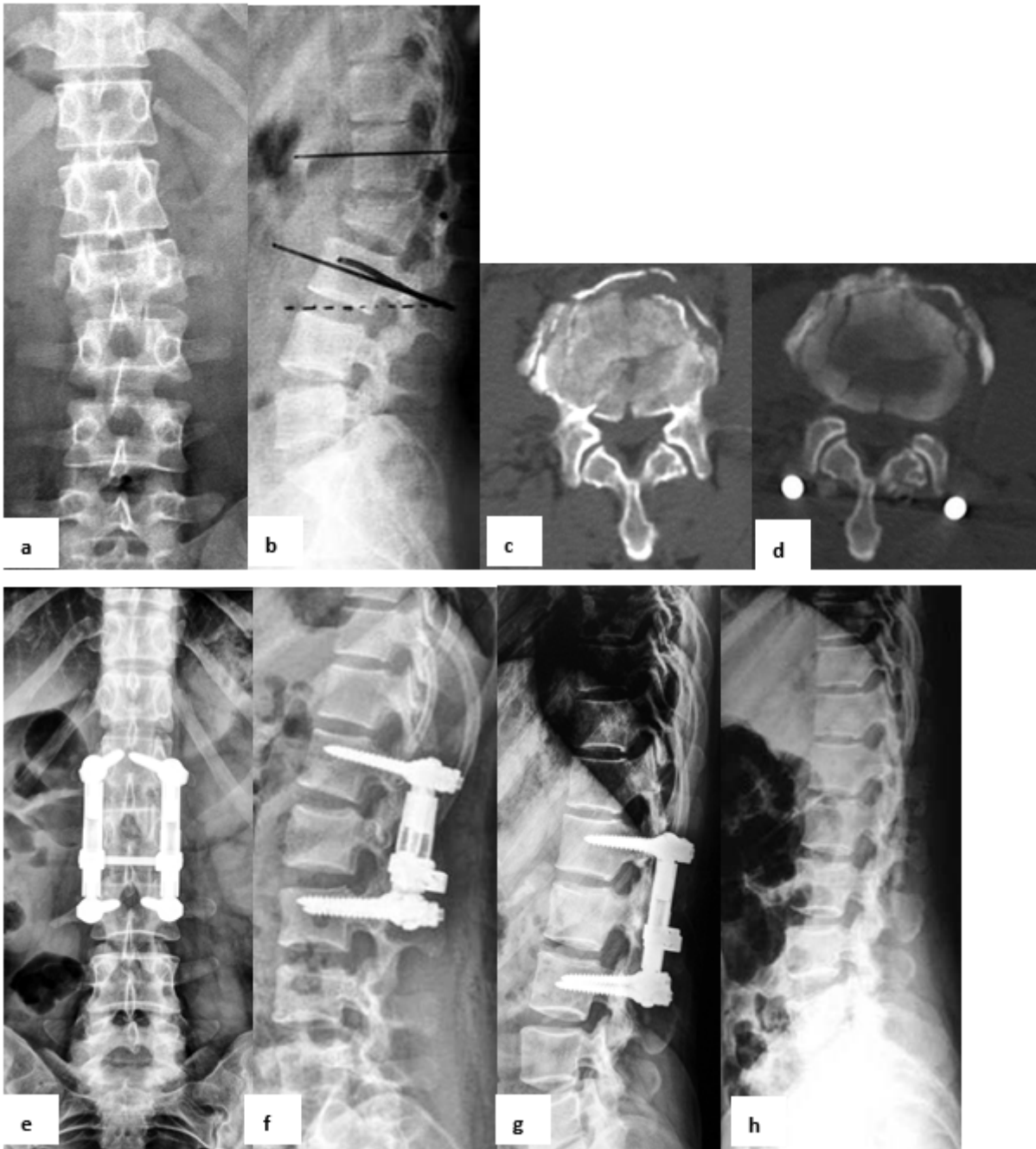


Figure 3

Male, 57 years old, lumbar 2 vertebral fracture. a–b Preoperative lumbar lateral X-ray: lumbar 2 vertebral body 3 degree compression fracture with kyphosis deformity, anterior compression ratio of injured vertebrae 36.7%, local Cobb angle of injured vertebrae -21.3 degree; c Preoperative transverse section CT: The fracture block entered the spinal canal more than 40%, and the spinal dura mater was compressed; d Intraoperative CT: Reduction of a fracture mass entering the spinal canal, decompression of the spinal cord without intravertebral decompression; e–f Anteroposterior and lateral lumbar radiograph on the 3rd day after surgery: the lumbar 2 vertebra height was restored and the kyphosis deformity was completely corrected; g Lumbar lateral radiograph at 12 months postoperatively; h lateral lumbar radiograph 12 months after removal with internal fixation (24 months after surgery)

## Supplementary Files

This is a list of supplementary files associated with this preprint. Click to download.

- [table2.doc](#)