

Comparative study of arthroscopically assisted Tight-Rope technique and clavicular hook plate fixation treatment in acute high grade acromioclavicular joint separations

Hong-bo Li

Jiangxi Provincial People's Hospital

Si Nie

Jiangxi Provincial People's Hospital

Zhi-ming Tang

Jiangxi Provincial People's Hospital

Xin-gen Liao

Jiangxi Provincial People's Hospital

Min Lan (✉ guihai864014948@163.com)

Jiangxi Provincial People's Hospital

Research article

Keywords: Acromioclavicular joint separation, Tight-Rope technique, Clavicular hook plate, Arthroscopic

Posted Date: April 16th, 2020

DOI: <https://doi.org/10.21203/rs.3.rs-21031/v1>

License: © ⓘ This work is licensed under a Creative Commons Attribution 4.0 International License.

[Read Full License](#)

Abstract

Background: Has the arthroscopically assisted reduction of acute acromioclavicular (AC) joint separations with the tight-rope technique advantages over the clavicular hook plate fixation.

Methods: A total of 518 patients with acute high grade AC joint dislocation received ligament reconstruction surgery between February 2015 and June 2017 were included in this study. Of these patients, 28 patients were treated with arthroscopic assisted fixation using Tight-Rope system. In order to compare the treatment results between Tight-Rope technique and clavicular hook plate fixation, each Tight-Rope technique group patients was matched with 3 controls that underwent clavicular hook plate fixation at the same period according to gender, age and diagnosis. Furthermore, the demographics and clinical characteristics were compared between the two groups.

Results: All patients had clinical and radiological results available at 2 year or greater, they was statistically significant improvement in the constant score and VAS score at the end of follow up respectively ($P < 0.001$). Compared with clavicular hook plate group, patients treated with arthroscopic assisted fixation using Tight-Rope system were incurred significant statistically lower skin incision, hospitalization time and estimated blood loss ($p < 0.001$), and the constant score and VAS score at the end of follow up was significant higher in Tight-Rope group ($p < 0.001$).

Conclusions: The Tight-Rope technique is advantageous for treating these patients because it is minimally invasive procedure with low complications and superior clinical outcomes.

Authors' Contribution:

The first and second author (Hong-bo Li and Si Nie) contributed equally to this study and share the first authorship.

Background

Traumatic injury to the acromioclavicular (AC) joint runs up to 9% of all shoulder injuries in human beings [1]. Recent epidemiological studies showed that around 60,000 new cases were diagnosed complete dislocations (Rockwood type's \geq III) every year [2]. Treatment of AC joint separations is remained controversial, according to the severity AC injury, Rockwood classified the AC joint disruption into six grades, Rockwood I and II AC joint injuries should be recommended for conservative treatment [3]. However, nonsurgical treatment for the high grade AC joint separations results in unsatisfactory outcomes. Studies revealed that at least 40% of those patients associated with significant residual symptoms, and the biomechanical consequences of the injury are permanent [4]. Therefore, most of the studies recommended surgery for patients in highly demanded and patients for whom nonsurgical treatment has failed [5].

During the past decade, growing interest has focused on the reconstruction techniques for high grade AC joint dislocations. Long-term AC joint stability requires initial fixation is strong enough to maintain restoration of the entire biological healing process. There are several methods used for fixation like K-wires, hook plate, Tight-Rope system, with no gold standard procedure. Compared with the open surgical techniques, evidence indicates that all-arthroscopic approach is advantageous for treating these patients, because it is minimally invasive procedure with low complications and superior clinical outcomes, and avoids the need of second procedure for implant extraction, also fixation failure or a loss of reduction after plate removal [6, 7].

Recent studies have reported complication rates of 27–52% in arthroscopic assisted AC ligament reconstructions, which limited widespread acceptance of surgical treatment [8]. Boileau et al [9] report the results of all-arthroscopic approach is advantageous (compared with the open approach) for treating these patients with chronic (> 6 weeks) high grade AC joint dislocations. However, arthroscopic assisted fixation using Tight-Rope system techniques for treating acute high grade AC joint dislocations had been examined in a few studies and some results remained controversial. The aim of this study is to compare the short term efficacy of Tight-Rope technique and clavicular hook plate technique in the treatment of acute high grade AC joint dislocation.

Materials And Methods

1. Patient selection

This study was approved by the medical research ethics committee of our hospital. A total of 518 patients with acute high grade AC joint dislocation (< 3 weeks and Rockwood type's III-V) received ligament reconstruction surgery between February 2015 and June 2017 were included in this study. Of these patients, 28 patients were treated with arthroscopic assisted fixation using Tight-Rope system. In order to compare the treatment results between Tight-Rope technique and clavicular hook plate fixation, each Tight-Rope technique group patients was matched with 3 controls that underwent clavicular hook plate fixation at the same period according to gender, age and diagnosis. AC joint dislocation was diagnosed according to clinical evidences and plain film or magnetic resonance imaging (MRI), and operative therapy was indicated depending on the type of AC-joint dislocation according to Rockwood classification (type III, IV, V).

Previous AC joint injuries, Chronic AC joint injuries (> 3 weeks after trauma), Rockwood I and II AC joint injury, AC joint arthritis, and those with fractures of the distal clavicle were excluded from this study. Furthermore, patients presenting with concomitant pathologies that could potentially preclude accurate evaluation were excluded from this study, such as neuromuscular, rheumatic, significant psychiatric or metabolic disorders.

2. Data Collection

The following parameters were recorded: patients' age at diagnosis of AC joint injuries, gender, comorbidities, Rockwood type, treatment for AC joint injuries, duration from injury to the surgery, the incision length, operation time, intraoperative blood loss, hospitalization time, preoperation and postoperative visual analogue scale(VAS) of the affected shoulder, functional recovery of shoulder joint and complications at 2-year follow-up.

3. Surgical Techniques

3.1 Clavicular hook plate techniques

The patient was positioned in beach chair position under general anesthesia. An approximately 8 cm long skin incision was made between the lateral clavicle and the AC joint. After clavicular reduction, the clavicular hook plate was positioned on the lateral clavicle and fixed in the clavicle with screws, and the wound closed in layers. Implant removal was performed 3 months after surgery.

3.2 Tight-rope Techniques

Arthroscopic evaluation and treatment of glenohumeral lesions were performed with the patient in the beach-chair position under general anesthesia. The antero-superior and antero-inferior portals were used to expose the base of the coracoid bone from intraarticular. An approximately 2 cm long skin incision was made on superior surface of the lateral clavicle, and then a guide pin was drilled from the clavicle to the base of coracoid under the special guide system assisted followed by insertion of a Tight-Ropes system, the AC joint was reduced under image intensifier control. The Tight-Rope was tightened, and the wounds were closed in layers.

4. Postoperative Management

The correct reduction and position of the clavicle were confirmed relies on plain film, all patients arm used a sling for 6 weeks, normal use of the arm for most activities of daily living was encouraged, full active motions of the shoulder were allowed after 6 weeks, no heavy strenuous activities was allowed for the first 12 weeks.

5. Outcome Assessment

Outcome was evaluated by 2 orthopedics surgeons, imaging and clinically examinations were performed at directly postoperative, 1 months, 3 months, 6 months, 12 months, and 24 months, and shoulder functional assessment was performed according the constant score and VAS score.

6. Statistical Analysis

Quantitative variables were presented as mean value \pm standard deviation (SD), and the two groups were compared using the Student's t-test. Qualitative variables were expressed as numbers and percentages, and were assessed by the Chi-square test. Statistical significance was set as P value less than 0.05. All analysis was performed by IBM SPSS Version 22 (SPSS Inc. Chicago IL).

Results

1. Patient demographics

The patients' demographics were demonstrated in Table 1. 28 acute AC joint dislocation patients were treated with arthroscopic assisted fixation using Tight-Rope system, and that concomitant glenohumeral lesions were treated during the same procedure (4 cases, 14.3%). There were no significant differences on age, gender, duration from injury to the surgery, injured side, Rockwood classification, comorbidities and mechanism of injury among two groups.

Table 1
Patient demographics in different groups.

Characteristic	TR group(28)	CH group (84)	P
Age (y)	35.9 ± 7.9	36.0 ± 8.3	0.968
Gender: male n (%)	11 (78.6%)	33 (78.6%)	1
Rockwood			0.838
III	2	4	
IV	16	46	
V	10	34	
Mechanism of injury			0.745
Traffic Accident	16	44	
Falling	10	36	
Other	2	4	
Comorbidities			
Diabetes mellitus	3	9	0.535
High blood pressure	3	8	0.457
Smoking status	8	20	0.317
Alcohol consumption status	3	9	0.535
Postoperative complications			
Infection	0	2	0.567
Fixation failure	2	10	0.407
Injured side: right n (%)	15(62.5%)	35(41.6%)	0.292
Injury to surgery(d)	9.1 ± 4.1	9.3 ± 4.3	0.823
TR: Tight-Rope; CH: Clavicular hook plate;			

There were no significant differences on postoperative complications among two groups ($P > 0.05$). There were no intraoperative and postsurgical complications such as fracture or infections were found in Tight-Rope system group, compared to 2.4% in the clavicular hook plate group (superficial infection in 1 patients and deep infection in 1 patient). And one patient in clavicular hook plate group with deep wound infection underwent reoperation. Patients who underwent clavicular hook plate had a higher incidence of partial loss of reduction or fixation failure [10 cases (11.9%) versus 2 cases (7.1%)] than those of Tight-

Rope system group. They all require arthroscopic revision surgery with semitendinosus autograft and Tight-Rope system, with good anatomic and functional outcomes at last review.

2. Functional Results Of The Study Groups

Functional and subjective results of patients in different group are revealed in Table 2. All 112 patients had outcome scores available at 2 year or longer, and based on the analysis, there was statistically significant improvement in the constant score and VAS score at the end of follow up respectively ($P < 0.001$ for both). All the patients were regained their normal range of motion, and very satisfied with the function of their shoulder at last review.

Table 2
Functional Results of the Study Groups

Characteristic	Preoperation	Postoperative	P
TR group			
VAS score	7.0 ± 1.6	1.2 ± 0.6	< 0.001
Constant score	52.6 ± 12.5	89.3 ± 4.2	< 0.001
CH group			
VAS score	6.9 ± 1.6	1.8 ± 1.1	< 0.001
Constant score	52.3 ± 10.3	83.3 ± 8.8	< 0.001
Data are reported as mean ± SD. TR: Tight-Rope; CH: clavicular hook plate.			

3. Comparison Of Surgery-related Factors Between Groups

Table 3 displayed the surgery related factors of patients in different group. Compared with clavicular hook plate group, patients treated with arthroscopic assisted fixation using Tight-Rope system were subject to smaller length of skin incision, estimated blood loss and length of hospital stay ($p < 0.001$). Compared with patients of clavicular hook plate group, those of Tight-Rope technique group demonstrated statistically significant improvement in the constant score and VAS score at the end of follow up respectively. However, There were no statistical significant differences on length of surgery, preoperative constant score and VAS score between the two groups ($P > 0.05$, respectively).

Table 3
Surgery-related factors by group

Characteristic	TR group(28)	CH group (84)	P
Length of surgery (h)	63.9 ± 10.1	66.1 ± 9.2	0.289
Estimated blood loss (ml)	57.1 ± 8.25	93.1 ± 22.1	< 0.001
Length of skin incision (cm)	3.9 ± 0.83	8.3 ± 1.1	< 0.001
Preoperative VAS score	7.0 ± 1.6	6.9 ± 1.6	0.780
Preoperative constant score	52.6 ± 12.5	52.3 ± 10.3	0.871
Postoperative VAS score	1.2 ± 0.6	1.8 ± 1.1	0.004
Postoperative constant score	89.3 ± 4.2	83.3 ± 8.8	0.001
Length of postoperative hospital stay (d)	3.7 ± 0.7	6.2 ± 1.0	< 0.001
Data are reported as mean ± SD. TR: Tight-Rope; CH: Clavicular hook plate;			

Discussion

The mechanism underlying most AC joint separations is caused by traffic accidents and downfall, traumatic injury to the AC joint runs up to 9% of all shoulder injuries in human beings [10]. Treatment of AC joint separations is remained controversial, for the high grade AC dislocations, some studies have recommended conservative treatment, however, many studies showed those patients may later report unsatisfactory outcomes, at least 40% of conservative treatment patients associated with significant residual symptoms, these patients may end up seeking a surgical treatment after many weeks or months of persistent shoulder symptoms [11, 12]. Chronic AC joint instability may be associated with persistently painful and weak shoulders, most of the studies recommended surgery for whom nonsurgical treatment has failed after many weeks or months of persistent shoulder symptoms[13]. Long-term stability requires that the initial fixation is strong enough to maintain reduction throughout the biological healing process. Surgical techniques and implants are multifaceted, various methods of fixation like K-wires, clavicular hook plate, Tight-Rope technique, with no gold standard procedure.

Many studies recommend using tendon grafts or suture-button configurations for the treatment of high grade AC dislocations injuries, because it had significant improved clinical results compared with nonsurgical treatment [14]. However, recent studies confirmed the incidence of complication after reconstruction of the AC ligaments was reported to be ranged from 27–52%, and 20% of the patients were identified with clavicle fracture complication[15].Tendon grafts may fail due to stretch during remodeling, and the failure of suture-button configurations associated with knot slippage or button migration. Cook et al [16] demonstrated an early failure rates as great as 29% with AC ligament reconstruction. The 2 buttons are now connected with a tape for Tight-Rope system can be self-propelled

adjust reconstruction length, which has been shown to resist higher loads [11]. All the patients had outcome scores available at 2 year or greater, the present study showed successful short term clinical outcomes for the patients who treated with arthroscopic assisted fixation using Tight-Rope system, with statistically significant difference between the preoperative and postoperative constant score and VAS scores, the most patients were regained their normal range of motion, and very satisfied with function of their shoulder at last review.

During the past decade, growing interest has focused on the reconstruction techniques for high-grade AC joint dislocations, compared with the open surgical techniques, evidence indicates that all-arthroscopic approach is advantageous for treating these patients because it is minimally invasive procedure allows successful reduced the risk of infection and big scar [17, 18]. Arthroscopic technique using the Tight-Rope system is minimally invasive procedure avoids the need of second procedure for implant extraction, and fixation failure or a loss of reduction after plate removal, this result in faster recovery and better shoulder function results [19]. In line with previous studies, compared with clavicular hook plate group, patients treated with arthroscopic assisted fixation using Tight-Rope system was subject to smaller length of skin incision, estimated blood loss and decreased length of hospital stay. Patients who underwent clavicular hook plate had a higher incidence of partial loss of reduction or fixation failure and infection than those of Tight-Rope system group. Furthermore, our study showed an important advantage of the arthroscopic approach for treating these patients is simultaneously achieving diagnosis and treatment of the frequently (14.3%) associated glenohumeral joint lesions.

Many studies recommend using double Tight-Rope technique for the treatment of high grade AC dislocations [20, 21]. However, Patzer et al [22] analyzed the clinical and radiological results of arthroscopically assisted Tight-Rope technique for high grade AC dislocations injuries, it was found that there was no significantly different between single and double Tight-Rope technique group. Furthermore, previous study confirmed the constant score of shoulder after Tight-Rope technique was reported to be ranged from 86.4 to 96.3 [23, 24]. Referring to our study, the mean postoperative constant score was 89.3 ± 4.2 in Tight-Rope group, and 83.3 ± 8.8 in clavicular hook plate group, the mean post-operative VAS scale was 1.2 ± 0.6 in Tight-Rope group, and 1.8 ± 1.1 in clavicular hook plate group. In a retrospective data investigated 69 patients, Jensen et al [10] confirmed that the arthroscopically assisted reduction of acute AC joint separations with the Tight-Rope technique advantages over the clavicular hook plate fixation. In line with previous studies, compared with patients of clavicular hook plate group, those patients of Tight-Rope group demonstrated statistically significant improvement in the constant score and VAS score at the end of follow up respectively.

Several limitations were also detected in this study. First of all, our current study is a single-center study, and a relatively small number of patients were treated with arthroscopic assisted fixation using Tight-Rope system may introduce bias into the results, further prospective study with an increased sample size is required to definitely the answer of question whether the arthroscopically assisted Tight-Rope technique is superior to the open procedure or not. Second, our study is not fully showed what the outcome results would be while performing AC reconstruction alone without performing any other

glenohumeral joint lesions surgery, the difference in outcomes could be related to the management of other pathology in 14.3% of patients. Third, we just observed the constant score and VAS score of shoulder within 2 year after injury in patients with AC reconstruction, therefore, a prospective study with long-term follow-up is necessary.

The present study showed successful short term clinical outcomes for the patients who treated with arthroscopic assisted fixation using Tight-Rope technique, the most patients were regained their normal range of motion, and very satisfied with the function of their shoulder at last review. Compared with the clavicular hook plate technique, Tight Rope technique is advantageous for treating these patients because it is minimally invasive procedure with low morbidities and superior clinical outcom

Declarations

Conflicts of Interest:

No benefits in any form have been or will be received from any commercial party related directly and indirectly to the subject of this manuscript.

Ethical approval

All procedures performed in studies involving human participants were in accordance with the ethical standards of the institutional and/or national research committee and with the 1964 Helsinki Declaration and its later amendments or comparable ethical standards. A waiver of informed consent was requested, and the approval was obtained from the Jiangxi Provincial People's Hospital Affiliated to Nanchang University.

Authors' contribution

The authors made the following contributions: Lan min made the conception for this research. Zhi-ming Tang and Xin-gen Liao analyzed the data, Lan min drafted the article. Hong-bo Li and Si Nie reviewed/edited the manuscript. All the authors critically revised the article for important intellectual content. The author(s) read and approved the final manuscript.

Funding

No funding was obtained for this study.

Availability of data and materials

The datasets used and/or analysed during the current study are available from the corresponding author on reasonable request.

Consent for publication

Consent for publication obtained from participants.

References

1. Bigoni M, Piatti M, Zanchi N, Gorla M, Gaddi D, Rigamonti L, et al. Clinical effectiveness of surgical treatment with polyester tapes and temporary K-wires on complete acromioclavicular dislocation. *Eur J Orthop Surg Traumatol*. 2019;29(3):567–73.
2. Chillemi C, Franceschini V, Dei GL, Alibardi A, Salate SF, Ramos Alday LJ, et al. Epidemiology of isolated acromioclavicular joint dislocation. *Emerg Med Int*,2013,(2013-1-28).
3. Rolf O, Hann VWA, Ewers A, Boehm TD, Gohlke F. Acromioclavicular dislocation Rockwood III-V: results of early versus delayed surgical treatment. *Arch Orthop Trauma Surg*. 2008;128(10):1153–7.
4. Schlegel TF, Burks RT, Marcus RL, Dunn HK. A prospective evaluation of untreated acute grade III acromioclavicular separations. *Am J Sport Med*. 2001;29(6):699.
5. Tauber M. Management of acute acromioclavicular joint dislocations: current concepts. *Arch Orthop Trauma Surg*. 2013;133(7):985–95.
6. Flinkkilä TE, Ihanainen E. Results of Arthroscopy-Assisted TightRope Repair of Acromioclavicular Dislocations. *Shoulder Elbow*. 2013;6(1):18.
7. Elmaraghy AW, Devereaux MW, Ravichandiran K, Agur AM. Subacromial morphometric assessment of the clavicle hook plate. *Injury*. 2010;41(6):613–9.
8. Struhl S, Wolfson T. Continuous Loop Double Endobutton Reconstruction for AC Joint Dislocation. *Am J Sport Med*. 2014;30(6):e9–10.
9. Boileau P, Gastaud O, Wilson A, Trojani C, Bronsard N. All-Arthroscopic Reconstruction of Severe Chronic Acromioclavicular Joint Dislocations. *Arthroscopy: the journal of arthroscopic related surgery : official publication of the Arthroscopy Association of North America the International Arthroscopy Association*. 2019;35:1324–35.
10. Gunnar J, Jan Christoph K, Laura Esther A, Helmut L, Christine V. Has the arthroscopically assisted reduction of acute AC joint separations with the double tight-rope technique advantages over the clavicular hook plate fixation? *Knee Surg Sports Traumatol Arthrosc*. 2014;22(2):422.
11. Hann C, Kraus N, Minkus M, Maziak N, Scheibel M. Combined arthroscopically assisted coraco- and acromioclavicular stabilization of acute high-grade acromioclavicular joint separations. *Knee Surg Sport Tr a*. 2017;33(2):1–9.
12. Nissen C, Chatterjee A. Type III acromioclavicular separation: results of a recent survey on its management. *Am J Orthop*. 2007;36(2):89.
13. Tauber M, Gordon K, Koller H, Fox M, Resch H. Semitendinosus tendon graft versus a modified Weaver-Dunn procedure for acromioclavicular joint reconstruction in chronic cases: a prospective comparative study. *Am J Sport Med*. 2009;37(1):181–90.
14. Martetschläger F, Horan MP, Warth RJ, Millett PJ. Complications after anatomic fixation and reconstruction of the coracoclavicular ligaments. *Am J Sport Med*. 2013;41(12):2896–903.
15. Schliemann B, Roßlenbroich SB, Schneider KN, Theisen C, Petersen W, Raschke MJ, et al. Why does minimally invasive coracoclavicular ligament reconstruction using a flip button repair technique fail? An analysis of risk factors and complications. *Knee Surg Sports Traumatol Arthrosc*. 2013;23(5):1419–25.

16. Cook JB, Shaha JS, Rowles DJ, Bottoni CR, Shaha SH, Tokish JM. Early failures with single clavicular transosseous coracoclavicular ligament reconstruction. *J Shoulder Elbow Surg.* 2012;21(12):1746–52.
17. Liu HH, Chou YJ, Chen CH, Chia WT, Wong CY. Surgical treatment of acute acromioclavicular joint injuries using a modified Weaver-Dunn procedure and clavicular hook plate. *Orthopedics.* 2010;33(8):553.
18. Esenyel CZ, Oztürk K, Bülbül M, Ayanoğlu S, Ceylan HH. Coracoclavicular ligament repair and screw fixation in acromioclavicular dislocations. *Acta Orthop Traumato.* 2010;44(3):194.
19. Pauly S, Gerhardt C, Haas NP, Scheibel M. Prevalence of concomitant intraarticular lesions in patients treated operatively for high-grade acromioclavicular joint separations. *Knee Surg Sports Traumatol Arthrosc.* 2009;17(5):513–7.
20. Rosslenbroich SB, Benedikt S, Schneider KN, Metzlauff SL, Koesters CA, Andre W, et al. Minimally Invasive Coracoclavicular Ligament Reconstruction With a Flip-Button Technique (MINAR): Clinical and Radiological Midterm Results. *Am J Sport Med.* 2015;43(7):1751–7.
21. Vascellari A, Schiavetti S, Battistella G, Rebuzzi E, Coletti N. Clinical and radiological results after coracoclavicular ligament reconstruction for type III acromioclavicular joint dislocation using three different techniques. A retrospective study. *Joints.* 2015;03(02):54–61.
22. Patzer T, Clauss C, Kühne CA, Ziring E, Efe T, Ruchholtz S, et al. Arthroscopically assisted reduction of acute acromioclavicular joint separations: comparison of clinical and radiological results of single versus double TightRope? technique. *Der Unfallchirurg.* 2013;116(5):442–50.
23. Chaudhary D, Jain V, Joshi D, Jain JK, Goyal A, Mehta N. Arthroscopic fixation for acute acromioclavicular joint disruption using the TightRope device. *J Orthop Surg-Hong K.* 2015;23(3):309.
24. Sallakh SAE. Evaluation of arthroscopic stabilization of acute acromioclavicular joint dislocation using the TightRope system. *Orthopedics.* 2012;35(1):18–22.
25. Song SJ, Bae DK, Kim KI, Park CH. Long-term survival is similar between closed-wedge high tibial osteotomy and unicompartmental knee arthroplasty in patients with similar demographics. *Knee Surg Sports Traumatol Arthrosc.* 2019(1):1–10.

Figures

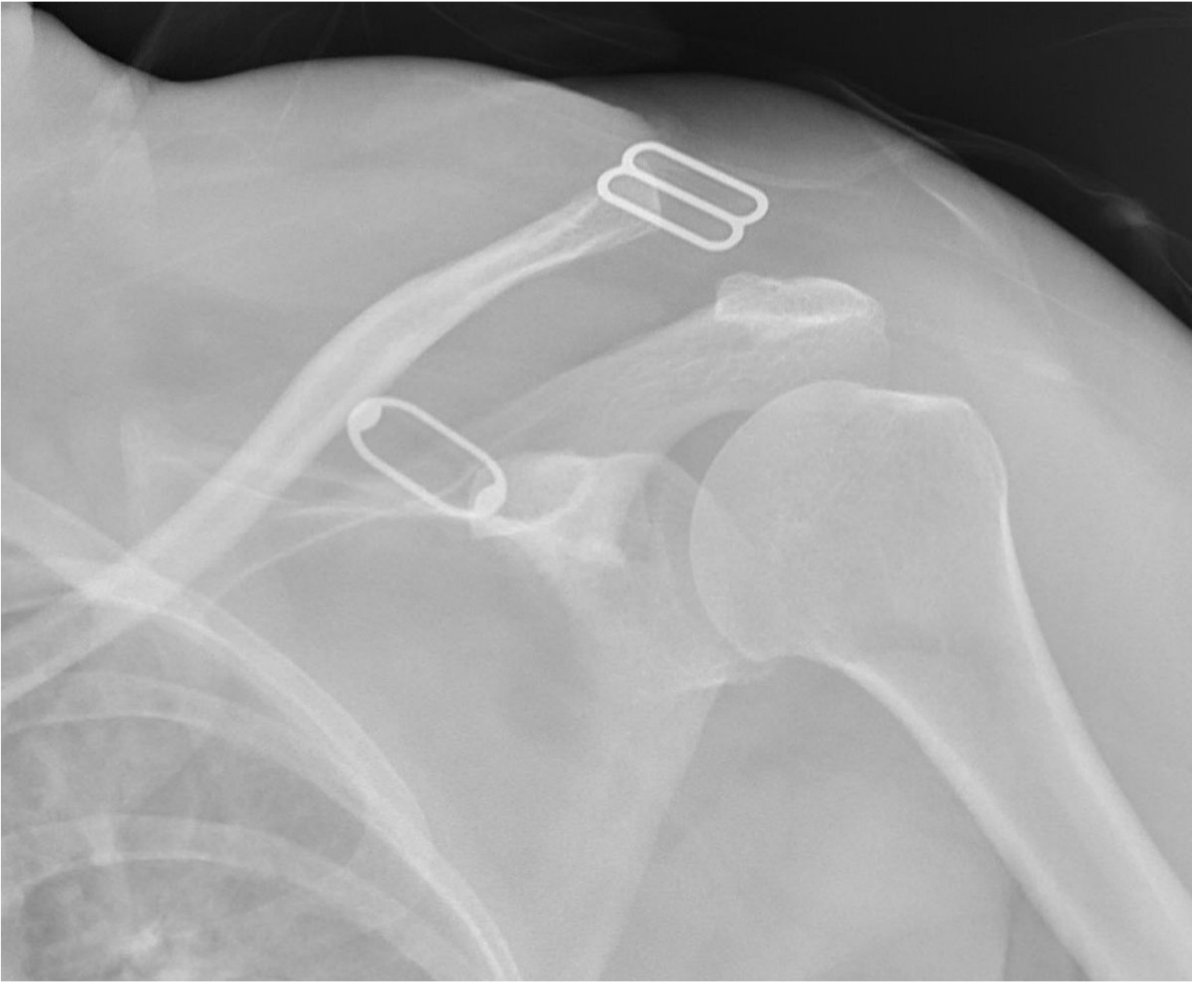


Figure 1

A 48 years female with a painful and weak shoulder after the traffic accident trauma, (A) preoperative radiograph showing a high grade (Rockwood type V) AC joint dislocation, (B.C) postoperative radiograph after treated with arthroscopic assisted fixation using Tight Rope technique (at 2-year follow-up).

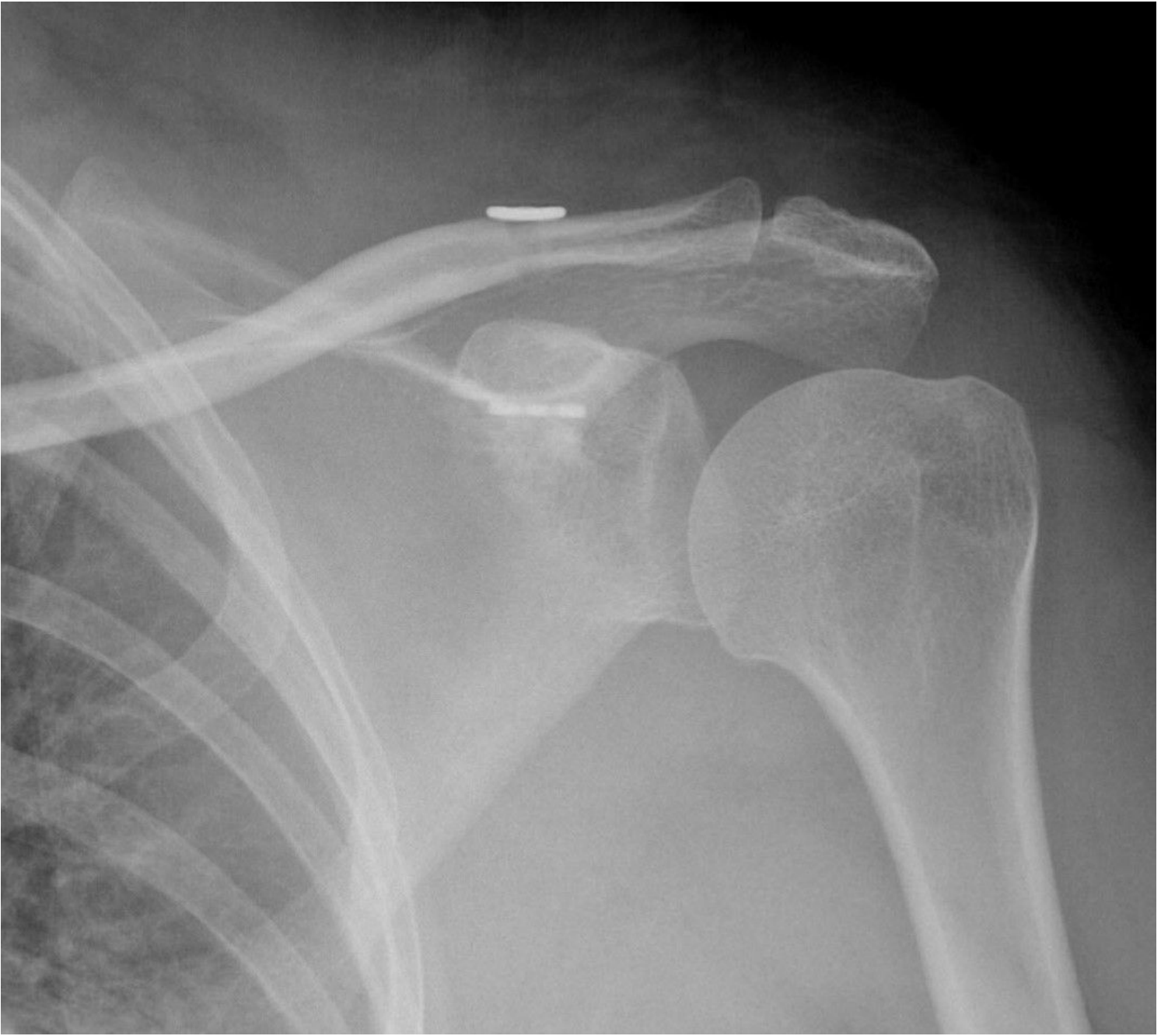


Figure 2

A 48 years female with a painful and weak shoulder after the traffic accident trauma, (A) preoperative radiograph showing a high grade (Rockwood type V) AC joint dislocation, (B.C) postoperative radiograph after treated with arthroscopic assisted fixation using Tight Rope technique (at 2-year follow-up).

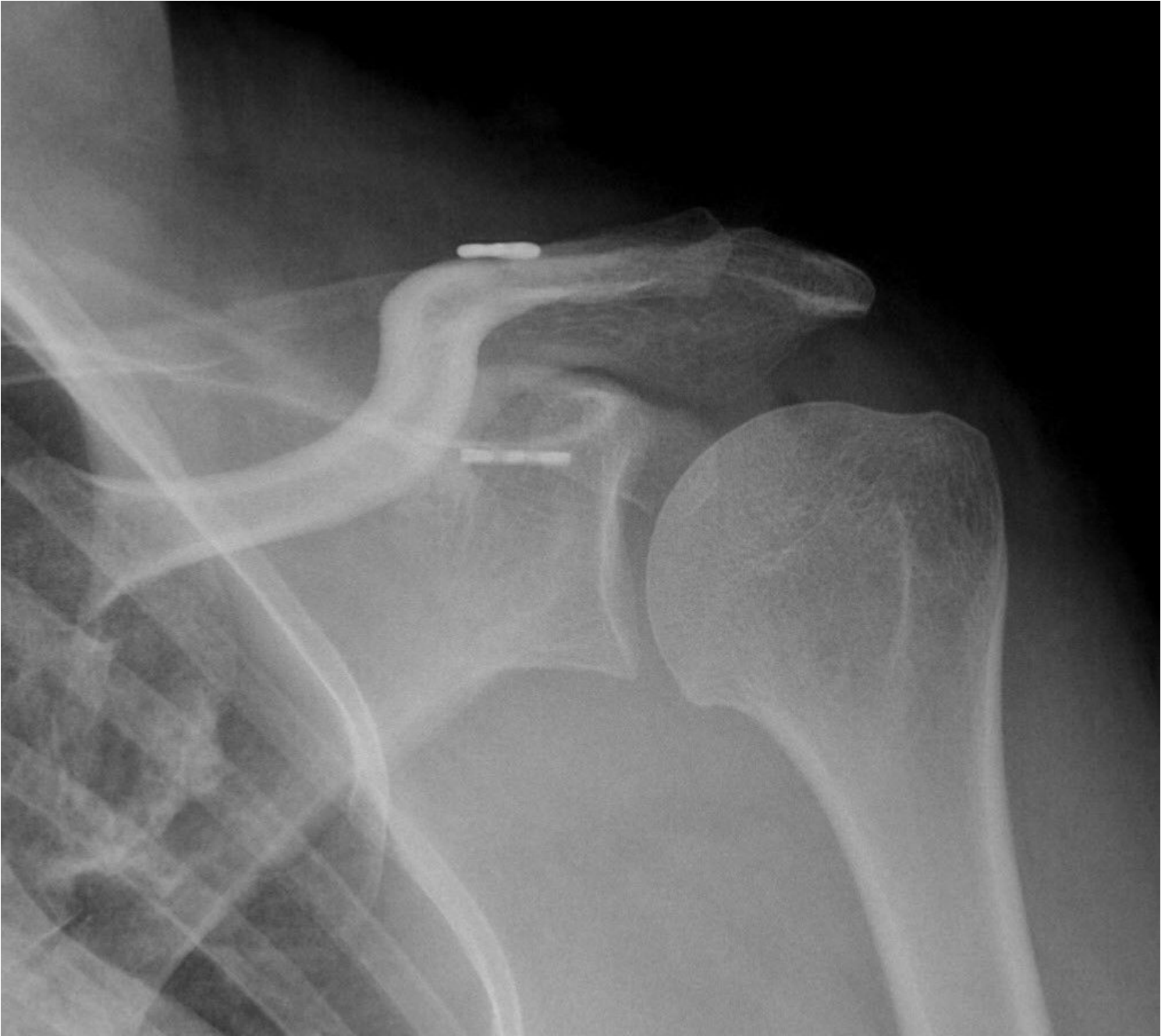

Figure 3

A 48 years female with a painful and weak shoulder after the traffic accident trauma, (A) preoperative radiograph showing a high grade (Rockwood type V) AC joint dislocation, (B.C) postoperative radiograph after treated with arthroscopic assisted fixation using Tight Rope technique (at 2-year follow-up).

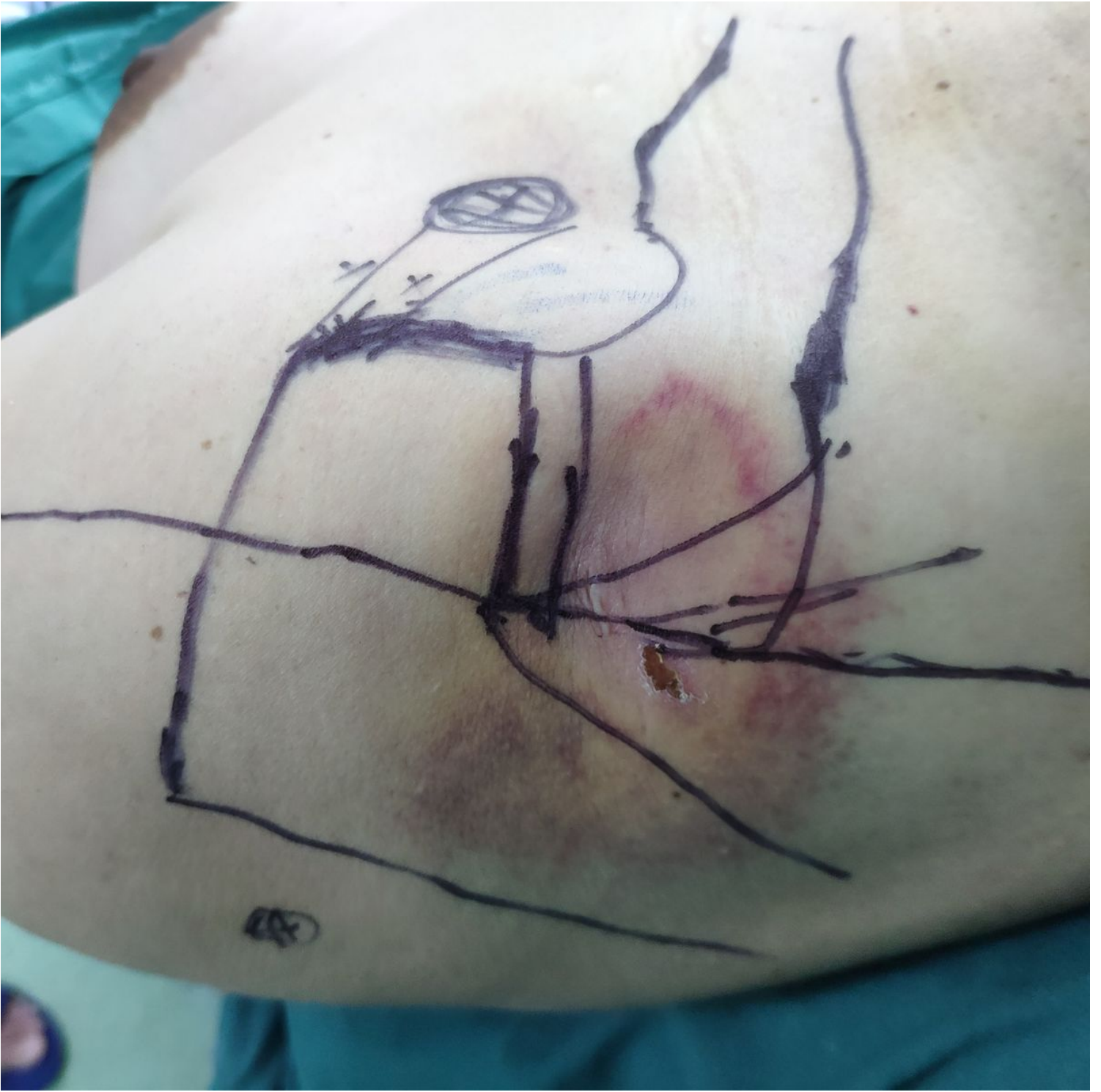

Figure 4

(A) Preoperative picture of the shoulder showing skin landmarks and portals.

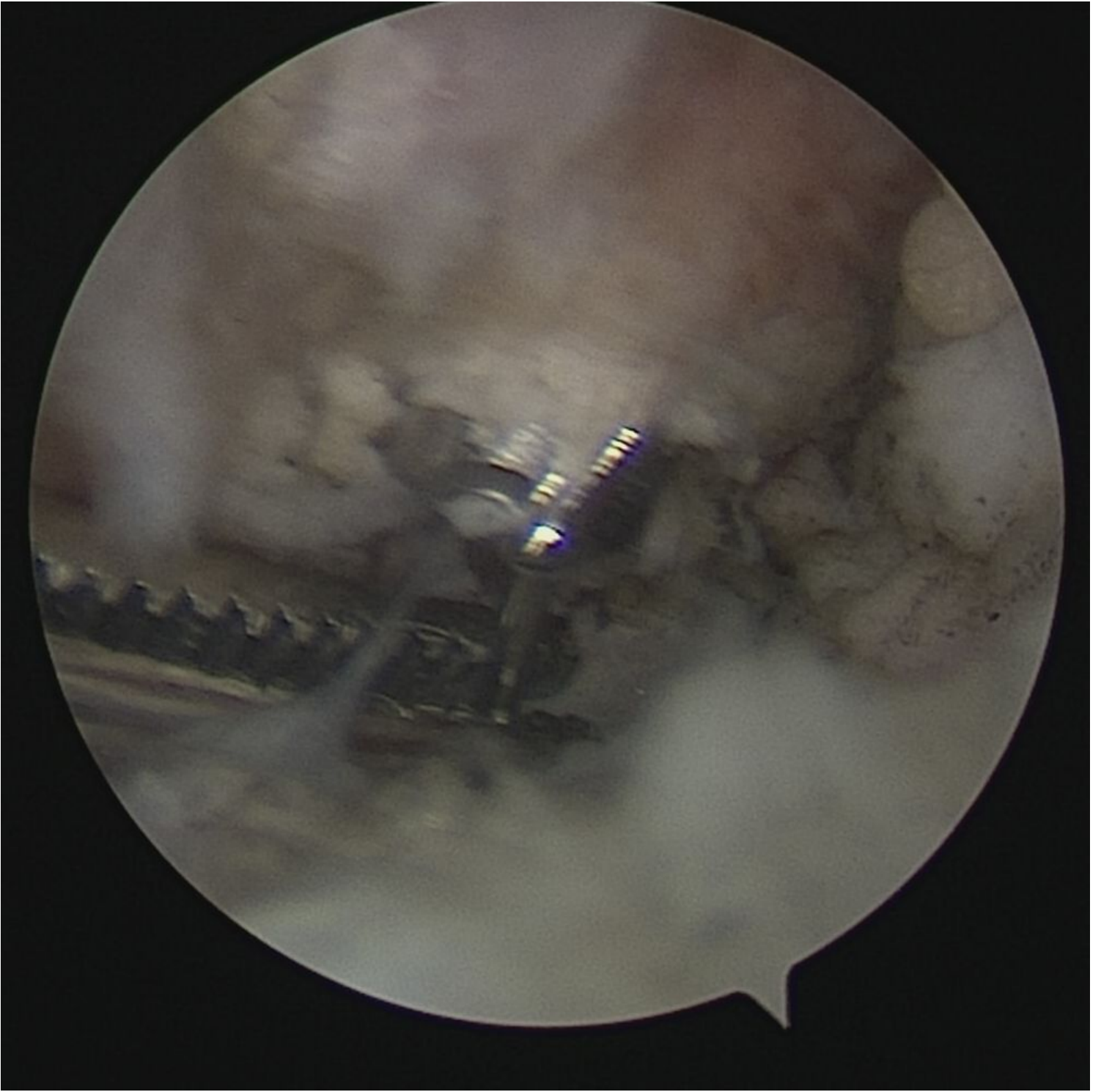


Figure 5

(B) Intra-operative image showing the cannulated drill came out of the under surface of the coracoid.

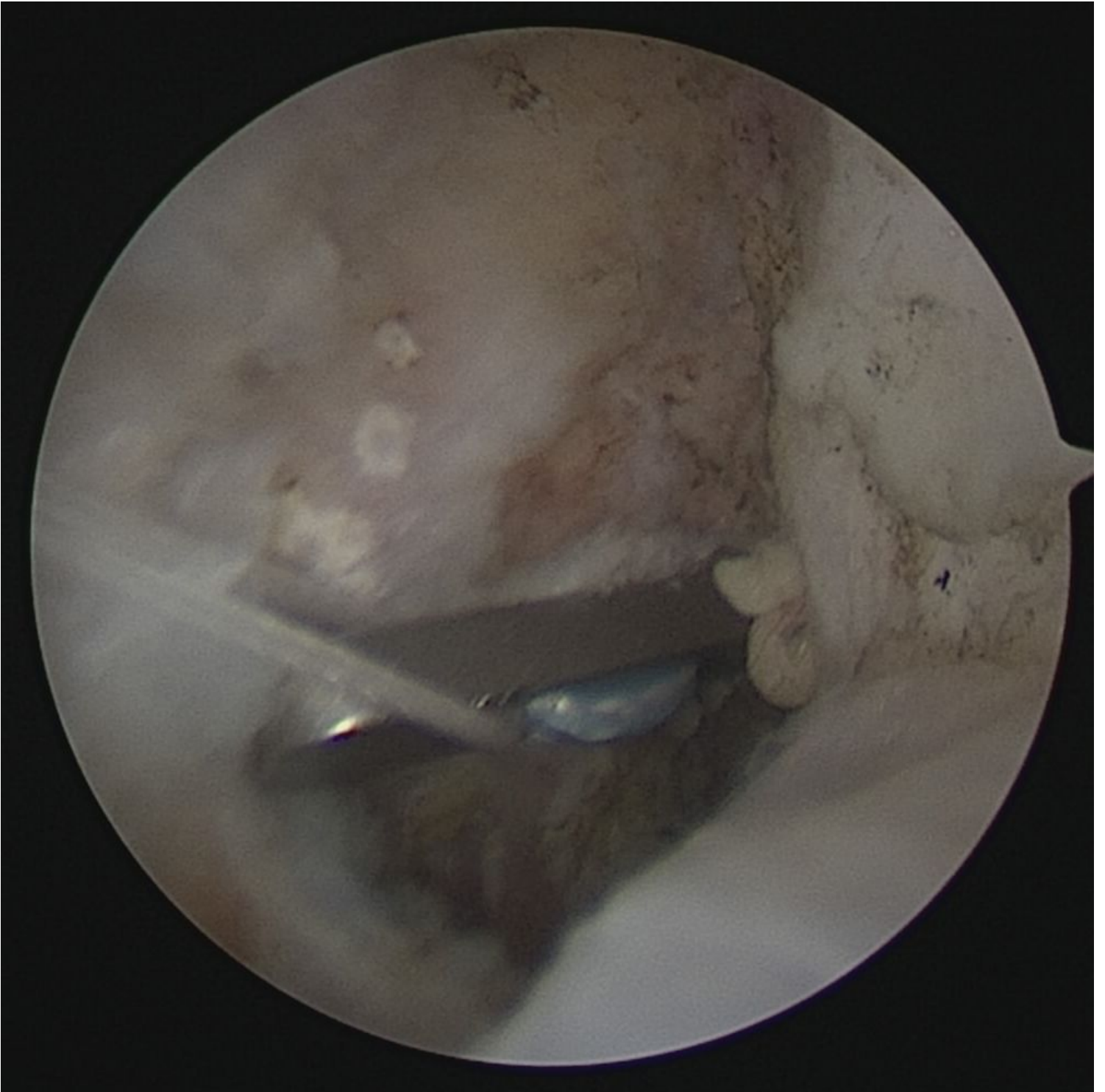

Figure 6

(C) The button of the Tight-Rope flipped on the inferior surface of the coracoid process.