

# Genetic investigation of 211 Chinese families expands the mutational and phenotypical spectrum in hereditary retinopathy genes through targeted sequencing technology

**Zhouxian Bai**

The First Affiliated Hospital of Zhengzhou University <https://orcid.org/0000-0001-7071-666X>

**Yanchuan Xie**

First Affiliated Hospital of Henan University of Science and technology

**Lina Liu**

First Affiliated Hospital of Zhengzhou University

**Jingzhi Shao**

Southern Medical University Nanfang Hospital

**Yuying Liu**

First Affiliated Hospital of Zhengzhou University

**Xiangdong Kong** (✉ [kongxd@263.net](mailto:kongxd@263.net))

The First Affiliated Hospital of Zhengzhou University <https://orcid.org/0000-0003-0030-7638>

---

## Research article

**Keywords:** hereditary retinopathy, novel mutations, targeted sequencing, genetic testing

**Posted Date:** January 7th, 2021

**DOI:** <https://doi.org/10.21203/rs.3.rs-20958/v3>

**License:** © ⓘ This work is licensed under a Creative Commons Attribution 4.0 International License. [Read Full License](#)

---

**Version of Record:** A version of this preprint was published at BMC Medical Genomics on March 29th, 2021. See the published version at <https://doi.org/10.1186/s12920-021-00935-w>.

## Abstract

**Background:** Hereditary retinopathy is a significant cause of blindness worldwide. Despite the discovery of many mutations in various retinopathies, a large part of patients remain undiagnosed genetically. Targeted next generation sequencing of the human genome is a suitable approach for retinopathy molecular diagnosis.

**Methods:** We described a cohort of 211 families from central China with various forms of retinopathy, 95 families of which were investigated using NGS multi-gene panel sequencing as well as the other 116 patients were LHON suspected tested by Sanger sequencing. We validated the candidate variants by PCR-based Sanger sequencing. We have made comprehensive analysis of the cases through sequencing data and ophthalmologic examination information.

**Results:** The potentially causal mutation was identified in majority of the families with retinopathy (57.9% of 95 families) and Leber hereditary optic neuropathy (LHON) (21.6% of 116 families). The identified mutations (68 mutations, 37 of which are novel) of the 95 families spanned 31 known disease genes, about half have not been reported relation to hereditary retinopathy. The NGS panel solution provides 45.3% potential diagnostic rate of the retinopathy families and another 12.6% families detect candidate gene mutations with undefined pathogenicity in this study.

**Conclusion:** Our study showed novel mutations and phenotypic aspects of retinopathy, and demonstrated genetic and clinical heterogeneity of the conditions. Our results illustrated the significance of molecular genetic testing for patients with hereditary retinopathy.

## Background

Hereditary retinopathy is one of the most common genetic blinding retinal diseases. Retinopathy is highly heterogeneous in hereditary and clinical phenotypes. The main inheritance patterns include autosomal dominant, autosomal recessive inheritance and X-linked inheritance. The hereditary retinopathy mainly includes retinitis pigmentosa, macular degeneration, Leber's hereditary optic neuropathy (retina inconvenienced early stage) and retinal dysplasia involved in this study. Retinitis pigmentosa (RP) is a group of hereditary blinding fundus diseases caused by abnormalities in photoreceptors of the retina[1]. Its main clinical features are progressive visual field defect, night blindness, bone spicule like pigmentation and abnormal electroretinogram. Leber hereditary optic neuropathy (LHON) is a mitochondrial hereditary eye disease that involves with retinal ganglion cells resulting eventually in degeneration and atrophy of optic nerve[2]. With the popularization and clinical application of gene sequencing technology, more and more disease-causing genes and its mutations have been discovered, and these genes are mainly expressed in photoreceptor cells and retinal pigment epithelial cells[3]. A good understanding of retinopathy genes not only provides theoretical basis for diagnosis and genetic counseling, but also supports guidance for gene therapy of the diseases[4-6].

The study of retinopathy genetics is important to increase our understanding of the molecular aspects of eye development, disease and treatment. In this research, we have chosen the family based strategy so as to determine the exact inheritance pattern and recurrence risk in offspring. Through family based strategy, we can also learn whether phenotype and genotype are co-segregated in one family, which helps to estimate the pathogenicity of candidate mutations. More than half of the patients were LHON suspected, they directly adopted Sanger sequencing of mitochondrial DNA, and the rest adopted next generation sequencing (NGS). Despite the discovery of pathogenic mutations and genes of various types of retinopathy (such as RP), there are many unknowns waiting to be found. Hence, targeted NGS of the human genome in related Chinese families and patients expanded the mutational spectrum and deepened our understanding of the mechanism of disease. This investigation also increased the understanding of heterogeneity of clinical manifestations of diseases and enriched the phenotypic spectrum of diseases.

## Methods

### Subject collection

There were 211 Chinese families with retinopathy from central China recruited for this study, included 116 patients from different families with chief complaints of monocular or binocular fundus optic atrophy (LHON suspected) and 95 families with chief complaints of other retinopathy. The 116 patients (Part A) receiving LHON Sanger sequencing with fundus optic atrophy, and the 95 patients (Part B) receiving targeted NGS with other retinopathy have been examined and diagnosed by ophthalmology department. Specific clinical manifestations of patients are shown in the results part of the paper. Sample was obtained with written informed consent. The retinopathy patients came for medical and genetic consultations in our hospital during 2017 and 2019, 4 mL peripheral blood samples were collected from the persons in the 211 retinopathy families respectively. The clinical materials of the patients included this study were collected when they got medical service at clinic.

The subjects of Part A were performed Sanger sequencing test that included specific pathogenic sites of mitochondrial DNA, and the mother of subject with pathogenic mitochondrial variant had done the same test to explore source of the variation. The proband of one family was screened by targeted second generation sequencing in the subjects of Part B. Then, the parents of proband and more other members of the family were tested by Sanger sequencing to detect and verify the carrying status of candidate mutation, which are screened out through targeted NGS.

### Targeted Next Generation Sequencing and Sanger Sequencing

Genomic DNA was extracted from EDTA-treated blood samples using Blood DNA Midi Kit D3494 (Omega Bio-tek, USA) through nucleic acid automatic extraction equipment (Eppendorf epMotion 5075m, Germany). Amniotic fluid cell DNA was extracted and cleaned using QIAamp Blood DNA Midi Kit (250, Germany) and Genomic DNA Clean & Concentrator (Zymo Research, USA).

A customized panel (MyGenostics, Beijing China) captured 463 known genes (**Table S1**) related with retinal disease was designed to detect the genetic cause of the congenital retinopathy families. The panel sequencing was conducted on the Illumina NextSeq500 system in our clinical lab. The average sequencing

depth of the target panel sequence was more than 100× and the coverage was 98%. Version GRCh37 is the human reference genome used for short reads mapping. PCR-based Sanger sequencing was used to validate the variants which chosen as disease causing mutations through NGS. The carrying situation of the novel mutations of their family members was also tested by Sanger sequencing. The PCR primers were designed by GeneTool software. Capillary electrophoresis apparatus (ABI 3130xl, USA) and dGTP BigDye® Terminator sequencing kit (ABI, USA) were used for Sanger sequencing.

The patients with chief complaints of LHON were tested through PCR-based Sanger sequencing, which just included 3 common mutant sites of mitochondrial DNA such as *MTND1* mt.3460, *MTND4* mt.11778 and *MTND6* mt.14484, and 10 rare mutant sites of mitochondrial DNA such as *MTND1* (mt.3376, mt.3635, mt.3700, mt.3733), *MTND6* (mt.14482, mt.14495, mt.14502, mt.14568, mt.14498, mt.14325). The pathogenicity of these mitochondrial mutations is known. The PCR primers were designed by GeneTool software (refer to **Table S2**).

### Population control

Frequency of the detected mutations in the population was investigated by querying the Genome Aggregation Database (gnomAD, <http://gnomad-old.broadinstitute.org/>) because of its wider large-scale sequencing data resource. We chose the frequencies of mutation sites in all populations and in East Asian populations as controls.

### Functional prediction analysis

Retrieve the candidate pathogenic mutation sites in the public databases which included dbSNP, 1000G and ExAC, and check them whether been recorded. We also plan to retrieve the candidate sites in HGMD (The Human Gene Mutation Database at the Institute of Medical Genetics in Cardiff) professional to ensure their pathogenicity. PhyloP and PhastCons software were used to analyse the conservation of corresponding amino acid sequence of the missense mutated locus. Pathogenic analysis was conducted by SIFT, PolyPhen\_2 and Mutation t@sting online tools. We also analyzed the second structure, disorder region and mutation effect of the missense mutated site by Predictprotein online tool. Three dimensional structure construction of target protein sequence was using Swiss-Model protein model structure simulation software. The pathogenicity of the candidate mutations were graded and judged according to the 2015 edition of ACMG standard and guidelines[7].

## Results

The genome variation results of different patients and their families were classified and summarized by pathogenic genes.

### Mutation distribution in suspected LHON patients

In two and one half years, 116 suspected patients with optic neuropathy or LHON were examined to help diagnose 25 cases of LHON (seen in **Figure 1**) among them. The diagnostic rate for LHON is 21.6% in our optic atrophy group using mtDNA Sanger sequencing panel (*OPA1*, *WFS1*, etc not included). The ratio of male to female in patients with LHON is 4/1 in our investigation. The average age of the patients diagnosed as LHON was 19 years old, their age ranged from 6 to 36 years old. The three common mutant sites of mt.3460, mt.11778 and mt.14484 are main (96%) causes of LHON, and *MTND4* m.11778G>A is the most common pathogenic mutation among them, then *MTND6* m.14484T>C and *MTND1* m.3460G>A. Just one rare mutant that *MTND6* m.14502T>C was found in these Chinese patients from central China. Several LHON patients are with incomplete mitochondrial mutation or two mutations.

### Pathogenic mutations of the hereditary retinopathy

In the same period, 95 families were examined by using the targeted sequencing technology, which are suspected with retinitis pigmentosa or congenital retinopathy. Partial genealogical trees are shown in **Figure S25**. We identified 68 distinct mutations from 31 different known disease genes in the patients of these families, 37 mutations are novel among them. The results are grouped by related genes found in the retinopathy patients. In this investigation, 57.9% of the families under test have been detected significant mutants (**Table 1** and **Table 2**). The mutations listed in **Table 1** are predicted as damaging or disease causing by function analysis software, and a part of the mutations have been studied and reported. The phenotype and mutation of each of these families are co-segregation, respectively. Targeted sequencing of retinopathy related genes provides 45.3% diagnostic rate, and another 12.6% families receive candidate gene mutations with undefined pathogenicity in this study.

Four families (Family 14, 15, 48 and 54) suffering from retinitis pigmentosa caused by *RHO* mutations, the patients of these families presented with night blindness from childhood, visual field defect or tubular visual field and retinitis pigmentosa. The Sanger sequencing results of mutant sites of Family 14 and Family 15 are presented in **Figure S13** and **S14** respectively. *NDP* mutations can lead to familial exudative vitreoretinopathy or Norrie disease. Two families (18 and 46) with *FEVR2* have been detected two novel *NDP* mutations, c.124C>A (p.H42N) (Sanger result in **Figure 3**) and c.401\_402delGA (p.\*134Wfs\*13). The probands were found that their eyes do not chase things when they a few months old, and no blood vessel area of binocular fundus detected by ophthalmoscopic examination. Male patients of the two families have no other serious visual problems. Two families (32 and 55) diagnosed as Norrie disease have two known *NDP* mutations, c.343C>T (p.R115X) and c.268C>T (p.R90C). The two months old male patient in Family 32 has vitreous hyperplasia, right microphthalmos and microcorneas, while the male patient in Family 55 is legal blindness and atrophy of eyeballs. Mutation of *USH2A* can cause retinitis pigmentosa with or without syndromic hearing loss. The patients from Family 7 and Family 47 with Usher syndrome, type 2A, they presented with retinitis pigmentosa and hearing impairment. The two patients have different mutations in *USH2A* gene (**Figure S11**, **S17** and **S18**). The patient of Family 9 with *USH2A* mutation just has nonsyndromic retinal diseases. Three families (Family 27, 38 and 51) were detected different *RS1* hemizygous mutations in the retinoschisis patients. The results of fundus examination and optical coherence tomography of the congenital retinoschisis patient in Family 38 are shown in **Figure S5** and **S6**. Patients from the two families (Family 1 and 2) can be diagnosed as RP, 38 caused by *MERTK* gene mutations. These patients are characterized by retinitis pigmentosa, night blindness and visual field loss.

Small deletion and nonsense mutation of *CYP4V2* resulted in Bietti crystalline corneoretinal dystrophy of the patients from Family 3 and 4. The Patient's result of visual electrophysiology in Family 3 is shown in **Figure S1**. The *CYP4V2* c.(802-8)\_810delTCATACAGGTCATCGCTinsGC and c.958C>T mutations in Family 4 are shown in **Figure S8** and **S9**. *FSCN2* c.72delG causes retinitis pigmentosa, type 30 in two unrelated families (Family 5 and 6). *FSCN2* c.72delG Sanger sequencing result is shown in **Figure S10**. Small deletion and frameshift mutation of *PRPF31* resulted in retinitis pigmentosa, type 11 of the patients from Family 12 (*PRPF31* c.1074-8\_1079delGTACCGTCCCCAG novel mutation seen in **Figure S12**) and Family 50. There are four RP patients from three generations of the Family 12. In addition to the symptoms of retinitis pigmentosa, night blindness and tubular visual field, the proband and his father (**Figure S25**) were also treated with bilateral cataract surgery. There are two families (Family 33 and 52) with family history of RP and night blindness caused by the same mutation, *RPGR* c.2236\_2237delGA. There are two families (Family 43 and 44) with family history of RP and night blindness caused by the different mutations of *RP2*, and the splicing mutation c.769-2A>G has been reported to pathogenic for RP, the frameshift mutation c.572\_582dup11 is novel.

There seventeen families affected by different retinal diseases have been detected pathogenic or likely pathogenic mutations of 17 different related genes. The patient of Family 36 with macular degeneration has poor eyesight. The patient of Family 16 has retinochoroidal coloboma, his results of visual field examination and mutation sequencing is shown in **Figure S4**. Sanger sequencing result of the mutant site in Family 17 is shown in **Figure S15**, and the RP proband also combined with cataract when he twenty-six years old. The patient of Family 20 was two years old (Sanger result seen in **Figure S20**), her full field ERG showed that rod cells had no waves, while scotopic ERG showed that the amplitudes of  $\alpha$  and  $\beta$  waves decreased. The ophthalmoscopic image and sequencing result of RCS patient from Family 22 are presented in **Figure S19**. The *CNGA1* mutations in Family 45 were validated by Sanger sequencing (**Figure S16**). The thirty-four years old mother and her daughter have macular degeneration of fundus in Family 34. The forty-one years old patient of Family 35 suffered from retinal detachment, primary vitreous hyperplasia and familial exudative vitreoretinopathy, and his mother with the same *FZD4* c.612T>A heterozygous mutation also had the same eye symptoms. Both of the thirty-three years old man and his mother with neurodeatrophia and familial exudative vitreoretinopathy carry the *LRP5* c.485\_488delACGG heterozygous mutation in Family 37. The three years old girl with congenital horizontal nystagmus has compound heterozygous variation of *SLC38A8* in Family 39, and her parents are carriers of the heterozygous variation. The two years old boy is a Leber congenital amaurosis patient, and his parents are the carriers of heterozygous variation of *AIP1* in Family 40. The hemizygous *FRMD7* c.910C>T (p.R304X) mutation led to Nystagmus of the boy in Family 41, and his mother carries the heterozygous mutation. The five years old boy diagnosed as Leber congenital amaurosis caused by homozygous mutation of *GUCY2D* c.3177\_3178delAC inherited from parents.

#### Variants of undetermined significance in retinopathy families

The mutations listed in **Table 2** are predicted as damaging or associated with the clinical phenotypes of the families, which can be considered as candidate mutants but not fully determined. The families included in **Table 2** usually have no family history of hereditary diseases. There are four families (8, 10, 23 and 53) been detected different compound heterozygous mutations of *USH2A*, the mutations associate with the nonsyndromic phenotype of retinitis pigmentosa of these patients without obvious hearing impairment. The mutations found in the four families are likely pathogenic. The four years old boy in Family 19 was detected compound heterozygous mutation of *USH1C*, which gene variation can cause Usher syndrome -type 1C characterized as severe hearing impairment and retinitis pigmentosa. The patient with RP and night blindness has suffered from bilateral secretory otitis media, but his bilateral hearing is basically normal. His both ears passed TEOAE (transient evoked otoacoustic Emissions) examination and DPOAE (distortion product otoacoustic emissions) test at the acoustic frequency (1k, 2k, 4k and 8k Hz), but left ear did not pass DPOAE at 0.5k Hz acoustic frequency. I wave latency was slightly longer after 80 dBnHL short-tone stimulation in ABR (auditory brainstem response) test of the boy, and other waves were normal. So the *USH1C* mutation is associated with the phenotypes, but undetermined significance. The other patients from different families (13, 25, 56, 24, 29 and 31) (**Table 2**) have candidate gene mutations and corresponding phenotypes, respectively. The Sanger sequencing results of Family 56 is shown in **Figure S21** and **S22**. It should be noted that the *RS1* c.240G>C (p.Q80H) mutation not co-separated from the phenotype and genotype in Family 26.

#### Specific cases

**Family 2:** There are two RP patients in Family 2. The thirteen years old sister with patchy defects of visual field and abnormal ERG, she has homozygous mutation of *MERTK* c.754delC (**Figure 4**). The ten years old brother's symptoms was milder than his sister, he also had defects of visual field (**Figure S7**) and carried the same homozygous mutation. They all suffered from night blindness and visual impairment. Their parents are the carriers of the heterozygous variation of *MERTK* c.754delC. According to ACMG guidelines, the novel frameshift mutation of *MERTK* c.754delC should be considered as pathogenic, and its grade (PVS1) is high. This family acquired a healthy boy through three generations of IVF technology (pre-implantation genetic diagnosis).

**Family 3:** The patient with homogeneous mutation of *CYP4V2* c.(802-8)\_810delTCATACAGGTCATCGCTinsGC has retinitis pigmentosa and visually impaired. This mutation is known pathogenic for Bietti crystalline corneoretinal dystrophy (Bietti CCD), it involves small deletion and insertion in splicing regions. She has the typical fundus and visual electrophysiological symptoms (**Figure S24** and **Figure S1**). So the patient can be diagnosed as Bietti CCD by combining ocular manifestations and gene mutation.

**Family 5:** The RP patient in Family 5 all carried known pathogenic mutation, *FSCN2* c.72delG. The proband has the typical fundus and visual electrophysiological symptoms (**Figure S23** and **Figure S2**). This mutation is the same genetic cause for Family 6, and it is a common pathogenic mutation for RP, 30.

**Family 11:** The three years old boy, one of fraternal twins, sought medical advice for night blindness. The patient's clinical manifestations also included retinal abnormalities, lateral nystagmus and finger stimulating eyeball phenomenon. He has the *TULP1* compound heterozygous mutation of c.1318C>T (p.R440X) and c.1142T>G (p.V381G), his parents are heterozygous variants carrier of each of the two mutations. The nonsense mutation c.1318C>T (p.R440X) is known pathogenic for Leber congenital amaurosis, type 15, and the missense mutation c.1142T>G (p.V381G) is novel. c.1142T>G can lead to amino acid substitution of the protein product, it affects the function. The eye examination and mutations are presented in **Figure 2**. So the boy was diagnosed as LCA 15 by combining clinical manifestations and gene mutation.

**Family 18:** The one years old boy's fundus photographs and mutation sequencing results are shown in **Figure 3**. The cornea was clear in both eyes, the anterior chamber was preserved and the lens was transparent. The fundus examination showed that there was no blood vessel area in both eyes. The temporal epiretinal membrane of the right fundus vascular arch pulled the macula. The mutation of *NDP* can lead to familial exudative vitreoretinopathy, type 2 (FEVR2), and c.124C>A (p.H42N) is novel for FEVR2. There is one known pathogenic mutation of c.125A>G (p.H42R) at the same location of polypeptide chain of this novel variant. According to ACMG guidelines and related prediction software, the c.124C>A (p.H42N) should be pathogenic. FEVR2 is characterized by no blood vessel area of fundus, but severity of the disease varies. There three persons with c.124C>A (p.H42N) mutation have no blood vessel area in both fundus from this family.

**Family 21:** This is a consanguineous marriage family of Chinese Hui (A Chinese minority). The patient presented with retinoschisis, macular edema and night blindness, and he carried the homozygous mutation of *NR2E3* c.925C>T (p.R309W). The ophthalmological examination and mutation sequencing results of the patient are shown in **Figure 5** and **Figure S3**. The missense mutation c.925C>T of *NR2E3* is novel for Goldmann-Favre syndrome, but the c.925C>G (p.R309G) at same location of mRNA and polypeptide chain is known pathogenic for Goldmann-Favre syndrome and Enhanced S-cone syndrome[8]. Some scholars believe that the severe type of Enhanced S-cone syndrome is Goldmann-Favre syndrome[9]. The patient's condition has worsened over the past 10 years, and he can be diagnosed as Goldmann-Favre syndrome by combining phenotype and genotype.

## Discussion

Using targeted NGS technology and Sanger sequencing, we investigated the mutation profile and clinical features in 211 Chinese families with hereditary retinopathy during the three years. Ninety-five families were studied by targeted next-generation sequencing, and fifty-five of them had meaningful positive findings. One hundred and sixteen patients from different families were tested through Sanger sequencing, and twenty-five persons of them detected related mitochondrial mutations. Hereditary retinopathy covers a group of genetically and clinical highly heterogeneous disorders. Targeted NGS analysis is a valuable method for molecular genetics diagnostics of these diseases supported by previous studies[10-12]. These studies show that the potential molecular genetics diagnostic rate of targeted sequencing is between 38%[11] and 76%[12], Jespersgaard's report indicates that the detection rate of related genotypes was 72%, and the detection rate of causative variants was 48%[10]. Our study provides 45.3% potential diagnostic rate of the hereditary retinopathy families and 58% meaningful detection rate of the subject families in totally. The rate of mutation found is probably comparable with the previous literatures. DNA sequencing has become a powerful diagnostic tool for hereditary retinal disease.

Twenty-five patients with positive results of mitochondrial gene testing in our study were 19 years old on average, with a male-to-female ratio of 4/1. It indicates that the patients from Chinese population have younger age and higher sex ratio than Europe and America, by comparisons with previous studies [13, 14]. Our study did not found new mitochondrial variant, it showed that the mt.11778 and mt.14484 are most common pathogenic mutations for LHON. The possibility of over represented in LHON diagnosis is due to the smaller scale and single center collection.

Since many subjects did not have definitely ophthalmological diagnosis before NGS examination due to the clinical heterogeneity, they were mostly (but not limited to) retinitis pigmentosa or lesions as the main disease characteristics. So we did not further subdivide the subtypes. But our genetic test results, in turn, can eventually help ophthalmologists to make a diagnosis, or even suggest undetectable lesions, which can be confirmed by further clinical examination. Our impression is that the rare and severe ocular lesions have a higher positive rate of genetic testing in this study. In recent years, one study of visual impairment gene detection in a large Dutch cohort has provided meaningful information, depending on the large sample size, which includes various types of inherited eye disorders[15]. There mainly four types, such as RP, cataract, developmental eye defects and optic atrophy, were investigated in this previous research, the detection rate was 63, 50, 33 and 17%, respectively. Due to the imbalance of number of subjects in different types, the detection rate of several types with fewer subjects may need more independent studies support. In contrast, we focused more on the genetic variation of fundus lesions such as generalized retinitis pigmentosa and special optic atrophy.

Retinitis pigmentosa is a hereditary progressive retinopathy. It is the most common group of blindness fundus diseases characterized as nocturnal blindness and progressive visual field defect caused by degeneration of retinal photoreceptor cells and pigment epithelial cells[16]. Its inheritance modes include autosomal dominant, autosomal recessive and X-linked recessive inheritance. Thirty families (Family 14, 15, 48, 54, 7, 9, 47, 1, 2, 3, 4, 5, 6, 12, 50, 33, 52, 43, 44, 36, 17, 45, 8, 10, 23, 53, 19, 13, 24 and 31) with retinitis pigmentosa (or macular degeneration) had positive meaningful finding of gene mutations. With the help of genetic diagnosis, these patients were diagnosed as various types of retinitis pigmentosa. Some of these families acquired healthy offspring through genetic prenatal diagnosis or third generation test-tube infant technology (preimplantation genetic diagnosis). RP accounts for a large proportion of hereditary retinopathy in our study. It is difficult to distinguish cone-rod dystrophy from retinitis pigmentosa because of its similarity in clinical manifestations[17]. Through molecular genetic testing, we can make accurate diagnosis for patients with con-rod dystrophy (Family 34). It is difficult for some patients to differentiate choroideremia from RP, and detection of *CHM* gene mutation has differential diagnostic value. Choroideremia has a worse prognosis than RP[18]. The patient of Family 16 with choroideremia was diagnosed through targeted sequencing. Congenital stationary night blindness (CSNB) is similar with RP in clinical presentation, but the prognosis is better. We identified a case (Family 20) of CSNB, type 1C, through genetic targeting sequencing in this study.

Vitreoretinopathy is another major type of hereditary retinopathy. There are nine families (Family 18, 32, 46, 55, 35, 37, 49, 25, 56) been detected gene mutations related to such diseases. Familial exudative vitreoretinopathy is a retinal vascular structural abnormality, with different inheritance patterns. The clinical symptoms of the disease vary greatly, even in the same family[19]. Mild patients have no symptoms, and only one disease related abnormality is a circular arc without vascular retina at the periphery of the terminal temporal area. The characteristics have been observed in these cases. Non-syndromic retinoschisis is an X-linked hereditary retinopathy, and its known pathogenic gene is *RS1*. We observed three different known pathogenic mutations of *RS1* from three different families (Family 27, 38 and 51). The new mutation *RS1* c.240G>C found in Family 26 may be benign, because both of the patient and his normal maternal grandfather carry the mutation. Goldmann-Favre syndrome is an ocular syndrome with clinical symptoms including retinoschisis (Family 21).

Leber congenital amaurosis (LCA) is early onset and serious impairment of visual function[20]. Most of the patients may develop into blind children. Usually parents can observe visual abnormalities within one year of the child's birth. The children from four different families (Family 11, 28, 40 and 42) were diagnosed as LCA in our investigation. Targeted sequencing is of great significance in the diagnosis of hereditary ophthalmopathy. It will become part of our eye health management. We have also detected two cases of fundus developmental disease in our study, which are renal coloboma syndrome (Family 22) and foveal hypoplasia (Family 39). These two diseases are usually untreatable and have a general prognosis, but families with the disease could avoid high-risk offspring according to genetic rules. Two families (Family 41 and 29) with nystagmus have been detected two different mutations of *GPR143* and *FRMD7*. The *GPR143* or *FRMD7* related nystagmus is X linked inheritance, with or without obvious retinal abnormalities. The genetic causes can guide these two families to have healthy offspring.

Previously, there were also studies that used Sanger method to sequence only one or several genes for molecular diagnosis of patients with different retinal disease[21-24]. One Bietti crystalline corneoretinal dystrophy research show us 84% detection rate by only *CYP4V2* sequencing[21], and *CYP4V2* is the only known pathogenic gene so far. It is likely to be a single example of over representation. The related detection rates of two familial exudative vitreoretinopathy studies are just 23%[22] and 38.7%[23] by sequenced three and six genes, respectively. Meaningful result of genetic testing usually requires a high level of accurate clinical diagnosis. However, retinal diseases have complex clinical manifestations and genetic heterogeneity. The clinical symptoms of some diseases are difficult to distinguish, and some diseases are related to more genes. As the number of genes needed to detect is increased, the efficiency of Sanger sequencing method becomes low. So, targeted sequencing becomes a better choice. The Analysis of copy number variants of the exons of targeted gene is also executed in this study using the panel sequencing data, however, there were no positive found. There exons duplication of *OCRL* has been found in Lowe syndrome in our previous work[25].

In summary, we researched the clinical and genetic characteristics of the families of hereditary retinopathy with positive findings on genetics level. We reported 37 novel related meaningful mutations and 31 known pathogenic variants for retinopathy, which lead to different relevant phenotypes of the eye diseases. These mutations are distributed in 31 different related genes. The diagnostic rate of LHON was 21.6% in our study, but no new mitochondrial pathogenic mutations were found. To our knowledge, this is a larger scale medical genetic study of retinal diseases in the Chinese population, and it reports many new pathogenic or significant related mutations and expands the phenotypic information of related diseases. Our study demonstrates the importance of studying a large collection of families with hereditary retinopathy due to the clinical manifestations and genetic heterogeneity of the diseases, which has guiding significance for this disease diagnosis and aristogenesis.

## Conclusion

Our study contributed more novel mutations and phenotypic aspects of retinopathy, and displayed genetic and clinical heterogeneity of the conditions. Our results illustrated the significance of molecular genetic testing for patients with hereditary retinopathy.

## Declarations

- Ethics approval and consent to participate– Clinical investigations were conducted according to the Declaration of Helsinki, and the study was approved by the institutional review board of the Medical Ethics Committee of the First affiliated Hospital of Zhengzhou University. For all the minor patients, their parents agree their participation in this study. The adult patients also consented to participate in this study.
- Consent for publication– Written informed consent for publication of clinical details and/or clinical images was obtained from all of the participants. Informed consent of individuals younger than the age of 18 was written by their parents. •Availability of data and material– The datasets used and analysed during the current study are available from the corresponding author on reasonable request.
- Competing interests– The authors report no conflicts of interest.
- Funding– This work was funded in part by National Key R&D Program of China (2018YFC1002206-2).
- The role of the funding body– This study is the authors' independent work, and the funding agency only provides relevant financial support. Design of the study and collection, analysis, and interpretation of data and writing the manuscript have been completed by all the authors, independently.
- Authors' contributions–BZ and KX contributed to the conception and design of the study. XY and LL carried out the experiments. BZ, SJ and LY performed data analysis. BZ wrote and revised the manuscript. All authors read and approved the final manuscript.
- Acknowledgements– We would like to thank all the participants for their help and willingness to participate in this study. We thank the reviewers for the comments. We also thank the editor of this manuscript.

## References

1. Xu, L., et al., *Prevalence of retinitis pigmentosa in urban and rural adult Chinese: The Beijing Eye Study*. Eur J Ophthalmol, 2006. **16**(6): p. 865-6.
2. Dimopoulos, I.S. and M. Xu, *Re: Feuer et al.: Gene therapy for Leber hereditary optic neuropathy: initial results (Ophthalmology 2016;123:558-570)*. Ophthalmology, 2017. **124**(3): p. e22.
3. Petrs-Silva, H., et al., *Suppression of rds expression by siRNA and gene replacement strategies for gene therapy using rAAV vector*. Adv Exp Med Biol, 2012. **723**: p. 215-23.
4. Ghazi, N.G., et al., *Treatment of retinitis pigmentosa due to MERTK mutations by ocular subretinal injection of adeno-associated virus gene vector: results of a phase I trial*. Hum Genet, 2016. **135**(3): p. 327-43.
5. Rodrigues, G.A., et al., *Pharmaceutical Development of AAV-Based Gene Therapy Products for the Eye*. Pharm Res, 2018. **36**(2): p. 29.
6. DiCarlo, J.E., V.B. Mahajan, and S.H. Tsang, *Gene therapy and genome surgery in the retina*. J Clin Invest, 2018. **128**(6): p. 2177-2188.

7. Richards, S., et al., *Standards and guidelines for the interpretation of sequence variants: a joint consensus recommendation of the American College of Medical Genetics and Genomics and the Association for Molecular Pathology*. Genet Med, 2015. **17**(5): p. 405-24.
8. Haider, N.B., et al., *Mutation of a nuclear receptor gene, NR2E3, causes enhanced S cone syndrome, a disorder of retinal cell fate*. Nat Genet, 2000. **24**(2): p. 127-31.
9. Marmor, M.F., *A teenager with nightblindness and cystic maculopathy: enhanced S cone syndrome (Goldmann-Favre syndrome)*. Doc Ophthalmol, 2006. **113**(3): p. 213-5.
10. Jespersgaard, C., et al., *Molecular genetic analysis using targeted NGS analysis of 677 individuals with retinal dystrophy*. Sci Rep, 2019. **9**(1): p. 1219.
11. Martin-Merida, I., et al., *Genomic Landscape of Sporadic Retinitis Pigmentosa: Findings from 877 Spanish Cases*. Ophthalmology, 2019. **126**(8): p. 1181-1188.
12. Stone, E.M., et al., *Clinically Focused Molecular Investigation of 1000 Consecutive Families with Inherited Retinal Disease*. Ophthalmology, 2017. **124**(9): p. 1314-1331.
13. Carelli, V., et al., *Parsing the differences in affected with LHON: genetic versus environmental triggers of disease conversion*. Brain, 2016. **139**(Pt 3): p. e17.
14. Black, G.C., et al., *Leber's hereditary optic neuropathy: implications of the sex ratio for linkage studies in families with the 3460 ND1 mutation*. Eye (Lond), 1995. **9** (Pt 4): p. 513-6.
15. Haer-Wigman, L., et al., *Diagnostic exome sequencing in 266 Dutch patients with visual impairment*. Eur J Hum Genet, 2017. **25**(5): p. 591-599.
16. Berson, E.L., *Retinitis pigmentosa. The Friedenwald Lecture*. Invest Ophthalmol Vis Sci, 1993. **34**(5): p. 1659-76.
17. Daiger, S.P., L.S. Sullivan, and S.J. Bowne, *Genes and mutations causing retinitis pigmentosa*. Clin Genet, 2013. **84**(2): p. 132-41.
18. Chan, S.C., et al., *Choroideremia research: Report and perspectives on the second international scientific symposium for choroideremia*. Ophthalmic Genet, 2016. **37**(3): p. 267-75.
19. Seo, S.H., et al., *Molecular Characterization of FZD4, LRP5, and TSPAN12 in Familial Exudative Vitreoretinopathy*. Invest Ophthalmol Vis Sci, 2015. **56**(9): p. 5143-51.
20. Kumaran, N., et al., *Leber congenital amaurosis/early-onset severe retinal dystrophy: clinical features, molecular genetics and therapeutic interventions*. Br J Ophthalmol, 2017. **101**(9): p. 1147-1154.
21. Yin, X., et al., *Identification of CYP4V2 mutation in 36 Chinese families with Bietti crystalline corneoretinal dystrophy*. Exp Eye Res, 2016. **146**: p. 154-62.
22. Tang, M., et al., *Mutation Spectrum of the LRP5, NDP, and TSPAN12 Genes in Chinese Patients With Familial Exudative Vitreoretinopathy*. Invest Ophthalmol Vis Sci, 2017. **58**(13): p. 5949-5957.
23. Rao, F.Q., et al., *Mutations in LRP5, FZD4, TSPAN12, NDP, ZNF408, or KIF11 Genes Account for 38.7% of Chinese Patients With Familial Exudative Vitreoretinopathy*. Invest Ophthalmol Vis Sci, 2017. **58**(5): p. 2623-2629.
24. Alapati, A., et al., *Molecular diagnostic testing by eyeGENE: analysis of patients with hereditary retinal dystrophy phenotypes involving central vision loss*. Invest Ophthalmol Vis Sci, 2014. **55**(9): p. 5510-21.
25. Bai, Z., et al., *[Clinical and genetic analysis of an infant with Lowe syndrome caused by exonic duplication of OCRL gene]*. Zhonghua Yi Xue Yi Chuan Xue Za Zhi, 2020. **37**(1): p. 28-32.
26. Sung, C.H., et al., *Rhodopsin mutations in autosomal dominant retinitis pigmentosa*. Proc Natl Acad Sci U S A, 1991. **88**(15): p. 6481-5.
27. Dryja, T.P., et al., *Mutation spectrum of the rhodopsin gene among patients with autosomal dominant retinitis pigmentosa*. Proc Natl Acad Sci U S A, 1991. **88**(20): p. 9370-4.
28. Bunge, S., et al., *Molecular analysis and genetic mapping of the rhodopsin gene in families with autosomal dominant retinitis pigmentosa*. Genomics, 1993. **17**(1): p. 230-3.
29. Shastry, B.S., J.F. Hejtmancik, and M.T. Trese, *Identification of novel missense mutations in the Norrie disease gene associated with one X-linked and four sporadic cases of familial exudative vitreoretinopathy*. Hum Mutat, 1997. **9**(5): p. 396-401.
30. Liu, D., et al., *A novel nonsense mutation in the NDP gene in a Chinese family with Norrie disease*. Mol Vis, 2010. **16**: p. 2653-8.
31. Smith, S.E., et al., *Norrie disease: extraocular clinical manifestations in 56 patients*. Am J Med Genet A, 2012. **158a**(8): p. 1909-17.
32. Dai, H., et al., *Identification of five novel mutations in the long isoform of the USH2A gene in Chinese families with Usher syndrome type II*. Mol Vis, 2008. **14**: p. 2067-75.
33. Katagiri, S., et al., *Whole exome analysis identifies frequent CNGA1 mutations in Japanese population with autosomal recessive retinitis pigmentosa*. PLoS One, 2014. **9**(9): p. e108721.
34. Xu, W., et al., *Seven novel mutations in the long isoform of the USH2A gene in Chinese families with nonsyndromic retinitis pigmentosa and Usher syndrome Type II*. Mol Vis, 2011. **17**: p. 1537-52.
35. *Functional implications of the spectrum of mutations found in 234 cases with X-linked juvenile retinoschisis. The Retinoschisis Consortium*. Hum Mol Genet, 1998. **7**(7): p. 1185-92.
36. Huang, Y., et al., *A novel deletion mutation in RS1 gene caused X-linked juvenile retinoschisis in a Chinese family*. Eye (Lond), 2014. **28**(11): p. 1364-9.
37. Xu, Y., et al., *Mutations of 60 known causative genes in 157 families with retinitis pigmentosa based on exome sequencing*. Hum Genet, 2014. **133**(10): p. 1255-71.
38. Wada, Y., et al., *Screening for mutations in CYP4V2 gene in Japanese patients with Bietti's crystalline corneoretinal dystrophy*. Am J Ophthalmol, 2005. **139**(5): p. 894-9.

39. Xiao, X., et al., *Identification of CYP4V2 mutation in 21 families and overview of mutation spectrum in Bietti crystalline corneoretinal dystrophy*. Biochem Biophys Res Commun, 2011. **409**(2): p. 181-6.
40. Wada, Y., et al., *Mutation of human retinal fascin gene (FSCN2) causes autosomal dominant retinitis pigmentosa*. Invest Ophthalmol Vis Sci, 2001. **42**(10): p. 2395-400.
41. Dong, B., et al., *Two novel PRP31 premessenger ribonucleic acid processing factor 31 homolog mutations including a complex insertion-deletion identified in Chinese families with retinitis pigmentosa*. Mol Vis, 2013. **19**: p. 2426-35.
42. Yang, L., et al., *Novel mutations of RPGR in Chinese retinitis pigmentosa patients and the genotype-phenotype correlation*. PLoS One, 2014. **9**(1): p. e85752.
43. Hosono, K., et al., *Molecular Diagnosis of 34 Japanese Families with Leber Congenital Amaurosis Using Targeted Next Generation Sequencing*. Sci Rep, 2018. **8**(1): p. 8279.
44. Ernest, P.J., et al., *Outcome of ABCA4 microarray screening in routine clinical practice*. Mol Vis, 2009. **15**: p. 2841-7.
45. Lewis, R.A., et al., *Genotype/Phenotype analysis of a photoreceptor-specific ATP-binding cassette transporter gene, ABCR, in Stargardt disease*. Am J Hum Genet, 1999. **64**(2): p. 422-34.
46. Wang, H., et al., *Comprehensive Molecular Diagnosis of a Large Chinese Leber Congenital Amaurosis Cohort*. Invest Ophthalmol Vis Sci, 2015. **56**(6): p. 3642-55.
47. Gerber, S., et al., *Complete exon-intron structure of the RPGR-interacting protein (RPGRIP1) gene allows the identification of mutations underlying Leber congenital amaurosis*. Eur J Hum Genet, 2001. **9**(8): p. 561-71.
48. van Genderen, M.M., et al., *Mutations in TRPM1 are a common cause of complete congenital stationary night blindness*. Am J Hum Genet, 2009. **85**(5): p. 730-6.
49. Negrisoló, S., et al., *PAX2 gene mutations in pediatric and young adult transplant recipients: kidney and urinary tract malformations without ocular anomalies*. Clin Genet, 2011. **80**(6): p. 581-5.
50. Lenis, T.L., et al., *Novel compound heterozygous mutations resulting in cone dystrophy with supernormal rod response*. JAMA Ophthalmol, 2013. **131**(11): p. 1482-5.
51. Poulter, J.A., et al., *Recessive mutations in SLC38A8 cause foveal hypoplasia and optic nerve misrouting without albinism*. Am J Hum Genet, 2013. **93**(6): p. 1143-50.
52. Li, N., et al., *Five novel mutations of the FRMD7 gene in Chinese families with X-linked infantile nystagmus*. Mol Vis, 2008. **14**: p. 733-8.
53. Chen, X., et al., *Targeted sequencing of 179 genes associated with hereditary retinal dystrophies and 10 candidate genes identifies novel and known mutations in patients with various retinal diseases*. Invest Ophthalmol Vis Sci, 2013. **54**(3): p. 2186-97.
54. Aparisi, M.J., et al., *Targeted next generation sequencing for molecular diagnosis of Usher syndrome*. Orphanet J Rare Dis, 2014. **9**: p. 168.
55. McGee, T.L., et al., *Novel mutations in the long isoform of the USH2A gene in patients with Usher syndrome type II or non-syndromic retinitis pigmentosa*. J Med Genet, 2010. **47**(7): p. 499-506.
56. Redin, C., et al., *Targeted high-throughput sequencing for diagnosis of genetically heterogeneous diseases: efficient mutation detection in Bardet-Biedl and Alstrom syndromes*. J Med Genet, 2012. **49**(8): p. 502-12.
57. Qin, M., et al., *Complexity of the genotype-phenotype correlation in familial exudative vitreoretinopathy with mutations in the LRP5 and/or FZD4 genes*. Hum Mutat, 2005. **26**(2): p. 104-12.
58. Jiang, F., et al., *Screening of ABCA4 Gene in a Chinese Cohort With Stargardt Disease or Cone-Rod Dystrophy With a Report on 85 Novel Mutations*. Invest Ophthalmol Vis Sci, 2016. **57**(1): p. 145-52.

## Tables

Table 1. General situation of families with pathogenic or likely pathogenic mutation

Fa	Np	Gene	Transcript	Ex	NA Changes	AA changes	Hzyo	Pf	Reported	Gm	Disease	SPM	ACMG grade
14	2	RHO	NM_000539	1	c.251T>C	p.L84P	Het	-	Novel	AD	RP, 4	+++	PS4+PM1+PM2+PP1+PP3
15	4	RHO	NM_000539	2	c.403C>T	p.R135W	Het	0/ 1.082 <sup>e-5</sup>	Yes[26]	AD	RP, 4	+++	PS1+PM1+PP1+PP3
48	1	RHO	NM_000539	3	c.541G>A	p.E181K	Het	-	Yes[27]	AD	RP, 4	+++	PS2+PM2+PP3
54	2	RHO	NM_000539	2	c.403C>T	p.R135W	Het	0/ 1.082 <sup>e-5</sup>	Yes[28]	AD	RP, 4	+++	PS1+PM1+PP1+PP3
18	3	NDP	NM_000266	2	c.124C>A	p.H42N	Hemi	-	Novel	XL	FEVR2[29]	+++	PM2+PM5+PP1+PP3
32	1	NDP	NM_000266	3	c.343C>T	p.R115X	Hemi	-	Yes[30]	XLR	Norrie	+++	PVS1+PS1+PM2+PP3
46	1	NDP	NM_000266	3	c.401_402delGA	p.*134Wfs*13	Hemi	-	Novel	XL	FEVR2	///	PVS1+PS2+PM2
55	3	NDP	NM_000266	3	c.268C>T	p.R90C	Hemi	-	Yes[31]	XLR	Norrie	+++	PS1+PM2+PP1+PP3
7	1	USH2A	NM_206933	2	c.99_100insT	p.R34Sfs*41	Hom	6.242 <sup>e-5</sup> / 3.231 <sup>e-5</sup>	Yes[32]	AR	Usher 2A	///	PVS1+PS1+PM2
9	1	USH2A	NM_206933	55	c.10859T>C	p.I3620T	Het	1.16 <sup>e-4</sup> / 1.219 <sup>e-5</sup>	Yes[33]	AR	Usher 2A/RP, 39	+++	PS1+PM2+PM3+PP3
		USH2A	NM_206933	13	c.2802T>G	p.C934W	Het	2.441 <sup>e-3</sup> / 1.915 <sup>e-4</sup>	Yes[34]	AR	Usher 2A/RP, 39	+++	PS1+PM2+PM3+PP3
47	1	USH2A	NM_206933	63	c.13596dupC	p.S4533Lfs*28	Het	-	Novel	AR	Usher 2A	///	PVS1+PM2+PM3
		USH2A	NM_206933	56	c.10962C>A	p.Y3654X	Het	-	Novel	AR	Usher 2A	+++	PVS1+PM2+PM3+PP3
27	1	RS1	NM_000330	6	c.598C>T	p.R200C	Hemi	-	Yes[35]	XLR	Retinoschisis	+++	PS1+PM2+PP3
38	1	RS1	NM_000330	4	c.214G>A	p.E72K	Hemi	0/ 1.678 <sup>e-5</sup>	Yes[35]	XLR	Retinoschisis	+++	PS1+PM2+PP3
51	2	RS1	NM_000330	4	c.206_207delTG	p.Leu69Argfs*16	Hemi	-	Yes[36]	XLR	Retinoschisis	///	PVS1+PS1+PM2+PP1
1	1	MERTK	NM_006343	8	c.1186G>T	p.E396X	Het	-	Yes[37]	AR	RP,38	///	PVS1+PS1+PM2
		MERTK	NM_006343	3	c.518A>G	p.Y173C	Het	0/ 1.219 <sup>e-5</sup>	Novel	AR	RP,38	+++	PM2+PM3+PP3+PP4
2	2	MERTK	NM_006343	4	c.754delC	p.P252Qfs*3	Hom	-	Novel	AR	RP,38	///	PVS1+PM2+PP1

Table 1 continued 1. General situation of families with pathogenic or likely pathogenic mutation



Fa	Np	Gene	Transcript	Ex	NA Changes	AA changes	Hzyo	Pf	Reported	Gm	Disease	SPM	ACMG
3	1	CYP4V2	NM_207352	7	c.(802-8)_810delTCATACAGGTCATCGTinsGC	?p.268_270del/Splicing	Hom	7.963 <sup>e-4</sup> / 6.856 <sup>e-5</sup>	Yes[38]	AR	Bietti CCD	///	PVS1+P5
4	2	CYP4V2	NM_207352	7	c.(802-8)_810delTCATACAGGTCATCGTinsGC	?p.268_270del/Splicing	Het	7.963 <sup>e-4</sup> / 6.856 <sup>e-5</sup>	Yes[38]	AR	Bietti CCD	///	PVS1+PS1+PM
		CYP4V2	NM_207352	7	c.958C>T	p.R320X	Het	0/ 4.061 <sup>e-6</sup>	Yes[39]	AR	Bietti CCD	///+	PVS1+PS1+PM
5	4	FSCN2	NM_001077182	1	c.72delG	p.T25Qfs*120	Het	0.01238/ 8.801 <sup>e-4</sup>	Yes	AD	RP, 30	///	PVS1+P5
6	2	FSCN2	NM_001077182	1	c.72delG	p.T25Qfs*120	Het	0.01238/ 8.801 <sup>e-4</sup>	Yes[40]	AD	RP, 30	///	PVS1+P5
12	4	PRPF31	NM_015629	11	c.(1074-8)_1079delGTCCCCAGGTACCG	? p.358_360delRYRinsS/Splicing	Het	-	Novel	AD	RP, 11	///	PVS1+P5
50	2	PRPF31	NM_015629	12	c.1215delG	p.Val406fs*7	Het	-	Yes[41]	AD	RP, 11	///	PVS1+PS1+
33	1	RPGR	NM_001034853	15	c.2236_2237delGA	p.E746Rfs*23	Hemi	-	Yes	XLR	MD	///	PVS1+P5
52	2	RPGR	NM_001034853	15	c.2236_2237delGA	p.E746Rfs*23	Hemi	-	Yes[42]	XLR	MD	///	PVS1+PS1+
43	5	RP2	NM_006915	3	c.769-2A>G	splicing	Hemi	-	Yes[43]	XL	RP, 2	///+	PVS1+PS1+
44	4	RP2	NM_006915	2	c.572_582dup11	p.Pro190Profs*52	Hemi	-	Novel	XL	RP, 2	///	PVS1+P5
36	1	ABCA4	NM_000350	29	c.4352+1G>A	splicing	Het	0/ 8.123 <sup>e-6</sup>	Yes[44]	AR	Stargardt 1	///+	PVS1+PS1+
		ABCA4	NM_000350	13	c.1804C>T	p.R602W	Het	2.904 <sup>e-4</sup> / 4.477 <sup>e-5</sup>	Yes[45]	AR	Stargardt 1	+++	PS1+PM2+
11	1	TULP1	NM_003322	13	c.1318C>T	p.R440X	Het	0/ 1.145 <sup>e-5</sup>	Yes[46]	AR	LCA 15	///+	PVS1+P5
		TULP1	NM_003322	12	c.1142T>G	p.V381G	Het	-	Novel	AR	LCA 15	+++	PM2+PM3-
16	1	CHM	NM_000390	5	c.544delT	p.C182Vfs*14	Hemi	-	Novel	XLD	choroideremia	///	PVS1+
28	1	RPGRIP1	NM_020366	16	c.2662C>T	p.R888X	Hom	0/1.68 <sup>e-5</sup>	Yes[47]	AR	LCA6	+++	PVS1+PS1+

Table 1 continued 2. General situation of families with pathogenic or likely pathogenic mutation

Fa	Np	Gene	Transcript	Ex	NA Changes	AA changes	Hzyo	Pf	Reported	Gm	Disease	SPM	ACMG grade
17	2	PRPF8	NM_006445	36	c.5792C>T	p.T1931M	Het	-	Novel	AD	RP, 13	+++	PM2+PP1+PP2+PP3+PP4
20	1	TRPM1	NM_001252020	21	c.2789T>A	p.I930N	Het	-	Novel	AR	CSNB1C	+++	PM2+PM3+PP2+PP3
		TRPM1	NM_001252020	22	c.3178+1G>A	splicing	Het	6.889 <sup>e-4</sup> /5.772 <sup>e-5</sup>	Yes[48]	AR	CSNB1C	///+	PVS1+PS1+PM2
21	1	NR2E3	NM_014249	6	c.925C>T	p.R309W	Hom	0/8.34 <sup>e-6</sup>	Novel	AR	GF	///+	PM2+PM5+PP2+PP4
22	1	PAX2	NM_003990	2	c.70dupG	p.V26Gfs*28	Het	0/1.237 <sup>e-5</sup>	Yes[49]	AD	RCS	///	PVS1+PS1
34	2	KCNV2	NM_133497	1	c.506_513delTGCTGCT	p.V169Gfs*40	Het	-	Novel	AR	RCD3B	///	PVS1+PM2+PM3+PP1
		KCNV2	NM_133497	1	c.137G>A	p.W46X	Het	-	Yes[50]	AR	RCD3B	+++	PVS1+PS1+PM2+PP1+PP3
35	2	FZD4	NM_206933	2	c.612T>A	p.C204X	Het	-	Novel	AD	FEVR1	+++	PVS1+PM2+PP1+PP3
37	2	LRP5	NM_002335	2	c.485_488delACGG	p.H162Rfs*38	Het	-	Novel	AD	FEVR4	///	PVS1+PM2+PP1
39	1	SLC38A8	NM_001080442	7	c.927_928delCT	p.Y310Pfs*57	Het	-	Novel	AR	FH2	///	PVS1+PM2+PM3
		SLC38A8	NM_001080442	6	c.697G>A	p.E233K	Het	2.778 <sup>e-4</sup> /6.886 <sup>e-5</sup>	Yes[51]	AR	FH2	+++	PS1+PM2+PP3
40	1	AIPL1	NM_001285399	3	c.385C>T	p.Q129X	Hom	-	Novel	AR	LCA4	+++	PVS1+PM2+PP3
41	1	FRMD7	NM_194277	10	c.910C>T	p.R304X	Hemi	0/5.608 <sup>e-6</sup>	Yes[52]	XLR	Nystagmus 1	+++	PVS1+PS1+PM2+PP3
42	1	GUCY2D	NM_000180	18	c.3177_3178delIAC	p.R1060Rfs*11	Hom	0/4.935 <sup>e-6</sup>	Novel	AR	LCA4	///	PVS1+PM2
45	1	CNGA1	NM_001142564	5	c.472delC	p.L158Ffs*4	Het	0.0012/6.455 <sup>e-5</sup>	Novel[53]	AR	RP, 49	///	PVS1+PM2
		CNGA1	NM_001142564	5	c.453C>A	p.Y151X	Het	5.798 <sup>e-5</sup> /4.068 <sup>e-6</sup>	Novel	AR	RP, 49	+++	PVS1+PM2+PP3
49	3	TSPAN12	NM_012338	8	c.731delT	p.L244Rfs*17	Het	0/4.064 <sup>e-6</sup>	Novel	AD	EV5	///	PVS1+PM2+PP1

Table 2. General situation of families with likely pathogenic mutations or related mutations of Undetermined Significance

Fa	Np	Gene	Transcript	Ex	NA Changes	AA changes	Hzyo	Pf	Reported	Gm	OMIM Disease	SPM	ACMG grade
8	1	USH2A	NM_206933	41	c.8002G>T	p.E2668X	Het	-	Novel	AR	Usher 2A/RP, 39	///+	PVS1+PM2
		USH2A	NM_206933	13	c.2802T>G	p.C934W	Het	2.441 <sup>e-3</sup> /1.915 <sup>e-4</sup>	Yes[34]	AR	Usher 2A/RP, 39	+++	PS1+PM2+PP3
10	1	USH2A	NM_206933	63	c.12608A>G	p.Q4203R	Het	9.457 <sup>e-3</sup> /3.677 <sup>e-3</sup>	Novel	AR	Usher 2A/RP, 39	---	PM2+BP4
		USH2A	NM_206933	22	c.4758+3A>G	Splicing	Het	1.855 <sup>e-2</sup> /1.457 <sup>e-3</sup>	Yes[54]	AR	Usher 2A/RP, 39	///	PS1+PM2
23	1	USH2A	NM_206933	66	c.14411G>A	p.G4804E	Het	-	Novel	AR	Usher 2A/RP, 39	///+	PM2
		USH2A	NM_206933	19	c.4217C>A	p.S1406X	Het	-	Novel	AR	Usher 2A/RP, 39	+++	PVS1+PM2+PP3
53	1	USH2A	NM_206933	65	c.14287G>A	p.G4763R	Het	-	Yes[55]	AR	Usher 2A/RP, 39	+++	PS1+PM2+PP3
		USH2A	NM_206933	4	c.784+2T>G	Splicing	Het	-	Novel	AR	Usher 2A/RP, 39	///	PVS1+PM2
19	1	USH1C	NM_153676	5	c.407G>A	p.R136Q	Het	1.16 <sup>e-4</sup> /1.223 <sup>e-4</sup>	Novel	AR	Usher 1C	///+	PM2
		USH1C	NM_153676	15	c.1250C>T	p.T417I	Het	-	Novel	AR	Usher 1C	///+	PM2
13	1	BBS2	NM_031885	6	c.626T>C	p.L209P	Het	-	Yes[56]	AR	RP, 74	+++	PS1+PM2+PP3
		BBS2	NM_031885	1	c.79A>C	p.T27P	Het	-	Novel	AR	RP, 74	---	PM2+BP4
25	1	LRP5	NM_002335	15	c.3361A>G	p.N1121D	Het	7.528 <sup>e-3</sup> /5.616 <sup>e-4</sup>	Yes[57]	AR	FEVR4	+++	PS1+PM2+PP3
		LRP5	NM_002335	18	c.3901G>A	p.A1301T	Het	2.403 <sup>e-3</sup> /2.149 <sup>e-4</sup>	Novel	AR	FEVR4	---	PM2+BP4
56	1	LRP5	NM_002335	15	c.3377T>C	p.L1126P	Het	-	Novel	AR	FEVR4	+++	PM2+PP3
		LRP5	NM_002335	22	c.4519G>T	p.D1507T	Het	-	Novel	AR	FEVR4	+++	PM2+PP3
24	1	ABCA4	NM_000350	5	c.553C>T	p.Q185X	Het	-	Yes[58]	AD	AMD2	+++	PVS1+PS1+PM2+PP3
26	1	RS1	NM_000330	4	c.240G>C	p.Q80H	Hemi	-	Novel	XLR	Retinosischisis	///+	PM2+PP4
29	1	GPR143	NM_000273	2	c.263G>A	p.R88Q	Hemi	-	Novel	XL	Nystagmus 6	+++	PM2+PP3
31	1	FBN2	NM_001999	30	c.3923dupG	p.C1308Wfs*5	Het	-	Novel	AD	EMD	///	PVS1+PM2

Notes for Table 1 and 2: Fa short for Family No.; Np short for number of patients; Ex short for exon; NA short for nucleic acid; AA short for amino acid; Hzyo short for heterozygosity; Pf short for population frequency recorded in gnomAD database; Gm short for genetic model; Disease stands for OMIM disease; SPM short for SIFT, PolyPhen.2 and Mutation t@sting predicting, '+' stands for damaging, '-' stands for benign and '/' stands for no data.

RP, 38 stands for retinitis pigmentosa, type 38; Bietti CCD stands for Bietti crystalline corneoretinal dystrophy; RP, 30 stands for retinitis pigmentosa, type 30; Usher 2A stands for Usher syndrome, type 2A; Usher 1C stands for Usher syndrome, type 1C; LCA 15 stands for Leber congenital amaurosis, type 15; RP, 11 stands for retinitis pigmentosa, type 11; RP,4 stands for retinitis pigmentosa, type 4; RP, 13 stands for retinitis pigmentosa, type 13; FEVR2 stands for familial exudative vitreoretinopathy, type 2; CSNB1C stands for congenital stationary night blindness, type 1C; GF stands for Goldmann-Favre syndrome; RCS stands for renal coloboma syndrome; FEVR1 stands for familial exudative vitreoretinopathy, type 1; Stargardt 1 stands for Stargardt's disease, type 1; FEVR4 stands

for familial exudative vitreoretinopathy, type 4; FH2 stands for foveal hypoplasia, type 2; LCA4 stands for Leber congenital amaurosis, type 4; MD stands for macular degeneration, X-linked atrophic; RCD3B stands for retinal cone dystrophy, type 3B; Nystagmus 1 stands for nystagmus, type 1, congenital, X-linked; RP, 2 stands for retinitis pigmentosa, type 2; RP,74 stands for retinitis pigmentosa, type 74; AMD2 stands for age-related macular degeneration, type 2; FEVR4 stands for familial exudative vitreoretinopathy, type4; LCA6 stands for Leber congenital amaurosis, type 6; Nystagmus 6 stands for nystagmus, type 6, congenital, X-linked; EMD stands for macular degeneration, early-onset; RP,39 stands for retinitis pigmentosa, type 39; EV5 stands for exudative vitreoretinopathy, type 5

## Figures

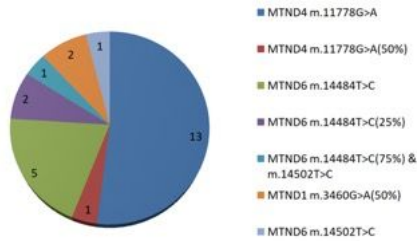


Figure 1

Variation distribution of 25 patients with Leber's hereditary optic neuropathy (21.6%)

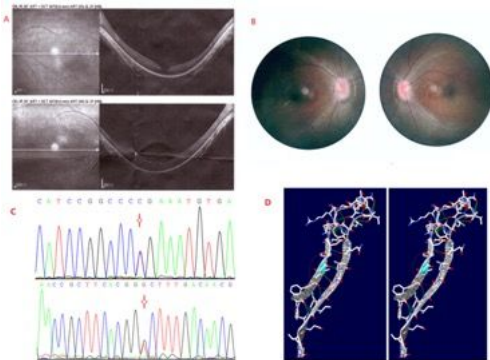


Figure 2

TULP1 mutations and clinical manifestation of the LCA 15 patient in Family 11. Part A, optical coherence tomography (OCT) shows that the temporal retinal neuroepithelium of macula of both eyes became thinning, the central fovea of macula formed backward concave; Part B, ophthalmoscopic examination shows that the boundary of optic disc is blurred and the retina is dark; Part C, the compound heterozygous mutation of TULP1 c.1318C>T p.R440X (above) and c.1142T>G p.V381G(below); Part D, Secondary structure change of the novel mutation, TULP1 c.1142T>G.




Figure 3

NDP c.124C>A hemizygous mutation and fundus avascular area of the FEVR2 patient in Family 18. Part A, fundus examination of the one year old patient showed that there was avascular area in both eyes. The temporal side of the blood vessel arch in the right eye fundus showed the epiretinal membrane and the macular traction. Part B, NDP c.124C>A mutation of the mother and the child, respectively.

