

# Robot-assisted esophageal surgery using the da Vinci® Xi system for Benign and malignant diseases of esophagus—Preliminary experience of robot assisted modified Sweet operation

**Bei Lu**

Harbin Medical University Fourth Hospital

**Li xin Sun**

Harbin Medical University Fourth Hospital

**Zhonghao Wang**

Harbin Medical University Fourth Hospital

**Xi Yan**

Harbin Medical University Fourth Hospital

**Zhenzhong Ai**

Harbin Medical University Fourth Hospital

**Jinzh Xu** (✉ [15104660282@139.com](mailto:15104660282@139.com))

Harbin Medical University Fourth Hospital

---

## Research

**Keywords:** Da Vinci® Xi system, Esophageal surgery, Modified Sweet operation—Benign and malignant diseases of esophagus, Preliminary experience

**Posted Date:** April 9th, 2020

**DOI:** <https://doi.org/10.21203/rs.3.rs-20638/v1>

**License:** © ⓘ This work is licensed under a Creative Commons Attribution 4.0 International License.

[Read Full License](#)

---

# Abstract

**Background** Since our hospital installed the DaVinci® Xi system, we have performed 60 thoracic surgeries in four months. As 25 of these 60 patients contain various types of esophageal benign and malignant diseases, we have no time to summarize our work after understanding and learning the experience of previous experts, so as to share our preliminary experience in using DaVinci® Xi system in esophageal surgery. Because robot surgery system is the most effective for small and hard to reach areas, we have made many attempts in benign esophageal diseases. Compared with DaVinci® Si, DaVinci® Xi has many new functions, so we explore new surgical methods for some special esophageal cancer cases, such as the robot assisted modified Sweet operation.

**Methods** Using DaVinci® Xi system(Intuitive Surgical, China), we performed robotic assisted thoracoscopic surgery (RATS) on 15 patients with esophageal cancer and 10 patients with various types of esophageal benign diseases. Among all esophageal cancer patients, 6 patients with lower esophageal cancer underwent resection of left thoracic esophageal cancer and lymphadenectomy, then diaphragm was cut, stomach was separated from abdominal cavity and lymphadenectomy was performed. Finally, 5 cases were anastomosed with stomach and esophagus under the aortic arch, and 1 case was anastomosed with stomach and esophagus in the neck combined with mediastinoscopic neck lymphadenectomy. McKeown was performed in 3 of the other 9 cases. Six patients underwent the Ivor Lewis operation, one of them was converted to the left thoracogastrostomy because of the extensive adhesion of the right thoracic cavity. Other benign diseases included esophageal leiomyomectomy in 3 cases, esophageal diverticulum in 1 case, hiatal hernia in 4 cases, esophageal cyst in 1 case, achalasia in 1 case.

**Results** All the procedures were successfully completed by robot except one patient with extensive adhesion of right thoracic cavity and only abdominal operation. The median operation time of esophageal cancer patients was 286±240-348 minutes, There were no complications during operation. One patient had a neck anastomotic leakage and the wound healed after local washing for 3 weeks. Because of the short time of observation, there is no death of malignant tumor and no serious complication of benign disease.

**Conclusions** Through the experience of such a small series of robotic assisted thoracoscopic surgery for various esophageal diseases, we support the impression that: 1. The esophagus is an ideal organ for robotic surgery, which is a good indication for malignant tumor surgery; 2. Under the vision of the robot, each layer of esophageal mucosa can be seen clearly, which is very conducive to the resection of small leiomyoma or cyst In addition, 3. Flexible arms can be used for various anastomosis or suture operations. 4. Through the left thorax and diaphragm incision can be used as a "robot" Sweet operation for the right patient, with mediastinoscopy to clean up the upper mediastinal lymph nodes can achieve better results.

## Introduction

It has been accepted by the vast majority of doctors to perform minimally invasive esophagectomy under the combination of thoracoscope and laparoscopy, and the clinical work is carried out with different proficiency. However, compared with da Vinci robot, thoracoscope and laparoscopy

surgery has many shortcomings, such as the field of vision is only two-dimensional plane, laparoscopic instruments only provide limited freedom of movement, with the disadvantages of limited movement, fulcrum effect [1] and increased physiological tremor [2]. The robot surgery system is developed to overcome these limitations.

Since our hospital installed the first DaVinci® Xi system in Northeast China in 2019, urologists have carried out the operation first, then applied it to gynecology and obstetrics, and then we have vigorously carried out this technology in thoracic surgery. In four months, we performed 60 thoracic operations, 25 of which included various types of esophageal benign and malignant diseases. In the short term, we have realized the advantages and technical characteristics of the robot system.

The high-resolution three-dimensional image of the Da Vinci robot system is helpful for detailed dissection during the operation. The omni-directional movement of multi joint instruments is helpful to complete complex surgical operations, such as suturing and internal knotting. Tremor filtering and motion scaling allow for more precise movements [3], such as organ and vascular anastomoses. This effectively reduces the surgical trauma, blood loss, hospital stay and mortality.

DaVinci® Xi system not only provides the above advantages, but also adds Firefly™ fluorescence imaging function. The technique can be used to evaluate the blood supply of the tubular stomach during the resection of esophageal cancer. Surgeons can use ICG to recognize the near-infrared fluorescence signal in the blood vessels in real time so as to predict the anastomotic leakage. This function can also be used in the development of thoracic duct to avoid chylous leakage, or it can track chylous leakage point after chylothorax. In addition, this function can also locate sentinel lymph nodes [4]. These functions are very important for esophageal cancer surgery.

On the other hand, compared with DaVinci® Si, Xi has a thinner arm, can provide a larger range of motion, and the instrument has a wider range of functions and can place ports more flexibly. The four overhead arm architecture allows multi quadrant access and can place the robot camera in any robot port. If necessary, you can easily switch between the surgical instrument and camera according to the surgical procedure. All of these functions should help simplify the complex procedure. These functions can greatly save the total operation time for the esophageal cancer operation with a large scope of operation.

## Patients And Methods

From September 2019 to January 2020, 25 patients with various esophageal diseases were treated with robot assisted minimally invasive therapy using DaVinci® Xi system(Intuitive Surgical, China). Obtain informed consent from all patients before using the DaVinci® Xi system. This group includes 15 patients

with esophageal cancer and 10 patients with various types of esophageal benign diseases. Before operation, all patients were examined by contrast-enhanced CT of chest and abdomen, color ultrasound of abdominal organs and SPECT. PET-CT was not performed routinely. Four cases of upper mediastinal lymph nodes were reported by chest enhanced CT. In all esophageal cancer patients, 6 patients with lower esophageal cancer underwent resection of esophageal carcinoma through left thoracotomy and lymph node dissection, then diaphragm was cut, stomach was separated in the abdominal cavity and left gastric lymph node and celiac lymph node dissection was performed. In 5 patients, the upper edge of tumor was below the plane of inferior pulmonary vein, so that we did not routinely clean the upper mediastinal lymph node, and finally the stomach and esophagus were anastomosed under the aortic arch; Another patient's chest enhanced CT showed 1.2cm lymph nodes in the upper mediastinum. We performed upper mediastinal lymph node dissection under mediastinoscopy, and then the stomach and esophagus were anastomosed in the neck, which we call robot based Sweet operation. In the other 9 cases, 3 cases underwent McKeown operation because of the visible lymph nodes in the upper mediastinum. In the other 6 cases, Ivor Lewis operation was performed, in which 1 case was converted to left thoracogastrostomy due to the extensive adhesion of the right thoracic cavity. Other benign diseases included esophageal leiomyomectomy in 3 cases, esophageal diverticulum in 1 case, hiatal hernia in 4 cases, esophageal cyst in 1 case, achalasia in 1 case. All patients were selected to ventilate the left or right lung by double lumen tracheal tube. After operation, they were awake in the operating room and pulled out the tracheal tube to return to the observation room of the thoracic surgery ward.

## **Operation of esophageal cancer**

### **Ivor Lewis or McKeown**

#### **Chest operation**

General anesthesia, double lumen endotracheal intubation, one lung ventilation, left lying position or side prone position. 4-hole method is adopted. First, an 8mm incision was made in the posterior axillary line of the 5th or 6th intercostal space. After thoracoscopic examination confirmed that there was no metastasis, an 8mm port was placed between the posterior axillary line of the 9th space and the scapular line, and another 8mm port was placed in the middle axillary line of the 3rd or 4th space. 5 cm auxiliary holes were set in the anterior axillary line of the seventh space. Then the robots dock.

In the case of McKeown's operation, the esophagus is free from the thoracic entrance to the esophageal hiatus, and the lymph nodes in the thoracic area are cleaned. The thoracic duct is ligated selectively. The azygos vein arch is cut off and the lymph nodes beside the recurrent laryngeal nerve are cleaned. If there is no obvious bleeding after thoracic surgery, a long tube like traction bag shall be reserved. The upper

end shall be sutured and tied at the top of the free esophagus, and the lower end shall be sutured and tied at the bottom. One 28F thoracic drainage tube was placed, and the anesthesiologist was instructed to suck sputum and expand the lung, and then the incision of thoracic operation was closed layer by layer.

If it's Ivor Lewis operation: free esophagus from the plane of azygos vein to the direction of esophageal hiatus, carry out lymph node dissection in the chest area, routinely disconnect the azygos vein, carry out lymph node dissection beside the bilateral recurrent laryngeal nerve, selectively ligate the thoracic duct, then cut the esophagus vertically under the planned gastroesophageal anastomosis, expose the lumen, place the anvil base of the anastomat, disconnect the esophagus, and make a purse stitch on the upper cut end of esophagus, knot and fix the anvil base of the stapler. The tube stomach was lifted from the esophageal hiatus to the thoracic cavity, and the tube stomach and the specimen were separated by ultrasonic knife. The specimens were taken out from the auxiliary incision, and then a 25 mm circular stapler was inserted. Indocyanine green (12.5mg) was injected intravenously to evaluate the blood supply of the gastric tube. The well blood supply of the tubular gastric region was selected as the anastomotic region, and the circular stapler was inserted into the chest cavity for intracavitary anastomosis. Endo Gia™ 60 mm gold load closes the incision in the upper part of the tubular stomach. After no obvious bleeding, wash the chest, place a 28F chest drainage tube through the 10th costal space, and ask the anesthesiologist to suck sputum and expand the lung, and then close the surgical incision layer by layer. Routine placement of nasogastric tube.

## Abdominal operation

In supine position, the pneumoperitoneum needle enters the abdominal cavity 8 mm above the umbilicus of the anterior midline. The camera is plugged into a 8mm port. After laparoscopy showed no metastatic disease, the remaining three ports were placed on the same line parallel to the navel (the left paramediastinal incision position, the left paramediastinal incision position and the right paramediastinal incision position). A 5 mm port was made at the lateral side of the right paramedian incision to insert the liver retractor. Endo Gia™ is placed in port the left paramediastinal incision position. The auxiliary port (also used for jejunostomy) is located in the median left incision. Then the robots dock.

Cut the gastrocolic ligament along the great curvature of the stomach, keep away from and protect the gastroepiploic vessels. A blood vessel occluder is used to clamp the short gastric vessels. Dissect the left and right phrenic feet. The esophagus is circled with a rubber ring for traction. The left gastric artery was exposed and dissected to the celiac artery. The seventh and ninth station of celiac lymph nodes were excised. The hepatic and splenic arteries were dissected and the tenth group of lymph nodes were cleaned. The left gastric artery was cut off with a vascular stapler. After transection of the abdominal esophagus, the Da Vinci mechanical arm was removed, and small incision on the right paramediastinal incision position was extended 3 cm under the costal arch to pull the stomach out of the abdominal cavity. EndoGIA was used to make the tubular stomach, and then it was sent back to the abdominal cavity to suture the small incision and recover the pneumoperitoneum.

In the case of Ivor Lewis operation, suture the upper end of the tubular stomach and the esophageal stump with two stitches in case of pulling the stomach to the chest during the following thoracic operation.

In the case of McKeown's operation, pull the traction bag reserved during the thoracic operation down to the abdominal cavity, sterilize the neck simultaneously, and make a left oblique incision at the inner boundary of sternocleidomastoid muscle. The hyoid muscle of scapula was routinely ligated and cut off. The cervical esophagus is exposed from the inside of the carotid sheath.

The left laryngeal reflux nerve was identified, protected and confirmed. After the cervical esophagus was completely free, the esophagus was cut 5cm below the circular pharyngeal muscle, and the distal esophagus which had been completely free during the thoracic operation was pulled out of the body from the neck, and the upper end of the reserved traction bag was pulled out of the neck. A long double joint instrument is inserted into the abdominal cavity from the neck traction bag, and the tube stomach is pulled from the abdomen without torsion to the neck incision with the help of laparoscopy, and the anastomosis is performed in the neck with manual suture technology or circular stapler. In the other group, pyloroplasty and jejunostomy were performed. The trocar was taken out from the auxiliary mouth, and we make a purse stitch with a 000 suture on the jejunal side wall 15 cm from the distal end of the Treitz ligament. Two stitches were sutured at the same time on the abdominal edge of the auxiliary mouth. The percutaneous puncture guide tube with guide wire of Kimberly Clark was inserted into jejunum from the auxiliary incision, the jejunum tube was placed, the guide wire was pulled out, the purse string was sewed in a circle, and the suture was at the edge of the auxiliary incision.

## **The Sweet surgery under the robot**

General anesthesia, double-lumen endotracheal intubation. The patient was placed in the right lateral decubitus position. First, an 8mm incision was made in the 5th intercostal space of the left midaxillary line as the first observation port. If thoracoscopy confirmed no evidence of metastasis, then, make an incision of about 8mm in the left anterior intercostal axillary line and the eighth intercostal axillary line on the left and place the electrocoagulation hook and bipolar forceps, respectively(Figure 1).

Place another 1cm port between the anterior axillary line and the midaxillary line of the third intercostal space as an auxiliary port. Then the robot is docked, and the docking direction is the operation area with the direction of diaphragm and abdominal cavity. The CO2 artificial pneumothorax pressure was set to 8 mm Hg.

Open the diaphragm through the liver and splenic sulcus and hang the diaphragm from the lateral chest wall with a silk thread(Figure 2A), explore the abdominal cavity, loosen the fibers of the side of the cardia, and free the cardia, and clean the lymph nodes next to the cardia, and then dissect the small curvature of the stomach to separate the liver and stomach ligament and skeletalize the left gastric blood vessel, clip

and disconnect the left gastric blood vessel with a single hemolock (Figure 2D), dissect the lymph nodes next to the left gastric blood vessel, then loosen the spleen and gastric ligament, dissect and disconnect the short gastric blood vessel (Figure 2C) Pull the gastric body upwards, loosen along the surface of the pancreas and sever the blood vessels behind the stomach, and continue to free the gastrocolonic ligament along the greater curvature of the stomach to the pylorus (Figure 2C), paying attention to retaining the right blood supply to the gastric omentum. After checking the abdominal cavity for no bleeding points, temporarily remove the robot arm.

A 5cm long incision was made on the left side of the 9th intercostal axillary line as the second auxiliary incision, and the incision protector was placed. The stomach was lifted to the outside of the body through the incision, and the stomach was unfolded to a untwisted state. The disposable straight-line cutting suture device was used to cut from the greater curvature side of the stomach at the bottom of the stomach to the lesser curvature side of the stomach, and a tubular stomach of suitable width was made, the diaphragm was closed, and the tubular stomach was lifted up as far as possible and sutured with the diaphragm foot for several stitches. A 8mm long incision was made on the left side of the 7th intercostal axillary midline for the second observation hole to put the robot camera system, and then the robot docking was carried out again. The direction of docking was in the direction of tracheal carina and upper mediastinum as the operation area.

If it is lower esophageal cancer and there is no metastasis of upper mediastinal lymph nodes in PET-CT before operation, free the esophagus upward to the level below the aortic arch, and clean the lymph nodes beside the esophagus and under the carina. Then cut the esophagus about 2 cm below the expected anastomosis plane, expose the lumen, place the stapler anvil base, disconnect the esophagus, A purse string suture was made at the broken end of esophagus by hand, and the anvil base of stapler was tied and fixed. Then, the specimens were taken out from the second auxiliary incision and a 25 mm circular stapler was placed. The blood supply of the gastric tube was evaluated by intravenous injection of indocyanine green (12.5mg). The well blood supply of the gastric tube was selected as the anastomotic area, and the circular stapler was placed into the chest cavity for intracavitary anastomosis. The linear cutting closure device closes the upper broken end of the tube stomach. After no obvious bleeding, wash the chest, place a 28F chest drainage tube through the second observation hole, and ask the anesthesiologist to suck sputum and expand the lung, and then close the surgical incision layer by layer. Routine placement of nasogastric tube.

In the case of upper and middle esophageal cancer, Dissection of esophagus is performed upward to the level behind the aortic arch, and clean the lymph nodes of the left upper mediastinum, the side of the esophagus and under the carina . Draw the esophagus from the back of the aortic arch to the upper mediastinum, reserve the second observation hole and the first auxiliary port in the chest, and suture the rest of the incision completely. The robot arm was removed after no bleeding was observed. Tilt the operating table back to 50 degrees, move the left upper limb from the head to the back, sterilize the neck and chest again, put the neck incision into the mediastinoscope, and clean the bilateral upper mediastinum and bilateral paralaryngeal recurrent nerve lymph nodes. Mediastinoscopy, assisted by

thoracoscopy, lifted the tubular stomach from the right side of the aortic arch to the left neck for manual or mechanical anastomosis.

### **Postoperative care**

Patients began tube feeding on the 3rd day after surgery and continued to take it until they were able to tolerate oral administration. All patients underwent upper gastrointestinal angiography on the 6th day after operation. If no leak is identified, the nasogastric tube of the patient will be stopped on the 7th day after the operation, and the patient will take pure liquid food for 1 day under the condition of limited volume, and gradually take soft food on the 8th to 9th day after the operation. The chest tube is usually removed 5 days after surgery. If a patient is diagnosed with delayed gastric emptying, they will be told to use gastric motility drugs, limit food intake or even fast water for a period of time until the function of the stomach is restored.

### **Esophageal leiomyoma (Figure 3)**

The position and direction of the observation port and the mechanical arm should be selected according to the position of the tumor. For larger leiomyomas, the Da Vinci robot can easily find and safely remove them. The detailed display of three-dimensional high-definition can remove leiomyoma from esophageal mucosa accurately. Our experience is that if the tumor is on the left side of the esophagus, unless it is on the right side of the aortic arch, the robot can put the instrument from the left chest, which can avoid the excessive free range of the esophagus after the instrument is placed from the right chest, and avoid the overturning of the esophagus. If the tumor is on the front side or the back side or the right side of the esophagus, it is very convenient to put the instrument from the right chest. Esophagoscopy must be performed at the same time in both groups. Some patients were found to have a small leiomyoma under the esophageal mucosa, but they were afraid of complications due to endoscopic treatment, or they also suffered from achalasia or hiatal hernia and received minimally invasive robot surgery. At this time, it is very necessary to cooperate with two endoscopes to find the tumor during the operation. Esophagoscopy can accurately locate the tumor location, and the robot can quickly find the location from the outside through the touch from the esophageal cavity. After three-dimensional magnification, mm level leiomyoma can be clearly displayed and safely removed. After resection, air blowing test should be carried out to confirm the integrity of esophageal mucosa.

### **Achalasia and hiatal hernia(Figure4)**

With the help of robots, these two diseases can be easily carried out through the thoracic cavity, especially when the hiatal hernia is large and combined with short esophagus, or when these two

diseases are combined with esophageal diverticulum or leiomyoma, it is very difficult to operate through the abdominal cavity. A 1cm long incision was made in the 5th intercostal space of the left axillary midline as the first observation port. Then, the electrocoagulation hook and bipolar forceps were respectively placed in the front of the axillary line of the 5th intercostal space and the posterior line of the axillary line of the 8th intercostal space with a length of about 8mm. If necessary, the bipolar inlay was replaced with a needle holder. Another 1cm port was placed between the axillary front and the axillary midline of the third intercostal space as the auxiliary port. Then the robot docking, docking direction in the direction of diaphragm and abdominal cavity as the operation area. Flexible suture and stripping are very conducive to myotomy and organ suture, which has a great advantage compared with thoracoscopic surgery.

### **Esophageal diverticulum**Figure 5

The robot docking is the same as the cardia achalasia the auxiliary port is placed with a device to pull the esophagus with a belt, and the esophagus is turned according to the position. The diverticulum is freed to the neck of diverticulum using the electric hook, and the muscularis of the diverticulum neck is cut layer by layer to the submucosa, and then the diverticulum was removed with a cutting closure. The transverse smooth muscle bundles at the lower end of the mucosal incision margin were cut off, and the longitudinal smooth muscle was sutured for several stitches to embed the mucosal stump. No leaks were found during endoscopy. Remove the robotic arm and release the drainage tube.

### **Esophageal cyst**Figure 6

Robot docking is the same as achalasia, but no auxiliary port is needed. The diameter of the lesion was about 5 cm, which was located in the lower part of the esophagus of the costal sinus of the posterior diaphragm. For better exposure, the middle of the diaphragm is fixed to the chest wall and the lung ligament is separated with a cauterizing hook. The cyst was separated from the adjacent muscle tissue, removed, and finally removed from the pouch (Fig. 4). Again, the muscle layer of the esophagus is repaired by a single stitch fashion.

## **Results**

All procedures were completed entirely using the da Vinci robotic system. In the four cases of oncologic esophageal dissection the median overall operating time was 173 (160–190) minutes and the median time for the surgeon working at the robotic console (console time) was 147 (135–160) minutes. In the two benign cases the median overall operating time was 121 minutes and the median console time was 94 minutes. The times for each procedure are listed in [Table 1](#). There was no relevant intraoperative blood

loss in any of the patients, and no surgical complications occurred. The robotic system itself did not experience any technical failure.

There was no serious accident during the operation leading to conversion to thoracotomy. The robot system itself has not encountered any technical failure. After abdominal operation, a patient with esophageal cancer who was preparing for Ivor Lewis operation found extensive adhesion in the right chest during the exploration of thoracic operation, and underwent left thoracotomy for gastroesophageal anastomosis.

The median operation time of Sweet esophageal cancer patients was 265–240–290 minutes, that of Ivor Lewis esophageal cancer patients was 300–282–348 minutes, and that of benign patients was 90 minutes. One Sweet patient had a neck anastomotic leakage, and the wound healed after local washing for 3 weeks. Because of the short time of observation, there is no death of malignant tumor and no serious complication of benign disease.

We compared the Sweet operation in which the stomach and esophagus anastomosed under the aortic arch in 5 cases with the Ivor Lewis operation in 6 cases (Table 1). All esophageal cancer patients were squamous cell carcinoma, no positive findings were found at the cut end of the tumor. The average hospital stay of benign patients was 6 days, and the pathological results were esophageal leiomyoma and esophageal cyst, respectively. There were no symptoms of esophageal reflux and dysphagia in patients with hiatal hernia. Ten days after the operation, there was no esophageal fistula and no dysphagia.

## Discussion

Da Vinci ® Xi system has been introduced into China for less than 2 years. Within half a year since it was introduced into our hospital, we have reported such a small sample study to preliminarily explore whether Da Vinci ® Xi is more conducive to esophageal surgery than previous thoracoscopic surgery or Da Vinci ® Si.

Due to the three-dimensional and ten times magnified field of vision, as well as the increase of freedom and flexibility, Da Vinci ® system greatly improves the ability of surgeons to dissect and manually anastomose. Although there is a high clinical cost, RAMIE technology is better than open esophagectomy in reducing postoperative complications, shortening hospital stay and improving quality of life. Compared with thoracoscopic minimally invasive surgery for esophageal cancer, RAMIE can be easily sutured by hand for intrathoracic anastomosis, and can dissect the recurrent laryngeal nerve in detail, which can easily reach the upper thoracic entrance and operate on tumors and involved lymph nodes in the upper mediastinum [5].

In the aspect of intrathoracic anastomosis, compared with laparoscopy, the multi-directional and flexible range of motion of robot makes manual suture more easy and feasible. Although it has been reported in the past that mechanical anastomotic method increase the risk of anastomotic stenosis [6,7], van der

Sluis PC et al. [8] found that robot intrathoracic anastomotic treatment of esophageal or gastroesophageal junction cancer is technically feasible and safe, and postoperative complications and short-term oncology results can be compared with the highest international standards. In our series, although we still use the mechanical anastomotic method in the Ivor Lewis operation and Sweet operation, we find it difficult to insert the purse tongs into the chest under the condition of robot operation, especially when the anastomotic plane is under the aortic arch or at the top of the pleura. So we take advantage of the advantages of manual suture by robot, and carry out manual suture on the upper cut end of esophagus conveniently. Then we put the anvil of stapler base into it and ligate the suture. Then we put the circular stapler from the 5cm auxiliary mouth for intrathoracic anastomosis, which is similar to the circular suture described by Victor et al. [9].

Although it has been reported that robot assisted recurrent laryngeal nerve chain lymph nodes lymphadenectomy is not safe [10], and has no advantage over open surgery in tumor prognosis [11], Chen j et al. [12], Deng et al. [13] and Li Xu et al. [14] found that RAMIE has a definite advantage in lymphadenectomy without increasing the risk of major postoperative complications. Our preliminary experience is that robot operation can provide more thorough and high-quality lymphadenectomy. Even the Sweet operation we explored can complete the lymphadenectomy of esophageal cancer with the help of mediastinoscopy. In addition, use Da Vinci ® Xi's Firefly™ fluorescence imaging function can not only ensure the good blood supply of the anastomotic site, but also conveniently identify the sentinel lymph nodes during the operation.

The top arm of Da Vinci ® Xi allows for multi quadrant surgery. When the robot esophagectomy is performed, without changing the position of the robot cart, only changing the direction of the mechanical arm can quickly switch the operation fields of abdominal operation and chest operation, which is a very useful advantage for the minimally invasive operation of esophageal cancer that can reach the neck from the abdominal cavity. Wang et al. [13] found that with the help of mediastinoscopy and with the help of mediastinoscopy, Sweet operation had a good effect on the removal of mediastinal and RLN lymph nodes. Inspired by this, we performed robot assisted left chest sweet operation on the lower esophageal cancer, and performed upper mediastinal lymph node dissection with robot and mediastinoscope on one of the patients. After the lymph nodes were cleaned, gastroesophageal neck anastomosis was performed. We compared Sweet operation with Ivor Lewis operation with a few samples. Although there is no definite conclusion, we found that Sweet group has some advantages in saving operation time, reducing intraoperative bleeding, reducing postoperative pain and reducing postoperative drainage. However, since we did not perform mediastinoscopic upper mediastinal lymph node dissection for every Sweet patient, the average number of lymph nodes in Ivor Lewis group was 2 more than sweet group. We focused on the respiratory status of patients in sweet group, and did not find complications such as dyspnea due to diaphragm incision, which may be due to the fact that when we cut the diaphragm, we only cut the central bond of diaphragm without damaging the muscle and nerve tissue. Sweet operation can cut off the tissue around the cardia, the short gastric vessels and the gastocolic ligaments quickly when the abdominal cavity is free. After pulling the stomach to the chest, it can clearly leak the left gastric artery and the main celiac artery. There is no obstacle for the lymph node cleaning of groups 7, 9 and 10.

Although Da Vinci ® Xi has reached an unprecedented level in the field of vision and multi-dimensional flexibility of the instrument, there are still many shortcomings to be overcome in the left chest Sweet operation. We assume that if it's a large esophageal tumor that adheres to the aortic arch, we can only have Ivor Lewis or McKeown surgery. If there is no such situation, other difficulties will be easily overcome after our initial attempt. With regard to the dissection of the upper mediastinal lymph nodes, we can dissect and clean the lymph nodes of the upper esophageal triangle as much as possible with the help of a robot. At this time, the aortic arch is covered with an elastic band to pull it to the left properly, and the esophagus can be easily dissociated in the right part of the aorta. After the robot completes the chest operation, remove the mechanical arm and sterilize the neck. At this time, just tilt the patient's body position to 60 degrees to the left, place the patient's outstretched upper limbs on the left side of the patient's body, that is, before the neck anastomosis, use the mediastinoscope to insert the upper mediastinum from the neck incision, and explore and remove the RLN lymph nodes in the upper mediastinum. Then, the tube stomach was lifted up to the neck by hand with the help of a robotic camera.

Despite McKeown's surgery or Ivor Lewis operation is the mainstream operation method at present, but due to the advantages of robot assisted Sweet operation, such as no need to change the body position, save the incision of the whole body, save the personnel in the abdominal operation group, and more convenient for the treatment of the cardia and left gastric artery, this operation method can at least be applied to the following situations: 1. When the right chest is widely adhered; 2. Doctors familiar with Sweet operation method, Before the operation, there were no imaging findings in the upper mediastinal lymph nodes; 3. Cardiac cancer; 4. Other special cases, such as simultaneous left lung cancer [15,16]. Of course, if the mediastinoscopy can be used to stage and clean the upper mediastinal lymph nodes before the operation, or the mediastinoscopy can be used for supplementary cleaning when the neck is anastomosed, then this operation can be used more.

For the resection of benign lesions in the esophageal wall, the enhanced three-dimensional view can clearly distinguish the anatomical layers of the esophageal wall, and the larger movements of the hand are transformed into precise surgical operations by the robot, which reduces the risk of mucosal perforation to the lowest, which is conducive to the safe dissection of fine anatomical structures. Our case includes a leiomyoma, the most common benign stromal esophageal tumor. At present, the standard treatment is open local resection, endoscopic resection for small leiomyoma is also vigorously carried out in the internal medicine. Because the traditional thoracoscopic surgery is very difficult to remove the small tumor, [17, 18, 19, 20], so many patients received endoscopic treatment, but this method because of the destruction of the esophageal mucosa, the possibility of esophageal fistula, once the emergency surgery is needed, it brings great danger. Robot assisted enucleation of intramural tumors can be performed without damaging the mucosa. In the operation of esophageal diverticulum, we can strip the muscular layer of the neck of the diverticulum layer by layer under the robot, and then close the mucous membrane and muscular layer by layer to avoid esophageal fistula.

Although most of the esophageal hiatal hernia has been operated by laparoscopy, and even a large hernia can be repaired by robot in the abdominal cavity [21], for the doctors who are familiar with intrathoracic hernia repair in the past, although it is difficult to perform transthoracic hernia repair with thoracoscopy in the past, it can be completed well with the help of robot. Robot assisted cardiac achalasia RAHD (robotic assisted Heller Dor procedure) operation ensures the delicacy of esophagotomy with low incidence of intraoperative and postoperative complications. Although robot technology does increase the cost of hand operation in the treatment of these functional esophageal diseases, it can also bring good clinical, imaging and functional results. We operated on this disease by transthoracic robot, also because we were very familiar with Heller Dor operation under thoracoscopy [22].

## Conclusion

Robot assisted thoracoscopic surgery (RATS) for esophageal diseases is becoming an important assistant means of complex thoracoscopic surgery [17, 23, 24, 25, 26]. Our experience in Da Vinci® Xi with robotics has significant advantages over VATS in the treatment of various esophageal diseases. In the future, we will continue to evaluate the efficacy and potential of RATS in the future with the summary of a large number of cases.

## Declarations

### Acknowledgements

None

### Funding

None

### Availability of data and materials

The raw data were collected and analyzed by the authors and are not ready to share their data because the data have not been published

### Authors' contributions

Jinzhi Xu and Bei Lu participated in the design of this study, and they all performed the statistical analysis. Lixin Sun, Zhonghao Wang and Xi Yan carried out the study and collected important background information. Bei Lu and Zhenzhong Ai drafted the manuscript. All authors read and approved the final manuscript.

### **Ethics approval and consent to participate**

This study was approved by the ethical committee of The Fourth Affiliated Hospital of Harbin Medical University

### **Consent for publication**

Not applicable

### **Competing interests**

The authors declare that they have no competing interests.

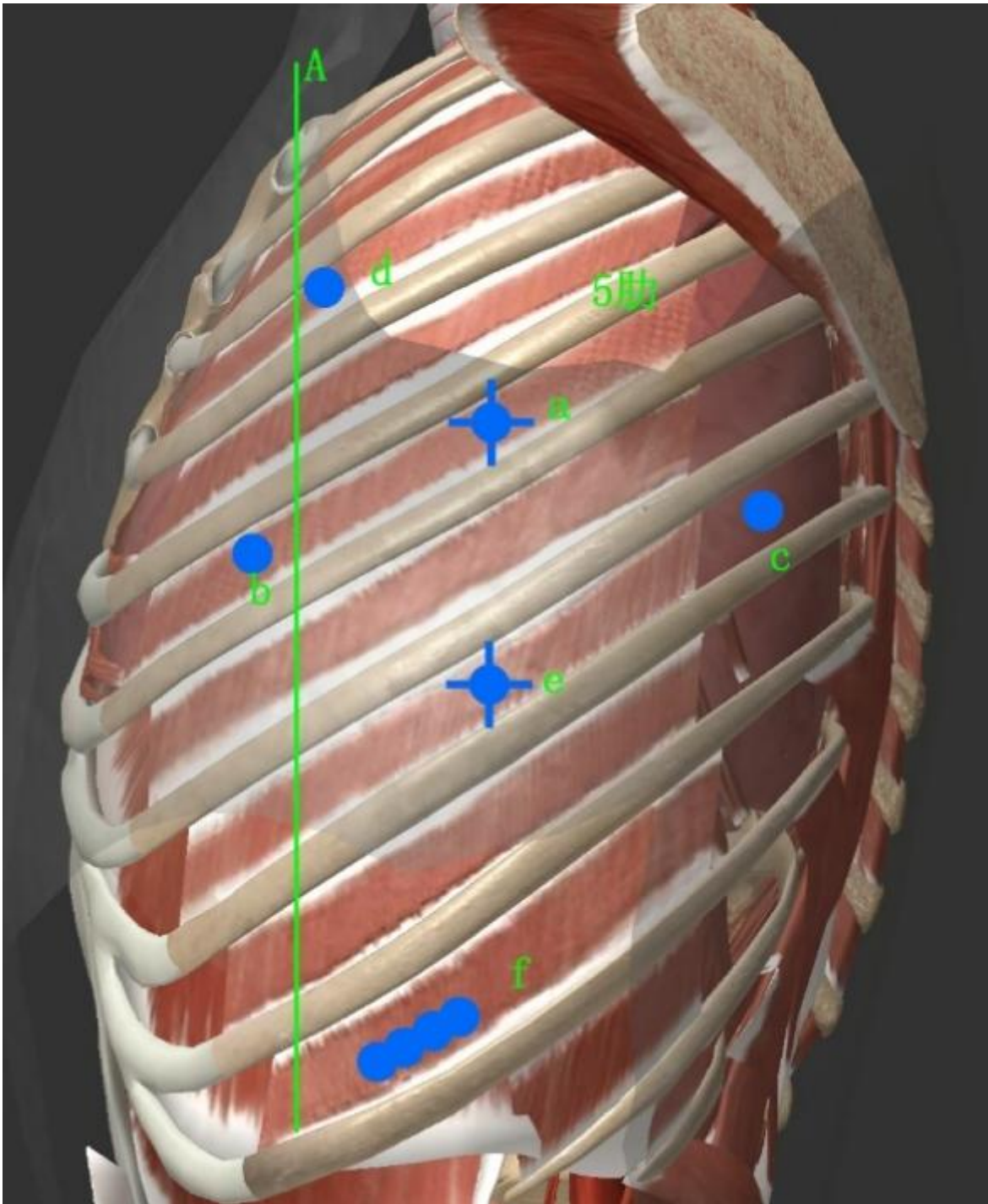
## **References**

1. Gallagher A G, McClure N, McGuigan J, et al. An ergonomic analysis of the fulcrum effect in the acquisition of endoscopic skills[J]. Endoscopy, 1998, 30(07): 617-620.
2. Lanfranco A R, Castellanos A E, Desai J P, et al. Robotic surgery: a current perspective[J]. Annals of surgery, 2004, 239(1): 14.
3. Lanfranco A R, Castellanos A E, Desai J P, et al. Robotic surgery: a current perspective[J]. Annals of surgery, 2004, 239(1): 14.
4. Bae S U, Baek S J, Hur H, et al. Intraoperative near infrared fluorescence imaging in robotic low anterior resection: three case reports[J]. Yonsei medical journal, 2013, 54(4): 1066-1069.
5. Kingma B F, de Maat M F G, van der Horst S, et al. Robot-assisted minimally invasive esophagectomy (RAMIE) improves perioperative outcomes: a review[J]. Journal of thoracic disease, 2019, 11(Suppl 5): S735.

6. Kayani B, Garas G, Arshad M, et al. Is hand-sewn anastomosis superior to stapled anastomosis following oesophagectomy?[J]. *International Journal of Surgery*, 2014, 12(1): 7-15.
7. CASTRO P M V, RIBEIRO F P G, ROCHA A F, et al. Hand-sewn versus stapler esophagogastric anastomosis after esophageal resection: systematic review and meta-analysis[J]. *ABCD. Arquivos Brasileiros de Cirurgia Digestiva (São Paulo)*, 2014, 27(3): 216-221.
8. van der Sluis P C, Tagkalos E, Hadzijušević E, et al. Robot-Assisted Minimally Invasive Esophagectomy with Intrathoracic Anastomosis (Ivor Lewis): Promising Results in 100 Consecutive Patients (the European Experience)[J]. *Journal of Gastrointestinal Surgery*, 2020: 1-8.
9. Plat V D, Stam W T, Schoonmade L J, et al. Implementation of robot-assisted Ivor Lewis procedure: Robotic hand-sewn, linear or circular technique?[J]. *The American Journal of Surgery*, 2019.
10. He H, Wu Q, Wang Z, et al. Short-term outcomes of robot-assisted minimally invasive esophagectomy for esophageal cancer: a propensity score matched analysis[J]. *Journal of cardiothoracic surgery*, 2018, 13(1): 52.
11. Chen J, Liu Q, Zhang X, et al. Comparisons of short-term outcomes between robot-assisted and thoraco-laparoscopic esophagectomy with extended two-field lymph node dissection for resectable thoracic esophageal squamous cell carcinoma[J]. *Journal of thoracic disease*, 2019, 11(9): 3874.
12. Van der Sluis P C, Ruurda J P, Verhage R J J, et al. Oncologic long-term results of robot-assisted minimally invasive thoraco-laparoscopic esophagectomy with two-field lymphadenectomy for esophageal cancer[J]. *Annals of surgical oncology*, 2015, 22(3): 1350-1356.
13. Deng H Y, Luo J, Li S X, et al. Does robot-assisted minimally invasive esophagectomy really have the advantage of lymphadenectomy over video-assisted minimally invasive esophagectomy in treating esophageal squamous cell carcinoma? A propensity score-matched analysis based on short-term outcomes[J]. *Diseases of the Esophagus*, 2019, 32(7): 110.
14. Li X, Wang W, Zhou Y, et al. Efficacy comparison of transcervical video-assisted mediastinoscopic lymphadenectomy combined with left transthoracic esophagectomy versus right transthoracic esophagectomy for esophageal cancer treatment[J]. *World Journal of Surgical Oncology*, 2018, 16(1): 25.
15. Wang W, Zhang B, Li X, et al. Minimally invasive esophagectomy via Sweet approach in combination with cervical mediastinoscopy for esophageal squamous cell carcinoma: a case series[J]. *International journal of surgery. Oncology*, 2017, 2(11): e45.
16. Zhang B, Ma J, Yan X, et al. Left minimally invasive esophagectomy in a patient with synchronous esophageal and lung cancers: Case report[J]. *Medicine*, 2018, 97(2).
17. Elli E, Espat N J, Berger R, et al. Robotic-assisted thoracoscopic resection of esophageal leiomyoma[J]. *Surgical Endoscopy And Other Interventional Techniques*, 2004, 18(4): 713-716.

18. Bonavina L, Segalin A, Rosati R, et al. Surgical therapy of esophageal leiomyoma[J]. Journal of the American College of Surgeons, 1995, 181(3): 257-262.
19. Swanstrom L L, Hansen P. Laparoscopic total esophagectomy[J]. Archives of Surgery, 1997, 132(9): 943-949.
20. Roviato G C, Maciocco M, Varoli F, et al. Videothoracoscopic treatment of oesophageal leiomyoma[J]. Thorax, 1998, 53(3): 190-192.
21. Tartaglia N, Pavone G, Di Lascia A, et al. Robotic voluminous paraesophageal hernia repair: a case report and review of the literature[J]. Journal of Medical Case Reports, 2020, 14(1): 1-6.
22. Pallabazzer G, Peluso C, de Bortoli N, et al. Clinical and pathophysiological outcomes of the robotic-assisted Heller–Dor myotomy for achalasia: a single-center experience[J]. Journal of robotic surgery, 2019: 1-5.
23. Shah J, Rockall T, Darzi A. Robot-assisted laparoscopic Heller's cardiomyotomy[J]. Surgical Laparoscopy Endoscopy & Percutaneous Techniques, 2002, 12(1): 30-32.
24. Gould J C, Melvin W S. Telerobotic foregut and esophageal surgery[J]. The Surgical clinics of North America, 2003, 83(6): 1421-1427.
25. Hollands C M, Dixey L N. Robotic-assisted esophagoesophagostomy[J]. Journal of pediatric surgery, 2002, 37(7): 983-985.
26. Hashizume M, Shimada M, Tomikawa M, et al. Early experiences of endoscopic procedures in general surgery assisted by a computer-enhanced surgical system[J]. Surgical Endoscopy and Other Interventional Techniques, 2002, 16(8): 1187-1191.

## Figures



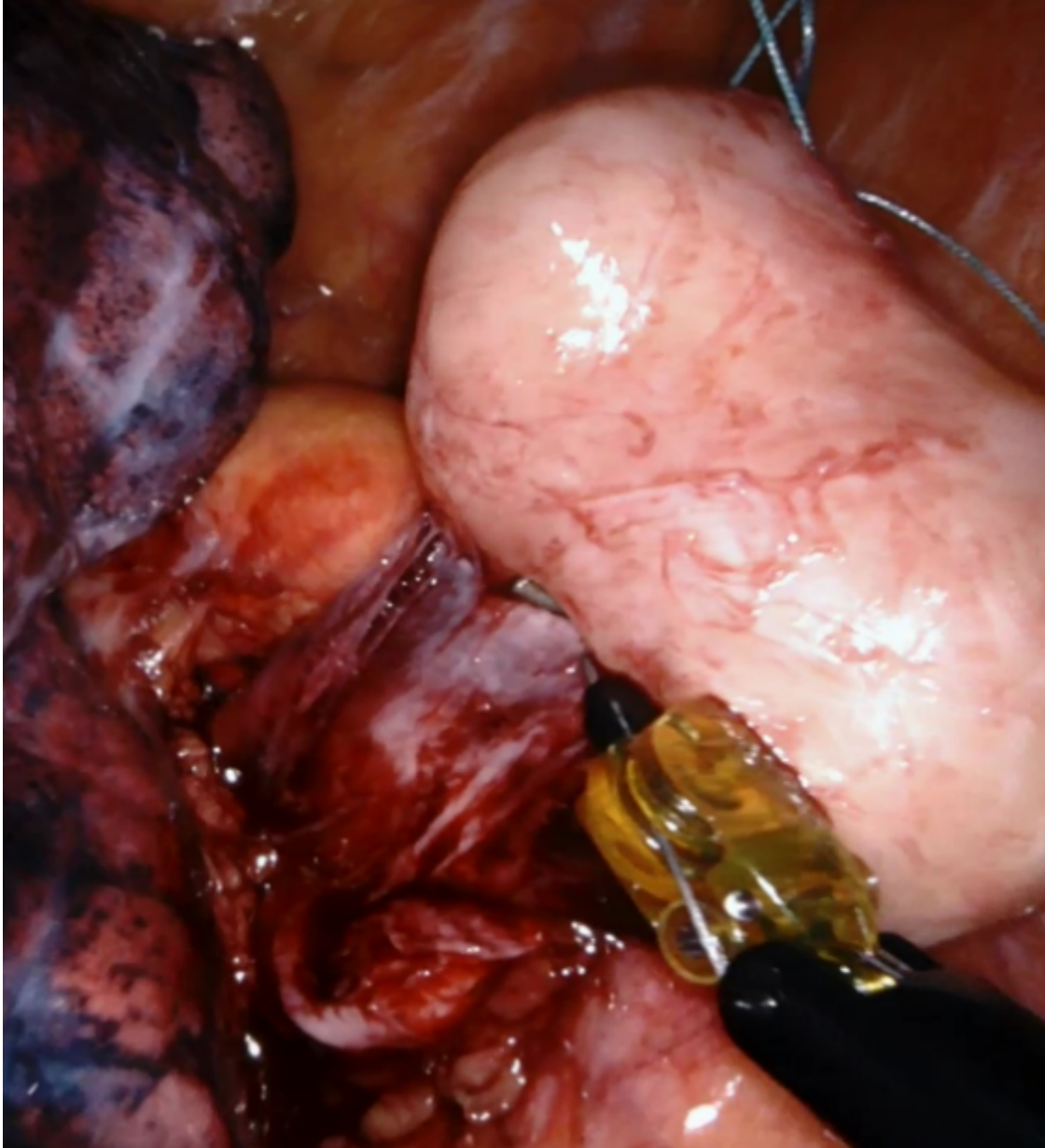
**Figure 1**

Schematic diagram of robot assisted Sweet operation incision: a: the first observation port; e: the second observation port; d: the first auxiliary port; F: the second auxiliary port; b, c: the manipulator operation port.



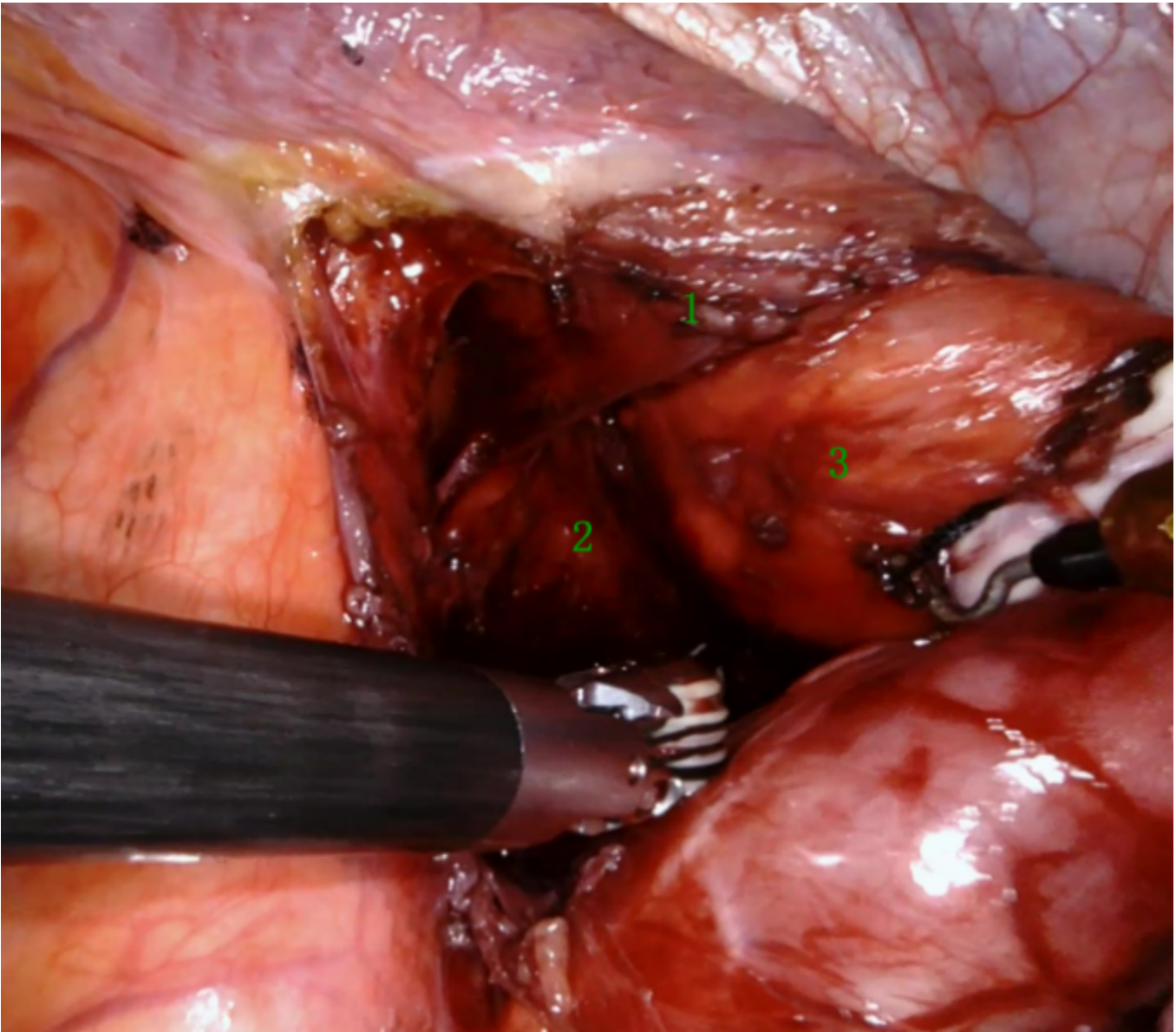
**Figure 2**

robot assisted sweet operation: A: incision from the central key of diaphragm; B: treatment of short gastric artery; C: treatment of gastrocolic ligament; D: treatment of left gastric artery.



**Figure 3**

Esophageal leiomyoma,robotic-assisted thoracoscopic surgery–resection.



**Figure 4**

esophageal hiatal hernia, robot assisted thoracoscopic surgery. 1: Left phrenic foot; 2: right phrenic foot; 3: cardia.



**Figure 5**

esophageal diverticulum, robot assisted thoracoscopic surgery. A: The diverticulum was lifted after dissociation; B: closed by cutting and closing device; C: closed mucosal end; D: layered suture of esophageal wall.



**Figure 6**

esophageal cyst, robot assisted thoracoscopic surgery. A: Free cyst; B: free to the neck of cyst. a Time from anesthesia intubation to extubation. Table 1. Primary comparison of operative time and postoperative evaluation between Sweet and Ivor Lewis