

# Interventricular septal curvature as an additional echocardiographic parameter for evaluating chronic thromboembolic pulmonary hypertension: A single-center retrospective study

**Akane Matsumura**

Chiba University

**Ayako Shigeta** (✉ [aya0107@chiba-u.jp](mailto:aya0107@chiba-u.jp))

Chiba University

**Hajime Kasai**

Chiba University

**Hajime Yokota**

Chiba University

**Jiro Terada**

International University of Health and Welfare Narita Hospital

**Keiko Yamamoto**

Chiba University

**Toshihiko Sugiura**

Chiba University

**Takuma Matsumura**

Chiba University

**Seiichiro Sakao**

Chiba University

**Nobuhiro Tanabe**

Chibaken Saiseikai Narashino Hospital

**Koichiro Tatsumi**

Chiba University

---

## Research Article

**Keywords:** chronic thromboembolic pulmonary hypertension (CTEPH), Interventricular septal curvature, sPAPRHC

**Posted Date:** February 17th, 2021

**DOI:** <https://doi.org/10.21203/rs.3.rs-199528/v1>

**License:**  This work is licensed under a Creative Commons Attribution 4.0 International License.

[Read Full License](#)

---

# Abstract

Background: Noninvasive estimation of the actual systolic pulmonary artery pressure measured via right-sided heart catheterization ( $sPAP_{RHC}$ ) is important for the management of pulmonary hypertension, including chronic thromboembolic pulmonary hypertension (CTEPH). Evaluation related to the interventricular septum (IVS) is generally performed with only visual assessment and has been rarely assessed quantitatively in the field of echocardiography. Thus, this study aimed to investigate the utility of echocardiographic IVS curvature to estimate  $sPAP_{RHC}$  in patients with CTEPH.

Methods: Data of 72 patients with CTEPH were studied retrospectively. We estimated  $sPAP_{RHC}$  using echocardiographic IVS curvature ( $esPAP_{CURV}$ ) and left ventricular eccentricity index ( $esPAP_{LVEI}$ ), and compared their ability to predict  $sPAP_{RHC}$  with estimated  $sPAP_{RHC}$  using tricuspid regurgitant pressure gradient ( $esPAP_{TRPG}$ ).

Results: IVS curvature and LVEI were significantly correlated with  $sPAP_{RHC}$  ( $r = -0.52$  and  $r = 0.49$ , respectively). Moreover, the IVS curvature was effective in estimating the  $sPAP_{RHC}$  of patients with trivial tricuspid regurgitation ( $r = -0.56$ ) and in determining patients with  $sPAP_{RHC} \geq 70$  mmHg with higher sensitivity (77.0%) compared to those with  $esPAP_{TRPG}$  and  $esPAP_{LVEI}$ .

Conclusion: Our results indicate that the echocardiographic IVS curvature could be a useful additional tool for estimating  $sPAP_{RHC}$  in CTEPH patients in whom accurate estimation of  $sPAP_{RHC}$  using tricuspid regurgitant pressure gradient is difficult.

## Introduction

Chronic thromboembolic pulmonary hypertension (CTEPH) is caused by untreated thromboembolism of the pulmonary arteries, leading to right ventricular afterload, progression of pulmonary hypertension (PH), and life-threatening right heart failure[1]. For diagnosis of PH, pulmonary artery pressure measurement using right-sided heart catheterization (RHC) is considered the gold standard, but receiving RHC is not easy because of the invasiveness of the procedure. Echocardiography is noninvasive and is routinely used for patients with suspected or confirmed PH to manage their treatment.

Tricuspid regurgitant pressure gradient (TRPG) measured using echocardiography is one of the most reliable parameters for predicting actual systolic pulmonary arterial pressure measured using RHC ( $sPAP_{RHC}$ ). Therefore, TRPG is widely used for the management of patients with PH in clinical practice including CTEPH. However, we sometimes encounter PH patients in whom the systolic pulmonary arterial pressure estimated using TRPG ( $esPAP_{TRPG}$ ) clearly differs from the  $sPAP_{RHC}$ , resulting in critical management errors. One reason for this discrepancy (i.e., between  $esPAP_{TRPG}$  and  $sPAP_{RHC}$ ) is that  $esPAP_{TRPG}$  depends on the degree of the angle between the tricuspid regurgitation (TR) jet and Doppler beam[2]. Another possible reason is that some patients have too trivial TR to measure TR velocity,

resulting in seemingly normal TRPG values. Previous studies reported that  $esPAP_{TRPG}$  may be significantly underestimated in some patients with severe PH because the modified Bernoulli equation cannot be used in such cases[3-5]. Thus,  $esPAP_{TRPG}$  cannot always be useful for evaluating the severity of PH. Therefore, other echocardiographic components are required for better management of patients with unreliable TRPG.

The 2015 European Society of Cardiology/European Respiratory Society (ESC/ERS) guidelines suggested grading the probability of PH based not only on TRPG but also on additional prespecified echocardiographic variables including left ventricular eccentricity index (LVEI) which is one of the parameters used to quantify the flattening of the interventricular septum (IVS)[5]. The IVS curvature is also the parameter used to quantify IVS configuration. In the 1980s, King et al. first showed moderately high correlation between the IVS curvature on echocardiography and right ventricular systolic pressure qualitatively in children with congenital cardiac disorders[6]. Studies on cardiac computed tomography (CT) and magnetic resonance imaging (MRI) have shown that quantified values of the IVS curvature correlate well with  $sPAP_{RHC}$  in patients with PH including CTEPH[7-9]. In routine clinical echocardiography, most examiners check IVS displacement in addition to TRPG measurements to predict the severity of PH. However, evaluation related to the IVS is generally performed with visual assessment alone and has been rarely assessed quantitatively in the field of echocardiography.

With the above background, this study aimed [1] to investigate the correlation between the echocardiographic IVS curvature and  $sPAP_{RHC}$  in CTEPH patients and [2] to evaluate the diagnostic performance of the IVS curvature in patients in whom accurate estimation of  $sPAP_{RHC}$  based on TRPG is difficult due to trivial TR and severe PH. We hypothesized that the IVS curvature could be a good echocardiographic parameter in addition to TRPG for evaluating  $sPAP_{RHC}$  in CTEPH patients especially with unreliable TRPG.

## Methods

### *Study subjects*

In this single-center retrospective study, we enrolled adult patients with suspected CTEPH diagnosed at Chiba University Hospital between August 2012 and July 2019. Registrations were consecutively conducted at each patient's first diagnostic investigation at the PH Clinics in our hospital (if consent to participate in our study was given). Patients with arrhythmias (n = 5), history of pulmonary endarterectomy (n = 27), and other cases (n = 5) regarded as conditions affecting IVS motion were excluded. No patient had complex congenital heart disease, history of myocardial infarction, intracardiac shunt, left ventricular hypertrophy, more than mild left-sided valvular regurgitation, prosthetic valves, valvular stenosis, or wall-motion abnormalities. After excluding 37 patients, we enrolled 72 patients ( $59.7 \pm 1.5$  years; 51 females) with proven CTEPH.

### *Clinical assessment*

Diagnosis of CTEPH was established based on clinical guidelines valid at study initiation[10]. In brief, PH was confirmed with RHC indicating mean pulmonary artery pressure  $\geq 25$  mmHg at rest and pulmonary capillary wedge pressure  $\leq 15$  mmHg. CTEPH was defined as abnormalities on a ventilation-perfusion scan and pulmonary angiography. All patients received anticoagulants and underwent two-dimensional and Doppler echocardiography as well as RHC. The time between RHC and echocardiography was less than 48 h. No hemodynamic manipulation was performed, and no changes were made to medication or oxygen therapy in the interim.

### *RHC*

A 7.5-F Swan-Ganz thermodilution catheter (Edwards Lifesciences LLC, Irvine, CA) was used, and a jugular approach was preferred. Pressure measurements were taken from the right atrium, right ventricle, and main pulmonary artery at end expiration. Cardiac output was determined using the thermodilution method averaging a minimum of three measurements. Left-to-right shunting was ruled out using oximetry. All invasive variables were recorded blinded to the echocardiography.

### *Echocardiography*

Complete echocardiography and Doppler echocardiography evaluations were performed using a commercially available system (Aplio300, Toshiba, Japan) with a 2.5-MHz transducer, in multiple views with patients in the spine or left lateral decubitus position. All echocardiographic examinations were performed by one of the three senior pulmonologists (AM, AS, and HK with 3-, 8-, and 8-year subspecialty training, respectively, in echocardiography as a part of routine clinical practice). Doppler echocardiography was performed in multiple views to obtain the optimal TR jet. After acquiring necessary images, TR velocity was measured in real time, and  $esPAP_{TRPG}$  was determined using the modified Bernoulli equation  $TRPG = 4 \times (TR \text{ velocity})^2$ , in conjunction with the echocardiographic estimation of the right atrial pressure. The estimated right atrial pressure was calculated based on the size and collapsibility of the inferior vena cava (IVC) and on the following established criteria. In brief, the estimated right atrial pressure was defined as 3 mmHg when the IVC diameter was  $\leq 21$  mm and collapsing  $>50\%$ ; 8 mmHg when the IVC diameter was  $\leq 21$  mm and collapsing  $<50\%$  or IVC diameter  $>21$  mm and collapsing  $>50\%$ ; and 15 mmHg when the IVC diameter was  $>21$  mm and collapsing  $<50\%$ [11].

### *Measurement of LVEI and IVS curvature*

Imaging data were stored digitally for off-line analyses. The LVEI and IVS curvature were obtained from the same compiled off-line images, which were the standard parasternal short-axis plane of the left ventricle at end systole, defined as the frame with the smallest short axis. Based on a method for the measurement of the IVS curvature in a previous study using cardiac CT[7], we set the left ventricular papillary muscle level as suitable to obtain images for the LVEI and IVS curvature.

LVEI was measured as the ratio of the major axis of the left ventricle parallel to the septum (D2) divided by the minor axis perpendicular to the septum (D1)[3, 12]. The IVS curvature was measured in views

showing the endocardial surface of the left ventricle at the papillary muscle level at end systole. As shown in Fig. 1, three different points at the posterior (a), middle (b), and anterior (c) positions of the interventricular septum were marked, and the X and Y coordinates were recorded at these three points using ImageJ (<https://imagej.nih.gov/ij/>) (Fig. 1b and 1e). A circle that passed through the three points on the septum was used to calculate IVS curvature defined as the reciprocal of the radius. A rightward (physiologic) curvature was denoted as a positive value (Fig. 1c) and a leftward curvature as a negative value (Fig. 1f). Two examiners (AS and HK) blinded to the subjects' identities provided all measurements.

### *Statistical analysis*

All statistical analyses were performed using R version 3.5.1 (The R Foundation for Statistical Computing, Vienna, Austria). To assess inter-rater reliability, the intraclass correlation coefficient (ICC)[13] with a two-way random model was calculated. Pearson's correlation was used to investigate the association of the IVS curvature and LVEI with sPAP<sub>RHC</sub>. To compare the trend of echo-derived measurements, the IVS curvature and LVEI were transformed into the sPAP scale using a linear regression model with sPAP<sub>RHC</sub> as the dependent variable. We evaluated the sensitivity and specificity of the echo-derived sPAP for predicting sPAP<sub>RHC</sub>  $\geq 70$  mmHg, which was categorized as severe PH. A P-value  $< 0.05$  was considered statistically significant in all tests.

## **Results**

### *Patient characteristics*

The study group comprised 72 consecutive patients with confirmed CTEPH. Baseline characteristics, hemodynamic data, and echocardiographic parameters of the subjects are shown in Table 1.

### **Table 1. Baseline characteristics of subjects.**

	All (n = 72)
Age (years)	59.7 ± 1.5
Sex, n (M/F)	21/51
Body surface area (m <sup>2</sup> )	1.62 ± 0.02
Pulmonary hemodynamic data	
Mean PAP (mmHg)	40.1 ± 1.3
Systolic PAP (mmHg)	70.1 ± 2.4
Diastolic PAP (mmHg)	20.5 ± 0.8
PVR (Wood units)	8.2 ± 0.5
Cardiac output (L/min)	4.5 ± 0.1
Cardiac index (L min <sup>-1</sup> m <sup>-2</sup> )	2.7 ± 0.1
Echocardiographic parameters	
TR grade, n	
Trivial	13
Mild	40
Moderate	11
Severe	6
TRPG (mmHg)	60.1 ± 2.6
TAPSE (mm)	19.6 ± 0.4

Data are represented as mean ± standard deviation or number. CTEPH, chronic pulmonary thromboembolic hypertension; PAP, pulmonary artery pressure; PVR, pulmonary vascular resistance; RA, right atrium; TAPSE, tricuspid annular plane systolic excursion; TR, tricuspid regurgitation; TRPG, tricuspid regurgitation pressure gradient

#### *Inter-rater reliability*

The ICC between two raters for the IVS curvature and LVEI showed a moderate value of 0.60 and 0.84, respectively, indicating that the measurements had substantial to almost perfect reliability.

#### *Relationships between sPAP<sub>RHC</sub> and echo-derived sPAPs*

Patients with trivial TR (n=13) were excluded from the correlation analysis because the trivial TR should be too small to be used for measuring accurate TR velocity. Fig. 2a-c show linear regression plots and correlation coefficients for sPAP<sub>RHC</sub> and compared the three types of echo-derived parameters in 59 patients. Statistically significant negative or positive correlations between the sPAP<sub>RHC</sub> and esPAP<sub>TRPG</sub>

( $r = 0.63$ ,  $P < 0.01$ ; Fig. 2a),  $sPAP_{RHC}$  and IVS curvature ( $r = -0.52$ ,  $P < 0.01$ ; Fig. 2b) and  $sPAP_{RHC}$  and LVEI ( $r = 0.49$ ,  $P < 0.01$ ; Fig. 2c) were found.

The IVS curvature and LVEI data were directly converted into the sPAP scale using a linear regression model:

$$esPAP_{curv} = -38.64 \times \text{curvature} + 76.60 \text{ (mmHg)}$$

$$esPAP_{LVEI} = 22.62 \times \text{LVEI} + 37.92 \text{ (mmHg)}$$

*Diagnostic performance of the IVS curvature for patients in whom accurate calculation of TRPG is difficult*

To ascertain whether the IVS curvature could estimate the  $sPAP_{RHC}$  more accurately in patients with unreliable TRPG, we verified the diagnostic performance of the IVS curvature for patients with trivial TR and severe PH whose TRPG are regarded as unreliable.

We were not able to obtain TRPG in some patients with trivial TR because their TR flow could not be detected clearly. Therefore, we confirmed whether the IVS curvature and LVEI can estimate the  $sPAP_{RHC}$  of patients with trivial TR accurately and not compare them with  $esPAP_{TRPG}$ . A statistically significant negative correlation between  $sPAP_{RHC}$  and  $esPAP_{curv}$  ( $r = 0.56$ ,  $P = 0.04$ ; Fig. 3a) was found, but there was no significant correlation between  $sPAP_{RHC}$  and  $esPAP_{LVEI}$  ( $r = 0.17$ ,  $P = 0.63$ ; Fig. 3b). These results indicate that the IVS curvature, not LVEI, would be useful to estimate  $sPAP_{RHC}$  for patients with trivial TR.

As mentioned above, the modified Bernoulli equation cannot be used in patients with severe PH, leading to the underestimation of  $esPAP_{TRPG}$ . Therefore, we confirmed sensitivity and specificity in estimating  $sPAP_{RHC} \geq 70$  mmHg for  $esPAP_{curv}$ ,  $esPAP_{LVEI}$ , and  $esPAP_{TRPG}$ . As shown in Table 2, the sensitivity of  $esPAP_{curv}$  (77%) were better than those of  $esPAP_{LVEI}$  (59%) and  $esPAP_{TRPG}$  (69%). This indicates that the IVS curvature, not LVEI, would be a good additional tool of  $esPAP_{TRPG}$  to avoid overlooking severe PH.

**Table 2. Sensitivity and specificity in estimating  $sPAP_{RHC} \geq 70$  mmHg for  $esPAP_{curv}$ ,  $esPAP_{LVEI}$  and  $esPAP_{TRPG}$**

	$esPAP_{curv}$	$esPAP_{LVEI}$	$esPAP_{TRPG}$
Sensitivity	77%	59%	69%
Specificity	65%	85%	58%

## Discussion

To the best of our knowledge, this is the first study to assess the quantitative utility of the IVS curvature obtained using echocardiography for estimating  $sPAP_{RHC}$  in patients with CTEPH.



The echocardiographic IVS curvature could compensate for the disadvantages of  $sPAP_{TRPG}$ , especially in the management of patients with unreliable TRPG including trivial TR and severe PH.

In this study, the ICC for the IVS curvature and LVEI showed mild values (0.60 [0.41–0.74, 95% confidence interval] and 0.84 [0.75–0.90], respectively), suggesting that the IVS curvature measured using echocardiography could be as reliable as that measured using cardiac CT[7].

Correlations of the IVS curvature with  $sPAP_{RHC}$  ( $r = -0.55$ ; Supplemental Fig. 1) in all CTEPH patients including them with trivial TR were less than those reported using CT[7] and MRI[14]. However, the echocardiographic IVS curvature should have the advantage of being a noninvasive, easy and low-cost tool unlike CT and MRI. From the viewpoint of safety, compared with MRI, it can be used for post-pulmonary endarterectomy patients with nontitanium wire. Moreover, the measurement of the echocardiographic IVS curvature can be performed easily using simple two-dimensional echocardiography without Doppler or three-dimensional echocardiography, unlike TRPG. This study excluded patients with insufficient TR jet for measuring TR velocity. Therefore, we suspected that the utility of the IVS curvature might be higher in the management of patients with CTEPH than predicted from this study.

Rich et al. and Fisher et al. both reported that the magnitude of pressure underestimation using  $esPAP_{TRPG}$  was greater than overestimation, particularly at high  $sPAP_{RHC}$  with fair or poor quality of Doppler TR jet[2, 15]. Mutlak et al. reported that severe TR is related to higher  $sPAP_{RHC}$  in general, but several patients with severe PH do not exhibit significant TR because of the remodeling of right heart cavities[4]. Therefore, we focused on patients with trivial TR and severe PH regarded as unreliable TRPG and investigated the utility of the IVS curvature for estimating  $sPAP_{RHC}$ .

In patients with trivial TR, significant correlation between  $sPAP_{RHC}$  and  $esPAP_{curv}$  was found statistically, indicating that the IVS curvature could estimate their  $sPAP_{RHC}$  to some extent even if their  $sPAP_{RHC}$  cannot be estimated due to trivial TR. Moreover, the sensitivity of  $esPAP_{curv}$  to predict patients with  $sPAP_{RHC} \geq 70$  mmHg were better than those of  $esPAP_{TRPG}$  and  $esPAP_{LVEI}$ . Echocardiographic results are often required to determine the need for RHC, and underestimation can therefore lead to a critical mistake, especially during the first visit. We assessed the utility of the IVS curvature to prevent underdiagnosis of patients with trivial TR and severe PH.

The 2015 ESC/ERS guidelines regarded LVEI  $>1.1$  in systole and/or diastole as an additional prespecified echocardiographic variable to predict the probability of PH in symptomatic patients suspected of PH [5]. This study showed that the ICC of LVEI is higher than that of IVS curvature, indicating that LVEI have smaller interobserver error. However, as mentioned above,  $esPAP_{LVEI}$  has no significant correlation with  $sPAP_{RHC}$  in patients with trivial TR, and its sensitivity in estimating  $sPAP_{RHC} \geq 70$  mmHg is lower than that of  $esPAP_{curv}$ . It indicates that the IVS curvature in CTEPH patients would be a more useful tool for estimating the probability and severity of PH than LVEI which are similar parameters for evaluating the flattening of IVS.

This study showed a linear relationship between the IVS curvature and  $sPAP_{RHC}$  as Roeleveld et al. reported in 379 adults suspected of PH and evaluated using MRI [16]. However, the correlation value was lower in the present study ( $r = -0.52$ ,  $P < 0.01$ ) than in their study ( $r = 0.77$ ,  $P < 0.001$ ). One possible reason for the lower correlation value in the present study is that echocardiographic IVS curvature might be dependent on patient's physique and operator's skill due to the use of local view in the heart instead of the whole heart in MRI. Another possible reason is that the present study included more patients with mild  $sPAP_{RHC} < 50$  mmHg than the study of Roeleveld et al.. Lopez-Candales et al. showed that LVEI measured at conventional papillary muscle level showed the best correlation with  $sPAP_{RHC}$  when the  $sPAP_{RHC}$  ranged between 45 and 60 mm [17]. This indicates that the mechanical compliance of the IVS might be linear within a limited range of  $sPAP_{RHC}$ .

This study has some limitations. First, it was a single-center retrospective study with a small number of patients. Multicenter studies with a larger number of subjects are needed to increase the generalizability of our findings. Second, we analyzed only CTEPH as a representative of conditions involving PH. To test the broad utility of the IVS curvature in PH management, further studies with several conditions involving PH need to be performed using the methods in this study.

## Conclusions

The echocardiographic IVS curvature could be a highly reliable and promising parameter for estimating  $sPAP_{RHC}$  in CTEPH and compensating for the disadvantages of  $sPAP_{TRPG}$ , especially in the management of patients with unreliable TRPG including trivial TR and severe PH.

## List Of Abbreviations

chronic thromboembolic pulmonary hypertension (CTEPH), computed tomography (CT), European Society of Cardiology/European Respiratory Society (ESC/ERS), intraclass correlation coefficient (ICC), inferior vena cava (IVC), interventricular septum (IVS), left ventricular eccentricity index (LVEI), magnetic resonance imaging (MRI), pulmonary hypertension (PH), right-sided heart catheterization (RHC),  $sPAP_{RHC}$  using echocardiographic IVS curvature ( $esPAP_{curv}$ ),  $sPAP_{RHC}$  using tricuspid regurgitant pressure gradient ( $esPAP_{TRPG}$ ), systolic pulmonary artery pressure measured via right-sided heart catheterization ( $sPAP_{RHC}$ ), tricuspid regurgitant pressure gradient (TRPG), tricuspid regurgitation (TR)

## Declarations

*Ethics approval and consent to participate*

The present study was a single-center retrospective investigation and was approved by the ethics committee of Chiba University (approved on June 1, 2009; approval number, 826). All patients provided informed consent.

### *Consent for publication*

All study participants provided informed consent and the study design was approved by the appropriate ethics review board.

### *Availability of data and materials*

The datasets generated and/or analyzed during the current study are available from the corresponding author on reasonable request.

### *Competing interests*

NT received a research grant from Nippon Shinyaku and honoraria from Actelion Pharmaceuticals, Nippon Shinyaku, Pfizer, Bristol-Myers Squibb, and Bayer. NT, AS, and TJ belong to the endowed department sponsored by Actelion Pharmaceuticals. Other authors have declared that no competing interests exist.

### *Funding*

KT, NT, SS, and JT received a grant from the Intractable Respiratory Diseases and Pulmonary Hypertension Research Group, the Ministry of Health, Labor and Welfare (2017), and a grant from Pulmonary Hypertension Research Group from the Japan Agency for Medical Research and Development, AMED (17ek0109127h0003). The funder had no role in the study design, collection of data or their analysis, decision to publish, or preparation of the manuscript.

### **Authors' contributions**

AM and AS conceived and planned this research and were major contributors in writing the manuscript. AS and HY verified the analytical methods. AM, AS, HK, and KY contributed to sample preparation. JT, TS, TM, SS, NT, and KT encouraged specific investigation and supervised the findings of this research. All authors provided critical feedback and helped shape the research, analysis, and manuscript. All authors have read and approved the final manuscript.

### **Acknowledgements**

We would like to thank Editage ([www.editage.com](http://www.editage.com)) for English language editing.

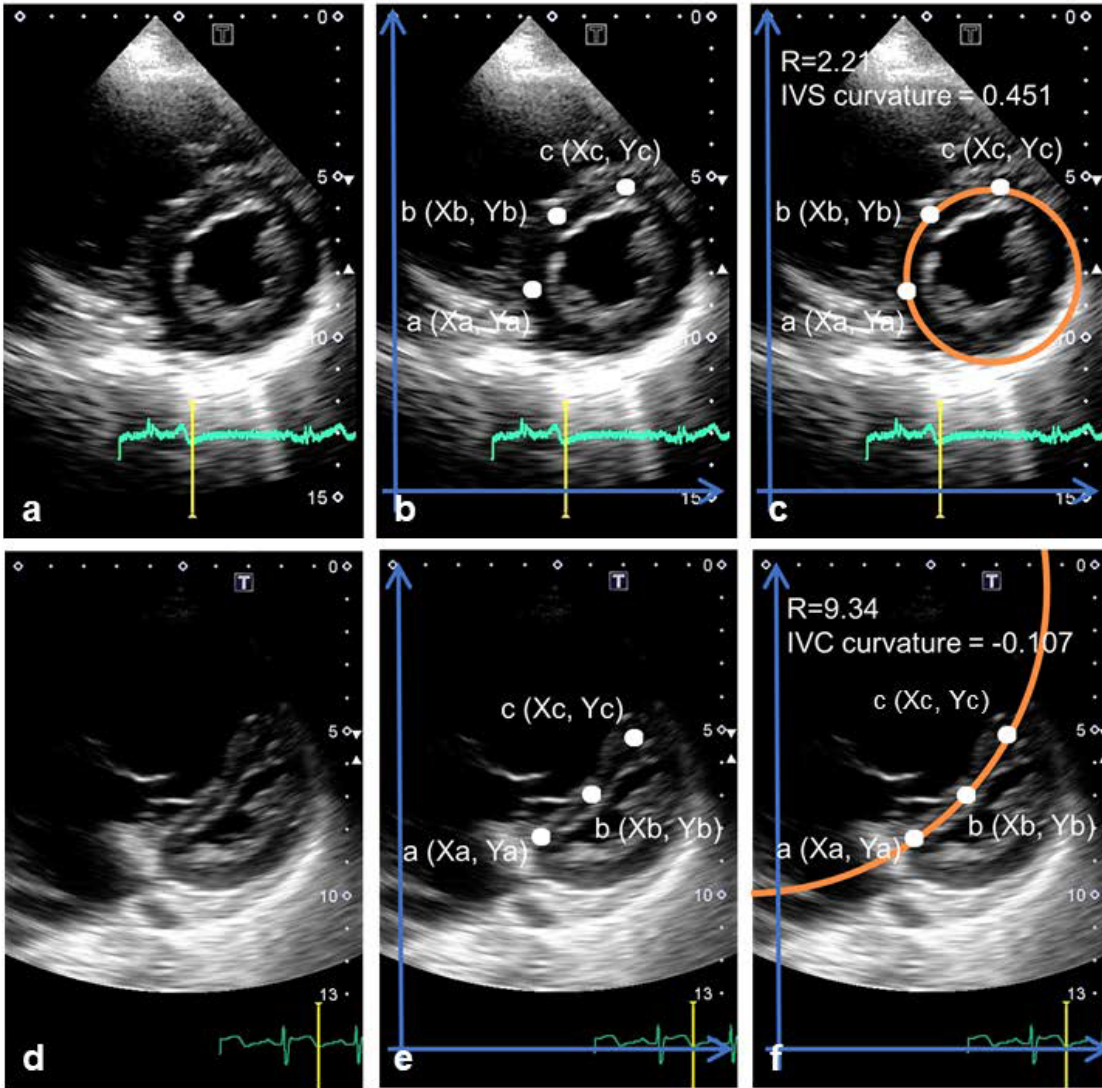
## **References**

1. Hoepfer MM, Mayer E, Simonneau G, Rubin LJ: Chronic thromboembolic pulmonary hypertension. *Circulation* 2006, 113(16):2011-2020.
2. Rich JD, Shah SJ, Swamy RS, Kamp A, Rich S: Inaccuracy of Doppler echocardiographic estimates of pulmonary artery pressures in patients with pulmonary hypertension: implications for clinical practice. *Chest* 2011, 139(5):988-993.

3. Howard LS, Grapsa J, Dawson D, Bellamy M, Chambers JB, Masani ND, Nihoyannopoulos P, Simon RGJ: Echocardiographic assessment of pulmonary hypertension: standard operating procedure. *Eur Respir Rev* 2012, 21(125):239-248.
4. Mutlak D, Aronson D, Lessick J, Reisner SA, Dabbah S, Agmon Y: Functional tricuspid regurgitation in patients with pulmonary hypertension: is pulmonary artery pressure the only determinant of regurgitation severity? *Chest* 2009, 135(1):115-121.
5. Galie N, Humbert M, Vachiery JL, Gibbs S, Lang I, Torbicki A, Simonneau G, Peacock A, Vonk Noordegraaf A, Beghetti M *et al*: 2015 ESC/ERS Guidelines for the diagnosis and treatment of pulmonary hypertension: The Joint Task Force for the Diagnosis and Treatment of Pulmonary Hypertension of the European Society of Cardiology (ESC) and the European Respiratory Society (ERS): Endorsed by: Association for European Paediatric and Congenital Cardiology (AEPC), International Society for Heart and Lung Transplantation (ISHLT). *Eur Respir J* 2015, 46(4):903-975.
6. King ME, Braun H, Goldblatt A, Liberthson R, Weyman AE: Interventricular septal configuration as a predictor of right ventricular systolic hypertension in children: a cross-sectional echocardiographic study. *Circulation* 1983, 68(1):68-75.
7. Sugiura T, Tanabe N, Matsuura Y, Shigeta A, Kawata N, Jujo T, Yanagawa N, Sakao S, Kasahara Y, Tatsumi K: Role of 320-slice CT imaging in the diagnostic workup of patients with chronic thromboembolic pulmonary hypertension. *Chest* 2013, 143(4):1070-1077.
8. Sciancalepore MA, Maffessanti F, Patel AR, Gomberg-Maitland M, Chandra S, Freed BH, Caiani EG, Lang RM, Mor-Avi V: Three-dimensional analysis of interventricular septal curvature from cardiac magnetic resonance images for the evaluation of patients with pulmonary hypertension. *Int J Cardiovasc Imaging* 2012, 28(5):1073-1085.
9. Saito T, Kasai H, Sugiura T, Takahashi Y, Tajima H, Shigeta A, Sakao S, Tanabe N, Tatsumi K: Effects of pulmonary endarterectomy on pulmonary hemodynamics in chronic thromboembolic pulmonary hypertension, evaluated by interventricular septum curvature. *Pulm Circ* 2020, 10(1):2045894019897502.
10. Task Force for D, Treatment of Pulmonary Hypertension of European Society of C, European Respiratory S, International Society of H, Lung T, Galie N, Hoeper MM, Humbert M, Torbicki A, Vachiery JL *et al*: Guidelines for the diagnosis and treatment of pulmonary hypertension. *Eur Respir J* 2009, 34(6):1219-1263.
11. Rudski LG, Lai WW, Afilalo J, Hua L, Handschumacher MD, Chandrasekaran K, Solomon SD, Louie EK, Schiller NB: Guidelines for the echocardiographic assessment of the right heart in adults: a report from the American Society of Echocardiography endorsed by the European Association of Echocardiography, a registered branch of the European Society of Cardiology, and the Canadian Society of Echocardiography. *J Am Soc Echocardiogr* 2010, 23(7):685-713; quiz 786-688.
12. Ryan T, Petrovic O, Dillon JC, Feigenbaum H, Conley MJ, Armstrong WF: An echocardiographic index for separation of right ventricular volume and pressure overload. *J Am Coll Cardiol* 1985, 5(4):918-927.

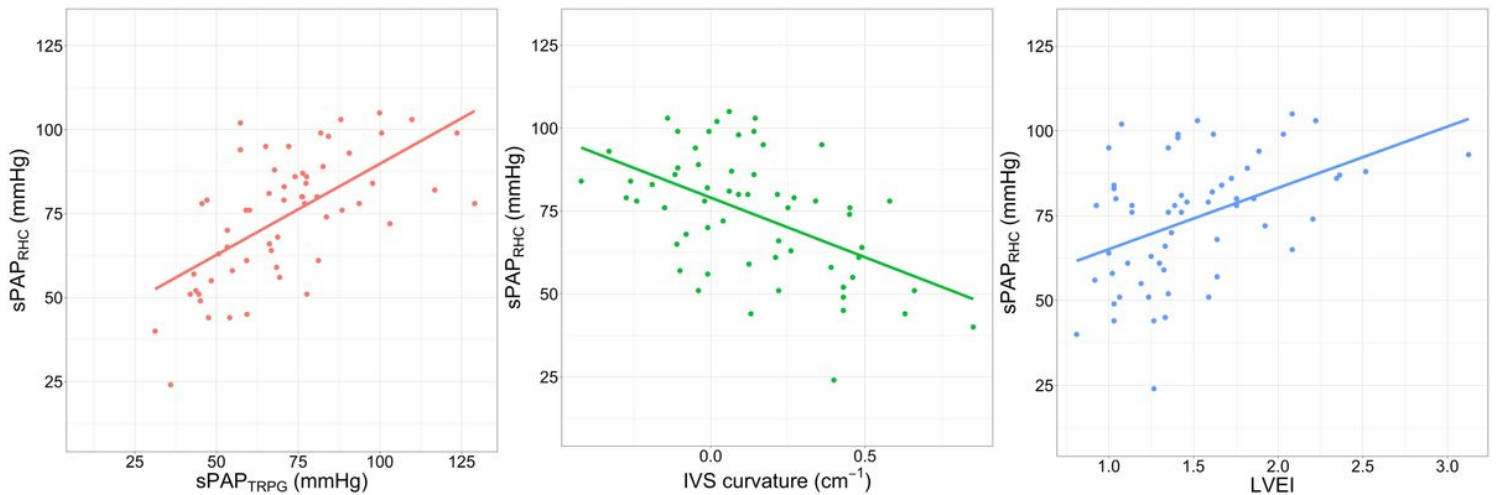
13. Park JE, Han K, Sung YS, Chung MS, Koo HJ, Yoon HM, Choi YJ, Lee SS, Kim KW, Shin Y *et al*: Selection and Reporting of Statistical Methods to Assess Reliability of a Diagnostic Test: Conformity to Recommended Methods in a Peer-Reviewed Journal. *Korean J Radiol* 2017, 18(6):888-897.
14. Alunni JP, Degano B, Arnaud C, Tetu L, Blot-Souletie N, Didier A, Otal P, Rousseau H, Chabbert V: Cardiac MRI in pulmonary artery hypertension: correlations between morphological and functional parameters and invasive measurements. *Eur Radiol* 2010, 20(5):1149-1159.
15. Fisher MR, Forfia PR, Chamera E, Houston-Harris T, Champion HC, Girgis RE, Corretti MC, Hassoun PM: Accuracy of Doppler echocardiography in the hemodynamic assessment of pulmonary hypertension. *Am J Respir Crit Care Med* 2009, 179(7):615-621.
16. Roeleveld RJ, Marcus JT, Faes TJ, Gan TJ, Boonstra A, Postmus PE, Vonk-Noordegraaf A: Interventricular septal configuration at mr imaging and pulmonary arterial pressure in pulmonary hypertension. *Radiology* 2005, 234(3):710-717.
17. Lopez-Candales A, Bazaz R, Edelman K, Gulyasy B: Apical systolic eccentricity index: a better marker of right ventricular compromise in pulmonary hypertension. *Echocardiography* 2010, 27(5):534-538.

## Figures



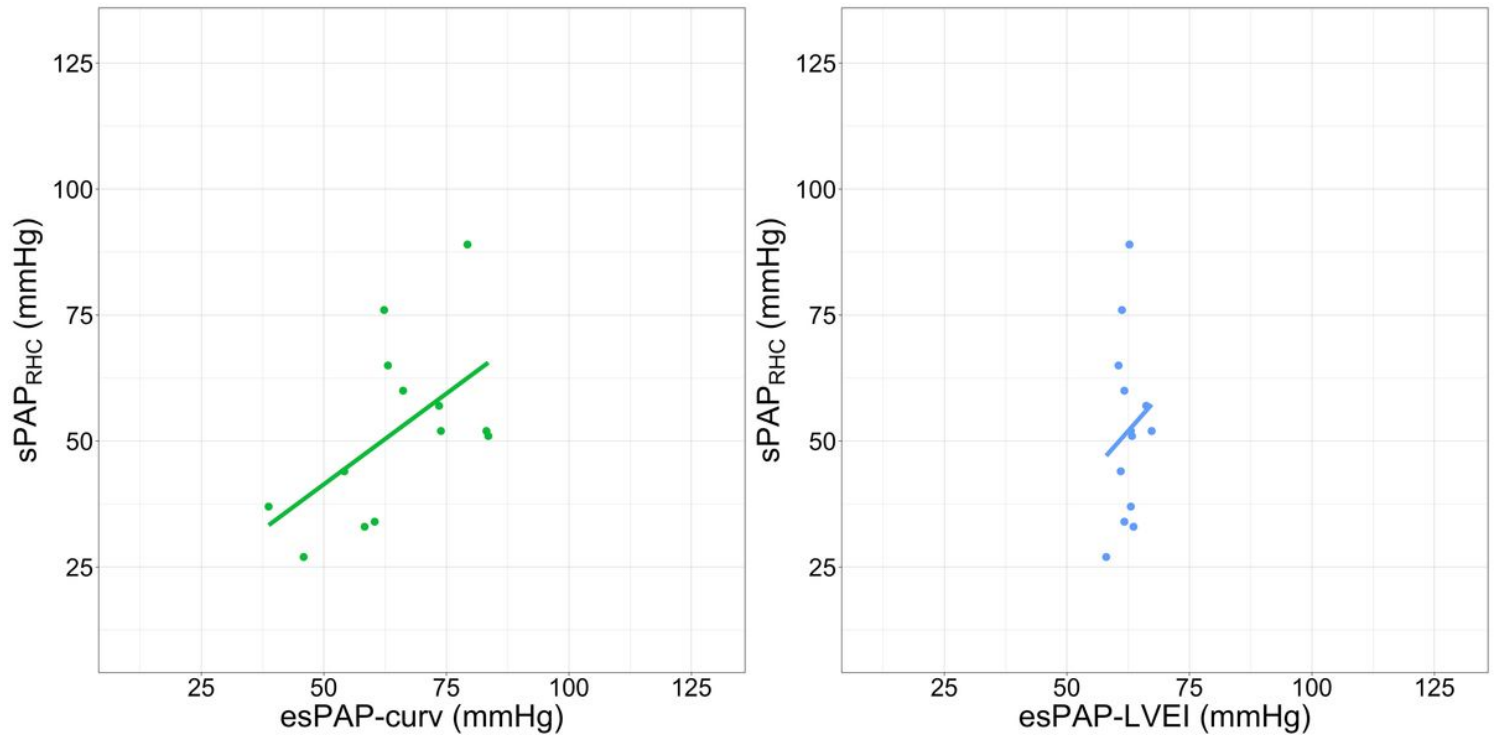
**Figure 1**

Three different points at the posterior (a), middle (b), and anterior (c) positions of the interventricular septum were marked, and the X and Y coordinates were recorded at these three points using ImageJ (<https://imagej.nih.gov/ij/>) (Fig. 1b and 1e).



## Figure 2

a-c show linear regression plots and correlation coefficients for sPAP<sub>RHC</sub> and compared the three types of echo-derived parameters in 59 patients. (2a Left panel), (2b Middle panel), (2c Right panel)



## Figure 3

A statistically significant negative correlation between sPAP<sub>RHC</sub> and esPAP<sub>curv</sub> ( $r = 0.56$ ,  $P = 0.04$ ; Left Panel a) was found; no significant correlation between sPAP<sub>RHC</sub> and esPAP<sub>LVEI</sub> ( $r = 0.17$ ,  $P = 0.63$ ; Right panel b).

## Supplementary Files

This is a list of supplementary files associated with this preprint. Click to download.

- [supFig1.tiff](#)