

The protective effect of curcumin on rats with DSS-induced ulcerative colitis and its mechanisms

Jing Guo (✉ guojing.1012@163.com)

Shengjing Hospital of China Medical University <https://orcid.org/0000-0002-2020-4575>

Yan-yan Zhang

Suzhou Municipal Hospital

Mei Sun

Shengjing Hospital of China Medical University

Ling-fen Xu

Shengjing Hospital of China Medical University

Research Article

Keywords: Curcumin, inflammatory bowel disease, regulatory T cell, Th17 cell

Posted Date: May 7th, 2021

DOI: <https://doi.org/10.21203/rs.3.rs-191627/v1>

License: © ⓘ This work is licensed under a Creative Commons Attribution 4.0 International License.

[Read Full License](#)

Abstract

Aim This study aimed to explore effect of curcumin on inflammatory bowel disease (IBD) in rats and its mechanism.

Methods: A dextran sulfate sodium (DSS)-induced ulcerative colitis (UC) rat model was established. The disease activity index (DAI) scores were calculated. The histopathological damage scores were determined by haematoxylin-eosin (H&E) staining. Regulatory T (Treg) cells and T helper 17 (Th17) cells in the spleen were analysed by flow cytometry. The levels of interleukin (IL)-10 and IL-17A were determined by enzyme-linked immunosorbent assay (ELISA).

Results: Compared with the DSS model group, the curcumin group exhibited significantly reduced DAI scores and improvements in histopathological damage. The expression of CD4+IL-17+ Th17 cells was significantly lower and the expression of CD4+CD25+Foxp3+ Treg cells was significantly higher in the curcumin group than in the DSS group.

Conclusion: Curcumin may be a new and effective treatment for IBD by regulating the balance of Treg/Th17 cells and the expression of IL-10 and IL-17A.

1. Introduction

Inflammatory bowel disease (IBD) is a chronic, nonspecific intestinal inflammatory disease with unknown aetiology and pathogenesis and included Crohn's disease (CD), ulcerative colitis (UC) and indeterminate colitis (IC). The treatment of IBD is mainly based on aminosalicylic acid preparations, glucocorticoids, immunosuppressants and biologics, but there are problems such as disease recurrence or adverse drug reactions [1]. The role of faecal bacteria transplantation is not clear [2]. It is important to find clinically safe and effective drugs for IBD treatment. Curcumin is a traditional Chinese herbal medicine that is used for anti-inflammation in China and Southeast Asia. Curcumin has antioxidant, anti-inflammatory, anticancer and antiapoptotic properties [3–5]. The advantages of curcumin, such as few adverse reactions, high levels of safety, and good compliance, have attracted the attention of many researchers. Studies have shown that curcumin can reduce airway inflammation by regulating the balance of Treg/Th17 cells in asthma models [6]. In IBD model mice with genetic deletion of IL-10, an emulsion of curcumin in sodium carboxymethyl cellulose induced anti-inflammatory effects [7]. However, the specific mechanism of curcumin in IBD is still unclear.

In this study, a DSS-induced juvenile rat colitis model was established to examine the mechanism of curcumin and provide an experimental basis for curcumin treatment of UC.

2. Experimental Method

2.1. Establishment of the DSS-induced UC rat model and groupings

In this study, 40 immature male Sprague-Dawley (SD) rats were purchased from Beijing Hua Kang Kang Biotechnology Co., Ltd. (licence number: SCXK (Jing) 2014-0004). The rats were housed in the Experimental Animal Department (SPF level) of Sheng Jing Hospital (licence number: SYXK (Liao) 2010-0008). The temperature was 22–25°C, with a relative humidity of 40–70% and a 12-h light-dark cycle. The rats were housed in separate cages with free access to food and drink and were allowed to adapt to the conditions for 7 days after arrival. This study was approved by the Ethics Committee of the Affiliated Sheng Jing Hospital of China Medical University (approval no. 2015PS244K, Shenyang, China).

The rats were randomly divided into four groups: (1) control group (n = 10) rats freely drank, sterile distilled water; (2) DSS model group (n = 10) rats drank sterile distilled water containing DSS (DSS was dissolved in sterile distilled water at a concentration of 30 g/L DSS (W/V)), and the water was replaced once every two days; (3) in the curcumin A group (n = 10), 5 g of carboxymethylcellulose sodium was dissolved in 100 ml of sterile distilled water to prepare a 0.5% CMC solution, 100 mg/kg curcumin was dissolved in 2 ml of the 0.5% sodium carboxymethyl cellulose solution, and 100 mg/kg curcumin was administered to the rats by gavage once a day for 7 days in addition to the DSS aqueous solution used for model establishments; and (4) in the curcumin B group (n = 10), 100 mg/kg curcumin was dissolved in 2 ml of 0.5% sodium carboxymethyl cellulose solution, and 100 mg/kg curcumin was administered to the rats by gavage once a day for 7 days in addition to the DSS aqueous solution used for model establishment. After 7 days of treatment, the materials were collected. Intraperitoneal injection of chloral hydrate was performed. After sterilization with alcohol, the spleen was removed on an ultraclean table. The collected serum was stored at -80°C, and the intestinal tissue from the caecum to 1 cm above the anus was quickly removed, rinsed with cold saline, and spread flat on disposable PE gloves to measure the length in a blinded manner.

2.2. DAI score and colonic histopathological damage evaluation

Daily records of the general state, weight changes, stool traits and faecal occult blood/gross blood in stool were maintained for the rats. According to the Cooper HS scoring standard, the disease activity index (DAI) score was calculated for the rats, and inflammatory damage in the colonic mucosa was evaluated as follows: $DAI = (\text{weight loss score} + \text{stool trait score} + \text{blood in the stool})/3$. The intestinal tissue at the end of the colon 8 cm above the anus was collected for HE staining. The HE staining procedure and the scoring criteria for colonic tissue pathological damage were previously described [8].

2.3. Flow cytometric analysis of Treg and Th17 cells

Anti-CD4-FITC, anti-CD25-PE, anti-Foxp3-APC antibody, and anti-IL17-PE (Ebioscience, California, USA) antibodies were used for IH staining. Flow cytometric analysis was performed as previously described [8].

2.4. ELISA analysis of serum cytokines

The levels of IL-17A and IL-10 in the serum were measured by double-antibody sandwich ELISA (Cusabio, Wu Han, China) according to the instructions. A microplate reader was zeroed with a blank well. The

optical density (OD) of each well was measured sequentially at a wavelength of 450 nm. The ELISA detection limits were determined according to a previous reference [9].

2.5. Statistical analysis

Statistical analysis was performed by SPSS 17.0. The experimental data are presented as the mean \pm SEM. If the data conformed to a normal distribution with the same variance between two groups, a t-test was performed. One-way analysis of variance was used to detect differences between multiple groups. DAI scores were statistically analysed by the Kruskal-Wallis nonparametric test, followed by the Mann-Whitney U test to compare the results of different groups. A value of $P < 0.05$ was statistically significant. All experiments were repeated three times.

3. Results

3.1. Protective effect of curcumin on rats with DSS-induced UC

Rats in the DSS group began to develop loose stools and faecal occult blood in stools on day 2, and rats in the curcumin A group began to develop loose stools and faecal occult blood in stools on day 3. The curcumin B group began to develop loose stools and faecal occult blood in stools on day 2, but the faecal occult blood score was lower than that of the DSS group. Weight gain slowed on day 5 in the DSS group and significantly decreased on day 6 of modelling. The DAI scores of the curcumin A and curcumin B groups were significantly lower than those of the DSS group beginning on day 5 (Fig. 1A, $P < 0.05$).

In addition, the total colon length in the DSS group was significantly shorter than that in the control group, and the colon lengths in the curcumin A and curcumin B groups were significantly longer than that in the DSS group (Fig. 1B and Fig. 1C, $P < 0.05$). These data showed that curcumin treatment alleviated the clinical manifestations of UC in rats.

Normal colon tissues have little to no inflammatory cell infiltration, an intact colon mucosa, and abundant and tightly arranged intestinal glands in the lamina propria. The intestinal mucosal epithelium of rats in the DSS model group showed large areas of necrosis and shedding, disordered gland structure, decreased numbers of goblet cells, the formation of cryptitis and crypt abscesses, hyperaemia of the submucosal layer, oedema, telangiectasia, and a large number of infiltrated lymphocytes in the intestine. The intestinal pathology of rats in curcumin group A and group B was between that of the normal group and the DSS group (Fig. 2A). As shown in Fig. 2B, the histopathological scores of the DSS model group were significantly higher than those of the normal group, but the histopathological scores of the curcumin A group and the curcumin B group were significantly lower than those of the DSS group. The difference was statistically significant ($P < 0.05$), which suggested that curcumin could improve the pathology of DSS-induced damage in rats.

3.2. Effect of curcumin on Treg/Th17 cells in rats with DSS-induced IBD

To examine the effect of curcumin on Treg/Th17 cells in rats with DSS-induced UC, we determined the ratio of CD4 + CD25 + Foxp3 + Treg cells and CD4 + IL17 + Th17 cells among CD4 + cells in the spleens of SD rats by flow cytometry. The ratio of CD4 + CD25 + Foxp3 + Treg cells in the DSS group was significantly lower than that in the normal group, the ratio in the curcumin A group and curcumin B group were significantly higher than that in the model group, and the difference was statistically significant (Fig. 3A and Fig. 3C, $P < 0.05$); however, there was no significant difference between the curcumin A group, the curcumin B group and the normal control group ($P > 0.05$). The ratio of CD4⁺IL17⁺ Th17 in the DSS group was significantly higher than that in the normal group, the ratio in the curcumin A group and curcumin B group were significantly lower than that in the DSS group, and the difference was statistically significant (Fig. 3B and Fig. 3D, $P < 0.05$); however, there was no significant difference between the curcumin A group, the curcumin B group and the normal group ($P > 0.05$). The Treg/Th17 cell ratios in the curcumin A group and curcumin B group were significantly higher than those in the DSS group, and the difference was statistically significant (Fig. 3E, $P < 0.05$). There was no significant difference in Treg/Th17 cells between the curcumin A and curcumin B group. Therefore, the protective effect of curcumin against DSS-induced IBD in rats may be associated with regulating the Treg/Th17 balance.

3.3 Effect of curcumin on inflammatory cytokines in rats with DSS-induced IBD

To further confirm the effect of curcumin on the balance of Treg/Th17 cells, ELISA was used to measure the levels of the pro-inflammatory factor IL-17A and the anti-inflammatory factor IL-10 in the serum of rats. The results showed that the serum level of IL-10 in the DSS group was significantly lower than that in the control group (Fig. 4A, $P < 0.05$), while the level of IL-17A was significantly higher in the DSS group than in the control group (Fig. 4B, $P < 0.05$). However, the levels of IL-17A in the curcumin A and curcumin B groups were significantly lower than those in the DSS group, and the IL-10 level was significantly higher in the curcumin B group than in the DSS group (Fig. 7B, $P < 0.05$). The expression of IL-17A was lower and IL-10 was higher in the curcumin A group than in the curcumin B group, but there was no significant difference. These results demonstrate that curcumin can increase the secretion of anti-inflammatory factors and inhibit the secretion of pro-inflammatory factors in rats with DSS-induced IBD.

4. Discussion

The aetiology and pathogenesis of IBD are not very clear. In recent years, research has mainly focused on genetic susceptibility, immune abnormalities, and changes in intestinal flora. Immune factors play an important role in the occurrence and development of IBD, especially T lymphocyte subsets [10]. In this study, a UC model was established with DSS, and the general conditions of the rats, DAI, histopathology, Treg cells and Th17 cells were analysed. It was found that curcumin could alleviate the disease course of experimental UC by regulating the balance of Treg/Th17 cells.

In this study, rats in the model group experienced weight loss, changes in faecal traits, positive faecal occult blood, and even bloody stools. Moreover, DAI and histopathological damage also changed significantly. Curcumin significantly improved the general conditions, DAI and intestinal injury of rats with UC. This finding is consistent with those of previous studies showing that curcumin can relieve intestinal inflammation. Joon-Yeop Yang et al. indicated that curcumin inhibits the severity of 3% DSS-induced inflammatory bowel disease through STAT3 [11]. Studies have shown that curcumin can inhibit DSS-induced murine colon cancer [12] and can also maintain the intestinal microecological balance and the relationship between microorganisms and the host [13].

Recently, it was discovered that Th17 and Treg cells are CD4 + T cell subgroups that are different from Th1 and Th2 cells. Th17 cells mainly secrete IL-17A, IL-17F, IL-21, IL-22 and other cytokines, while Treg cells inhibit immune responses and mainly secrete IL-10. A large amount of evidence shows that improving the imbalance of Treg/Th17 cells is a potential strategy for the treatment of IBD [14]. In this study, flow cytometry showed that the proportion of Treg cells in experimental UC rats was significantly lower and the proportion of Th17 cells was significantly higher than those of rats the normal group. This finding is consistent with the protective effect of Treg cells and the damaging effect of Th17 cells in autoimmune diseases [15].

IL-17 is a pro-inflammatory cytokine produced by T cells that can further trigger T cells and other immune cells to produce chemokines, cell adhesion molecules and other cytokines and plays a key role in the progression of IBD. In an experimental model of encephalomyelitis, it was found that the level of IL-17 and the mRNA expression of IL-17 in the curcumin treatment group were reduced, the levels of TGF- β , STAT3 and p-STAT-3 were inhibited, and the phosphorylation of STAT-3 in T cells was inhibited, blocking the differentiation of Th-17 cells [16]. An experimental animal model of autoimmune myasthenia gravis (EAMG) showed that curcumin inhibited the expression of pro-inflammatory factors (IL-17, IFN- γ and TNF- α) and increased the expression of the anti-inflammatory cytokine IL-10, thereby reducing the clinical symptoms of EAMG in rats [17]. The present study showed that compared with those of IBD rats in the DSS group, IL-17A levels in IBD rats in the curcumin group were significantly decreased. In conclusion, curcumin can regulate inflammation by regulating the expression of IL-17.

IL-10 is a cytokine with immunomodulatory effects that can counteract pro-inflammatory factors such as IL-2, TNF- α and IFN- γ and balance the body's inflammatory response. Many studies have shown that defects in IL-10 expression are related to the pathogenesis of IBD. Studies [18] have shown that curcumin can reduce the expression of the pro-inflammatory cytokines IL-1 β , IL-12, IFN- γ , TNF- α and IL-1 while increasing the expression of the anti-inflammatory cytokines IL-4 and IL-10. Curcumin can also limit colitis mediated by the Th1 response in IL-10(-/-) mice and has a synergistic effect with IL-10, downregulating the activity of NF- κ B in intestinal epithelial cells [19]. Epstein et al. [20] showed that curcumin could increase the expression of IL-10D in the colonic mucosa of children and adults with IBD. The present study showed that compared with those of IBD rats in the DSS group, IL-10 levels of IBD rats in the curcumin group were significantly higher. Therefore, the protective effect of curcumin was related to IL-10.

In summary, curcumin attenuated colonic tissue damage in DSS-induced UC rats by improving the Treg/Th17 cell balance and influencing the expression of inflammatory cytokines.

Declarations

Funding: This work was supported by grants from Ling-fen Xu (Natural Science Foundation of Liaoning Province, China, 2019-MS-372), and 345 Talent Project from Jing Guo.

Competing interests: The authors declare that they have no competing interests.

Availability of data and materials: All data generated or analysed during this study are included in this published article.

Authors' Contributions: Author Jing Guo did the experiment and write the paper, author Yan-yan Zhang did the experiment and collected data, author Mei Sun did the statistics, and author Ling-fen Xu as a communication author for overall guidance.

Ethics approval and consent to participate: The study was approved by the ethics committee of the Affiliated Shengjing Hospital of China Medical University (approval no. 2015PS244K, Shenyang, China).

Consent for publication: Not applicable.

Acknowledgements: We appreciated Li-yun Wang for guiding the writing of this article.

References

1. Jeong, D. Y., S. Kim, M. J. Son, C. Y. Son, J. Y. Kim, A. Kronbichler, K. H. Lee, and J. I. Shin. 2019. Induction and maintenance treatment of inflammatory bowel disease: A comprehensive review. *Autoimmun Rev* 18: 439–454.
2. [https://doi: 10.1016/j.autrev.2019.03.002](https://doi.org/10.1016/j.autrev.2019.03.002).
3. Imdad, A., M. R. Nicholson, E. E. Tanner-Smith, J. P. Zackular, O. G. Gomez-Duarte, D. B. Beaulieu, and S. Acra. 2018. Fecal transplantation for treatment of inflammatory bowel disease. *Cochrane DB Syst Rev* 11: CD012774.
4. [https://doi: 10.1002/14651858.CD012774.pub2](https://doi.org/10.1002/14651858.CD012774.pub2).
5. Esatbeyoglu, T., P. Huebbe, I. M. A. Ernst, D. Chin, A. E. Wagner, and G. Rimbach. 2012. Curcumin-From Molecule to Biological Function. *Angew Chem Int Edit* 51: 5308–5332.
6. [https://doi: 10.1002/anie.201107724](https://doi.org/10.1002/anie.201107724).
7. Hatcher, H., R. Planalp, J. Cho, F. M. Torti, and S. V. Torti. 2008. Curcumin: from ancient medicine to current clinical trials. *Cell Mol Life Sci* 65: 1631–1652.
8. [https://doi: 10.1007/s00018-008-7452-4](https://doi.org/10.1007/s00018-008-7452-4).

9. Kunnumakkara, A. B., P. Anand, and B. B. Aggarwal. 2008. Curcumin inhibits proliferation, invasion, angiogenesis and metastasis of different cancers through interaction with multiple cell signaling proteins. *Cancer Lett* 269: 199–225.
10. <https://doi: 10.1016/j.canlet.2008.03.009>.
11. Ma, C., Z. Ma, Q. Fu, and S. Ma. 2013. Curcumin attenuates allergic airway inflammation by regulation of CD4 + CD25 + regulatory T cells (Tregs)/Th17 balance in ovalbumin-sensitized mice. *Fitoterapia* 87: 57–64.
12. <https://doi: 10.1016/j.fitote.2013.02.014>.
13. Ung, V. Y., R. R. Foshaug, S. M. MacFarlane, T. A. Churchill, J. S. G. Doyle, B. C. Sydora, and R. N. Fedorak. 2010. Oral administration of curcumin emulsified in carboxymethyl cellulose has a potent anti-inflammatory effect in the IL-10 gene-deficient mouse model of IBD. *Digest Dis Sci* 55: 1272–1277.
14. <https://doi: 10.1007/s10620-009-0843-z>.
15. Guo, J., L. Y. Wang, J. Wu, L. F. Xu, and M. Sun. 2020. The JAK2 Inhibitor AG490 Regulates the Treg/Th17 Balance and Alleviates DSS-induced Intestinal Damage in IBD Rats. *Clin Exp Pharmacol Physiol* 47: 1374–1381.
16. <https://doi: 10.1111/1440-1681.13311>.
17. Zhang, L., Y. Zhang, W. Zhong, C. Di, X. Lin, and Z. Xia. 2014. Heme Oxygenase-1 ameliorates dextran sulfate sodium induced acute murine colitis by regulating Th17/Treg cell balance. *J Biol Chem* 289: 26847–26858.
18. <https://doi: 10.1074/jbc.M114.590554>.
19. Gibson, D. J., E. J. Ryan, and G. A. Doherty. 2013. Keeping the bowel regular: the emerging role of Treg as a therapeutic target in inflammatory bowel disease. *Inflammatory Bowel Diseases* 19: 2716–2724.
20. <https://doi: 10.1097/MIB.0b013e31829ed7df>.
21. Yang, J. Y., X. Zhong, H. W. Yum, H. J. Lee, J. K. Kundu, and H. K. Na, Y.J.Surh. 2013. Curcumin Inhibits STAT3 Signaling in the Colon of Dextran Sulfate Sodium-treated Mice. *J Cancer Prev* 18: 186–191.
22. <https://doi: 10.15430/jcp.2013.18.2.186>.
23. Kagami, S., T. Owada, H. Kanari, Y. Saito, A. Suto, K. Ikeda, K. Hirose, N. Zatanabe, I. Iwamoto, and H. Nakajima. 2009. Protein geranylgeranylation regulates the balance between Th17 cells and Foxp3 + regulatory T cells. *Int Immunol* 21: 679–689.
24. <https://doi: 10.1093/intimm/dxp037>.
25. Murakami, A., I. Furukawa, S. Miyamoto, T. Tanaka, and H. Ohigashi. 2013. Curcumin combined with turmerones, essential oil components of turmeric, abolishes inflammation-associated mouse colon carcinogenesis. *BioFactors (Oxford, England)* 39: 221–232.
26. <https://doi: 10.1002/biof.1054>.

27. Awasthi, A., G. Murugaiyan, and V. K. Kuchroo. 2008. Interplay between effector Th17 and regulatory T cells. *J Clin Immuno* 28: 660–670.
28. [https://doi: 10.1007/s10875-008-9239-7](https://doi.org/10.1007/s10875-008-9239-7).
29. Li, L., and V. A. Boussiotis. 2013. The role of IL-17-producing Foxp3 + CD4 + T cells in inflammatory bowel disease and colon cancer. *Clin Immunol* 148: 246–253.
30. [https://doi: 10.1016/j.clim.2013.05.003](https://doi.org/10.1016/j.clim.2013.05.003).
31. Xie, L., X. K. Li, N. Funeshima-Fuji, H. Kimura, Y. Matsumoto, Y. Isaka, and S. Takahara. 2009. Amelioration of experimental autoimmune encephalomyelitis by curcumin treatment through inhibition of IL-17 production. *Int Immunopharmacol* 9: 575–581.
32. [https://doi: 10.1016/j.intimp.2009.01.025](https://doi.org/10.1016/j.intimp.2009.01.025).
33. Wang, S., H. Li, M. Zhang, L. T. Yue, C. C. Wang, P. Zhang, and Y. Liu, R.S.Duan. 2016. Curcumin ameliorates experimental autoimmune myasthenia gravis by diverse immune cells. *Neurosci Lett* 626: 25–34.
34. [https://doi: 10.1016/j.neulet.2016.05.020](https://doi.org/10.1016/j.neulet.2016.05.020).
35. Midura-Kiela, M.T,V.M., C. B. Radhakshnan, D. Larmonier, F. K. Laubitz, P. R. Ghishan, and Kiela. 2012. Curcumin inhibits interferon- γ signaling in colonic epithelial cells. *Am J Physiol-Gastr L* 302: G85–G96.
36. [https://doi: 10.1152/ajpgi.00275.2011](https://doi.org/10.1152/ajpgi.00275.2011).
37. Larmonier, C. B., J. K. Uno, K. M. Lee, T. Karrasch, D. Laubitz, R. Thurston, M. T. Midura-Kiela, F. K. Ghishan, R. B. Sartor, and C. Jobin, et al. 2008. Limited effects of dietary curcumin on Th-1 driven colitis in IL-10 deficient mice suggest an IL-10 dependent mechanism of protection. *Am J Physiol-Gastr L* 295: G1079–G1091.
38. [https://doi: 10.1152/ajpgi.90365.2008](https://doi.org/10.1152/ajpgi.90365.2008).
39. Epstein, J., G. Docena, T. T. MacDonald, and I. R. Sanderson. 2010. Curcumin suppresses p38 mitogen activated protein kinase activation, reduces IL-1 β and matrix metalloproteinase 3 and enhances IL-10 in the mucosa of children and adults with inflammatory bowel disease. *British J Nutrition* 103: 824–832.
40. [https://doi: 10.1017/S0007114509992510](https://doi.org/10.1017/S0007114509992510).

Figures

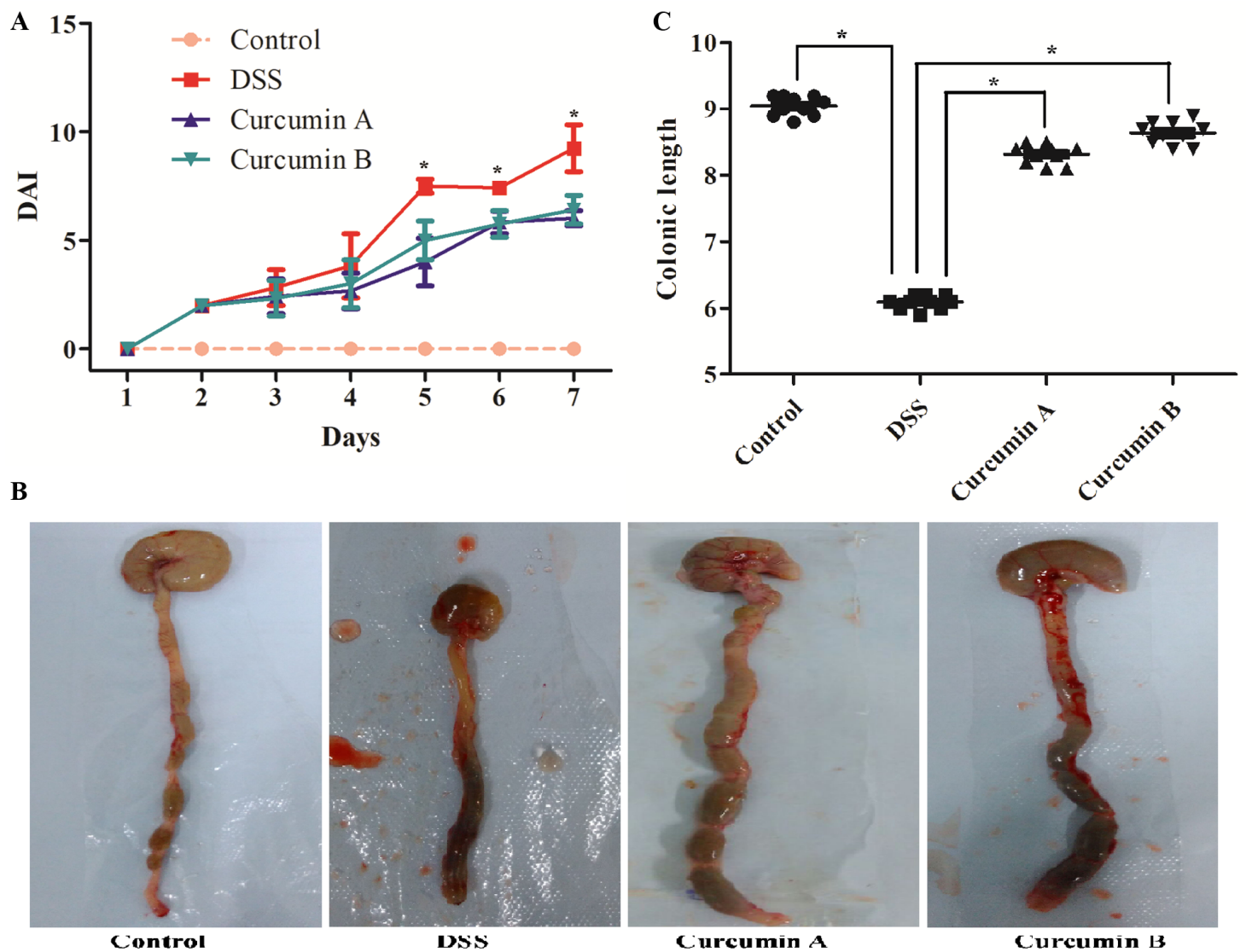


Figure 1

Curcumin treatment alleviates the severity of DSS-induced IBD. A: The trend in DAI of IBD rats. The DAI scores of the DSS group was significantly higher than that of the control group, and the DAI score of the curcumin A and B groups were significantly lower than that of the DSS group; * $P < 0.05$. B: Colon gross specimen changes. The lesion of colon gross specimen was mainly in the terminal ileum. C: The colon length of the rats in the curcumin A and B groups were significantly longer than that in the DSS group; * $P < 0.05$.

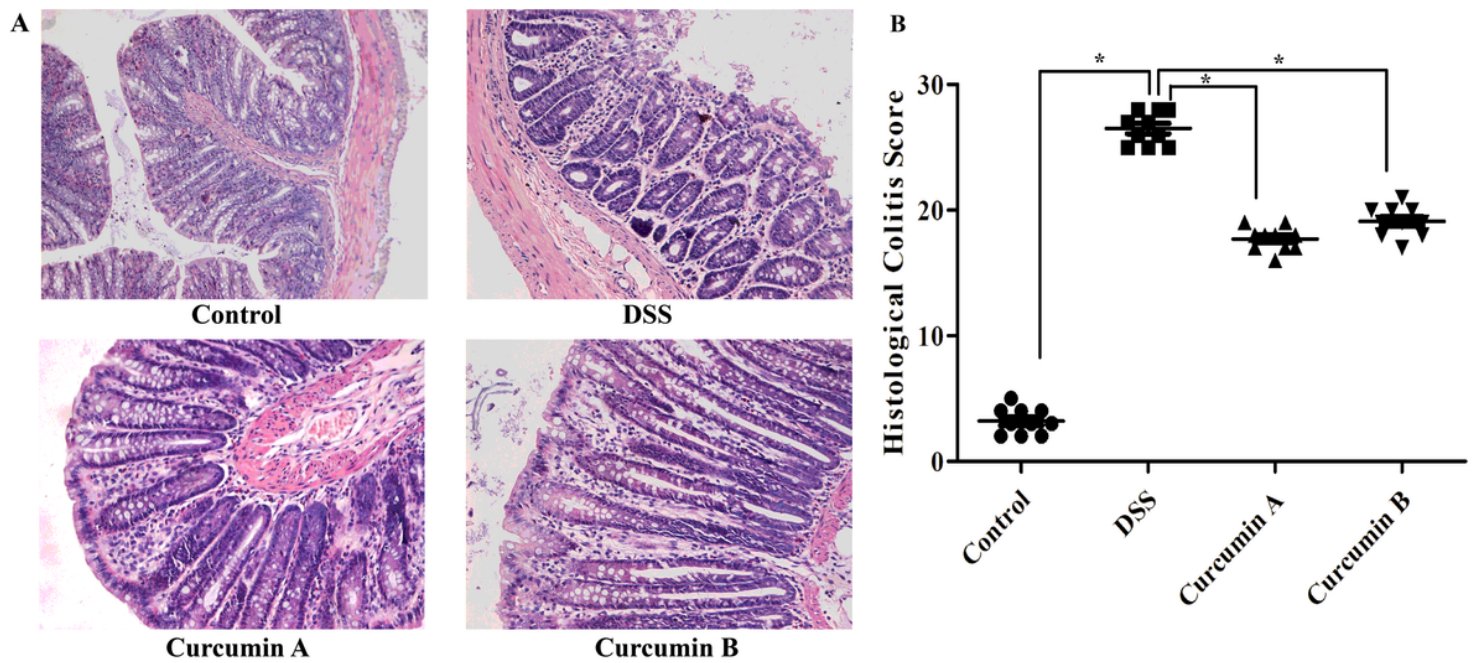


Figure 2

Pathological changes in the colon tissue of inflammatory bowel disease (IBD) rats after curcumin treatment. A shows the distal colon with H&E staining at 200×. B: Histopathology score, * $P < 0.05$, there was a significant difference between groups.

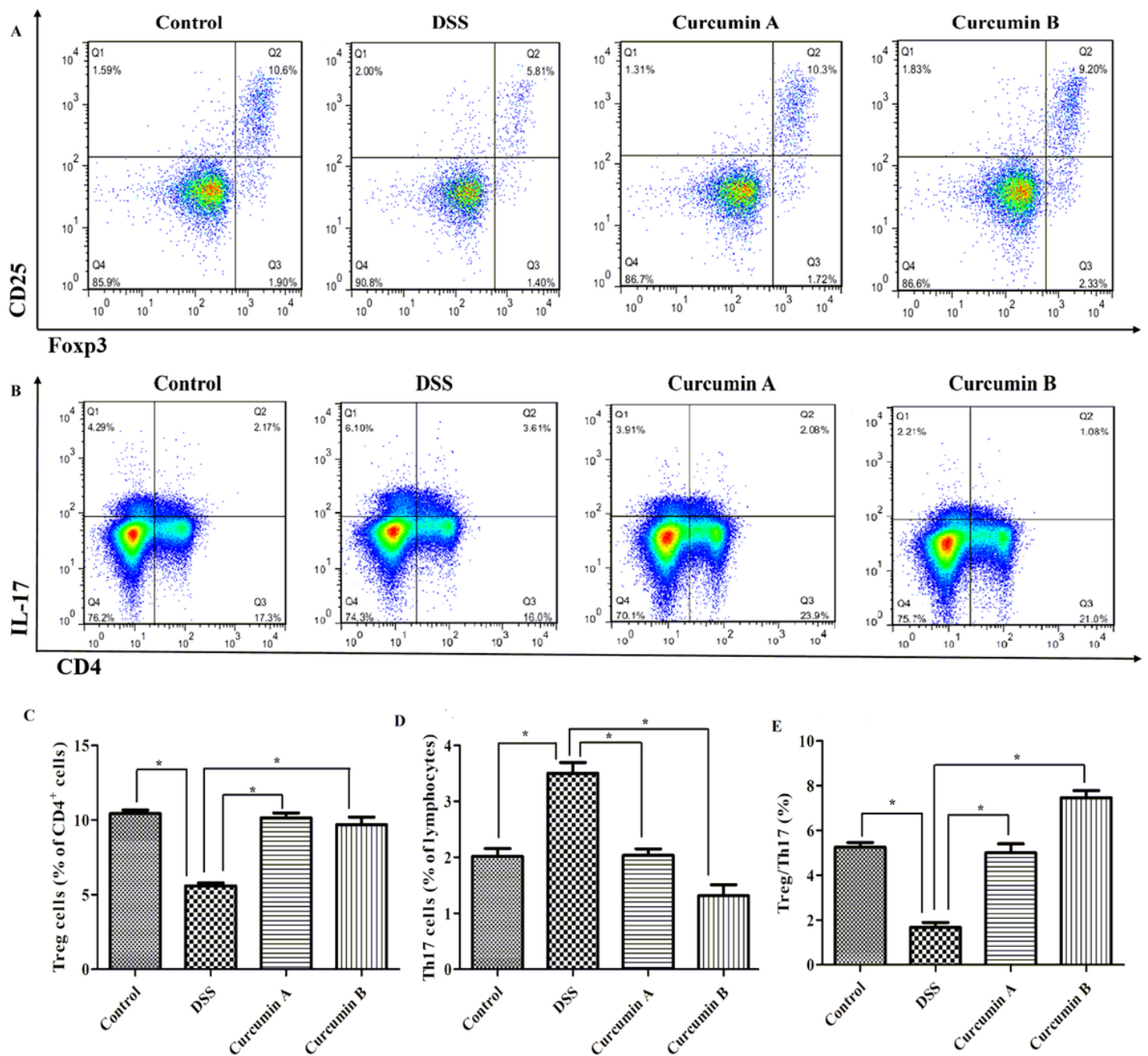


Figure 3

A: Effect of curcumin treatment on Treg cells. Percentages of Treg cells in the control group (10.6%), DSS group (5.81%), curcumin A group (10.3%), and curcumin B group (9.2%). B: Effect of curcumin treatment on Th17 cells. Percentages of Th17 cells in the control group (2.17%), DSS group (3.61%), curcumin A group (2.08%), and curcumin B group (1.08%). C: Analysis of the proportion of Treg cells in CD4⁺ T cells. D: Analysis of the proportion of Th17 cells. D: Analysis of the Treg/Th17 cell ratio. * $P < 0.05$, there was a significant difference between groups.

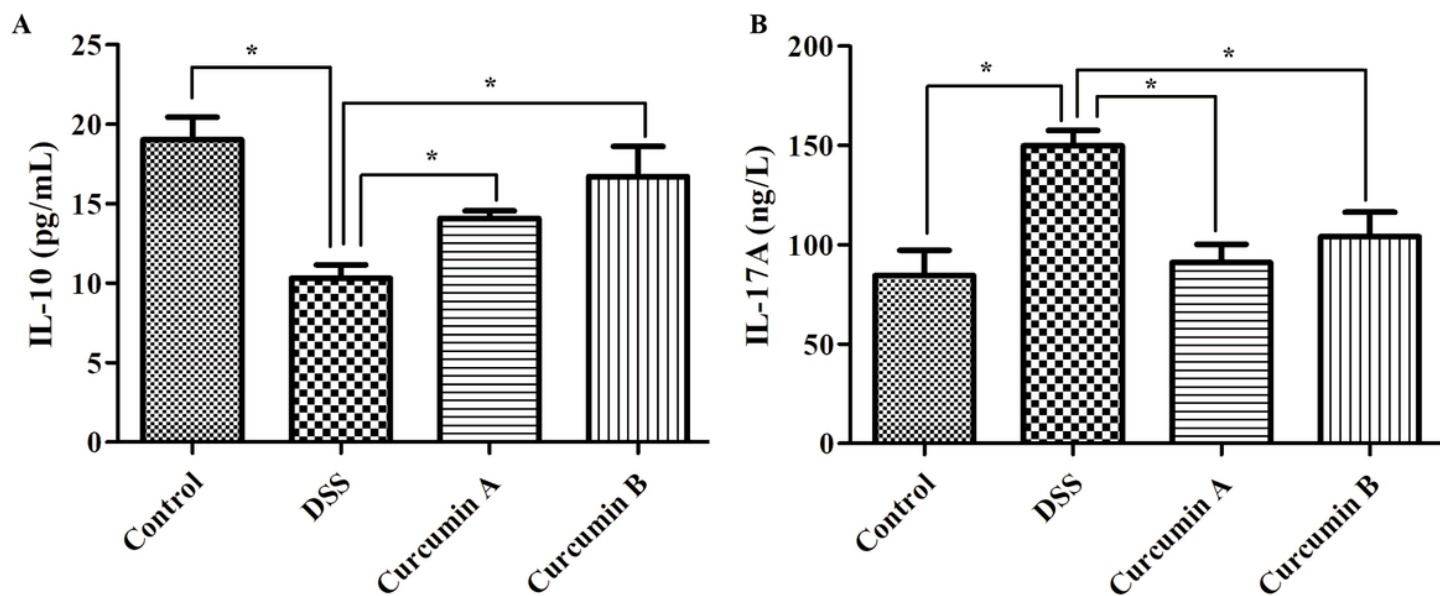


Figure 4

Effect of curcumin treatment on inflammatory cytokines. A: ELISA detection IL-10 levels in serum. B: ELISA detection IL-17A levels in serum. * $P < 0.05$, there was a significant difference between groups.