

Uterine Arteriovenous Fistula: Rare Cause of Vaginal Bleeding and Experience from 14 Case Series in a Single Center

Ruan fei

womens'hospital zhejiang university school of medical

wu zaigui (✉ 411773@zju.edu.cn)

zhejiang university <https://orcid.org/0000-0003-4033-872X>

zhou jianhong



womens'hospital zhejiang university school of medicine

Research

Keywords: Uterine Arteriovenous Fistula, Vaginal bleeding, uterine arteriovenous malformations, dilation and curettage, UAE

Posted Date: March 25th, 2020

DOI: <https://doi.org/10.21203/rs.3.rs-17773/v1>

License:   This work is licensed under a Creative Commons Attribution 4.0 International License.
[Read Full License](#)

Abstract

Background: This study aimed to summarize the characteristics of uterine arteriovenous fistul for proper treatment.

Methods: This was a retrospective study of fourteen women diagnosed with uterine arteriovenous fistul and eventually proved by pelvic angiography at our department.

Results: Six women presented with late postpartum hemorrhage and the other seven had abnormal uterine bleeding while only one was asymptomatic. The majority of them had uterine manipulation with the most common being repeated dilation and curettage but the time interval ranged from more than ten days to months even several years. they could originate from ovarian artery or internal iliac artery in rare cases and even some cases showed uterine artery- ovarian vein fistul. Most of them had a good outcome with bleeding resolved or mild bleeding after arterial embolization with controllable fever and pain, and only three cases had surgery unsuitable for embolization or formation of traffic branch after embolization.

Conclusions: uterine arteriovenous fistul were rare but easy to be diagnosed with characteristic ultrasound findings along medical history such as D&G and feature of vaginal bleeding. A successful treatment for artery embolization was based on careful evaluated vessels mapped by angiography while a comprehensive assessment with color and spectral flow Doppler was very necessary to exclude retained products of conception or placenta and avert unnecessary D&G after embolization. Surgical therapy was the last choice in women difficult to embolism or failed with UAE.

Background

Vaginal bleeding was common symptom of women in the emergency department. As one of the above causes, uterine arteriovenous malformations(AVMs) were rare but failure to diagnose it could give rise to improper treatment, life-threatening hemorrhage, or even unnecessary hysterectomy. Thus a prompt diagnosis and subsequent proper management was vital.

AVMs could be classified as congenital or acquired. Congenital AVMs was featured with multiple connections between arteries and veins due to abnormal embryologic development in the primitive capillary plexus[1] while acquired AVMs, named uterine arteriovenous fistul, lacked intervening capillary network between intramural arterial branches and the myometrial venous plexus[2]. In clinical, uterine arteriovenous fistul was more common than congenital AVMs and usually caused by all kinds of intrauterine manipulation such as dilation and curettage(D & C)[3]and therapeutic abortion[4],uterine surgery[5] and direct uterine trauma[6]. Other rare causes included but not limited to gestational trophoblastic disease(GTD)[7], endometrial carcinoma.

Besides the above history, ultrasound examination was necessary for abnormal vaginal bleeding patients. Color Doppler ultrasound demonstrated high-velocity arterial flow within the myometrium or

spectral analysis showed high peak systolic velocities with low-resistive index and pulsatile venous waveforms consistent with AV shunting[8]. Although the initial diagnosis could be made on the basis of sonographic and color Doppler, pelvic angiography remained the gold standard for diagnosis of uterine arteriovenous fistul as it could provide a precise mapping of vessels supplied by enlarged feeding arteries, early venous drainage into hypertrophied veins, and accumulation of contrast medium in the abnormal vasculature. The purpose of this paper was to retrospectively analyze the clinical process of patients with uterine arteriovenous fistul proved by pelvic angiography in our single centre to guide its diagnosis and treatment.

Patients And Methods

We conducted a retrospective study over a 7-year period from October 2012 to May 2019. Data and findings were collected from 14 patients diagnosed with uterine arteriovenous fistul who were proved by pelvic angiography eventually. Due to the retrospective nature of this study, the written informed consent were waived. Each patient's medical records including feature of vaginal bleeding, presumed etiology, time interval ,photographic images of ultrasound and angiography, feeding arteries and treatment outcomes were reviewed as follows.

Results

A total of 22 cases were diagnosed with uterine arteriovenous fistul by ultrasound examination and 14 of them were further proved by pelvic angiography. The other 8 patients were early pregnant and had artificial abortion without angiography nor serous bleeding(data not show). Only the 14 cases proved by angiography were included in the present paper.

The average age of the 14 cases at the diagnosis was 33.6 years.Six patients presented with postpartum hemorrhage,the mean time from delivery to diagnosing postpartum uterine arteriovenous fistul was 26.5 days with the earliest happened in 11 days after vaginal delivery and the latest nearly two months after cesarean section. Three women presented with aroxysmal, heavy vaginal bleeding and the other three with intermittent, minor bleeding. About the presumed etiology, most of them had D&G due to placenta accreta or implantation(Table 1). Uterine arteriovenous fistul resulted from gynecological operations or diseases often occurred a few months or even many years after the procedure. Three patients experienced persistent or repeated bleeding after abortion.Two patients presented only with long term increase of menstrual volume.One presented with heavy vaginal bleeding due to GTD though the HCG level was normal.One showed heavy vaginal bleeding after menopause with a history of hydatid mole 30 years ago. the uterine arteriovenous fistul in one women was diagnosed by routing ultrasound and had no sign of abnormal bleeding.(Table 2).

Table 1

Summary of patient data with postpartum uterine arteriovenous fistul

Case	Age	Childbearing	Feature of vaginal bleeding	HB(g/L)	Presumed etiology	Time interval(days)
1	32	2-0-1-2	Paroxysmal, heavy, 3 times	120	V-delivery, remove placenta manually	27
2	29	2-0-1-2	Paroxysmal, heavy, 620ml	66	V-delivery,placenta maternal surface rough	11
3	27	0-1-0-2	Intermittent, mild, 57 days	136	C-section,twin pregnancy,	57
4	34	2-0-0-2	Intermittent, minor, 1 + month	95	C-section, second time at 34 weeks,with	30
5	35	1-0-0-1	Repeated ,paroxysmal, heavy	82	C-section, remove placenta manually and	14
6	31	1-1-2-2	Intermittent, minor, 20 days	89	C-section, remove placenta manually and	20
			D&C for placenta implantation			

Table 2

Summary of patient data with abnormal uterine bleeding

Case	Age	Childbearing	Feature of vaginal bleeding	HB(g/L)	Presumed etiology	Time interval (days)
7	36	1-0-3-1	Increased menstrual volume	96	Hysteroscopy after MTX chemotherapy	11months only for 8 months 2 times for leakage suck
8	29	0-0-2-0	Persistent bleeding,1 month	64	D&G 2 days after bilateral uterine	30
9	29	1-0-0-1	Paroxysmal, heavy bleeding	36	D&C one time and irregular hormone	90+
10	39	1-0-3-1	Persistent bleeding,26 days	46	Repeated D&G and uterine packaging	26
11	27	1-0-0-1	Active bleeding along	122	GTN with normal HCG, 8 + months	with apsychia bilateral uterine artery embolization(other hospital)80+
12	53	2-0-1-2	Postmenopausal, heavy bleeding	116	Unknown, D&G for hydatid mole	30 years 2 times
13	44	1-0-0-1	Routine discovery on ultrasound	141	Laparoscopic myomectomy	3 years
14	26	0-0-3-0 (1 st)	Prolonged bleeding for1 month	116	Hysteroscopic adhesionectomy	60+
			(2 nd) Active bleeding about 400ml	82	3days after discharge	
			(3 rd) Excessive bleeding for 1 day	72	11days after embolization	

As to the enlarged feeding arteries,most of them originated from unilateral or bilateral uterine artery and even their branch, they can also stem from ovarian artery (case 11) or inferior gluteal artery (case 13) and the same is that the draining vein can come through ovarian vein (case 10,11,12) or iliac vein (case 13) (Tables 3 and 4).12 patients had one uterine arteries embolization while case 11 had a second embolization. After uterine arteries embolization, 4 patients' vaginal bleeding resolved ,7 improved with uterine arteriovenous fistul persisted.Case 14 still had repeated bleeding 11 days after embolization due to establishment of collateral circulation. Case 10 had active bleeding 8 hours after embolization due to the coexisted with retained products of conception. Case 7 had AVM resection directly by laparoscope for abundant feeding artery in myometrium. Postembolization syndrome consisting of low-grade fever and pelvic pain occurred in 58.3%(7/12) cases in present paper. The highest temperature reached to 39.2°Cin case 2 and usually happened in the first two days while the pain degree was related to the range of

embolization as described in case 13. These could be solved successfully by symptomatic treatments. (Table 3, 4)

Table 3
Mapping of vessels by angiography and treatments or outcomes

Case	Enlarged feeding arteries	Large draining vein	Embolized artery or Treatment	Outcome & complications
1	Right uterine artery	Right uterine vein	Right with 3 coils & 2 gelfoam strips	Mild bleeding branch from left uterine artery early drainage left with 1 coil & gelfoam grain no pain and fever
2	Right and left uterine arteries	Bilateral uterine vein	Bilateral uterine artery with	Bleeding resolved, fever gelfoam grain highest 39.2°C at D1
3	Left uterine artery	Left uterine vein	Left with gelfoam coarse grain	Persistent, mild bleeding early drainage right with gelfoam (1400–2000um) fever, highest 38.2°C at D2
4	Blood- supply generally normal in the myometrium	Bilateral uterine arteries	Bleeding resolved with gelfoam (1400–2000um)	fever, highest 38.8°C at D1
5	Bilateral uterine artery	Bilateral uterine vein	Bleeding resolved left with gelfoam (1400–2000um)	fever, highest 38.2°C at D2
6	Right uterine artery	Right uterine vein	Right with 2 coils & gelfoam grain	Persistent, mild bleeding left with gelfoam (1400–2000um) no pain and fever

Table 4
Mapping of vessels by angiography and treatments or outcomes

Case	Enlarged feeding arteries	Large draining vein	Embolized artery or Treatment	Outcome & complications
7	Abundant feeding artery in myometrium, difficult to embolism	Laparoscopic AVM resection	Bleeding resolved	
8	Right uterine artery	Right uterine vein	Expectant management because	Mild bleeding early drainage other hospital had embolization no pain and fever
9	Bilateral uterine artery	Bilateral uterine vein	Bilateral uterine artery	Mild bleeding Low-grade fever
10	Bilateral uterine artery, with left	Left ovarian vein	Left artery with 3 spring coils	Active bleeding 8 hours artery saccular aneurysm right with 1 coil & sponge gelatin after embolization no pain and fever
11	Left ovarian artery	Left ovarian vein	Second uterine artery embolization	Bleeding resolved Postembolization appearance in left uterine artery & abdominal AVM resection no pain and fever
12	Bilateral uterine artery, mainly	Bilateral ovarian vein	Left artery with 3 spring coils	Mild bleeding from the left artery early drainage right artery with 2 coils mild pain
13	Mainly from left inferior gluteal	Left internal iliac artery	with 8 spring coils	Severe pain in waist artery and left uterine artery, Left iliac vein right uterine artery with sponge gelatin and buttock, fever right uterine artery small branch (highest T 38.2°C)
14	(1 st) Bilateral uterine arteries	Bilateral uterine vein	Expectant management	Mild bleeding (2 nd) contrast agent effusion, Uterine vein early drainage Bilateral uterine artery Mild bleeding with gel foam strips no pain and fever
	(3 rd) Remove retained products and electrocoagulate two active bleeding vessels by hysteroscopy			Bleeding resolved

Discussion

Uterine arteriovenous fistul are rare entities and not all cases suspected on ultrasonography could be proved by pelvic angiography as reported in our paper, making difficulty in estimating the exact incidence[3]. They are usually caused by trauma resulting from uterine curettage, cesarean section, gestational trophoblastic neoplasia or endometrial neoplasia[4, 9, 10]. Of the six cases with postpartum uterine arteriovenous fistul, most of them had multiple risk factors including manual placenta extraction, infection, D&G for placenta accreta or implantation during cesarean section. The most common risk factor in patients presenting abnormal uterine bleeding remained D&G and even some patients had repeated D&G for cesarean section pregnancy. Another risk factor was hysteroscopic surgery due to complications from abortion such as leakage suck, bleeding, and uterine adhesion. Other rare factors were myomectomy and GTD. From Table 1 and Table 2 we could see that D&G was still the leading presumed etiology for uterine arteriovenous fistul, which was in line with literature[11]. As reported[12], the main clinical manifestation was vaginal bleeding characterized by paroxysmal-heavy or intermittent-mild while some presented only with prolonged or persistent vaginal bleeding or just increased menstrual volume. Vaginal bleeding occurred when vessels of uterine arteriovenous fistul were exposed from sloughing of the endometrium during the menstrual cycles or iatrogenic manipulation.

Ultrasonography including color and spectral flow Doppler was the first and essential examination for patients with abnormal vaginal bleeding[8, 13]. Uterine arteriovenous fistul were suspected when heterogeneous echo in myometrium as well as a cluttered vascular plexus with diffused distribution in myometrium and endometrium were found and there was a very rich blood flow signal presenting as lake-shape and uterine arteriovenous fistul spectral waveform showed in Table 5. Pelvic angiography by CT or MRI could mapping the vessels supplied by enlarged feeding arteries, early venous drainage into hypertrophied veins as summarized in Table 3 and Table 4. It is worth noting that though the vast majority of feeding arteries were uterine artery, it could come from inferior gluteal artery and ovarian artery in rare cases. Pelvic angiography remained the gold standard for diagnosing uterine arteriovenous fistul yet dynamic angio-MRI tended to replace it as first-line[14].

UAE was the primary treatment and vessels mapped by angiography were vital for making treatment planning and predicting the outcome of embolization[15]. There were 12 patients employed this method and UAE was performed using coils or gelatin sponge in present paper with total effective rate 83.3% (10/12). Case 11 failed because the enlarged feeding artery come from the left ovarian artery while case 14 had excessive bleeding and might have communication branches formed 11 days after UAE. Of the 12 cases, the post-embolization syndrome occurred in 58.3% (7/12) of cases and all was controlled with non-steroidal anti-inflammatory or antibiotics. Though case report demonstrated clinical success with repetitive embolization[15, 16], it was very important to carefully evaluate the collateral vessels as only when all arteries supplying the vascular malformation were embolized could clinical success be achieved. Took case 13 for example, if it was the uterine artery rather than the internal iliac artery that be occluded, the success rate would significantly reduced just because the enlarged feeding arteries mainly originated from left inferior gluteal artery and left uterine artery. Same conclusion could also be drew from case 11 and other reports[17]. When facilities of embolisation were available and patients were

suitable, uterine artery embolisation remained the preferred treatment, as it has a high success rate coupled with few controllable complications.

As retained products of conception or placenta was similar to uterine arteriovenous fistulae on color Doppler imaging[18], one issue should be emphasized was whether or not to have a D&G after embolization. Case 10 had D&G due to active bleeding 8 hours after embolization and proved to have retained placenta. Case 1 also had D&G for lesions in uterine cavity but scratched tissue was proved to be endometrium without placenta. Uterine arteriovenous fistulae frequently involved the myometrium and the endometrial cavity while the former usually was confined to endometrial cavity. Literature had also reported the peak systolic velocity as the crucial differentiating Doppler feature which was markedly elevated, typically 4–6 times higher than that of normal myometrial vessels in uterine arteriovenous fistulae[19]. The spectral waveforms obtained from pelvic vein near to uterine arteriovenous fistulae was pulsatile flow, opposed to that of patients with retained placenta tissue. It was a pity that peak systolic velocity and/or spectral waveforms were not measured at that time.

Except uterine artery embolization, the treatment methods still consisted of expectant management[20, 21] and surgical therapy. When applying conservative management, a global assessment should be made including the number of involved blood vessels, the presence of retained pregnant products as well as Doppler indices[22]. There were two cases (8 and 14) applying this method in present paper. Case 8 had D&G for cervix pregnancy after uterine artery embolization and succeeded in expectant management. Further examinations proved cervix lesion about 3cm in diameter with little blood by color Doppler and unilateral enlarged feeding uterine artery by a second pelvic angiography. Case 14 firstly had expectant management, but she had uterine artery embolization with gel foam strips due to active bleeding about 400 ml and CTA showed bilateral enlarged uterine arteries with contrast agent effusion as well as uterine vein early drainage. Not only that, she eventually had hysteroscopy to remove retained products and electrocoagulate two active bleeding vessels. Another two patients also had surgical therapy, of whom the case 7 had laparoscopic AVM resection for abundant feeding artery in myometrium difficult to embolism and the case 11 had abdominal AVM resection due to noneffective uterine artery embolization. Other traditional surgical therapies including hysterectomy[23], hypogastric artery ligation, uterine artery ligation[24] and even occlusion of internal iliac artery by laparoscopy[25] had also been reported. In a word, surgical therapy was the alternative choice in women difficult to embolism or failed with UAE.

Conclusions

uterine arteriovenous fistulae were rare but easy to be diagnosed with characteristic ultrasound findings along medical history such as D&G and feature of vaginal bleeding. A successful treatment for artery embolization was based on careful evaluated vessels mapped by angiography while a comprehensive assessment with color and spectral flow Doppler was very necessary to exclude retained products of conception or placenta and avert unnecessary D&G after embolization. Surgical therapy was the last choice in women difficult to embolism or failed with UAE.

Declarations

Abbreviations

AVMs :uterine arteriovenous malformations; D & C :dilation and curettage ;GTD:gestational trophoblastic disease

Authors' contributions

Wu zaigui collected the clinical data, analysis these data and drafted the manuscript. Ruan fei and Zhou jianhong helped to provide the topic. All authors read and approved the final manuscript.

Funding

his study was supported by the Zhejiang provincial Natural Science Foundation of China(Q19H040050) and Zhejiang provincial Science and Technology Plan projects (2019KY431). Both the two funding body played a role in designing the study and writing the manuscript.

Competing interests.

The authors declare that they have no competing interests.

Consent for publication

Written informed consent has been obtained from all the cases or her guardian of 17 years old for publication of this paper report.The authors declare that they have no competing interests.

Ethical approval and consent to participate.

This research conformed to the provisions of the Declaration of Helsinki and was approved by the ethics committee of Women's hospital Zhejiang University(No:2019034).The patients were informed and provided her written informed consent.

Availability of data and materials

The data-sets used and /or analyzed during the current study are available from the authors on reasonable request.

Acknowledgements

We would thank zou yu for his providing the CTA images.

References

1.
O'Brien P, Neyastani A, Buckley AR, Chang SD, Legiehn GM. Uterine arteriovenous malformations: from diagnosis to treatment. *J Ultrasound Med*. 2006;25:1387–92, 1394–1395.
2.
Ghai S, Rajan DK, Asch MR, Muradali D, Simons ME, TerBrugge KG. Efficacy of embolization in traumatic uterine vascular malformations. *J VASC INTERV RADIOL*. 2003;14:1401–8.
3.
Peitsidis P, Manolakos E, Tsekoura V, Kreienberg R, Schwentner L. Uterine arteriovenous malformations induced after diagnostic curettage: a systematic review. *ARCH GYNECOL OBSTET*. 2011;284:1137–51.
4.
Javed A, Chander R, Hoodbhoy Z. Uterine Arteriovenous Malformations after Suction Evacuation of Missed Miscarriage. *J Coll Physicians Surg Pak*. 2018;28:33–4.
5.
Sharma A, Vogelzang RL. Uterine arteriovenous fistula as a long-term complication of hysterectomy: presentation and management. *OBSTET GYNECOL*. 2009;113:489–91.
6.
Chaabane K, Louati D, Fourati H, Feki W, Sahbi K, Amouri H, Mnif Z. M. Guermazi. [Traumatic uterine arteriovenous fistula: report of one case]. *Tunis Med*. 2013;91:616–7.
7.
McGrath S, Harding V, Lim AK, Burfitt N, Seckl MJ, Savage P. Embolization of uterine arteriovenous malformations in patients with gestational trophoblastic tumors: a review of patients at Charing Cross Hospital, 2000–2009. *J REPROD MED*. 2012;57:319–24.
8.
Aiyappan SK, Ranga U, Veeraiyan S. Doppler Sonography and 3D CT Angiography of Acquired Uterine Arteriovenous Malformations (AVMs): Report of Two Cases. *J Clin Diagn Res*. 2014;8:187–9.
9.
Touhami O, Gregoire J, Noel P, Trinh XB, Plante M. Uterine arteriovenous malformations following gestational trophoblastic neoplasia: a systematic review. *Eur J Obstet Gynecol Reprod Biol*. 2014;181:54–9.

10.

Kim TH, Lee HH, Kwak JJ. Conservative management of abnormally invasive placenta: choriocarcinoma with uterine arteriovenous fistula from remnant invasive placenta. *Acta Obstet Gynecol Scand*. 2013;92:989–90.

11.

Evans A, Gazaille RR, McKenzie R, Musser M, Lemming R, Curry J, Meyers W. N. Austin. Acquired uterine arteriovenous fistula following dilatation and curettage: an uncommon cause of vaginal bleeding. *Radiol Case Rep*. 2017;12:287–91.

12.

Singh N, Tripathi R, Mala YM, Tyagi S, Tyagi S, Singh C. Varied presentation of uterine arteriovenous malformations and their management by uterine artery embolisation. *J OBSTET GYNAECOL*. 2014;34:104–6.

13.

Scioscia M, Zantedeschi B, Trivella G, Fratelli N, Cosma S, Minelli L. A suggestive diagnosis of uterine arteriovenous fistula based on ultrasonography and hysteroscopy. *Eur J Obstet Gynecol Reprod Biol*. 2012;160:116–7.

14.

Vandenbroucke L, Morcel K, Bruneau B, Moquet PY, Bauville E, Leveque J. V. Lavoue. [Acquired uterine arteriovenous malformations]. *Gynecol Obstet Fertil*. 2011;39:469–72.

15.

Yoon DJ, Jones M, Taani JA, Buhimschi C, Dowell JD. A Systematic Review of Acquired Uterine Arteriovenous Malformations: Pathophysiology, Diagnosis, and Transcatheter Treatment. *AJP Rep*. 2016;6:e6–14.

16.

Hasegawa A, Sasaki H, Wada-Hiraike O, Osuga Y, Yano T, Usman SM, Akahane M, Kozuma S. Y. Taketani. Uterine arteriovenous fistula treated with repetitive transcatheter embolization: case report. *J Minim Invasive Gynecol*. 2012;19:780–4.

17.

Guo N, Liu H, Peng Z. Uterine arteriovenous fistula necessitating hysterectomy after two unsuccessful embolizations in an 18-year-old patient. *ANN VASC SURG*. 2010;24:827–9.

18.

Aziz N, Lenzi TA, Jeffrey RJ, Lyell DJ. Postpartum uterine arteriovenous fistula. *OBSTET GYNECOL*. 2004;103:1076–8.

19.

Kwon JH, Kim GS. Obstetric iatrogenic arterial injuries of the uterus: diagnosis with US and treatment with transcatheter arterial embolization. *RADIOGRAPHICS*. 2002;22:35–46.

20.

Mekaru K, Oishi S, Akamine K, Heshiki C, Aoki Y. Spontaneous Regression of Uterine Arteriovenous Malformations with Conservative Management. *Case Rep Obstet Gynecol*. 2017;2017:6437670.

21.

- Taneja A, Chopra I, Kaur H, Naik SS, Aggarwal R, Sachdeva E, Kaur P. Successful management of abnormal uterine bleeding from uterine arteriovenous malformations with progesterone in postabortal patients. *J Obstet Gynaecol Res.* 2019;45:1114–7.
- 22.
- Lee TY, Kim SH, Lee HJ, Kim MJ, Lee SK, Kim YH. S.H. Cho. Ultrasonographic indications for conservative treatment in pregnancy-related uterine arteriovenous malformations. *ACTA RADIOL.* 2014;55:1145–52.
- 23.
- Guo N, Liu H, Peng Z. Uterine arteriovenous fistula necessitating hysterectomy after two unsuccessful embolizations in an 18-year-old patient. *ANN VASC SURG.* 2010;24:827–9.
- 24.
- Bettaiah R, Kamath SS. Laparoscopic Uterine Artery Ligation for Uterine Arteriovenous Malformation. *J Minim Invasive Gynecol.* 2018;25:1124–5.
- 25.
- Levy-Zaubermann Y, Capmas P, Legendre G, Fernandez H. Laparoscopic management of uterine arteriovenous malformation via occlusion of internal iliac arteries. *J Minim Invasive Gynecol.* 2012;19:785–8.

Figures

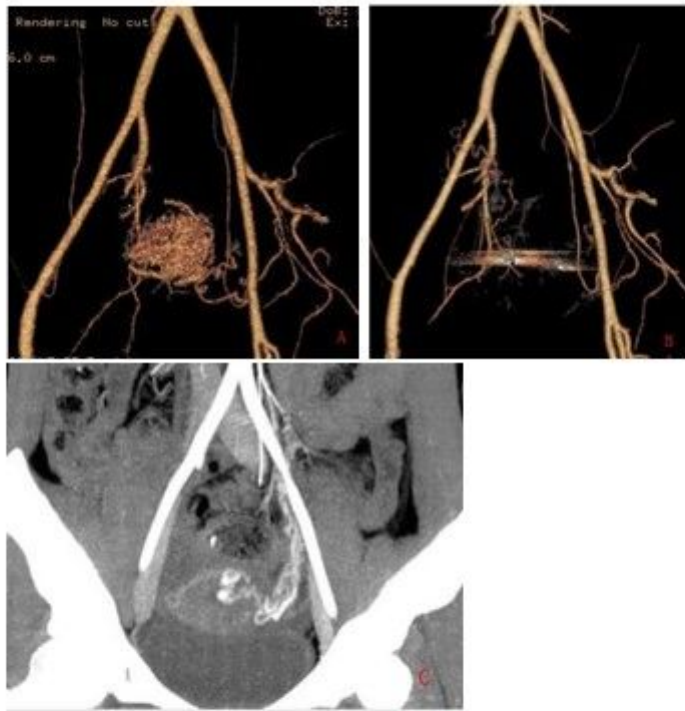


Figure 1

CTA image of the pelvis from case 1 (A,B) and case 11(C).