

Surgical Management of Bacille Calmette-Guérin Vaccine-related Regional Lymphadenitis in Infants

Chen Liu

Binzhou medical university hospital <https://orcid.org/0000-0002-0250-1875>

Minxiang Huang

Binzhou Medical University Hospital

Lei Geng

Binzhou Medical University Hospital

Guojian Ding

Binzhou Medical University Hospital

Xijie Liu

Binzhou Medical University Hospital

Bufeng Zheng

Binzhou Medical University Hospital

Wenyu Feng

Binzhou Medical University Hospital

Tingliang Fu

Binzhou Medical University Hospital

Xiaoliang Xu (✉ xuxiaoliang1983@163.com)

Binzhou Medical University Hospital <https://orcid.org/0000-0003-3994-6154>

Research

Keywords: Bacille Calmette-Guérin vaccine, Lymphadenitis, Surgical management, Infants

Posted Date: February 4th, 2021

DOI: <https://doi.org/10.21203/rs.3.rs-175204/v1>

License:   This work is licensed under a Creative Commons Attribution 4.0 International License.

[Read Full License](#)

Abstract

Background

The management of Bacille Calmette-Guérin (BCG) vaccine-related regional lymphadenitis in infants is still controversial. We present the results of surgical treatment for this condition.

Aim

To report our experience in the surgical management in infants with BCG vaccine-related regional lymphadenitis.

Results

From January 2013 to June 2020, 65 patients with BCG vaccine-related regional lymphadenitis were retrospectively reviewed. The patients included 55 boys and ten girls. Median age was 3.35 months (5.83 ± 8.17 , IQR 3.35-5.1). The infants were all full-term with normal birth weight and received vaccination in the first 24 h of life. All patients underwent surgical excision of the abscess and involved regional lymph nodes, and tolerated anesthesia and the surgical procedure well. Postoperative seroma occurred in 20 patients (20/65). The effusion was aspirated with a fine needle. Sixty-four patients recovered uneventfully. No anti-tuberculosis drugs were given postoperatively. Postoperative abscess recurred in one case and re-operation was required one year later. Postoperative follow-up of three to 12 months showed that all patients had a good outcome.

Conclusion

Surgical management of infantile BCG vaccine-related lymphadenitis is safe and effective with a low recurrence rate and few complications. Surgical intervention shortened the treatment period and avoided the use of anti-tuberculosis drugs. Surgeons should follow the natural course of this disease and be cautious in choosing surgical treatment.

Highlights

1. BCG vaccine-related lymphadenitis, defined as the development of ipsilateral regional enlarged lymph node following BCG vaccination, is considered as one of the most common complications
2. The use of anti-tuberculous drugs for infants may have a high incidence of the adverse effects. Some authors have reported that oral erythromycin or anti-tuberculous drugs such as isoniazid (alone or in combination with rifampin) for BCG lymphadenitis treatment have no significant effects on both of suppurative lymphadenitis and ulceration.
3. Surgical management of infantile BCG vaccine-related lymphadenitis is safe and effective with a low recurrence rate and few complications. Surgical intervention shortened the treatment period and

avoided the use of anti-tuberculosis drugs. Surgeons should follow the natural course of this disease and be cautious in choosing surgical treatment.

Introduction

The original strain of *Mycobacterium bovis* Bacille Calmette-Guérin (BCG) strain was first isolated by Calmette and Guérin and used for immunization of tuberculosis in 1921^[1, 2]. BCG was incorporated into the Expanded Program of Immunization (EPI) by the World Health Organization (WHO) in 1974^[3]. At present, there are various strains of BCG vaccines in use around the world. BCG D2 PB302S A 10 strain, a passage strain of BCG Danish 823 has been used in China since 1993^[4]. BCG vaccination of infants has reduced the risk of pulmonary tuberculosis by over 50%^[3, 5]. However, local or systemic adverse reactions related to BCG vaccination have been increasingly reported, such as regional lymphadenitis in the axillary, supraclavicular or cervical area with suppuration^[1, 6-8]. The incidence of BCG vaccination-induced lymphadenitis is approximately 2 to 5 per 1000 vaccinations^[6, 9]. Some authors have reported the results of non-operative management with anti-tuberculosis drugs for regional lymphadenitis and abscess formation^[10-14]. However, infants may have a risk of adverse reactions to anti-tuberculosis medications^[15, 16]. Surgical treatment of BCG vaccine-related regional lymphadenitis has been reported in recent years^[1, 17]. Thus, we report our experience in the surgical management of BCG vaccine-related lymphadenitis in children.

Materials And Methods

Seventy-six patients with ipsilateral regional lymphadenitis following BCG vaccination were admitted to our institute between January 2013 and June 2020. Sixty-five patients met the inclusion criteria, which were as follows: (1) Accurate medical history of BCG vaccination and no history of close contact with active tuberculosis; (2) All children, up to 5 years of age, presenting with BCG vaccine-related lymphadenitis who had been given 0.1 mL of BCG vaccine intradermally at birth; (3) The clinical manifestations were a painless mass with internal liquefaction in the lymphatic drainage area at the inoculation side (mainly in the axillary, supraclavicular, chest wall area), or the involved skin, perforation, or chronic sinus tract formation with fluctuant and enlarged lymph nodes in the above areas; (4) The patients did not have immunodeficiency disease or generalized lymphadenopathy or non-specific lymphadenitis; (5) Other contraindications for the surgical procedure. All the patients' guardians were informed regarding the details of the procedure and they provided a signed consent form. Age in months, gender, gestational weeks, total leucocyte count (TLC), percentage of lymphocytes (LYM%), hemoglobin (HB) level, chest X ray (CXR) findings, ultrasonographic findings, pathological findings, the time of suture removal and hospital stay were recorded. Data were analyzed using Microsoft Excel 2020. Average (AVG), median (M), standard deviation (SD), and interquartile range (IQR) were noted.

Operative treatment and postoperative management

Fine-needle aspiration before surgery was performed to obtain pus for acid fast bacilli (AFB) and Gram staining and culture. In the liquefied and erythema area, a dermatoglyphic shuttle-shaped incision was made. The involved lymph node(s) with abscess were excised en bloc (Fig. 1). The blood vessel from the involved lymph node(s) was ligated using an absorbable suture. After removal of the mass, the wound cavity was flushed with isoniazid injection (50 mg in 5 mL sterilized normal saline). The incision was sutured without drainage and bandaged with appropriate pressure. Histopathological examination of all samples was performed. Dressing change was carried out on the second postoperative day. The skin sutures were removed on the ninth to tenth postoperative day.

Results

Of 65 patients included, 55 (84.62%) were male and ten (15.38%) were female, and the male to female ratio was approximately 5.5:1. All the infants were full-term with normal birth weight and received the vaccination in the first 24 h of life. The median age at development of symptoms was 3.35 months (5.83 ± 8.17 , IQR 3.35–5.1, range, 1 to 52 months). The clinical course ranged from 1 to 60 days. Physical examination revealed regional non-tender lymphadenopathy in the left axillary (Fig. 2), supraclavicular or neck region. The median diameter of lymph nodes examined by ultrasonography was 2.2 cm (the mean diameter was 2.25 ± 0.65 cm). Ulceration with discharge from the mass was present in three cases (5%). A single region was involved in 63 cases (96.92%) and the left axilla was mainly affected (59/65, 90.77% cases). The left axillary lymph node was involved in 61 cases (93.85%, included 59 cases in a single region and 2 cases involving another region simultaneously). The left supraclavicular lymph node was involved in three cases (4.62%). The left cervical lymph node was involved in one case (1.54%). The left axillary and left supraclavicular lymph nodes were simultaneously involved in one case (1.54%). Enlargement of the left axillary and subscapularis dorsi intramuscular lymph node were simultaneously involved in one case (1.54%). No fever, night sweat, emaciation, or other symptoms were observed in these patients. TLC was normal in 25 cases (38.46%) and increased in 40 cases (61.54%). LYM% increased in all cases (100%) and HB level decreased in 26 cases (40%). Chest X-ray and ultrasound examination were carried out in all patients. No lung lesions were found in any of the cases. A lumpy high-density shadow was seen in the left armpit in eight cases (12.3%) by CXR. Ultrasonography examination showed enlarged lymph node(s), the presence or absence of liquefaction indicating abscess formation or proliferative lesions. Bacterial culture was negative in twenty-three cases (23/23). No acid fast bacilli were noted on acid fast staining in twenty cases (20/20). Gram staining was negative in eight cases (8/8). Pathological findings in all cases showed typical tuberculous granulomatous lesions in the involved lymph nodes and abscess (Fig. 3). The existence of epithelioid cells, multinucleated giant cells, and lymphocytic infiltration in the involved lymph nodes were consistent with BCG vaccine-related lymphadenitis.

Seroma formation occurred in 20 patients postoperatively (20/65, 30.77%). The effusion was aspirated with a fine needle approximately two to five times after strict disinfection. The wound was bandaged with appropriate pressure. The incision healed with no complications in all cases. Sutures were removed on the ninth or tenth day after surgery. The mean hospitalization time after surgery was 4 ± 1.62 days.

No anti-tuberculosis drugs were given postoperatively in 65 cases. An involved lymph node was missed in one patient. After receiving anti-tuberculosis drugs for 4 months, the patient underwent re-operation due to frequent recurrence of the abscess for one year. The patient recovered uneventfully after the second operation. All patients had a good recovery during the three to 12 months postoperative clinical follow-up.

Discussion

BCG is a live attenuated vaccine which is extensively used worldwide^[2, 18]. BCG-associated adverse events include injection site abscess and ulceration, BCG vaccine-related lymphadenitis, osteomyelitis and disseminated BCG diseases^[2, 19], which were classified into five categories, *i.e.*, adverse event (AE), adverse reaction (AR), severe adverse event (SAE), severe adverse reaction (SAR), and suspected unexpected severe adverse reaction (SUSAR)^[20]. BCG vaccine-related lymphadenitis, defined as the development of ipsilateral regional enlarged lymph nodes following BCG vaccination, is considered to be one of the most common complications^[8, 18]. Regional and suppurative lymphadenitis were classified as AR and if leading to hospitalization, they were classified as SAE^[20].

The occurrence of BCG vaccine-related lymphadenitis is mainly due to improper vaccination, such as the vaccinators' skills and experience, subcutaneous injection, excessive dose of BCG and residual virulence of BCG strain, immunocompromised individuals, younger age, *etc*^[5,21-23].

In Sadeghi-Shanbestari study, except for 2 cases who were under 3 years old, the rest were male and they were less than one year old, and 48 infants with BCG lymphadenitis, within range of 2–62 months (9.9 ± 9.85) were selected^[24]. In our study, except 5 cases that were within 4.4 years old, all of them were younger than one year old, and 65 infants with BCG lymphadenitis, within range of 1–52 months (5.83 ± 8.17) were selected. The results were similar.

BCG vaccine-related lymphadenitis is classified into two forms: suppurative and non-suppurative. Approximately 60% of non-suppurative lymphadenitis develops into suppurative lymphadenitis, the affected lymph nodes show swelling and redness of the overlying skin, abscess formation (with fluctuation), and eventually rupture and a sinus tract is formed^[12, 19, 21]. In our study, BCG vaccine-related lymphadenitis frequently involved the left axillary lymph node, followed by the supraclavicular lymph node, and left cervical lymph node. Occasionally, lesions were observed in the left axillary and supraclavicular lymph nodes or left axillary and left subscapular latissimus dorsi lymph nodes. Similar results were reported by Bukhari^[12]. As the injection site for the vaccine is usually located on the left arm, BCG-related lymphadenitis occurred in the ipsilateral axillary, and even in the neck or back. Some experts have reported that right axillary lymphadenitis occurs when the injection site is on the right arm^[25].

Although several methods for the management of regional lymphadenitis with abscess formation have been reported^[1, 3, 7, 21], each method has advantages and disadvantages. Nowadays, the reported methods include clinical observation, oral antituberculosis drugs, needle aspiration, incision and drainage, and surgical excision of lymph nodes. Non-suppurative lymphadenitis (< 1 cm) is suitable for

observation and in some cases may resolve spontaneously^[5]. Some authors have reported that oral erythromycin or anti-tuberculosis drugs such as isoniazid (alone or in combination with rifampin) for BCG vaccine-related lymphadenitis treatment had no significant effects on both suppurative lymphadenitis and ulceration. The use of anti-tuberculosis drugs in infants may lead to a high incidence of adverse effects^[7].

Needle aspiration with or without instillation of isoniazid or rifampicin can decrease the occurrence of spontaneous rupture but does not debride the lesions^[5, 21, 26, 27]. Surgical management of BCG vaccine-related lymphadenitis has been reported to have fewer side effects and shorter treatment time^[10, 13, 17, 28]. In the present study, 65 children with BCG vaccine-related lymphadenitis underwent excision of the lesions en bloc, and most patients recovered uneventfully.

Postoperative seroma formation occurred in 20 patients (20/65, 30.77%), the effusion was aspirated using a fine needle and the wound was bandaged with appropriate pressure after aspiration. The seroma disappeared after two to five aspirations. Only one child required re-operation due to abscess recurrence. The average length of hospital stay in our study was 9.32 ± 2.34 days (range: 4–17 days). Nazir *et al*^[29] found that of all the patients who received anti-tuberculosis drug treatment for one to nine months, fifty-two children who presented with large fluctuant lymph nodes required a surgical procedure. However, surgical management can shorten the duration of healing.

Although our study shows that surgical treatment of BCG vaccine-related lymphadenitis has many advantages, we should also follow its natural course and be cautious in choosing surgical treatment. In our experience, surgeons should pay more attention to the following steps. (1) large abscesses should be aspirated before excision to avoid rupture and contamination of the wound; (2) the extent of the deep tissues to be excised should be limited to the involved parts in order to protect the axillary vessels, nerves and normal lymph nodes. In some cases, lesions may tightly adhere to the axillary sheath, and electrocautery should not be used as underlying axillary vessels and nerves may be damaged; (3) before suturing the incision, fluid and air should be removed and the wound bandaged with appropriate pressure to decrease the risk of seroma formation.

Conclusion

Surgical management of infantile BCG vaccine-related lymphadenitis is safe and effective with a low recurrence rate and few complications. Surgical intervention shortened the treatment period and avoided the use of anti-tuberculosis drugs.

Abbreviations

BCG: Bacille Calmette-Guérin; EPI: Expanded Program of Immunization; WHO: World Health Organization; TLC: total leucocyte count; LYM%: percentage of lymphocytes; HB: hemoglobin; CXR: chest X ray; AVG: Average; M: median; SD: standard deviation; IQR: interquartile range; AFB: acid fast bacilli; AE: adverse

event; AR: adverse reaction; SAE: severe adverse event; SAR: severe adverse reaction; SUSAR: suspected unexpected severe adverse reaction.

Declarations

Acknowledgments

We thank all the patients and their families who participated in this study and acknowledge the assistance of colleagues in the Department of Pediatric Surgery, Binzhou Medical University Hospital, Binzhou, Shandong Province, China.

Authors' contribution

LC conducted data collation, data analysis and interpretation, drafted the manuscript, and revised the manuscript. HMX, GL, DGJ, LXJ, ZBF, and FWY participated in data collection. FTL assisted in the concept, design, data interpretation, revision, and final approval of the article. XXL assisted in the concept, design, revision and final approval of the article. All authors re-checked the data and data analysis, reviewed the manuscript, and provided important content and a relevant literature search.

Funding

None.

Availability of data and materials

All data generated or analysed during this study are included in this published article.

Competing interests

The authors declare that they have no competing interests.

Informed Consent

All of the patients' guardian were informed regarding the details of the procedure and they signed a written consent form.

References

1. Abdulhameed FD, Hummida Tarig I. Surgical Management of BCG Vaccine-Induced Regional Lymph Nodes Adverse Effects. *Annals of Pediatric Surgery*. 2009; 5(3): 187-93
2. Yang TL, Lee CM, Lee KL, et al. Clinical features of tuberculosis and Bacillus Calmette-Guerin (BCG) - associated adverse effects in children: A 12-year study. *J Formos Med Assoc*. 2020; S0929-6646(20)30241-2. <http://dx.doi.org/10.1016/j.jfma.2020.06.012>

3. Suliman OM, Ahmed MJ, Bilal JA. Clinical characteristics and needle aspiration management of Bacillus Calmette-Guerin lymphadenitis in children. Saudi Med J. 2015; 36(3): 280-5.
<http://dx.doi.org/10.15537/smj.2015.3.10294>
4. Zhao AH, Wang GZ, Fu LL, et al. Comparison of BCG vaccine quality standards of domestic and foreign. Chin J Antituberc. 2018; 40(10): 1125-8. [in Chinese with English abstract]
5. Elsidig N, Alshahrani D, Alshehri M, et al. Bacillus Calmette-Guerin vaccine related lymphadenitis in children: Management guidelines endorsed by the Saudi Pediatric Infectious Diseases Society (SPIIDS). Int J Pediatr Adolesc Med. 2015; 2(2): 89-95. <http://dx.doi.org/10.1016/j.ijpam.2015.05.003>
6. Holliday T, Seddon J, Whittaker E. G157(P) Adverse events in infants following bcg vaccination: preliminary results. Archives of Disease in Childhood. 2019; 104(Suppl 2): A64.
<http://dx.doi.org/10.1136/archdischild-2019-rcpch.153>
7. Goraya JS, Viridi VS. Treatment of Calmette-Guerin bacillus adenitis: a metaanalysis. Pediatr Infect Dis J. 2001; 20(6): 632-4. <http://dx.doi.org/10.1097/00006454-200106000-00020>
8. Rermruay R, Rungmaitree S, Chatpornvorarux S, et al. Clinical features and outcomes of Bacille Calmette-Guerin (BCG)-induced diseases following neonatal BCG Tokyo-172 strain immunization. Vaccine. 2018; 36(28): 4046-53. <http://dx.doi.org/10.1016/j.vaccine.2018.05.098>
9. Bai QR, Hu JY, Wu LL, et al. Survey on adverse reaction rate of Bacillus Calmette-Guérin in Shanghai. Shanghai J Prevent Med. 2018; 30(7): 562-5. [in Chinese with English abstract]
10. Caglayan S, Yegin O, Kayran K, et al. Is medical therapy effective for regional lymphadenitis following BCG vaccination? Am J Dis Child. 1987; 141(11): 1213-4. PubMed PMID: 3673975.
11. Bolursaz MR, Lotfian F, Velayati AA. Bacillus Calmette-Guerin vaccine complications in Iranian children at a University Hospital. Allergol Immunopathol (Madr). 2017; 45(4): 356-61. <http://dx.doi.org/10.1016/j.aller.2016.10.006>
12. Bukhari E, Alzahrani M, Alsubaie S, et al. Bacillus Calmette-Guerin lymphadenitis: A 6-year experience in two Saudi hospitals. Indian J Pathol Microbiol. 2012; 55(2): 202-5. <http://dx.doi.org/10.4103/0377-4929.97869>
13. Noah PK, Pande D, Johnson B, et al. Evaluation of oral erythromycin and local isoniazid instillation therapy in infants with Bacillus Calmette-Guerin lymphadenitis and abscesses. Pediatr Infect Dis J. 1993; 12(2): 136-9. <http://dx.doi.org/10.1097/00006454-199302000-00006>
14. Kuyucu N, Kuyucu S, Ocal B, et al. Comparison of oral erythromycin, local administration of streptomycin and placebo therapy for nonsuppurative Bacillus Calmette-Guerin lymphadenitis. Pediatr Infect Dis J. 1998; 17(6): 524-5. <http://dx.doi.org/10.1097/00006454-199806000-00020>
15. Li Y, Zhu Y, Zhong Q, et al. Serious Adverse Reactions From Anti-tuberculosis Drugs Among 599 Children Hospitalized for Tuberculosis. Pediatr Infect Dis J. 2017; 36(8): 720-5.
<http://dx.doi.org/10.1097/INF.0000000000001532>
16. Nansumba M, Kumbakumba E, Orikiriza P, et al. Treatment outcomes and tolerability of the revised WHO anti-tuberculosis drug dosages for children. Int J Tuberc Lung Dis. 2018; 22(2): 151-7.
<http://dx.doi.org/10.5588/ijtld.17.0535>

17. Naumeri F, Khan MS, Rauf A, et al. Role of needle aspiration and surgical excision in management of suppurative Bacillus Calmette Guerin lymphadenitis. *J Pak Med Assoc.* 2018; 68(7): 1120-3. PubMed PMID: 30317317.
18. Venkataraman A, Yusuff M, Liebeschuetz S, et al. Management and outcome of Bacille Calmette-Guerin vaccine adverse reactions. *Vaccine.* 2015; 33(41): 5470-4.
<http://dx.doi.org/10.1016/j.vaccine.2015.07.103>
19. Daei Parizi M, Kardoust Parizi A, Izadipour S. Evaluating clinical course of BCG lymphadenitis and factors affect on it during a 5-year period in Kerman, Iran. *J Trop Pediatr.* 2014; 60(2): 148-53.
<http://dx.doi.org/10.1093/tropej/fmt100>
20. Nissen TN, Birk NM, Kjaergaard J, et al. Adverse reactions to the Bacillus Calmette-Guerin (BCG) vaccine in new-born infants-an evaluation of the Danish strain 1331 SSI in a randomized clinical trial. *Vaccine.* 2016; 34(22): 2477-82. <http://dx.doi.org/10.1016/j.vaccine.2016.03.100>
21. Goraya JS, Viridi VS. Bacille Calmette-Guerin lymphadenitis. *Postgrad Med J.* 2002; 78(920): 327-9.
<http://dx.doi.org/10.1136/pmj.78.920.327>
22. Hengster P, Schnapka J, Fille M, et al. Occurrence of suppurative lymphadenitis after a change of BCG vaccine. *Arch Dis Child.* 1992; 67(7): 952-5. <http://dx.doi.org/10.1136/adc.67.7.952>
23. Barari-Savadkouhi R, Shour A, Masrou-Roudsari J. A study of the incidence of BCG vaccine complications in infants of Babol, Mazandaran (2011-2013). *Caspian J Intern Med.* 2016; 7(1): 48-51. PubMed PMID: 26958333.
24. Sadeghi-Shabestari M, Ansarin K, Maljaei SH, et al. Clinical Management of Localized Bcg Adverse Events in Children. *Ital J Pediatr.* 2009; 35(1): 42. PMID:20030825. <http://dx.doi.org/10.1186/1824-7288-35-42>.
25. Moreira TN, Moraes-Pinto MI, Costa-Carvalho BT, et al. Clinical Management of Localized Bcg Adverse Events in Children. *Rev Inst Med Trop Sao Paulo.* 2016; 58: 84.
<http://dx.doi.org/10.1590/S1678-9946201658084>
26. Valadares RMC, Carvalho WDS, Miranda SS. Association of adverse drug reaction to anti-tuberculosis medication with quality of life in patients in a tertiary referral hospital. *Rev Soc Bras Med Trop.* 2019; 53: e20190207. <http://dx.doi.org/10.1590/0037-8682-0207-2019>
27. Lange C, Dheda K, Chesov D, et al. Management of drug-resistant tuberculosis. *Lancet.* 2019; 394(10202): 953-66. [http://dx.doi.org/10.1016/S0140-6736\(19\)31882-3](http://dx.doi.org/10.1016/S0140-6736(19)31882-3)
28. Engelis A, Kakar M, Meiksans R, et al. BCG-SSI((R)) vaccine-associated lymphadenitis: Incidence and management. *Medicina (Kaunas).* 2016; 52(3): 187-91.
<http://dx.doi.org/10.1016/j.medici.2016.05.001>
29. Nazir Z, Qazi SH. Bacillus Calmette-Guerin (BCG) lymphadenitis-changing trends and management. *J Ayub Med Coll Abbottabad.* 2005; 17(4): 16-8. PubMed PMID: 16599027

Figures

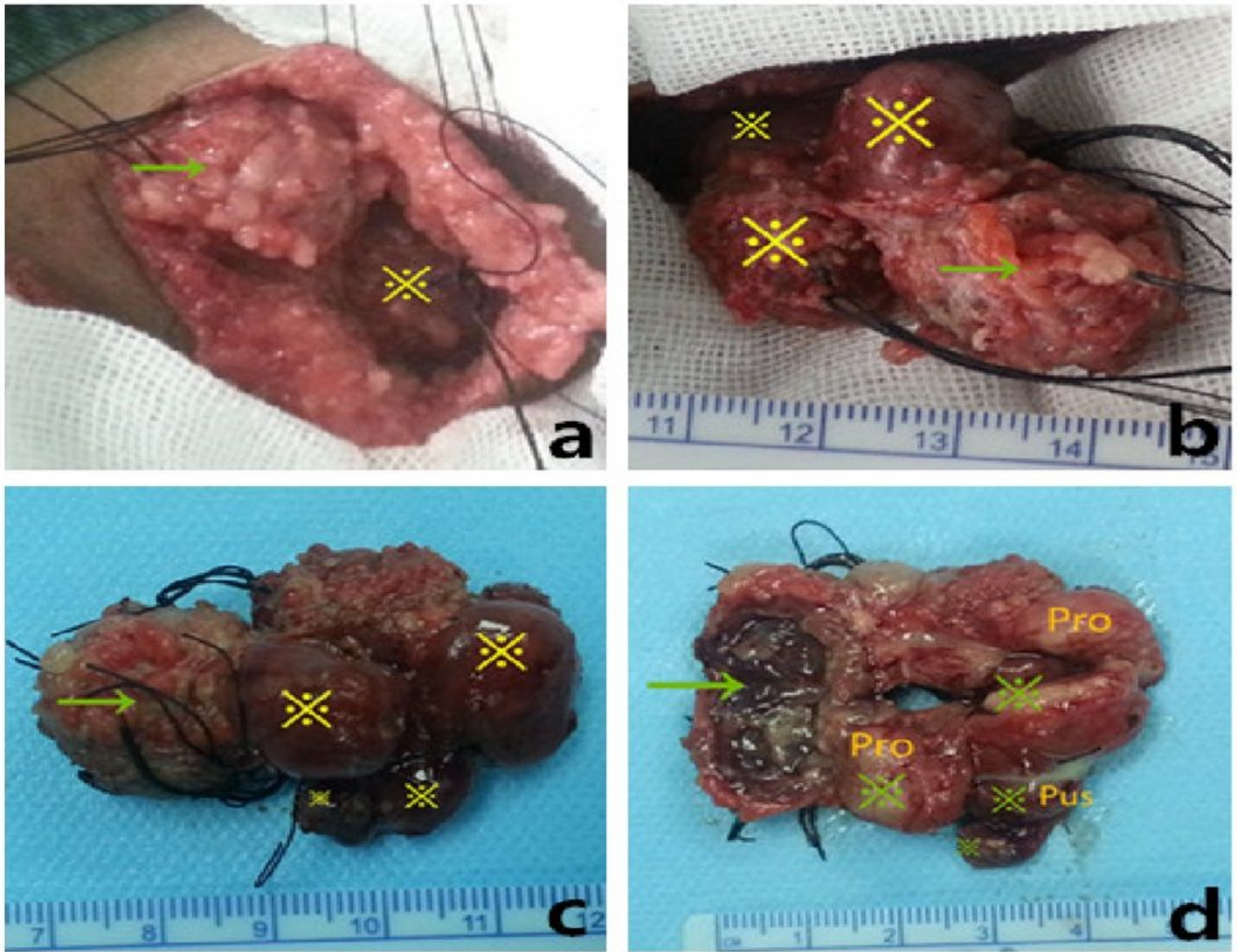


Figure 1

a. to expose the abscess (→) and involved lymph node (※). b. to dissect the involved lymph nodes (※). c. the gross appearance of the excised specimen, abscess (→), lymph nodes (※). d. vertical section showed that subcutaneous abscess cavity (→) and proliferative (Pro) and suppurative (Pus) lesions in the involved lymph nodes (※).

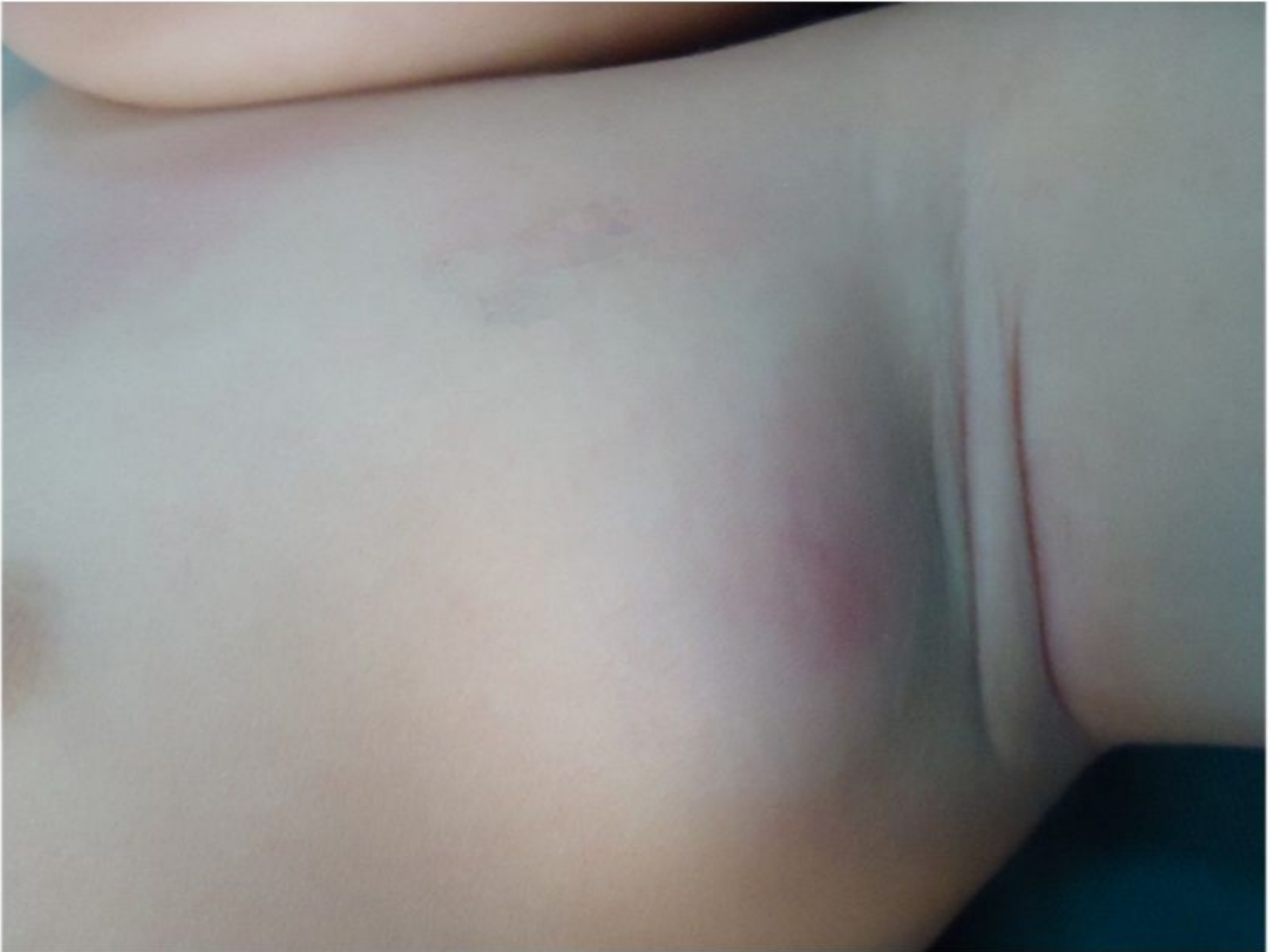

Figure 2

Swelling with regional reddish in the left chest wall and axillary.

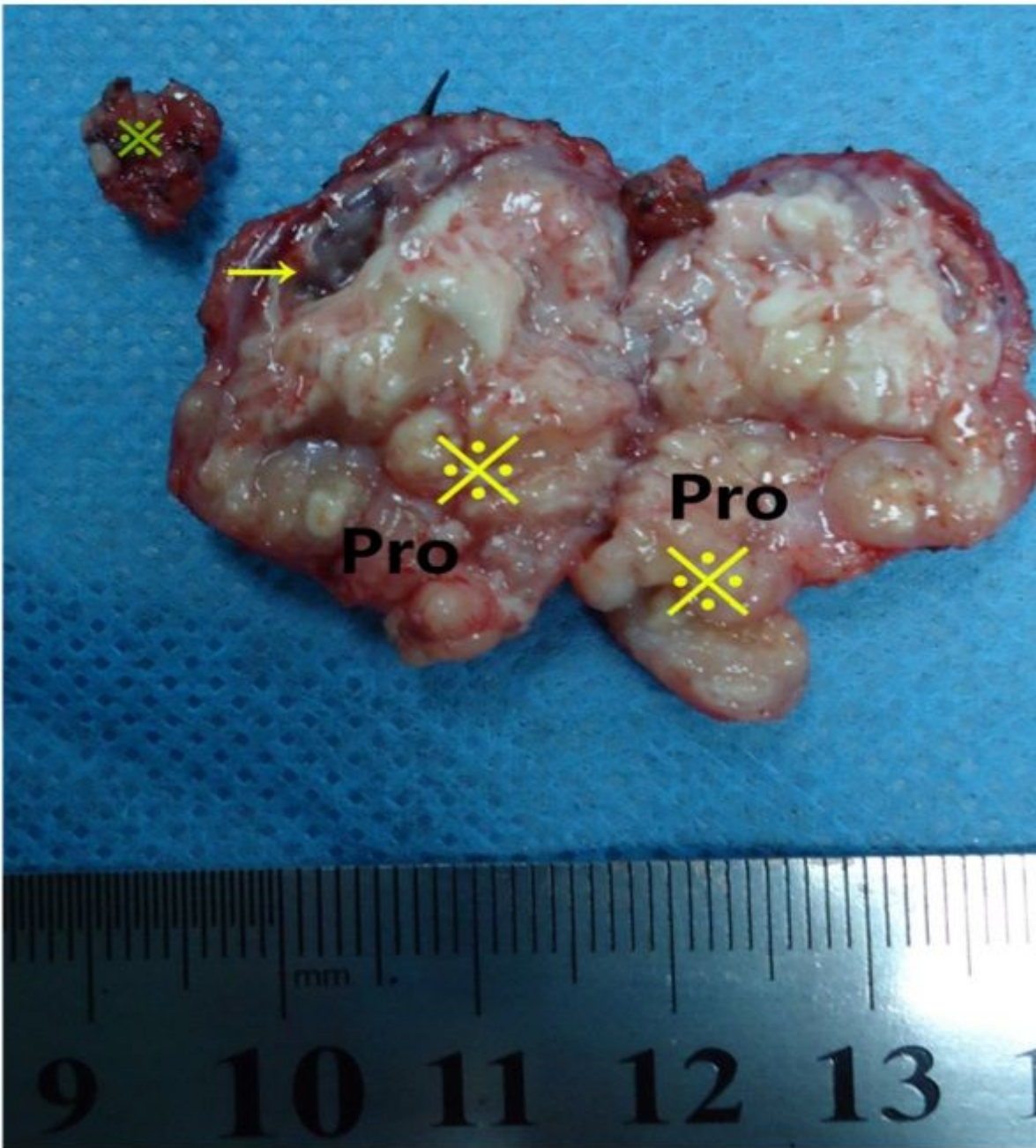


Figure 3

Surgical specimen illustrated that abscess formation (→) with involved lymph nodes (⌘) in the same case of Fig.2.