

Tracheoinnominate Fistula: Acute Bleeding and Hypovolemic Shock Due to a Trachea-Innominate Artery Fistula After Long-Term Tracheostomy, Treated With a Stent-Graft

Ali Khanafer (✉ mr-khanafer@hotmail.com)

City of Stuttgart Hospitals Katharinenhospital: Klinikum Stuttgart Katharinenhospital

<https://orcid.org/0000-0002-9482-0151>

Victoria Hellstern

Klinikum Stuttgart Katharinenhospital

Helfried Meißner

Klinikum Stuttgart Katharinenhospital

Christoph Harmening

Klinikum Stuttgart Katharinenhospital

Klaus Schneider

Klinikum Stuttgart Katharinenhospital

Hans Henkes

Klinikum Stuttgart Katharinenhospital

Case Report

Keywords: Tracheostomy, Tracheoinnominate fistula, Stent-graft, Platelet function inhibition

Posted Date: February 5th, 2021

DOI: <https://doi.org/10.21203/rs.3.rs-175048/v1>

License:   This work is licensed under a Creative Commons Attribution 4.0 International License.

[Read Full License](#)

Version of Record: A version of this preprint was published on March 19th, 2021. See the published version at <https://doi.org/10.1186/s42155-021-00216-8>.

Abstract

Background

A tracheo-innominate fistula is a rare but life-threatening complication of tracheostomy and has a mortality rate of 100% without therapy. The underlying cause is an acquired fistula between the brachiocephalic trunk and the trachea, induced by a tracheostomy cannula's mechanical impact.

Case presentation

A 25-year-old female was admitted with pulsatile bleeding from a tracheostomy. The cause of the bleeding was a tracheo-innominate artery fistula, which was difficult to recognize. Said fistula was treated with implantation of a self-expanding stent-graft. The bleeding stopped immediately after the implantation of the stent-graft. Dual antiplatelet medication with aspirin IV and ticagrelor PO, bridged with a bolus of eptifibatid IV, was started right after the stent deployment.

Conclusions

Endovascular self-expanding stent-graft implantation is a viable treatment option for tracheo-innominate artery fistulae, especially in hemorrhagic emergencies. Antiplatelet medication is required to prevent distal emboli from the implant.

Background

Tracheo-innominate fistula (TIF) is a sporadic (0.1%-1%) and potentially lethal complication after tracheostomy (Cooper and Grillo 1969, Qureshi 2018). In most cases (80%), the fistula is located between the brachiocephalic trunk ("innominate artery") and the anterior aspect of the trachea. TIF mostly develop in a period of 3 days to 6 weeks after tracheostomy. The clinical manifestation is sudden massive tracheal hemorrhage. Rapid management is essential during the acute stage due to life-threatening airway obstruction and hemorrhagic shock. TIF has a high mortality rate, reaching 100% in the absence of treatment. Open surgery is the traditional treatment for TIF. However, endovascular stenting and embolization have become alternative treatments in recent years (Taechariyakul et al. 2020). We report a case of a patient with TIF that was successfully treated with endovascular stent graft reconstruction of the innominate artery.

Case Presentation

A 25-year-old female was brought to our Emergency Room with acute pulsatile bleeding from her tracheostomy with an 8.1 mg/dl hemoglobin value upon admission. The patient suffered from long-term spastic tetraparesis due to cerebral palsy. She had a history of aspiration pneumonia with sepsis and respiratory failure 4 years ago. The inspection with the bronchoscope showed massive bleeding from the anterior tracheal wall. Blood was aspirated to clear the airways, and the cuff of the tracheostomy tube

was overinflated to control the bleeding in the short term. A diagnostic digital subtraction angiography (DSA) was carried out under emergency circumstances. The initial angiogram revealed no visible extravasation. Therefore, the tracheal tube was temporarily removed, and the cuff was temporarily released three times. The brachiocephalic trunk's selective injection demonstrated a difficult to recognize small dot of contrast medium accumulation, which was considered the site of extravasation from the posterior wall of the brachiocephalic trunk to the anterior aspect of the adjacent trachea. We decided to implant a self-expanding stent-graft into the brachiocephalic trunk to seal the vessel wall's erosion without covering the subclavian artery's origin. The available implant was a Fluency Plus Stent Graft 8 mm × 40 mm (BD Bard), mounted in an 80 cm long catheter with a 9F crossing profile. A stiff 0.035" diameter and 300 cm length Radiofocus guidewire (Terumo) with an angled tip was navigated into the right external carotid artery using a 4F Tempo4 vertebral catheter (Codman) through a 9F sheath (Terumo), followed by the removal of the 4F catheter. The Fluency Stent Graft was inserted over the said guidewire into the brachiocephalic trunk without using a guide catheter. Deployment of the stent-graft immediately stopped the tracheal bleeding (Fig. 1). To prevent a thromboembolic occlusion of the stent, a loading dose of 1× 500 mg acetylsalicylic acid (ASA; Aspirin, Bayer Vital) IV and 1× 9 mg eptifibatide (Integrilin, GlaxoSmithKline) IV were given before implantation; 1× 180 mg ticagrelor (Brilique, AstraZeneca) PO was administered immediately after access via a feeding tube. The final DSA run demonstrated regular blood flow without evidence of perfusion disturbance. Daily medication consisted of 2× 500 mg ASA IV and 2× 90 mg ticagrelor PO. Daily testing with Multiplate (Roche Diagnostics) and VerifyNow (Accriva) confirmed dual platelet function inhibition. Follow-up bronchoscopy performed after 17 days showed no hemorrhage, and follow-up cranial CT obtained after 30 days revealed no ischemic cerebral lesions. After discharge, the patient suffered from complicated pneumonia. During the second clinical admission, she died 31 days after the endovascular treatment in the intensive care unit from pulmonary failure.

Discussion

Long-term tracheostomy may cause a fistula's development between the trachea and the brachiocephalic trunk due to tracheitis, focal necrosis, cartilage loss, and then fistulization (Komatsu et al. 2013). Common risk factors are low tracheostomy position, excessive cuff inflation, and steroids (Qureshi 2018). The rapid management and the early control of the hemorrhage play a crucial role in patient survival (Seung et al. 2012, Komatsu et al. 2013). The primary goal is to secure the airway by hyperinflating the tracheal cuff and the advancement of the endotracheal tube. Besides, the digital compression of the bleeding area is required to prevent hemorrhagic shock.

Clinical signs of incipient TIF are small amounts of blood from the tracheostomy, hemoptysis, or pulsatile movements of the tracheal cannula (Schaefer and Irwin 1995). It can be challenging to confirm the diagnosis of TIF with computed tomography angiography and may require bronchoscopy and catheter angiography to determine the location of the bleeding (Seung et al. 2012). In a typical emergency, it is not feasible to establish a sophisticated work-up. A rapid diagnosis will allow the decision-making for an emergent therapy concept (Reger et al. 2018).

There are various techniques available for the treatment of acute TIF. The immediate surgical treatment is the most common approach to controlling bleeding and reconstructing the vessel and the tracheal defect (Komatsu et al. 2013). A median sternotomy is required to gain access. Once the TIF is identified, the vascular clamps are placed to stop the bleeding. The defect can be reconstructed by ligation or resection with replacement by a vascular prosthesis. Reconstruction with a bypass is also possible in emergencies. The mortality rate after emergency surgery has been reported to be beyond 50%. Neurological deficits of 10% and sternal wound complications of 39% were reported (Seung et al. 2012, Reger et al. 2012, Nakai et al. 2013).

Endovascular therapy is increasingly considered an attractive and practical approach to treat arterial bleeding due to fistulas and vascular erosions. There are few publications in the English literature discussing the endovascular treatment of TIF, either as a stand-alone treatment or as a bridging concept for patients in a poor clinical condition for an operation in the subacute phase after at least partial recovery (Taechariyakul et al. 2020).

Taechariyakul et al. (2020) identified 261 published cases of TIF in a meta-analysis and reported a lower procedure-related complication rate (30% vs. 50%, $p = 0.045$) and 30-day mortality (9% vs. 23%, $p = 0.008$) for the endovascular treatment compared to surgery. Endovascular stent-graft implantation is a rapid and safe procedure. However, possible complications such as graft infection, graft occlusion, and postoperative rebleeding due to tracheal erosion must be considered (Nakai et al. 2013).

In our case, we opted for an endovascular therapy due to the high-risk of the already unstable patient and because open surgery was considered hazardous, especially with a vaguely identified bleeding source. In the English literature, reports of post-procedural complications such as occlusion of the right carotid artery or right subclavian artery leading to steal syndrome can be found. Therefore, the decision for the correct stent dimensions and position is crucial. Thromboembolic complications such as stent-graft occlusion or cerebral ischemia may result from any inconsistency of the antiplatelet medication.

Conclusions

Endovascular treatment of TIF with a stent graft is both effective and safe. The procedure is well suited in acute situations to avoid fatal exsanguination. The peri- and post-procedural antiplatelet medication is essential to prevent thromboembolic complications.

Abbreviations

CT: Computed tomography; DSA: digital subtracted angiography; F: French catheter scale;

Declarations

Acknowledgments

Not applicable.

Authors' contributions

VH and HH performed the procedure. AK wrote the manuscript under the supervision of HH. VH, HM, and CH reviewed and corrected the case report. All authors read and approved the final manuscript.

Funding

Not applicable.

Availability of data and materials

The primary data underlying this manuscript are available from the corresponding author upon request.

Ethics approval and consent to participate

Not applicable.

Consent for publication

Written consent was obtained from the legal representative of the patient.

Competing interests

The authors declare that they have no competing interests.

Author details

¹Neuroradiologische Klinik, Klinikum Stuttgart, Kriegsbergstraße 60, D-70174 Stuttgart, Germany

²Klinik für Gefäßchirurgie, Endovaskuläre Chirurgie und Transplantationschirurgie, Klinikum Stuttgart, Kriegsbergstraße 60, D-70174 Stuttgart, Germany

³Klinik für Anästhesiologie, operative Intensivmedizin, Notfallmedizin und Schmerztherapie, Klinikum Stuttgart, Kriegsbergstraße 60, D-70174 Stuttgart, Germany

⁴Klinik für Hals-, Nasen-, Ohrenkrankheiten, Plastische Operationen, Klinikum Stuttgart, Kriegsbergstraße 60, D-70174 Stuttgart, Germany

⁵Medical Faculty, University Duisburg-Essen, Essen, Germany

References

Cooper JD, Grillo HC (1969) The evolution of tracheal injury due to ventilatory assistance through cuffed tubes: a pathologic study. *Ann Surg* 169:334-48

Komatsu T, Sowa T, Fujinaga T et al (2013) Tracheo-innominate artery fistula: two case reports and a clinical review. *Ann Thorac Cardiovasc Surg* 19:60-2

Nakai M, Sato H, Sato M et al (2013) Tracheo-innominate artery fistula successfully treated by endovascular stent-graft repair. *Jpn J Radiol* 31:65-70

Qureshi AZ. Fatal innominate artery hemorrhage in a patient with tetraplegia: Case report and literature review (2018) *J Spinal Cord Med* 41:731-734

Reger B, Neu R, Hofmann HS et al (2018) High mortality in patients with tracheoarterial fistulas: clinical experience and treatment recommendations. *Interact Cardiovasc Thorac Surg* 1;26:12-17

Schaefer OP, Irwin RS (1995) Tracheoarterial fistula: an unusual complication of tracheostomy. *J Intensive Care Med* 10:64-75

Seung WB, Lee HY, Park YS (2012) Successful treatment of tracheoinnominate artery fistula following tracheostomy in a patient with cerebrovascular disease. *J Korean Neurosurg Soc* 52:547-50

Taechariyakul T, Keller FS, Jahangiri Y (2020) Endovascular treatment of tracheoinnominate artery fistula: case report and literature review with pooled cohort analysis. *Semin Thorac Cardiovasc Surg* 32:77-84

Figures

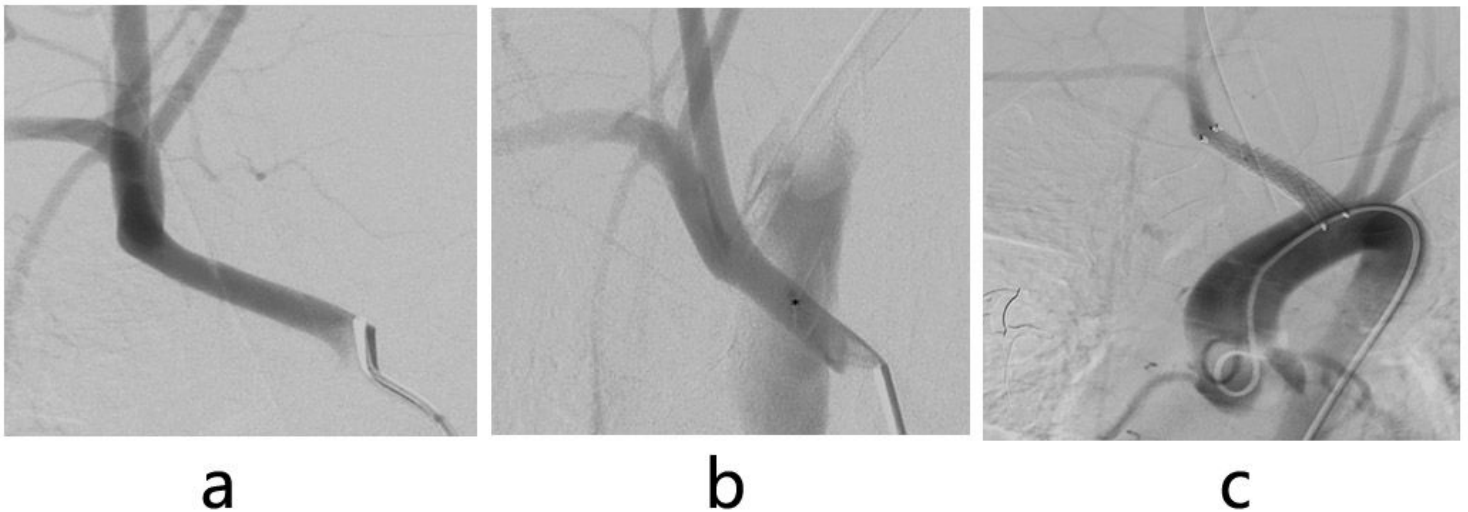


Figure 1

Diagnostic imaging in a 25-year-old female patient with a tracheoinnominate fistula. DSA of the brachiocephalic trunk with overinflated tracheal tube (a) showed no bleeding source. Temporary removal of the tracheal tube and releasing the cuff revealed the contrast medium extravasation from the brachiocephalic trunk's posterior wall to the anterior wall of the adjacent trachea (asterisk: bleeding spot

(b)). The following DSA run of the aortic arch showed the proper position of the stent-graft, the interruption of the previous extravasation, and the patency of the origin of the subclavian artery (c)