High Hip Center Technique in Total Hip Arthroplasty for Crowe Type II-III Developmental Dysplasia: Results of Midterm Follow-up

Junmin Shen
Chinese PLA General Hospital
Yonggang Zhou (ygzhou301@163.com)
Chinese PLA General Hospital https://orcid.org/0000-0002-7304-4691
Jingyang Sun
Chinese PLA General Hospital
Haiyang Ma
Chinese PLA General Hospital
Yinqiao Du
Chinese PLA General Hospital
Tiejian Li
Chinese PLA General Hospital

Research article

Keywords: Total Hip Arthroplasty, High Hip Center, Developmental Dysplasia of the Hip, Crowe Type II-III

Posted Date: March 12th, 2020

DOI: https://doi.org/10.21203/rs.3.rs-16950/v1

Version of Record: A version of this preprint was published at Orthopaedic Surgery on August 1st, 2020. See the published version at https://doi.org/10.1111/os.12756.

Abstract

Background: High hip center technique is still controversial about the survivorship of prothesis and postoperative limp. We aimed to show the utility of high hip center technique used in patients with Crowe II-III developmental dysplasia of the hip at the midterm follow-up and evaluated the clinical and radiographic results between different heights of hip center.

Methods: We retrospectively evaluated 69 patients (85 hips) with Crowe II-III dysplasia who underwent a high hip center cementless total hip arthroplasty at a mean follow up of 8.9 years (range, 6.0-14.1). The patients were divided into two groups according to the height of hip center, respectively group A (≥22mm and <28mm) and group B (≥28mm). Radiographic, functional and survivorship outcomes were evaluated.

Results: There were no statistically significant differences between two groups in horizontal distance, offset, abductor lever arm, leg length discrepancy and cup inclination. At the final follow up, the WOMAC and Harris hip scores were excellent in both groups. Of the 85 hips, 7 (8.2%) showed a positive Trendelenburg sign. Besides, 6 patients (8.7%) had a symptom of claudication. No significant differences were shown regarding the Harris hip score, WOMAC score, Trendelenburg sign and claudication between two groups. The Kaplan-Meier 8-year implants survivorship rates for all-causes revisions in group A and group B were similar (96.7% [95% confidence interval, 90.5%-100%] and 96.2% [95% confidence interval, 89.0%-100%], respectively).

Conclusions: The high hip center technique is a valuable alternative to achieve excellent midterm results for Crowe II-III developmental dysplasia of the hip, preferably combined with COC interface or high crosslinked polyethylene liner.

Introduction

Total hip arthroplasty (THA) in developmental dysplasia of the hip (DDH) presents technical challenges due to complex acetabular and femoral deformities which are partially dependent on the Crowe classification[1, 2]. The issue of acetabular reconstruction should be a priority especially for Crowe type II-III DDH which always encompasses segmental or complete absence of a superolateral rim. Previously, most studies concurred that the true acetabulum was the optimal location for the cup[3]. To achieve anatomical placement of the cup, augmentation by structural bone graft to supplement bone insufficiency was commonly required[4]. Nevertheless, high failure rates of bone graft have been revealed in many literatures[5, 6].

As an alternative option, high hip center technique (HHC) recently came into the focus of discussion. HHC had several advantages in sufficient bone-implant contact and simplifying the procedure of operation. However, a few studies have shown superolateral placement could result in accelerated polyethylene (PE) wear, decreased abductor moment arm and component loosening[7]. In contrast, most recent clinical studies have demonstrated promising results of this technique. Kaneuji et al.[8] gave a report of no cup

loosening in thirty hips (29 patients) using HHC technique for a mean of 15.2 years after surgery. Nawabi et al.[9] showed no difference in survivorship, wear rates and hip scores between the HHC group and the control group. Even so, it's still controversial about high placement of the cup. In addition, there were various of defined values of the height of HHC in previous studies, such as 22 mm defined for Japanese by Fukui et al.[10] and a mean height of 28 mm in HHC group reported by Nawabi et al.[9] and Galea et al.[11]. As far as I know, there is no research on the comparison between different heights of HHC.

In this study, we wished to show the utility of HHC technique used in patients with Crowe II-III DDH at the midterm follow-up. Specifically, we aimed to evaluate the clinical and radiographic outcomes between different heights of HHC.

Methods

Patients

After obtaining institutional review board approval, we performed a retrospective cohort analysis. From our departmental database, we identified 76 patients diagnosed with Crowe II-III dysplasia with the acetabular cup placed at the high hip center, of which the threshold was defined as 22 mm above the inter-teardrop line[10]. All operations were performed between December 2003 and November 2013 by one senior orthopedic surgeon. Cases with non-standard x-rays and those with deformed pelvises and histories of neuromuscular disease or trauma were excluded. One patient died of unrelated cause to the procedure at 8 years after surgery and 4 patients were lost to follow-up. Two patients refused to participate for questionnaires and clinical examination. Therefore, 69 patients (85 hips) were ultimately available for this study.

In this study, 54 patients were female (78.3%) and 15 patients were male (21.7%). Forty-two right hips (49.4%) and 43 left hips (50.6%) were surgically treated. The mean age of the patients at the time of THA was 46.4 years (range, 18–69 years). The mean body mass index was 24.1 kg/m² (range, 15.2–35.5 kg/m²). The mean follow-up time was 8.9 years (range, 6.0–14.1 years). According to the Crowe classification, 49 hips were categorized as type II and 36 hips were categorized as type III. Eleven patients had a history of previous surgeries: open reduction in 1 case, femoral derotational osteotomy in 2 cases, pelvic osteotomy in 3 cases and hip shelf operation in 5 cases.

The patients were divided into two groups according to the height of hip center. In group A which consisted of 39 hips, the hip center was located at a vertical distance of $\geq$ 22 mm and $<$ 28 mm from the inter-teardrop line, when the hip center of group B which consisted of 46 hips was $\geq$ 28 mm (Table.1).

Surgical Technique

All operations were performed using a posterolateral approach. The location of the cup was determined by intraoperatively measuring where the cup could be accommodated by the remaining acetabular bone.

Medialization of the component was performed to achieve sufficient bone coverage. When good initial stability was guaranteed, the superolateral rim partially not covered by host bone was acceptable. No superior acetabular grafts or spongioplasty were used in all operations. In some case, a larger size stem was used to elevate the position of the stem in the femoral canal with different head/neck lengths, aiming to restore the proper tension of the gluteus medius and correct limb-length discrepancy. The detailed information of acetabular and femoral components and types of bearing were shown in Table 2.

Table 1
Demographics of the Patients.

Demographic	Group A	Group B	P value
Number of patients (hips)	39 (31)	46 (38)	
Mean (range) age (y) at surgery	46.5 (18–66)	46.4 (20–69)	0.959*
Gender (female/male)	25/6	29/9	0.665†
Mean (range) height (cm)	161.1 (142–180)	161.8 (141–186)	0.723*
Mean (range) BMI (kg/m²)	23.7 (18.7–29.1)	24.5 (15.2–35.5)	0.333*
Crowe II /III (hips)	32/7	17/29	0.000†
Mean (range) follow up (y)	9.5 (6.6–13.3)	8.4 (6.0-14.1)	0.007*
Mean (range) blood loss (ml)	403.8 (100–1000)	440.8 (150–2000)	0.544*
Mean (range) duration of surgery (h)	1.9 (1.2–2.8)	2.1 (1.2–4.5)	0.173*

* independent-samples t test; †Chi-squared test; BMI, body mass index.

Table 2
Specific designs of acetabular and femoral components and types of bearing used in all patients.

	Group A	**Group B**
Median cup size (mm) (IQR)	50 (50, 52)	50 (48, 52)
Acetabular component		
Betacup (Link, Hamburg, Germany)	20 (51.3%)	24 (52.2%)
Duraloc (DePuy, Warsaw, IN, USA)	11 (28.2%)	9 (19.5%)
Pinnacle (DePuy, Warsaw, IN, USA)	7 (17.9%)	13 (28.3%)
Trident (Stryker, Mahwah, NJ, USA)	1 (2.6%)	-
Femoral stem		
Corail (DePuy, Warsaw, IN, USA)	32 (82.0%)	31 (67.4%)
S-ROM (DePuy, Warsaw, IN, USA)	5 (12.8%)	12 (26.1%)
Ribbed (Link, Hamburg, Germany)	1 (2.6%)	2 (4.3%)
LCU (Link, Hamburg, Germany)	-	1 (2.2%)
Accolade (Stryker, Mahwah, NJ, USA)	1 (2.6%)	-
Bearing type		
COC	36 (92.3%)	42 (91.3%)
COP	2 (5.1%)	2 (4.35%)
MOP	1 (2.6%)	2 (4.35%)

IQR, interquartile range; COC, ceramic on ceramic; COP, ceramic on polyethylene; MOP, metal on polyethylene.

Radiographic Evaluation

Radiological assessment based on anteroposterior (AP) radiograph of the pelvis was undertaken postoperatively for all patients at three and six months, at one year, then biennially thereafter and at last follow up. Osteolysis was defined as circular or oval areas of distinct bone loss. The location of radiolucent lines with a width of over 1 mm at the component-bone interface was described according to DeLee and Charnley[12]. The cup was considered loosened in presence of a change of more than 3 mm of migration or at least 4° in the angle of abduction. The position of the cup was defined as the vertical and horizontal distances of the center of rotation in relation to the acetabular teardrop as described by Russotti and Harris[3]. Medialization was measured by contrast with the contralateral hip in unilateral HHC. In bilateral HHC, the Ranawat triangle was drawn to define the correct anatomic hip center to

calculate the medialization[13]. The femoral offset (FO) was defined as the length from the center of rotation to the perpendicular line drawn under the central axis of the femur. The cup inclination was defined as the abduction angle, formed by the inter-teardrop line and the connecting line to the edges of the rim of the cup. The leg length was measured as the perpendicular distance from the apex of the lesser trochanter to the inter-teardrop line. The abductor lever arm (ALA) was measured from the femoral head to the line joining the lateral part of the greater trochanter to the anterosuperior iliac crest (Fig. 1).

Clinical Assessment

We clinically evaluated each patient with the Harris Hip Score, WOMAC score, Trendelenburg sign and gait. The scores for WOMAC OA index were normalized with 96 indicating the best state of health. Trendelenburg sign was regarded as an assessment of the abduction strength. The gait was assessed according to the symptom of claudication.

Statistical Assessment

The consecutive variables were expressed as mean and range. The skewed distributional data was expressed as median and interquartile. Statistical analysis was realized using $\chi 2$ test for qualitative data. Differences in mean parameter values between groups were assessed by Student's t test. Homogeneity of parameter variance between the two groups was evaluated by Levene's test. The end point for survival was defined as revision for any reason. Kaplan-Meier analysis was performed to determine the probability of survivorship in both groups. The equality of the survival distributions between two groups was compared by Log-rank test. Significance was set at $p < 0.05$. All analyses were performed using SPSS Version 24.0 software.

Result

Radiographic Results

The results of the radiographical evaluations are shown in Table 3. These outcomes indicated that horizontal distance, FO, ALA, leg length discrepancy and cup inclination in group B were maintained as well as they were in group A. Scatter diagram provides medialization or lateralization about all hips (Fig. 2). At the final follow-up, the slight osteolysis was observed in 2 hips in DeLee and Charnley zone 1. These 2 hips were all from group A. All the other prostheses were observed in a good position (Fig. 3).

Table 3
Postoperative radiographic evaluation.

Evaluation parameter	Group A*	Group B*	P value†
Vertical distance (mm)	25.1 (22.1–27.8)	33.1 (28.0-43.7)	0.000
Horizontal distance (mm)	30.0 (22.9–40.0)	31.4 (22.3–53.6)	0.212
Femoral offset (mm)	32.9 (18.3–46.6)	32.2 (13.4–45.6)	0.636
Abductor lever arm (mm)	54.0 (37.0-69.5)	52.1 (28.0-70.4)	0.233
Leg length discrepancy (mm)	5.0 (0.5–12.3)	5.5 (0.2–25.8)	0.628
Cup inclination (degree)	41.1 (29.0-50.3)	41.2 (26.6–59.9)	0.955

* Values given as mean (range); † independent-samples t test.

Clinical Results

The Harris hip score and WOMAC score at the time of follow-up were significantly improved in either group A (P = 0.000) or group B (P = 0.000). Table 4 showed no statistically significant differences between two groups regarding the Harris hip score, WOMAC score, Trendelenburg sign and claudication. Besides, limps in unilateral and bilateral HHC were similar (P = 0.912), respectively 7.5% and 6.3%. Of the 85 hips, 2 hips (2.4%) required revision during the follow-up period. One hip of group A was revised by reason of dislocation at 8.3 years after surgery. The other one hip of group B, which utilized a metal on conventional polyethylene bearing at the primary THA, was diagnosed with osteolysis and underwent a revision at 8.1 years after surgery. With revision for any reason as the end point, the Kaplan-Meier survival rates at last follow-up were similar (P = 0.805) in both groups. The 8-year survival rates were respectively 96.7% (95%CI, 90.5%-100%) in group A and 96.2% (95%CI, 89.0%-100%) in group B (Fig. 4).

Table 4
Clinical evaluation.

Parameters	Group A	Group B	P value
Preoperative HHS*	53.5 (35.5–65.0)	51.1 (33.0–68.0)	0.199†
HHS at last follow-up*	94.0 (78.9–99.7)	92.8 (76.5–99.1)	0.187†
Preoperative WOMAC*	53.3 (43–65)	51.8 (39–68)	0.340†
WOMAC at last follow-up*	88.7 (59–96)	88.0 (56–96)	0.640†
Positive Trendelenburg sign	4 (10.3%)	3 (6.5%)	0.819‡
Patients with claudication	4 (12.9%)	2 (5.3%)	0.526‡

* Values given as mean (range); † independent-samples t test; ‡ Chi-squared test.

Discussion

The reconstruction of the acetabulum in patients with Crowe II-III DDH is a demanding procedure for orthopedic surgeons. Most surgeons found it technically difficult to achieve acceptable cup coverage at the anatomical acetabulum on account of superolateral bone deficiency[14]. Therefore, femoral head structural autograft was usually utilized at the superolateral rim to provide additional support[15]. However, other authors have proposed the instability of cemented acetabular component with bulk bone grafts[16]. Though some excellent results were reported in cementless THA with autograft[17, 18], this procedure still could be correlated with longer duration of surgery and increased blood loss.

Because the posterosuperior bone above the native acetabulum is almost intact, the acetabular cup can be placed at high hip center to optimize host bone-implant contact[19]. In this study, we sought to show the utility of HHC technique used in patients with Crowe II-III DDH and evaluated the clinical and radiographic results between different heights of hip center.

Early results have shown superior placement and especially lateralization of the cemented acetabular cup resulted in high rate of loosening[7]. In addition, in the cementless THA, aseptic loosening also occurred in long-term follow-up. Watts et al.[20] reviewed 88 primary cementless THA at a mean follow-up of 10 years and found a higher incidence of aseptic loosening and cup revision with superolateral placement of the cup, which was described as more than 10 mm superior and 10 mm lateral to the approximate femoral head center. To avoid this situation, the acetabular component was placed medially adjacent to medial wall during operation in our study. Medialization not only prevented the increase of gravity level arm and joint reaction force, but biomechanically relieved the burden of abductor muscle which was mostly malfunction due to chronically shortened condition and subsequent atrophy. In our study, the mean horizontal distance of the center of rotation which was 30.0 mm in group A and 31.4 mm

in group B was comparable to the results described by Flecher et al.[21] (horizontal distance was 30.4 mm when vertical distance was 23.4 mm), Fukui et al.[10] (horizontal distance was 28.9 mm when vertical distance was 28 mm) and Galea et al.[11] (horizontal distance was 31.6 mm when vertical distance was 30.9 mm). However, referring to the anatomical center, only 73 (85.9%) acetabular cups attained the objective of medialization or lateralization less than 10 mm. Lateral cup placement more than 10 mm in group B significantly exceeded that of group A. Obviously, it's more difficult for medialization when the rotation of the hip was elevated increasingly higher. A possible explanation may be the funnel-shaped geometry of the bony pelvis. Nevertheless, it should be stated that no complications such as loosening and liner wear occurred in our hips with excessive lateralization. Different from previous studies utilizing polyethylene liner in most of cases, COC interface was applied in 91.8% of our cases. Therefore, we considered that the incidence of wear could be reduced by choosing COC interface of which the favorable wear features may efficaciously counteract the excessive joint reaction forces related to lateralization.

Some authors indicated that there is a negative correlation of abductor strength with a high rotation center of the hip. Through a radiological and biomechanical study, Abolghasemian et al.[22] suggested that elevated hip center resulted in a decrease in the muscle length and a corresponding decrease in the preload, leading to the weakness of abductor strength. But in a recent study, Traina et al.[23] demonstrated that restoration of optimal femoral offset and abductor lever arm produced satisfactory results even for a center of hip rotation of > 30 mm. This paper came up with a similar result as well. Though the height of hip center in group B (33.1 ± 4.8) significantly exceeded that in group A (25.1 ± 1.6), the clinical and radiographic outcomes were all excellent after restoration of leg length, FO and ALA, and no significant difference was shown in two groups. In spite of the slack of gluteus medius due to elevated hip center, a larger size stem and appropriate head/neck lengths could be applied as a compensation and could also contribute to correcting leg length discrepancy, avoiding lower limbs of claudication. Further, preserving the continuity of abductors meant a favorable event regarding the restoration of normal gait. In our series, only 8.2% of all hips presented with a positive Trendelenburg sign and 8.7% of patients presented with a limp. The result of Trendelenburg sign was superior to the cases described by Chen et al.[19] (14.2%) and Fukui et al.[10] (13%). Furthermore, a recent gait analysis study by Karaismailoglu et al.[24] claimed that the bilateral HHC technique could provide similar gait characteristics as anatomical reconstruction. Although there was no detailed research on this issue, the rates of limp in unilateral and bilateral HHC were similar (P = 0.912) and low in our cohort, respectively 7.5% and 6.3%.

In our series, the 8-year survival rates of implant were high, respectively 96.7% (95%CI, 90.5%-100%) in group A and 96.2% (95%CI, 89.0%-100%) in group B. Comparison of our survivorships with other studies showed that the HHC technique was a reliable alternative method for Crowe II-III DDH[8, 9, 25]. Meanwhile, higher hip center won't significantly reduce the survivorship of implants even if it was above 28 mm.

This study shows some limitations. First, our conclusion is based on a relatively small sample size. In addition, the validation of HHC technique needs a longer follow-up, and the consistency associated with a study setting limited to a single surgeon's practice in single center. Second, this is a retrospective study.

However, our patients were identified from a consecutive series with DDH, which may reduce the possibility of selection bias. Third, there is a lack of comparison between HHC technique and other methods. Fourth, the issue of gait in this study is insufficient compared with other gait analysis study. However, we believe that our satisfying results can provide effective supports to HHC technique and can be considered as an important reference to future research.

Conclusion

When bone stock of true acetabulum is insufficient to support a cup, we believe that HHC technique could be valuable alternative for Crowe II-III DDH, preferably combined with COC interface or high crosslinked polyethylene liner. HHC technique can not only provide an excellent midterm result, but simplify the surgical procedure.

Declarations

Abbreviations

HHC: High hip center; DDH: Developmental dysplasia of the hip; THA: Total hip arthroplasty; PE: polyethylene; BMI: body mass index; AP: anteroposterior; FO: femoral offset; ALA: abductor level arm; HHS: Harris hip score; WOMAC: Western Ontario and McMaster Universities.

Ethics approval and consent to participate

The Ethics Committee of our hospital, General Hospital of Chinese People's Liberation Army, approved the study protocol. A certificate of approval has been provided. The requirement of informed consent was exempted due to the retrospective nature of the study.

Consent for publication

Not applicable.

Availability of date and materials

The data will be made available from the authors upon reasonable request.

Competing interests

The authors declare that they have no competing interests.

Funding

No benefits in any form have been received or will be received from a commercial party related directly or indirectly to the subject of this article.

Authors' contributions

JMS: Designing the study, Analyzing the data, Writing the manuscript; YGZ: Designing the study, Editing the manuscript; JYS, HYM and YQD: Collecting the data, Analyzing the data, Reviewing the manuscript; TJL: Reviewing the literature. All authors have read and approved the final version of this manuscript.

Acknowledgments

Not applicable.

Author details

Department of orthopaedics, Chinese People's Liberation Army General Hospital, 28 Fuxing Road, Haidian District, Beijing, China.

References

1. Crowe JF, Main VJ, Ranawat CS: **Total hip replacement in congenital dislocation and dysplasia of the hip**. *J Bone Joint Surg Am* 1979, **61**(1):15-23.
2. Greber EM, Pelt CE, Gililland JM, Anderson MB, Erickson JA, Peters CL: **Challenges in Total Hip Arthroplasty in the Setting of Developmental Dysplasia of the Hip**. *J Arthroplasty* 2017, **32**(9S):S38-S44.
3. Russotti GM, Harris WH: **Proximal placement of the acetabular component in total hip arthroplasty. A long-term follow-up study**. *J Bone Joint Surg Am* 1991, **73**(4):587-592.
4. Hintermann B, Morscher EW: **Total hip replacement with solid autologous femoral head graft for hip dysplasia**. *Arch Orthop Trauma Surg* 1995, **114**(3):137-144.
5. Shinar AA, Harris WH: **Bulk structural autogenous grafts and allografts for reconstruction of the acetabulum in total hip arthroplasty. Sixteen-year-average follow-up**. *The Journal of bone and joint surgery American volume* 1997, **79**(2):159-168.
6. Kwong LM, Jasty M, Harris WH: **High failure rate of bulk femoral head allografts in total hip acetabular reconstructions at 10 years**. *The Journal of arthroplasty* 1993, **8**(4):341-346.
7. Doehring TC, Rubash HE, Shelley FJ, Schwendeman LJ, Donaldson TK, Navalgund YA: **Effect of superior and superolateral relocations of the hip center on hip joint forces. An experimental and analytical analysis**. *J Arthroplasty* 1996, **11**(6):693-703.
8. Kaneuji A, Sugimori T, Ichiseki T, Yamada K, Fukui K, Matsumoto T: **Minimum ten-year results of a porous acetabular component for Crowe I to III hip dysplasia using an elevated hip center**. *J Arthroplasty* 2009, **24**(2):187-194.
9. Nawabi DH, Meftah M, Nam D, Ranawat AS, Ranawat CS: **Durable fixation achieved with medialized, high hip center cementless THAs for Crowe II and III dysplasia**. *Clin Orthop Relat Res* 2014, **472**(2):630-636.

10. Fukui K, Kaneuji A, Sugimori T, Ichiseki T, Matsumoto T: **How far above the true anatomic position can the acetabular cup be placed in total hip arthroplasty?** *Hip Int* 2013, **23**(2):129-134.
11. Galea VP, Laaksonen I, Donahue GS, Fukui K, Kaneuji A, Malchau H, Bragdon C: **Developmental Dysplasia Treated With Cementless Total Hip Arthroplasty Utilizing High Hip Center Reconstruction: A Minimum 13-Year Follow-up Study**. *J Arthroplasty* 2018, **33**(9):2899-2905.
12. DeLee JG, Charnley J: **Radiological demarcation of cemented sockets in total hip replacement**. *Clin Orthop Relat Res* 1976(121):20-32.
13. Ranawat CS, Dorr LD, Inglis AE: **Total hip arthroplasty in protrusio acetabuli of rheumatoid arthritis**. *J Bone Joint Surg Am* 1980, **62**(7):1059.
14. Olory B, Havet E, Gabrion A, Vernois J, Mertl P: **Comparative in vitro assessment of the primary stability of cementless press-fit acetabular cups**. *Acta Orthop Belg* 2004, **70**(1):31-37.
15. de Jong PT, Haverkamp D, van der Vis HM, Marti RK: **Total hip replacement with a superolateral bone graft for osteoarthritis secondary to dysplasia: a long-term follow-up**. *J Bone Joint Surg Br* 2006, **88**(2):173-178.
16. Delimar D, Aljinovic A, Bicanic G: **Failure of bulk bone grafts after total hip arthroplasty for hip dysplasia**. *Arch Orthop Trauma Surg* 2014, **134**(8):1167-1173.
17. Saito S, Ishii T, Mori S, Hosaka K, Nemoto N, Tokuhashi Y: **Long-term results of bulk femoral head autograft in cementless THA for developmental hip dysplasia**. *Orthopedics* 2011, **34**(2):88.
18. Abdel MP, Stryker LS, Trousdale RT, Berry DJ, Cabanela ME: **Uncemented acetabular components with femoral head autograft for acetabular reconstruction in developmental dysplasia of the hip: a concise follow-up report at a mean of twenty years**. *The Journal of bone and joint surgery American volume* 2014, **96**(22):1878-1882.
19. Chen M, Luo ZL, Wu KR, Zhang XQ, Ling XD, Shang XF: **Cementless Total Hip Arthroplasty With a High Hip Center for Hartofilakidis Type B Developmental Dysplasia of the Hip: Results of Midterm Follow-Up**. *J Arthroplasty* 2016, **31**(5):1027-1034.
20. Watts CD, Martin JR, Fehring KA, Griffin WL: **Inferomedial Hip Center Decreases Failure Rates in Cementless Total Hip Arthroplasty for Crowe II and III Hip Dysplasia**. *J Arthroplasty* 2018, **33**(7):2177-2181.
21. Flecher X, Parratte S, Brassart N, Aubaniac JM, Argenson JN: **Evaluation of the hip center in total hip arthroplasty for old developmental dysplasia**. *J Arthroplasty* 2008, **23**(8):1189-1196.
22. Abolghasemian M, Samiezadeh S, Jafari D, Bougherara H, Gross AE, Ghazavi MT: **Displacement of the hip center of rotation after arthroplasty of Crowe III and IV dysplasia: a radiological and biomechanical study**. *J Arthroplasty* 2013, **28**(6):1031-1035.
23. Traina F, De Fine M, Biondi F, Tassinari E, Galvani A, Toni A: **The influence of the centre of rotation on implant survival using a modular stem hip prosthesis**. *International orthopaedics* 2009, **33**(6):1513-1518.
24. Karaismailoglu B, Kaynak G, Can A, Ozsahin MK, Erdogan F: **Bilateral High Hip Center Provides Gait Parameters Similar to Anatomical Reconstruction: A Gait Analysis Study in Hip Replacement**

Patients With Bilateral Developmental Dysplasia. *J Arthroplasty* 2019, **34**(12):3099-3105.

25. Murayama T, Ohnishi H, Okabe S, Tsurukami H, Mori T, Nakura N, Uchida S, Sakai A, Nakamura T: **15-year comparison of cementless total hip arthroplasty with anatomical or high cup placement for Crowe I to III hip dysplasia**. *Orthopedics* 2012, **35**(3):e313-318.

Figures

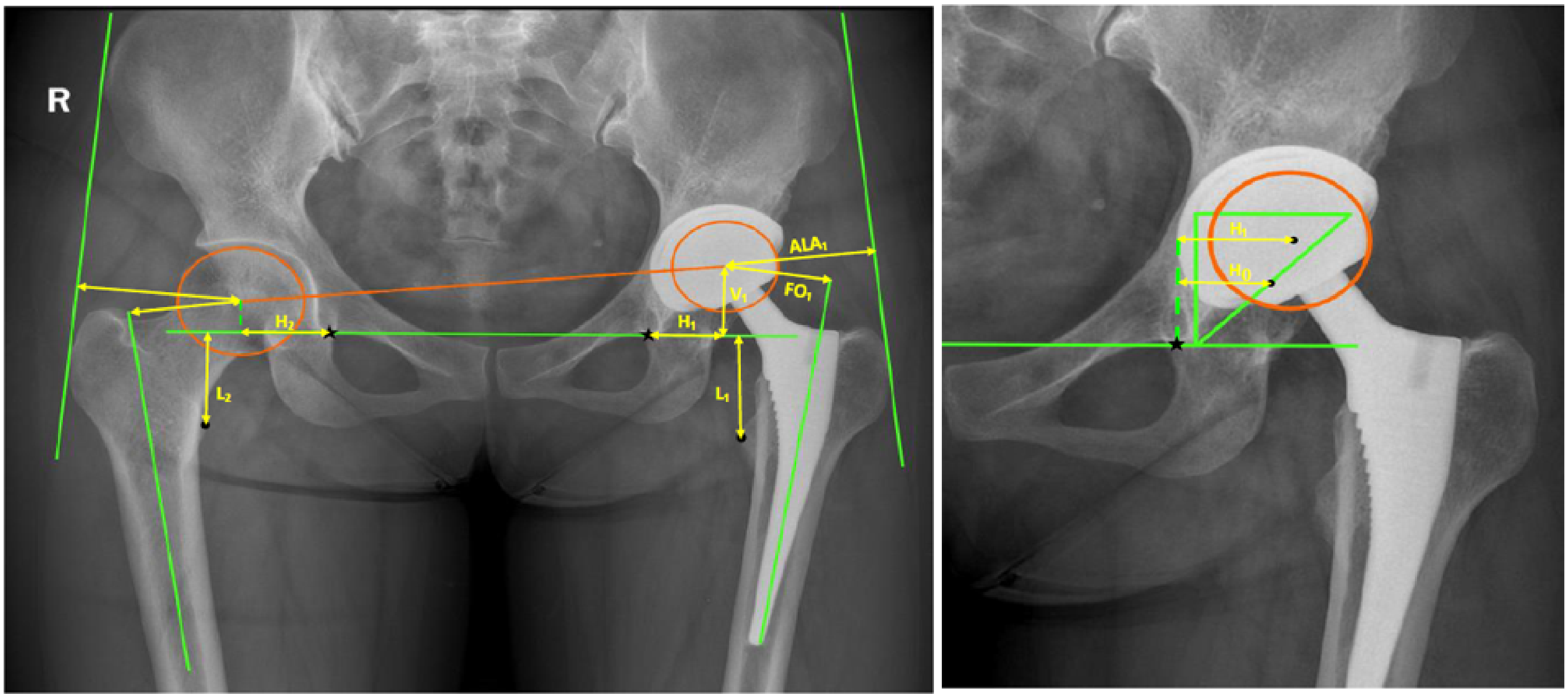

Figure 1

a) Diagram for radiographic measurement of unilateral HHC; b) Ranawat triangle was drawn to define the anatomic hip center of bilateral HHC. The star represents teardrop and the dot represent the apex of the lesser trochanter. V: vertical distance; H: horizontal distance; L: leg length; FO: femoral offset; ALA: abductor lever arm; Leg length discrepancy = |L1-L2|; △H = H2-H1 (unilateral HHC) or H0-H1 (bilateral HHC), positive indicates medialization and negative indicates lateralization.

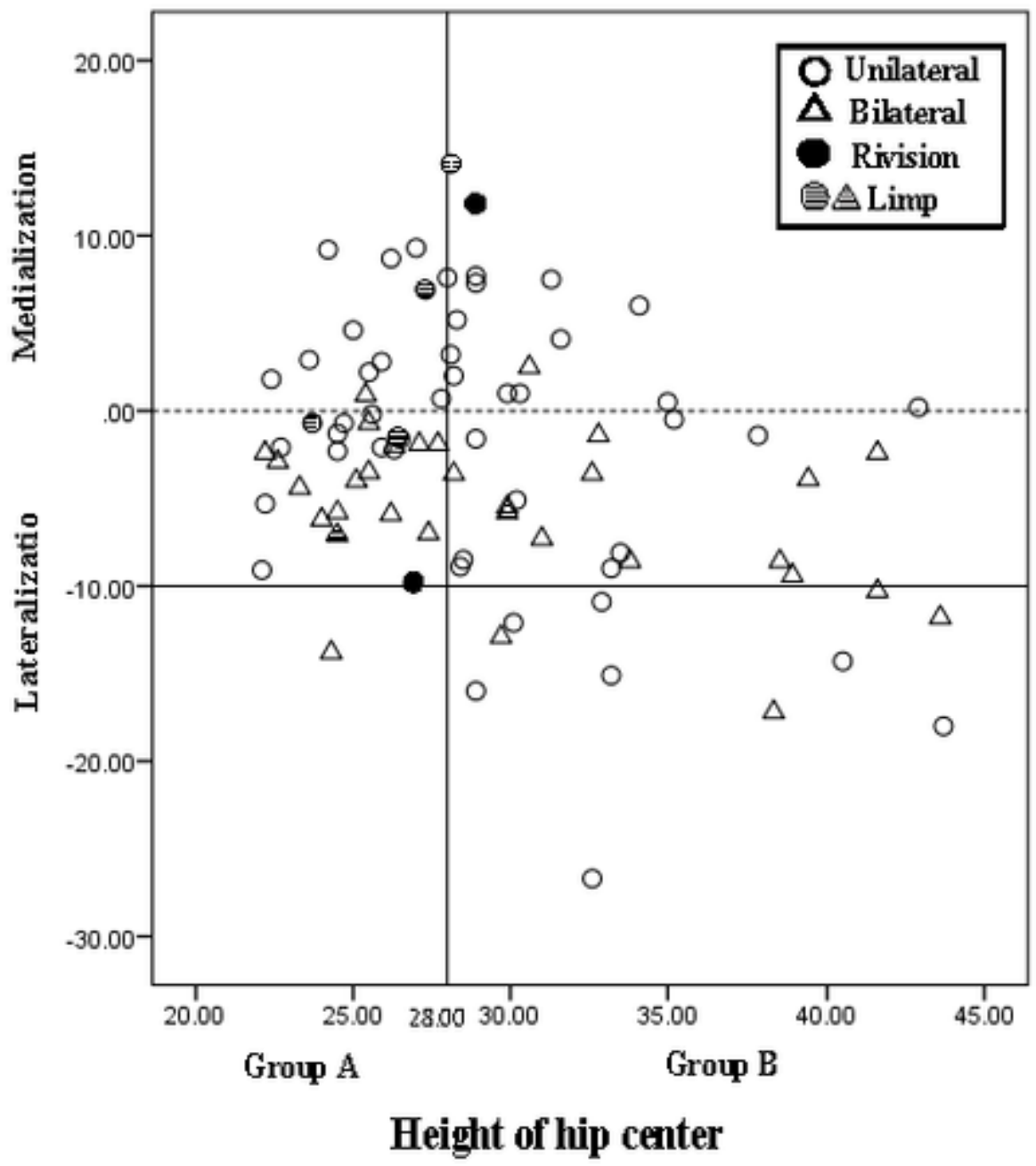

Figure 2

Scatter-gram of medialization or lateralization in both groups. Lateralization over 10mm in group B (11 hips) is significantly more than that (1 hip) in group A(P=0.012). No revision and limp were observed in lateral placement (≥ 10mm). Between unilateral (53 hips) and bilateral (32 hips) HHC, there is no significant difference of lateralization≥10mm (P=0.756).

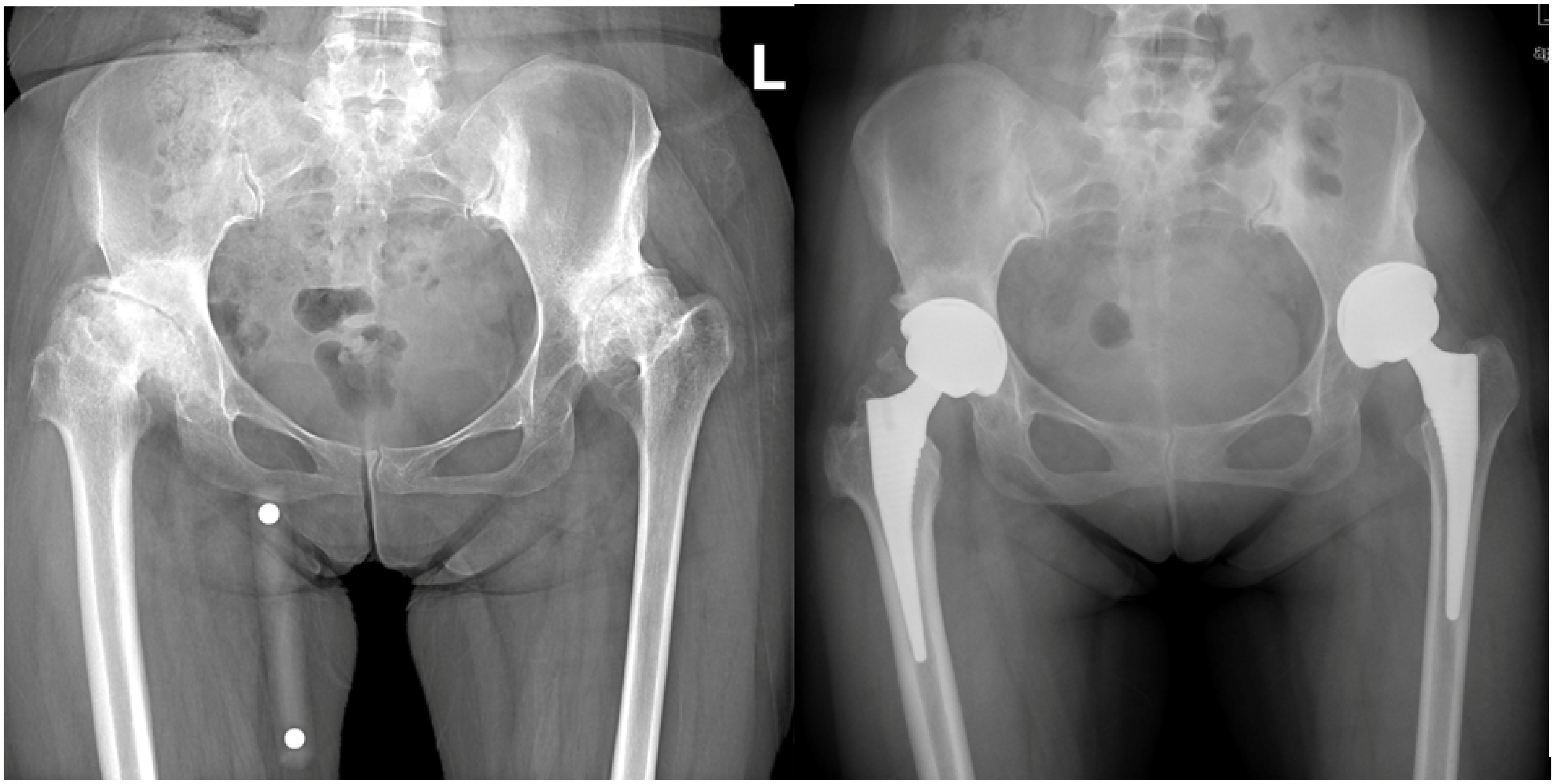

Figure 3

Preoperative (a) anterior-posterior X-ray highlighted a bilateral DDH (right hip as Crowe II and left hip as Crowe III) in a 47-year-old female patient (Crowe index: 0.13 in right hip and 0.16 in left hip). The postoperative anteroposterior radiographic evaluation after 8.8 years (b) showed no osteolysis and radiolucent line. The height of rotation center was 29.7mm in right hip and 38.5mm in left hip.

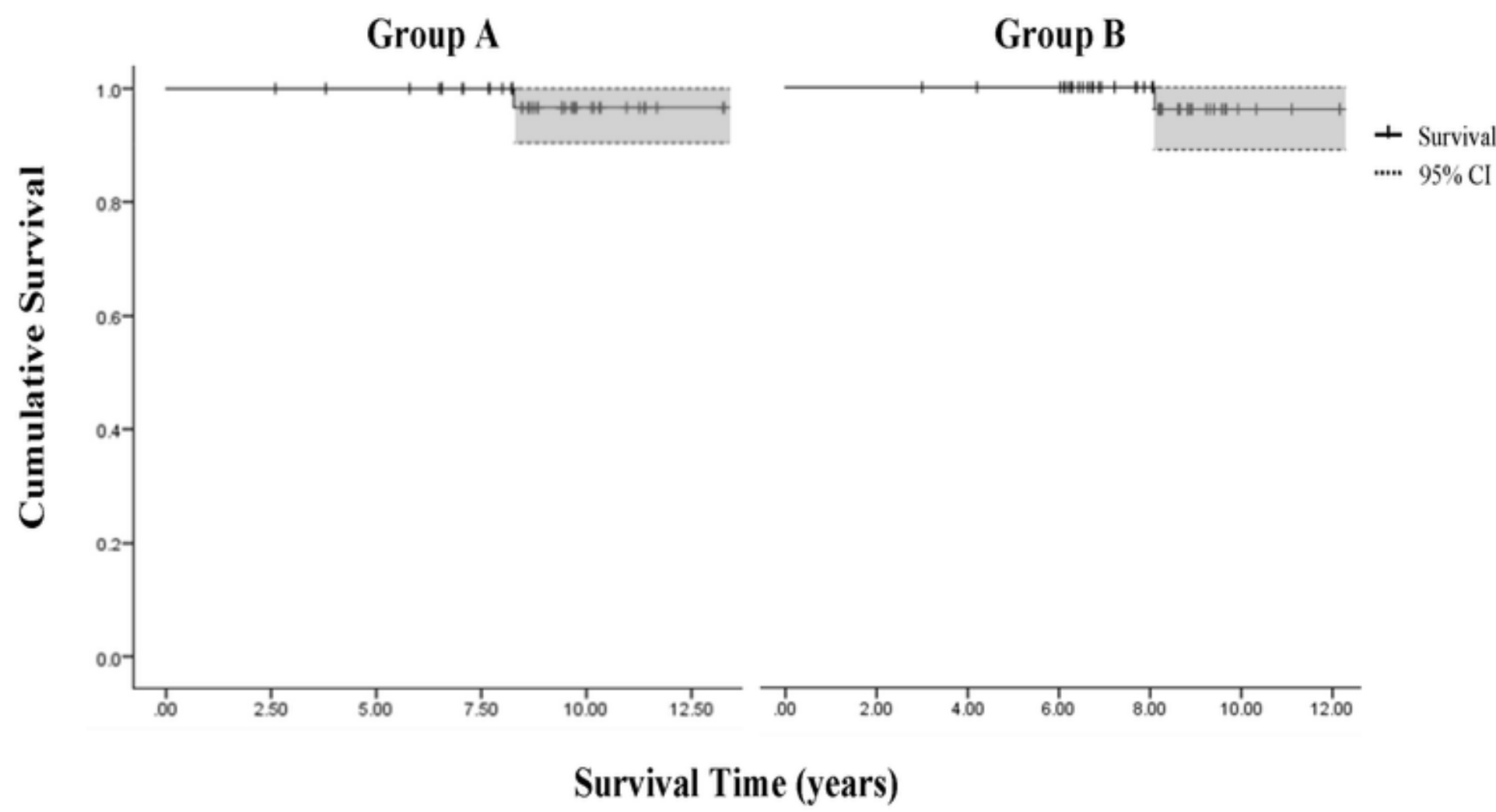

Figure 4

The Kaplan-Meier survival curve with revision for any reason as the end point for group A and group B was shown. CI, confidence interval.