

# Establishment and validation of finite element model of ossification of cervical posterior longitudinal ligament with intervertebral fusion

Li Hui

linfen people's hospital

Liu Huiqing

linfen people's hospital

Zhang Yaning (✉ [61975788@qq.com](mailto:61975788@qq.com))

---

## Research article

**Keywords:** ossification of posterior longitudinal ligament, finite element analysis, model, Biomechanics

**Posted Date:** March 12th, 2020

**DOI:** <https://doi.org/10.21203/rs.3.rs-16873/v1>

**License:** © ⓘ This work is licensed under a Creative Commons Attribution 4.0 International License.

[Read Full License](#)

---

# Abstract

[Background ]: To establish a three-dimensional finite element model of ossification of the posterior longitudinal ligament of the cervical spine with intervertebral fusion and verify its effectiveness, and provide a platform for finite element calculation and biomechanical analysis in the later stage.

[Method]: Select the Department of Spinal Surgery, Linfen People's Hospital A volunteer imported 719 DICOM format images of cervical spine CT scans into Mimics modeling software to build a preliminary 3D model in the stl format, and used Geomagic Studio 2013 software to refine and refine the 3D model to smooth out noise and generate NURBS surfaces The model was then imported into the finite element analysis software Ansys workbench 15.0, adding ligaments and intervertebral discs, meshing, assigning material properties, and simulating 6 activities of the human cervical spine, and comparing them with references.

[Results]: A total of 7 Cervical vertebral body, 1 thoracic vertebral body, 5 intervertebral discs and ligaments, etc., with a total of 320512 nodes and 180905 units. It has a realistic appearance, high degree of detail reduction, and ossification of the cervical longitudinal longitudinal ligament with good geometric similarity Incorporate a three-dimensional finite element model of intervertebral fusion. In flexion and extension, left and right lateral flexion, and axial rotation activity compared with references, there is not much difference.

[Conclusion]: OPLL merger interbody fusion dimensional finite element model has good mechanical and geometric similarity after similarity cervical established in this study, the model can provide a platform for the latter to further biomechanical analysis.

## Background

Ossification of posterior longitudinal ligament (OPLL) is a serious type of cervical degenerative disease. Epidemiological studies have shown that the incidence rate is high in Asian populations. The etiology is currently unknown. The pathogenesis is due to bone The compressed posterior longitudinal ligament compresses the spinal cord to produce a series of symptoms of spinal canal compression <sup>[1-2]</sup>. Mild patients can show numbness of the limbs, high muscle tone, and severe cases can form paraplegia. Osteosis of the posterior longitudinal ligament of the cervical spine often requires surgery. It is divided into anterior and posterior approaches or anterior and posterior approaches. Because the ossification of the posterior longitudinal ligament of the cervical spine is different from the normal cervical spine, the biomechanical characteristics are complex <sup>[3-4]</sup>. May cause related complications <sup>[5]</sup>. CT tomographic images of volunteers with ossification of posterior longitudinal ligament of cervical spine and degenerative intervertebral fusion were collected in this study, and computer-aided engineering software (Mimics 17.0, Geomagic Studio2013, Ansys workbench 15.0) A structurally complete three-dimensional finite element model was established, which provided a reliable model basis for later biomechanical analysis.

# 1. Methods

## 1.1 Research object

A volunteer from the Department of Spinal Surgery of Linfen People's Hospital was selected. The basic information of the patient was: male, 62 years old, 172 cm tall, 73 kg in weight, and the main complaint of admission was: numbness of the limbs, 3 years of convulsions, and aggravation of 3 months. A 128-slice CT scan + three-dimensional reconstruction of the cervical spine, cervical MRI, and cervical lateral x-rays (Figures 1 and 3) were performed. The cervical CT scan conditions were: layer thickness 0.625 mm, voltage 120 kv, cycle 0.6s, and a total of 719 sheets were obtained. DICOM format CT image. According to cervical CT, ossification of cervical posterior longitudinal ligament (neck 2-4, neck 5-6), intervertebral fusion (neck 5-6) (Figure 2), and clinical classification are mixed.

## 1.2 3D model with ct data

Mimics modeling: Use Mimics medical 3D reconstruction software to open the picture sequence in DICOM format. The software automatically reads the information contained in the picture sequence to restore the complete fault structure of the human body, and then sets the fault according to the orientation (axial, coronal, sagittal) prompts. The actual orientation of the picture, enter the main interface of mimics, the interface is divided into 4 windows (axial, coronal, sagittal, 3D), we can easily observe the situation of the structure in different orientations. Select the appropriate window of axial, coronal, sagittal, Set appropriate thresholds, distinguish vertebral bodies and soft tissues, establish different masks, and use draw and erase to edit the areas in the mask, so that the vertebral body structure boundaries we want are clear and complete. Create vertebral cortical bone by repeating detailed operations And cancellous bone model (Figure 4), export the processed spine model to stl format.

Geomagic Studio software refinement and refinement: Geomagic Studio is a stl processing software, importing stl files generated by mimics, using the software's repair function, to correct point clouds with poor quality in the stl format, removing noise and sharp parts, and closing openings Operations such as regions, eliminating small channels in the model, smoothing the surface of the model, etc., provide high-quality model preparation for subsequent meshing in the establishment of the finite element model. The refined model generation surface model is output to the igs format (Figure 6).

## 1.3 Building a finite element model

The three-dimensional model of the cervical posterior longitudinal ligament ossification combined with intervertebral fusion established earlier was imported into the finite element software Ansys workbench 15.0, and the finite element meshing was performed. Cervical 5-6 intervertebral fusion, posterior longitudinal ligaments and fused intervertebral discs cannot be added, only the remaining intervertebral discs and ligaments are added, and finally a complete three-dimensional finite element model of cervical posterior longitudinal ligament ossification combined with intervertebral fusion is generated (Figure 7). A torque of 1.5 Nm was gradually applied to the model to simulate the six basic movements of the human

cervical spine (forward flexion, extension, lateral flexion, and left-to-right rotation), and the cervical motion of the six sports was compared with the literature. Verification of the validity of a three-dimensional finite element model of the whole cervical spine

The six activities of the cervical spine model established above were compared with literature data to verify the effectiveness of the model in this paper.

## 2. Result

The three-dimensional finite element model of ossification of the posterior longitudinal ligament of the cervical spine and intervertebral fusion established in this study includes 7 cervical vertebral bodies, 1 thoracic vertebral body, 5 intervertebral discs, and ligaments, etc., a total of 320512 nodes and 180905 units. And the appearance is realistic, the degree of detail reduction is high, and it has very good geometric similarity (Fig. 7). In the comparison of flexion and extension, left and right side bending, axial rotation activity and the literature, it can be seen that there is not much difference, which was established in this institute. The model's mobility is smaller than that of the reference, on the one hand, due to the ossification of the posterior longitudinal ligament of the cervical spine, which limits the mobility of the cervical spine, and on the other hand, due to cervical 5–6 intervertebral fusion.

## 3. Conclusion

OPLL merger interbody fusion dimensional finite element model has good mechanical and geometric similarity after similarity cervical established in this study, the model can provide a platform for the latter to further biomechanical analysis.

## 4. Discussion

Ossification of the posterior longitudinal ligament of the cervical spine (OPLL) is a disease in which the posterior longitudinal ligament in the spinal canal is replaced by calcified tissue, which leads to spinal cord compression and neurological deterioration in the spinal canal. First reported by Key in 1960, Japanese scholars found that extensive posterior longitudinal ligament ossification in the cervical spinal canal during autopsy and caused cervical spinal cord compression. In 1964, Terayama and others officially named it "cervical posterior longitudinal ligament ossification." ". The disease is more common in Asian populations, especially in East Asia. The Japanese population has the highest incidence, while Europeans and other whites have a lower incidence, and men have a higher incidence than women.

The posterior longitudinal ligament is an internal structure of the spinal canal, starting from the pivot and lowering to the sacrum, covering the back of the vertebra, the front is the vertebra, and the back is the spinal cord. The ligament is wide and narrow, and the thoracic spine is thicker than the cervical and lumbar spines. The longitudinal ligament is wider in the intervertebral disc position and in close contact with the bone<sup>[4]</sup>. Compared to the anterior longitudinal ligament, the posterior longitudinal ligament is

denser and firmer than the anterior longitudinal ligament. The function of the posterior longitudinal ligament is mainly to maintain the stability of the spine and limit excessive spine Flexion and extension<sup>[10]</sup>. The etiology of ossification of the posterior longitudinal ligament of the cervical spine is still unclear, and may be related to trauma, chronic strain, inflammation, cervical disc degeneration, and genetic factors. The diagnosis of ossification of the posterior longitudinal ligament of the cervical spine mainly depends on cervical CT and three-dimensional Reconstruction<sup>[11]</sup>. In addition, cervical spine mri can observe the spinal cord compression and the severity of spinal cord disease, and predict the degree of spinal cord recovery after surgery.

The ossification of the posterior longitudinal ligament of the cervical spine combined with intervertebral fusion is different from the normal cervical vertebra morphology and biomechanics. The specific manifestations are as follows: first, the patient's cervical spine physiological curvature straightens and even recurves; second, cervical mobility Declining, the fusion of the upper and lower segments of the intervertebral segment will accelerate degeneration, and the above reasons will cause changes in the cervical biomechanics of the patient; in addition, ossification of the posterior longitudinal ligament often requires surgery, and surgery will once again change the biomechanics of the patient's cervical spine. Oppl surgical approach can be divided into anterior, posterior, and anterior and posterior approaches. For multi-segment ligament ossification, posterior approach is often chosen. Postoperative approach has the advantages of short operation time, less bleeding, and fewer complications. Whether it is a single door or a double door, the risk of cervical spine instability is greatly increased due to the damage to the posterior column<sup>[12]</sup>, cervical kyphosis will occur after surgery, and axial pain complications will occur. With the level of surgical technology With the continuous improvement of the anterior approach, the indications for anterior approach surgery are also expanding, and a new improved method<sup>[13]</sup> has appeared. Although anterior approach surgery does not have the problem of posterior cervical spine instability, multiple anterior approaches Will come out after fusion There is a decline in cervical mobility and further degeneration of adjacent segments.

How to analyze the biomechanical characteristics of the ossification of the posterior longitudinal ligament of the cervical spine and formulate corresponding measures to avoid cervical degeneration and the stability of spinal reconstruction after surgery are issues worthy of discussion by spinal surgeons. Defining biomechanical characteristics for the formulation of personalized surgery plans and Pre-judgment of postoperative curative effect is particularly important. In the past, when clinicians formulated a surgical plan before surgery, they often made it based on personal experience. There was no systematic theoretical support, and it included computer simulation modeling, biomechanical analysis, and surgical simulation drills. Digital medicine is particularly important for the formulation of scientific and personalized surgical strategies<sup>[14]</sup>. As early as the middle and late last century, digital medicine has emerged, and by the end of the last century, with the rapid development of information technology, digital medicine has With the rapid development, based on the assistance of digital medicine, it helps to diagnose and treat many diseases. With the formation of precise, minimally invasive and individualized

concepts in disease diagnosis and treatment, this concept has important implications for the field of spine surgery. significance.

The finite element model of ossification of the posterior longitudinal ligament of the cervical spine and intervertebral fusion established in this research is based on the CT data of the patient's cervical spine. The scan layer thickness is only 0.625 mm. The details of the model established can be restored to true, which can be 1: 1 Truly reflect the patient's cervical vertebra morphology. Based on this model, different working conditions can be designed in the later stage to simulate real surgical operations, such as posterior single-door spinal angioplasty, anterior direct decompression fusion, or anterior-posterior combination. Postoperative stability of the cervical spine, postoperative flexion, extension, and rotation stress tests, load stress tests at different segments or different internal fixation schemes, and the human sagittal balance parameters can be evaluated at the same time. Based on the statistical data, the best surgical plan is obtained through statistical analysis, to achieve the accurate formulation of individual surgical techniques before surgery and to predict the biomechanical characteristics of postoperative analysis. On the other hand, the format of the CT data imported into Mimics software is stl The model can be connected to 3D printing to print the model physically, perform surgical drills on the model, formulate internal fixation schemes, and evaluate postoperative effects.

The shortcomings of this study are that there are many clinical types of ossification of the posterior longitudinal ligament of the cervical spine, and the scope of ossification of the posterior longitudinal ligament is also different. This study only modeled one patient. In the later stage, the sample size needs to be expanded. Collect different types of cases and perform personalized modeling and biomechanical analysis on these cases.

To sum up, digital orthopedics is a new digital medical discipline based on orthopedics, supplemented by computer image processing technology, orthopedics clinical and computer technology. Digital orthopedics technology includes medical image processing, three-dimensional reconstruction and visualization technology, Computer aided design (cad), computer aided manufacturing (cam), finite element analysis technology (fea), etc. <sup>[15–16]</sup>. These technologies cover computer modeling, osteotomy simulation, implementation of internal fixation schemes, 3d printing, biomechanics The digital simulation of a complete system such as analysis provides a digital simulation platform for the formulation of personalized surgical plans and the avoidance of postoperative complications.

## Abbreviations

OPLL: Ossification of posterior longitudinal ligament

## Declarations

Ethics approval and consent to participate The ethics committee of Linfen People's Hospital agreed and approved the Establishment and validation of finite element model of ossification of cervical posterior

longitudinal ligament with intervertebral fusion study. All patients signed an informed consent approved by the institutional Review Board.

Consent for publication Patients in this study agree to publish personal information There are no conflicts of interest in this study.

Funding Without foud support in this study.

Authors' contributions LH's contribution to this article: brewing and designing experiments; conducting research; collecting data; analyzing / interpreting data.

L HQ's contribution to this article: implementation research; collection of data; analysis of data.

Z YN's contribution to this article: brewing and designing experiments; conducting research; collecting data.

Availability of data and material All data generated or analysed during this study are included in this published article.

Competing interests Without Competing interests.

## References

- [1] Umesawa M, Uchiyama K, Taneichi H, et al. Risk Factors for Ossification of Posterior Longitudinal Ligament[M]//Epidemiological Studies of Specified Rare and Intractable Disease. Springer, Singapore, 2019: 15-31.
- [2] Lee C H, Jahng T A, Hyun S J, et al. Expansive laminoplasty versus laminectomy alone versus laminectomy and fusion for cervical ossification of the posterior longitudinal ligament[J]. Journal of Spinal Disorders and Techniques, 2016, 29(1): E9-E15.
- [3] Tsukimato H A case report autopsy of compression of spinal cord owing to ossification within spinal canal of the cervical spine[J] Nippon Geka Hoka 1960 29 1003-1007
- [4] Koda M, Mochizuki M, Konishi H, et al. Comparison of clinical outcomes between laminoplasty, posterior decompression with instrumented fusion, and anterior decompression with fusion for K-line (–) cervical ossification of the posterior longitudinal ligament[J]. European Spine Journal, 2016, 25(7): 2294-2301.
- [5] Kawaguchi Y, Nakano M, Yasuda T, et al. Clinical impact of ossification of the posterior longitudinal ligament progression after cervical laminoplasty[J]. Clinical spine surgery, 2019, 32(3): E133-E139.
- [6] Brolin K, Halldin P. Development of a finite element model of the upper cervical spine and a parameter study of ligament characteristics[J]. Spine, 2004, 29(4): 376-385.

[7] Bevilaqua-Grossi, Debora, et al. "Cervical mobility in women with migraine." Headache: The Journal of Head and Face Pain49.5 (2009): 726-731.

[8] Tali, Danit, et al. "Upper cervical mobility, posture and myofascial trigger points in subjects with episodic migraine: case-control study." Journal of bodywork and movement therapies 18.4 (2014): 569-575.

[9] Trott, P. H., et al. "Three-dimensional analysis of active cervical motion: the effect of age and gender." Clinical Biomechanics11.4 (1996): 201-206.

[10] Boody B S, Lendner M, Vaccaro A R. Ossification of the posterior longitudinal ligament in the cervical spine: a review[J]. International orthopaedics, 2019, 43(4): 797-805.

[11] Katsumi K, Watanabe K, Izumi T, et al. Natural history of the ossification of cervical posterior longitudinal ligament: a three dimensional analysis[J]. International orthopaedics, 2018, 42(4): 835-842.

[12] Yang H, Sun J, Shi J, et al. Anterior controllable antedisplacement fusion (ACAF) for severe cervical ossification of the posterior longitudinal ligament: comparison with anterior cervical corpectomy with fusion (ACCF)[J]. World neurosurgery, 2018, 115: e428-e436.

[13] Katsumi K, Izumi T, Ito T, et al. Posterior instrumented fusion suppresses the progression of ossification of the posterior longitudinal ligament: a comparison of laminoplasty with and without instrumented fusion by three-dimensional analysis[J]. European Spine Journal, 2016, 25(5): 1634-1640.

[14] Bono, Christopher M, Min, et al. Avoiding complications in patients with ankylosing spondylitis undergoing spine surgery[J]. Current Opinion in Orthopaedics, 2005, 16(16):178-183.

[15] Baofeng L I, Zhang Y, Tai G, et al. Application of 3D digital orthopedic techniques in treatment of acetabular fracture[J]. Nan fang yi ke da xue xue bao = Jour nal of Southern Medical University, 2016, 36(7):1014.

[16] Zhao X, Chen C, Zhou T, et al. Analysis of single cage position in transforaminal lumbar interbody fusion through digital images.[J]. International Orthopaedics, 2018:1-7.

# Tables

Table 1: Model material parameters <sup>[6]</sup>



structure	Elastic Modulus	Poisson's ratio
Cortical bone	12000	0.3
Cancellous bone	500	0.2
Anterior longitudinal ligament	30	0.3
Interspinous ligament	20	0.3
Yellow ligament	20	0.3
Pterygium ligament	20	0.3
Transverse ligament	20	0.3
Cruciate ligament	20	0.3

Table 2 Comparison of flexion and extension of cervical spine model and literature data

Author	Forward bend	Back extension
Tali <sup>[7]</sup>	53.05°±11.41°	89.35°±18.07°
Bevilaqua <sup>[8]</sup>	57.56°±10.33°	68.13°±11.28°
Trott <sup>[9]</sup>	57.5°	76.1°
this research	46.1°	61.3°

Table 3 Comparison of cervical scoliosis activity and literature data

Author	Left turn	Right turn
Tali <sup>[7]</sup>	47.70°±7.71°	50.10°±5.33°
Bevilaqua <sup>[8]</sup>	45.64°±6.54°	49.11°±6.27°
Trott <sup>[9]</sup>	45.5°	47.6°
this research	32.4°	35.4°

Table 4 Comparison of cervical spine model rotation and literature data

Author	Rotate left	Rotate right
Tali <sup>[7]</sup>	69.95°±8.84°	71.30°±7.07°
Bevilaqua <sup>[8]</sup>	68.62°±8.47°	64.13°±7.32°
Trott <sup>[9]</sup>	71.7°	78.0°
this research	63.4°	60.4°

## Figures

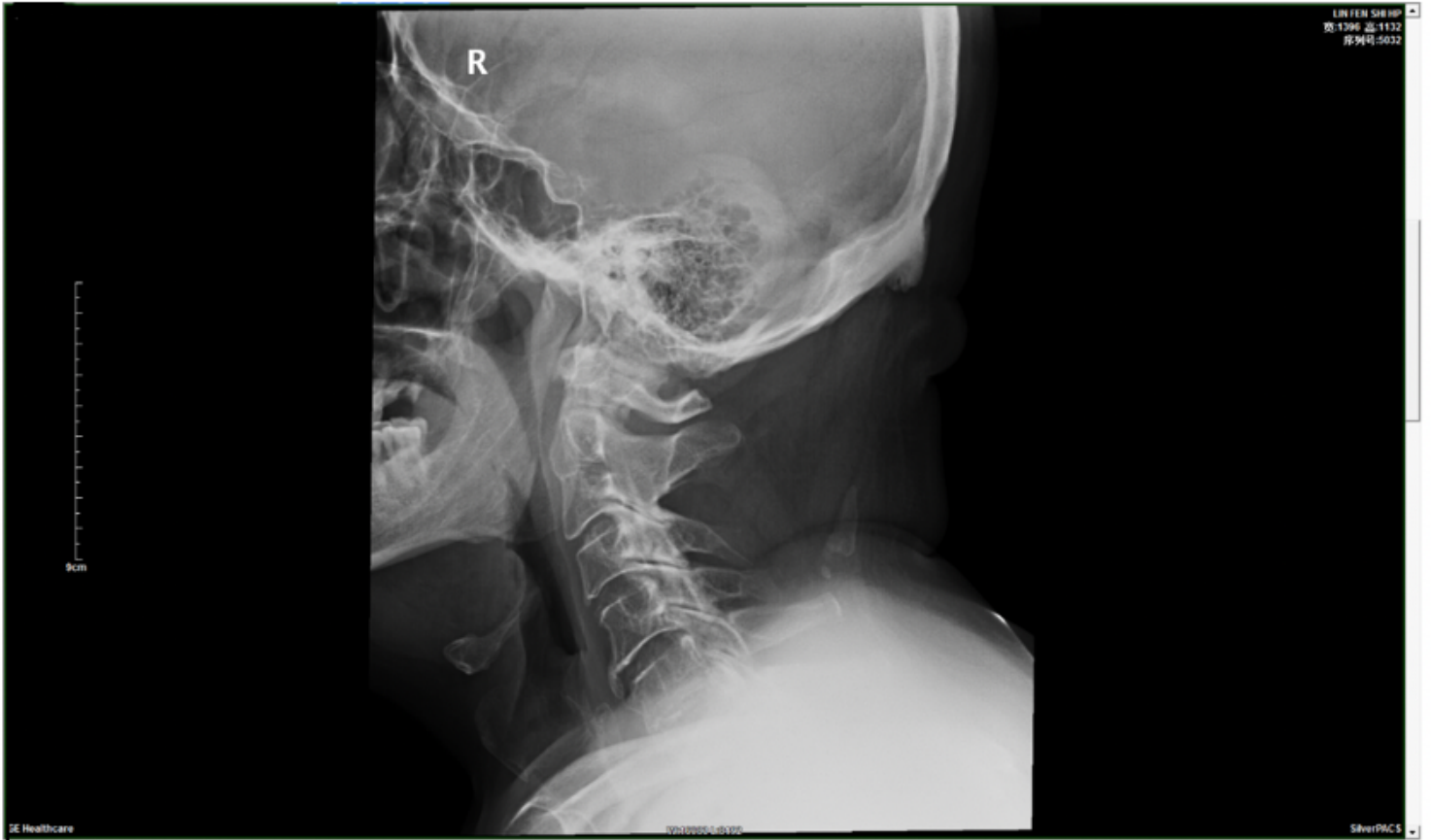


Figure 1

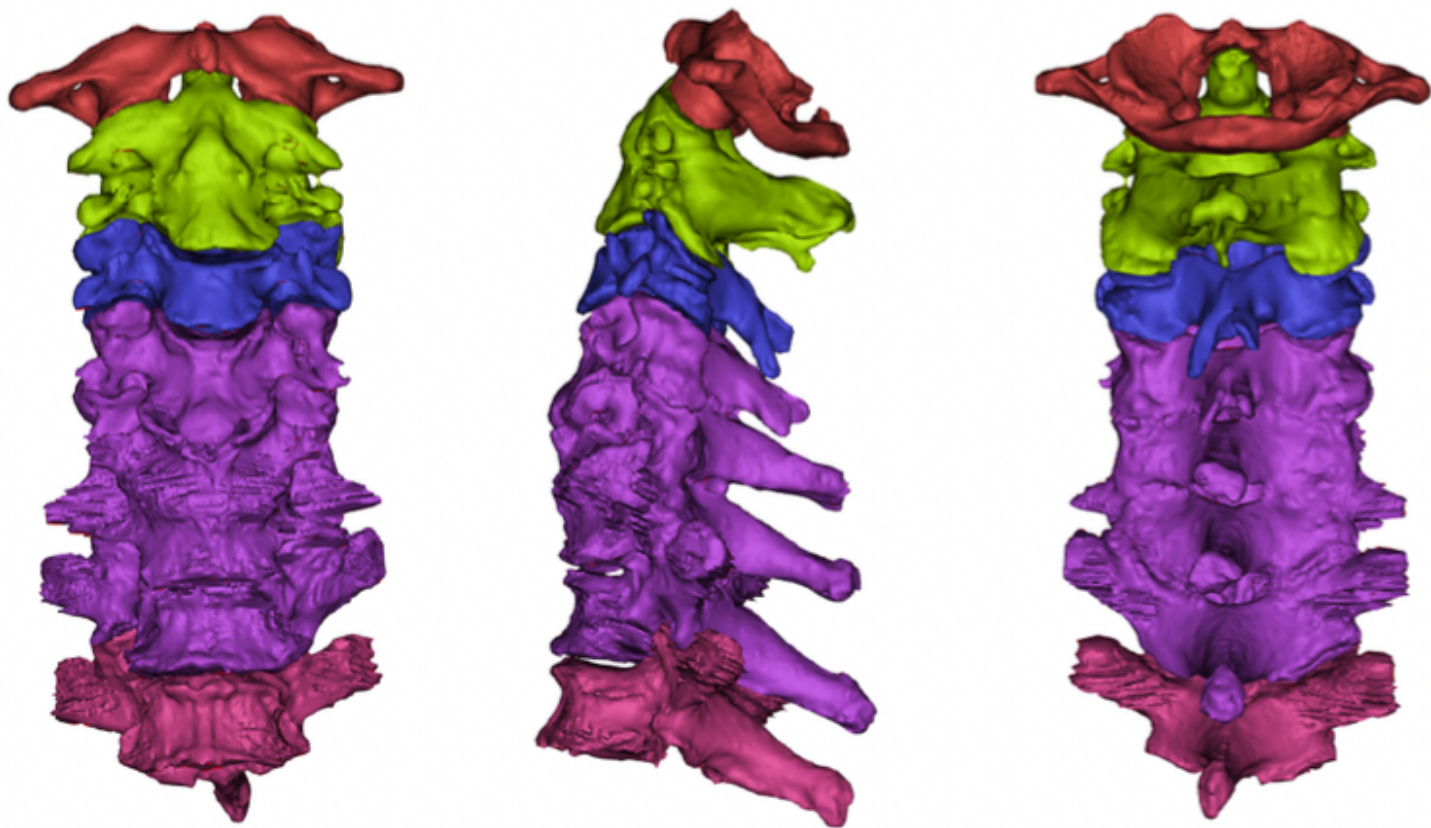
Patient's cervical spine x-ray

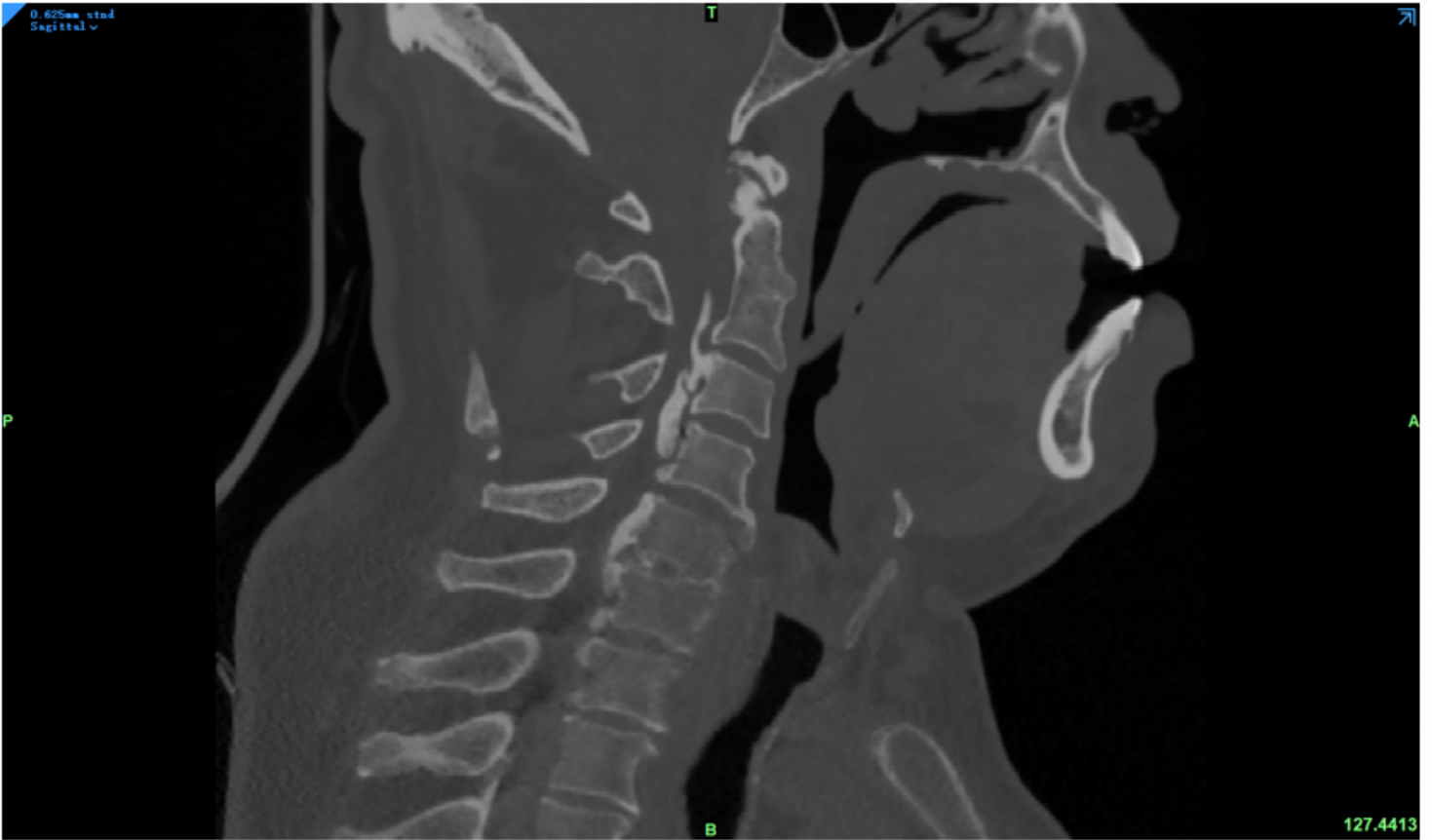

Figure 2

CT scan of the patient's cervical spine

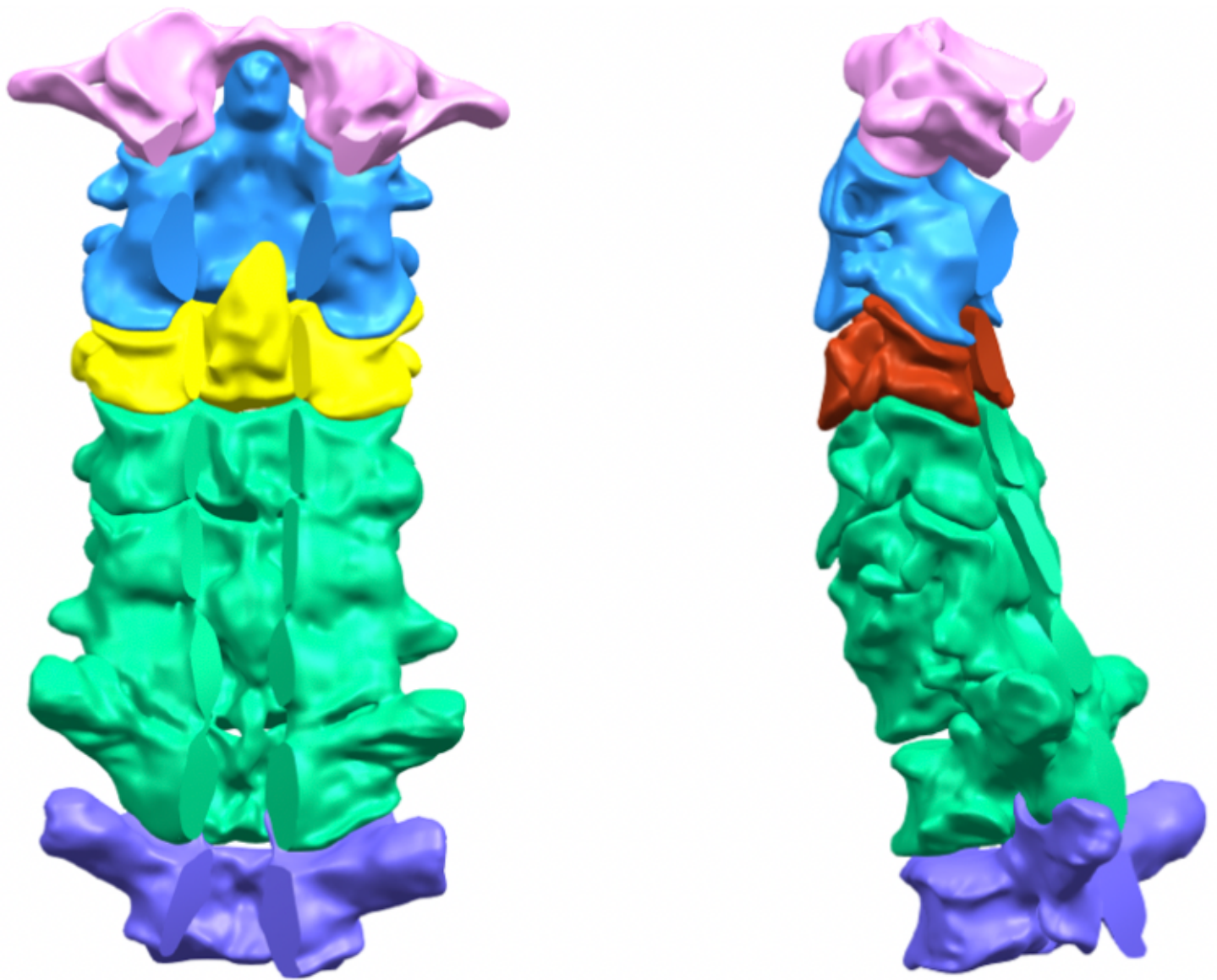




**Figure 4**

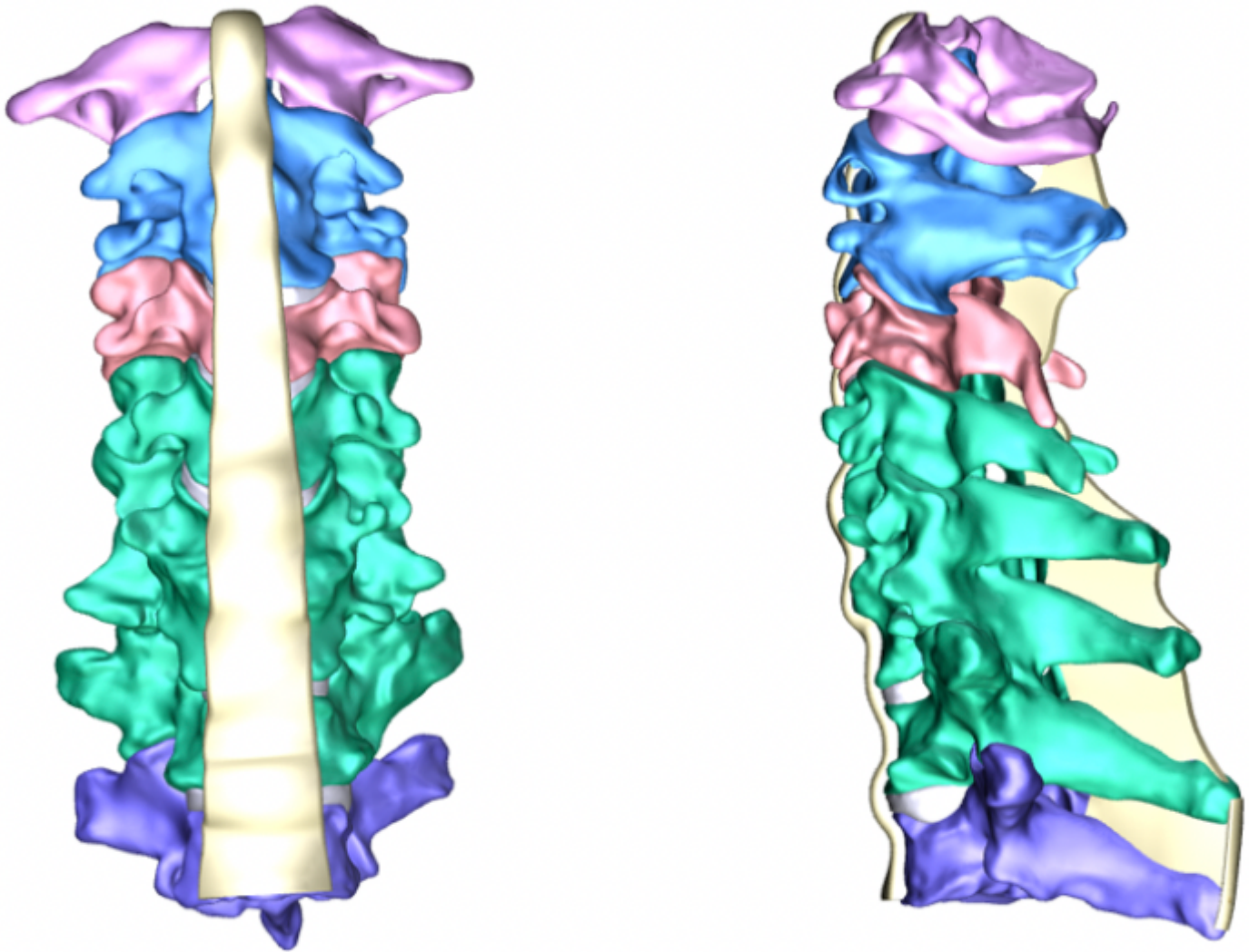
Preliminary 3D model of the vertebral body






**Figure 5**

Model of ossification of posterior longitudinal ligament



**Figure 6**

A complete 3D model of the cervical spine



**Figure 7**

Three-dimensional finite element model of cervical spine with posterior longitudinal ligament bone and interbody fusion