

# Infection after knee arthroplasty in an immunosuppressive patient caused by *Mycobacterium senegalense*: a case report and literature review

**Lei Tian**

Tongji Hospital of Tongji Medical College of Huazhong University of Science and Technology

**Feng Wang**

Tongji Hospital of Tongji Medical College of Huazhong University of Science and Technology

**Zhongju Chen**

Tongji Hospital of Tongji Medical College of Huazhong University of Science and Technology

**Yifan Zeng**

Tongji Hospital of Tongji Medical College of Huazhong University of Science and Technology

**Xuhui Zhu**

Tongji Hospital of Tongji Medical College of Huazhong University of Science and Technology

**Lu Gong**

Tongji Hospital of Tongji Medical College of Huazhong University of Science and Technology

**Xueman Wang**

Tongji Hospital of Tongji Medical College of Huazhong University of Science and Technology

**Ziyong Sun** (✉ [zysun@tjh.tjmu.edu.cn](mailto:zysun@tjh.tjmu.edu.cn))

Tongji Hospital of Tongji Medical College of Huazhong University of Science and Technology

---

## Case report

**Keywords:** nontuberculous *Mycobacterium*, *Mycobacterium fortuitum* group, debridement

**Posted Date:** March 11th, 2020

**DOI:** <https://doi.org/10.21203/rs.3.rs-16843/v1>

**License:** © ⓘ This work is licensed under a Creative Commons Attribution 4.0 International License. [Read Full License](#)

---

## Abstract

**Background** The infection caused by nontuberculous Mycobacterium (NTM) is gradually increasing in both hospital-acquired infection and community-acquired infection. The most common NTM mainly includes Mycobacterium fortuitum group, the M. chelonae/abscessus group and the M. smegmatis group. The infection caused by the third biological variety in M. fortuitum group is rarely reported worldwide.

**Case presentation** A 33-year-old female patient with 8-year history of rheumatoid arthritis underwent a right knee arthroplasty and developed postoperative infection. In hospital A, debridement was carried out to preserve the prosthesis joint. M. fortunatum was cultured in biopsy tissue taken out during operation and puncture fluid. Unfortunately, it is impossible to carry out the drug sensitivity test of Mycobacterium in hospital A. Local doctors used amikacin and levofloxacin to treat the patient empirically. In order to treat the infection accurately, the patient went to hospital B (a specialized hospital of tuberculosis) for drug sensitivity test. According to the results of drug sensitivity, cefoxitin, clarithromycin, amikacin and moxifloxacin were used in combination treatment. After two weeks of treatment, there was no significant remission, so the patient went to hospital C (a large teaching hospital) for joint prosthesis removal and bone cement frame transfer operation, and anti-infection treatment was carried out according to the drug sensitivity test results. One month later, the patient's condition improved significantly and the wound healed.

**Conclusions** NTM should be considered as main pathogens in immunosuppressive patients when the wound did not heal due to infection. Simple antibiotic treatment is not good for deep abscess, but treatment combined with surgical debridement and appropriate antibiotics is obviously effective.

## Background

Nontuberculous Mycobacterium (NTM) is mainly distributed in soil, dust, river and tap water. According to the different growth speed, it can be divided into rapid growing mycobacterium (RGM) and slow growing mycobacterium (SGM). RGM refers to the colony that can be seen by naked eyes within 7 days when grow on solid medium. The mycobacteria with colonies more than 7 days old can be seen are SGM. For skin and soft tissue infection, RGM is the main pathogen usually. In clinic, Mycobacterium fortunatum, Mycobacterium chelonae and Mycobacterium abscessus are the most common.

In taxonomy, M. fortuitum group includes M. fortuitum, M. peregrinum, and the unnamed third biovariant complex [1]. Traditionally, according to the result of sorbitol test, the third biological variety of M. fortuitum group can be divided into two groups: negative and positive of sorbitol test. With the development of molecular biology and whole genome sequencing technology, the classification of the third biological variety of M. fortuitum group is becoming more and more precise. At present, the third biological variety of M. fortuitum group included M. senegalense, M. mageritense, M. septicum, M. porcinum, M. neworleanense, M. brisbanense, M. houstonense and M. bonickei [2]. The gene sequences of these strains are very close, and the difference of 16sDNA sequence is 15 bp or less [1].

There are very limited reports of infection caused by the third biological variant of M. fortuitum. Here we report a case of infection after arthroplasty caused by M. senegalense. From this case, we summarize the diagnosis and treatment process of patients, hoping to provide some reference for the future clinical treatment.

## Case Presentation

A 33-year-old female patient developed incision pain accompanied by exudation of yellow purulent secretion after right knee replacement (fig 1). The patient had a history of rheumatoid arthritis for more than 8 years. She took methotrexate and leflunomide for a long time. The patient first went to hospital A and found that the right knee joint was swollen and the skin temperature was slightly high. The incision of the operation was interrupted, which could be seen to pass through the superficial subcutaneous sinus about the size of mung bean all the time, and the yellow brown purulent secretion could be seen to flow out (fig 1). The main laboratory test positive indexes were C-reactive protein 32.97mg/l, rheumatoid factor 78.7u/ml, ESR 120mm / h, hemoglobin 85g / L, albumin 27g / L, blood potassium 3.36mmol/l, blood calcium 1.72mmol/l. The swollen right knee joint was punctured, and a large number of leukocytes were found in the puncture fluid and *M. fortuitum* was detected in the puncture fluid culture. The surgeons performed surgical debridement while preserving the prosthesis joint. *M. fortuitum* was detected in the tissues taken during operation and the culture of puncture fluid. Because in hospital A the drug sensitivity test of *M. fortuitum* is unable to be carried out, amikacin 0.4g per day, levofloxacin 0.6g per day intravenous drip were used to treat the patients. In order to accurately use antibiotics for treatment, the patient went to hospital B (a special hospital of tuberculosis) to carry out the drug sensitivity test of *M. fortuitum*. According to the results of drug sensitivity, the doctors adjusted the treatment drug, and changed it into intravenous drip of cefoxitin 4.0 g twice a day, intravenous drip of amikacin 0.5 g once a day, intravenous drip of moxifloxacin 0.4 g once a day, and oral administration of clarithromycin 0.5 g twice a day. However, after two weeks of treatment, the patient's condition did not improve significantly. In order to relieve the pain as soon as possible, the patient went to hospital C (a large teaching hospital). In the hospital C, doctors carried out a systematic test on the patient. The detection results of rheumatoid factor and autoantibody of patient were detailed in Table 1. The analysis of the immune function of the patients, including the lymphocyte classification count and its function analysis, were detailed in Table 2. Lymphocyte technology and function analysis were performed by flow cytometry (FACSC CANTO, BD, USA). The results showed that the number of lymphocytes was normal, but the function of T and B lymphocytes and NK cells decreased, demonstrating the patient was in the state of immunosuppression. Surgeons removed the prosthesis and moved the bone cement frame into the patient. The preoperative and postoperative joint imaging data are shown in Figure 2 and figure 3, respectively. *RGM* was detected by bacteriological culture of the tissue samples taken out during the operation. It was identified as *M. senegalense* by IVD-MALDIBIOTYPER (Antu, zhengzhou, China) (fig 4). The strain was re identified as *M. senegalense* by sequencing technology. First generation sequencer (Life Technology 2500 DX, ABI, Japan) was used for sequencing operation. PCR amplification of 16S rDNA and sequencing of PCR products were performed using primers described previously [3]. Compared with those available in the National Center for Biotechnology Information GenBank database, the expansion products of the strain is 99.83% similar to that of *M. Senegal* (GenBank accession no. Lc082328.1). The drug sensitivity test used the *RGM* drug sensitivity test strip provided by thermo company, and the test principle was micro broth dilution method. The results were interpreted according to CLSI M24-A2 [4], as shown in Table 3. According to the drug sensitivity results, doctors found that the antibiotics selected in hospital B did not contradict the drug sensitivity results, so they continued to treat according to this plan. After one month of treatment, the wound healed and the patient's condition improved significantly.

## Literature review

We searched PubMed for cases of *M. fortuitum* group infection and found 10 case reports in addition to ours (Table 4). We found that the previous case reports showed that the *M. fortuitum* group mainly caused wound infection and skin and soft tissue infection. In most cases, the immune function of the patients was not evaluated but drug sensitivity tests were carried out for all of them. The antibiotics used in the treatment were mainly fluoroquinolones such as ciprofloxacin, levofloxacin, moxifloxacin, ofloxacin, aminoglycosides such as amikacin and gentamycin, carbapenems such as imipenem and meropenem, doxycycline and trimethoprim-sulfamethoxazole. When the patient had deep abscess formation, the combination of surgical debridement and appropriate antibiotics had a very significant therapeutic effect. All the patients were cured of the infection caused by *M. fortuitum* group.

## Discussion And Conclusions

NTM is a common pathogen and a life-threatening infection for people with low immune function, especially for organ transplant patients or stem cell transplant patients [14]. In this case, the patient had a history of rheumatoid arthritis for eight years, and took methotrexate and leflunomide for a long time. The lymphocyte classification of the patients showed that the number of total T-lymphocytes, total B-lymphocytes, helper / inducer T-lymphocytes and suppressor / cytotoxic T-lymphocytes were normal. However, the analysis of lymphocyte function showed that the proportion of IFN -  $\gamma$  positive cells in total CD4 positive T cells, total CD8 positive T cells and NK cells decreased after induction. It showed that the lymphocyte function of the patients was decreased. The results were consistent with the history of rheumatoid arthritis and long-term use of immunosuppressive drugs. For people whose immune function was inhibited, NTM should be considered as a common pathogen.

The pathogenic bacteria in this case is *M. senegalense*, which was identified by IVD-MALDIBIOTYPER and sequencing in hospital C. However, the identification results of both hospital A and hospital B were *M. fortuitum*. In fact, these results were not contradictory. *M. senegalense* belongs to the third biological variety of *M. fortuitum* group. The commonly used laboratory identification methods include IVD-MALDIBIOTYPER and sequencing. Adela ALCOLEA Medina et al. showed that the accuracy of IVD-MALDIBIOTYPER in identifying Mycobacterium was not 100% compared with sequencing method. The results showed that the accuracy of identification of RGM and SGM were 75% and 85%, respectively compared with sequencing technology [15]. It can be seen that the identification results of NTM by IVD-MALDIBIOTYPER are not 100% accurate. At present, the level of NTM identification to species must depend on the means of sequencing.

*M. senegalense* was first found in Africa and was mainly prevalent in Africa. In taxonomy, it belongs to the third biological variety of *M. fortuitum*. The third biological variation of *M. fortuitum* mainly caused catheter-related infection in immunosuppressed population and surgical wound infections, osteomyelitis following open fractures and localized post-traumatic wound infections in normal immune function population [1]. As NTM mainly come from the soil, dust and water flow in the natural environment, the outbreak of nosocomial infection was mainly seen in the pollution of medical water, and community acquired infection was mainly seen in post-traumatic infection, such as foot on nail or motor vehicle accident trauma [1]. Based on the review of previous reports, we found that *M. fortuitum* group mainly caused wound and skin soft tissue infection.

Through the summary of this case, we know that for the treatment of deep abscess, only relying on antibiotics treatment, the effect is not good. Surgical debridement combined with appropriate antibiotics is very effective. If

it is treated by surgery alone, the infection will recur easily 4–6 weeks after operation [1]. Early studies by Wallace et al. showed that 17% (13 / 76) of the *M. fortunatum* group and 6% (3 / 47) of the *M. cheloni*-abscess group could be successfully cured only by surgical means [16].

## Conclusions

For the infection of immunosuppressive patients, NTM is a very important pathogen. The treatment of deep abscess only depends on antibiotics or surgical debridement alone, and the therapeutic effect is not good enough. Only surgical debridement combined with appropriate antibiotics can achieve satisfactory therapeutic effect.

## Abbreviations

NTM: nontuberculous Mycobacterium, RGM: rapidly growing mycobacteria, SGM: slow growing mycobacterium

## Declarations

### Ethics approval and consent to participate

The study protocol was approved by the Tongji Hospital ethics committee for research in health. Informed written consent was obtained from the patient.

### Consent to publish

The patient provided written consent for the case details to be published.

### Availability of data and materials

All data is contained within the manuscript. Clinical isolates will be made available upon requests from Dr. Ziyong Sun.

### Competing interests

The authors declare that they have no competing interest.

### Funding

This work was supported by research grants from the National Mega Project on Major Infectious Disease Prevention (2017ZX10103005-007) and Provincial Natural Science Foundation (2019CFB666). The funders had no role in study design, data collection and analysis, decision to publish, or preparation of the manuscript.

### Authors' contributions

LT drafted the manuscript. FW analyzed the immune function of patients by flow cytometry. YZ was in charge of the patient's treatment process. XW, LG and HZ completed the sequencing operation. ZC and ZS were in charge of the laboratory work. All authors read and approved the final manuscript.

## Acknowledgements

We are particularly grateful to THERMO corporation for providing the antimicrobial sensitivity test strip (TREK Diagnostic Systems, SENSITITRE) for this experiment.

## Authors' Information

LT, FW, ZC, HZ, LG, XW and ZS were from Department of Clinical Laboratory, Tongji Hospital, Tongji Medical College, Huazhong University of Science and Technology, Wuhan, Hubei Province, China. YZ was from Department of Orthopedic surgery, Tongji Hospital, Tongji Medical College, Huazhong University of Science and Technology, Wuhan, Hubei Province, China.

## References

1. Brown-Elliott BA, Wallace RJ, Jr.: **Clinical and taxonomic status of pathogenic nonpigmented or late-pigmenting rapidly growing mycobacteria.** *Clin Microbiol Rev* 2002, **15**(4):716-746.
2. Schinsky MF, Morey RE, Steigerwalt AG, Douglas MP, Wilson RW, Floyd MM, Butler WR, Daneshvar MI, Brown-Elliott BA, Wallace RJ, Jr. *et al.*: **Taxonomic variation in the *Mycobacterium fortuitum* third biovariant complex: description of *Mycobacterium boenickei* sp. nov., *Mycobacterium houstonense* sp. nov., *Mycobacterium neworleansense* sp. nov. and *Mycobacterium brisbanense* sp. nov. and recognition of *Mycobacterium porcinum* from human clinical isolates.** *Int J Syst Evol Microbiol* 2004, **54**(Pt 5):1653-1667.
3. Lane DJ. 16S/23S rRNA sequencing. In: Stackebrandt E, Goodfellow M, editors. *Nucleic acid techniques in bacterial systematics.* Wiley: Chichester, 1991. p. 115-175.
4. Clinical and Laboratory Standards Institute. *Susceptibility Testing of Mycobacteria, Nocardiae, and Other Aerobic Actinomycetes; Approved Standard— Second Edition M24-A2.* Wayne, PA: Clin Lab Stand Institute; 2011.
5. Tian L, Zhang Z, Chen Z, Sun Z: **Surgical wound infection following open humeral fracture caused by *Mycobacterium houstonense*: a case report.** *BMC Infect Dis* 2019, **19**(1):333.
6. Tsai SC, Chen LH, Liao HH, Chiang CY, Lin WL, Chen SC, Tsao SM, Hung HC, Lee YT: **Complicated skin and soft tissue infection with *Mycobacterium fortuitum* following excision of a sebaceous cyst in Taiwan.** *J Infect Dev Ctries* 2016, **10**(12):1357-1361.
7. Chogtu B, Malik DV, Magazine R, Shenoy VP: ***Mycobacterium fortuitum* Infection at Umbilical Hernioplasty Site.** *J Clin Diagn Res* 2017, **11**(9):OD01-OD02.
8. Torres-Duque CA, Diaz C, Vargas L, Serpa EM, Mosquera W, Garzon MC, Mejia G, Garcia LM, Gonzalez LA, Castro CM *et al.*: **Disseminated mycobacteriosis affecting a prosthetic aortic valve: first case of *Mycobacterium peregrinum* type III reported in Colombia.** *Biomedica* 2010, **30**(3):332-337.
9. Hod T, Kushnir R, Paitan Y, Korzets Z: ***Mycobacterium fortuitum* infection in continuous ambulatory peritoneal dialysis.** *Clin Nephrol* 2008, **70**(6):546-553.
10. Nagao M, Sonobe M, Bando T, Saito T, Shirano M, Matsushima A, Fujihara N, Takakura S, Iinuma Y, Ichiyama S: **Surgical site infection due to *Mycobacterium peregrinum*: a case report and literature review.** *Int J Infect Dis* 2009, **13**(2):209-211.
11. Cheung I, Wilson A: ***Mycobacterium fortuitum* infection following total knee arthroplasty: a case report and literature review.** *Knee* 2008, **15**(1):61-63.

12. Serra C, Loi G, Saddi B, Pautasso M, Manzin A: **Unusual clinical presentation of *Mycobacterium fortuitum* infection in an immunocompetent woman.** *J Clin Microbiol* 2007, **45**(5):1663-1665.
13. Saccente M: ***Mycobacterium fortuitum* group periprosthetic joint infection.** *Scand J Infect Dis* 2006, **38**(8):737-739.
14. Friedman DZP, Cervera C, Halloran K, Tyrrell G, Doucette K: **Non-tuberculous mycobacteria in lung transplant recipients: Prevalence, risk factors, and impact on survival and chronic lung allograft dysfunction.** *Transpl Infect Dis* 2019:e13229.
15. Alcolea-Medina A, Fernandez MTC, Montiel N, Garcia MPL, Sevilla CD, North N, Lirola MJM, Wilks M: **An improved simple method for the identification of *Mycobacteria* by MALDI-TOF MS (Matrix-Assisted Laser Desorption- Ionization mass spectrometry).** *Sci Rep* 2019, **9**(1):20216.
16. Wallace RJ, Jr., Swenson JM, Silcox VA, Bullen MG: **Treatment of nonpulmonary infections due to *Mycobacterium fortuitum* and *Mycobacterium chelonae* on the basis of in vitro susceptibilities.** *J Infect Dis* 1985, **152**(3):500-514.

## Tables

Table 1. Detection of rheumatoid index

Testing items	Results	Reference range	Unit
Rheumatoid factor	118↑	0-30	IU/ml
Anti-keratin antibody	positive	negative	
Anti-cyclic citrullinated peptide antibody	>400↑	0-20	RU/ml
Antinuclear antibody	1:100 Nuclear particle type 1:100 nuclear homogeneous type	<1:100 negative	

Table 2. Lymphocyte classification and function analysis

Testing items	Results	Reference range	Unit
Total T lymphocytes (CD3+CD19-) (#)	1202	955-2860	Quantity/ul
(CD3+CD19-) (%)	77.44	50-84	%
Total B lymphocytes (CD3-CD19+) (#)	324	90-560	Quantity/ul
(CD3-CD19+) (%)	20.91↑	5-18	%
Helper / inducible T lymphocytes (CD3+CD4+) (#)	807	550-1440	Quantity/ul
(CD3+CD4+) (%)	52.04↑	27-51	%
Suppressor / cytotoxic T lymphocytes (CD3+CD8+) (#)	369	320-1250	Quantity/ul
(CD3+CD8+) (%)	23.79	15-44	%
NK cell (CD3-/CD16+CD56+) (#)	19↓	150-1100	Quantity/ul
(CD3-/CD16+CD56+) (%)	1.20↓	7-40	%
Percentage of IFN - $\gamma$ positive cells after induction in total CD4 + T cells	6.80↓	14.54-36.96	%
Percentage of IFN - $\gamma$ positive cells after induction in total CD8 + T cells	16.72↓	34.93-87.95	%
Percentage of IFN - $\gamma$ positive cells after induction in total NK cells	24.14↓	61.2-92.65	%

Table 3. Antimicrobial sensitivity of *Mycobacterium porcinum*

Antibacterial drugs	MIC (ug/ml)	Breakpoints( µg/mL)			Results
		Susceptible	Intermediate	Resistant	
trimethoprim sulfamethoxazole	8/152	≤2/38	-	≥4/76	resistant
ciprofloxacin	≥4	≤1	2	≥4	resistant
moxifloxacin	2.0	≤1	2	≥4	Intermediate
cefoxitin	32	≤16	32-64	≥128	Intermediate
amikacin	≤1	≤16	32	≥64	sensitive
doxycycline	0.5	≤1	2-4	≥8	sensitive
tegafycline	0.5	-	-	-	-
linezolid	4	≤8	16	≥32	sensitive
imipenem	16	≤4	8-16	≥32	Intermediate
cefepime	≥32	-	-	-	-
amoxicillin-clavulanate	≥64/32	-	-	-	-
ceftriaxone	≥64	-	-	-	-
minocycline	≤1	-	-	-	-
tobramycin	4	≤2	4	≥8	Intermediate
clarithromycin	≤0.06	≤2	4	≥8	sensitive

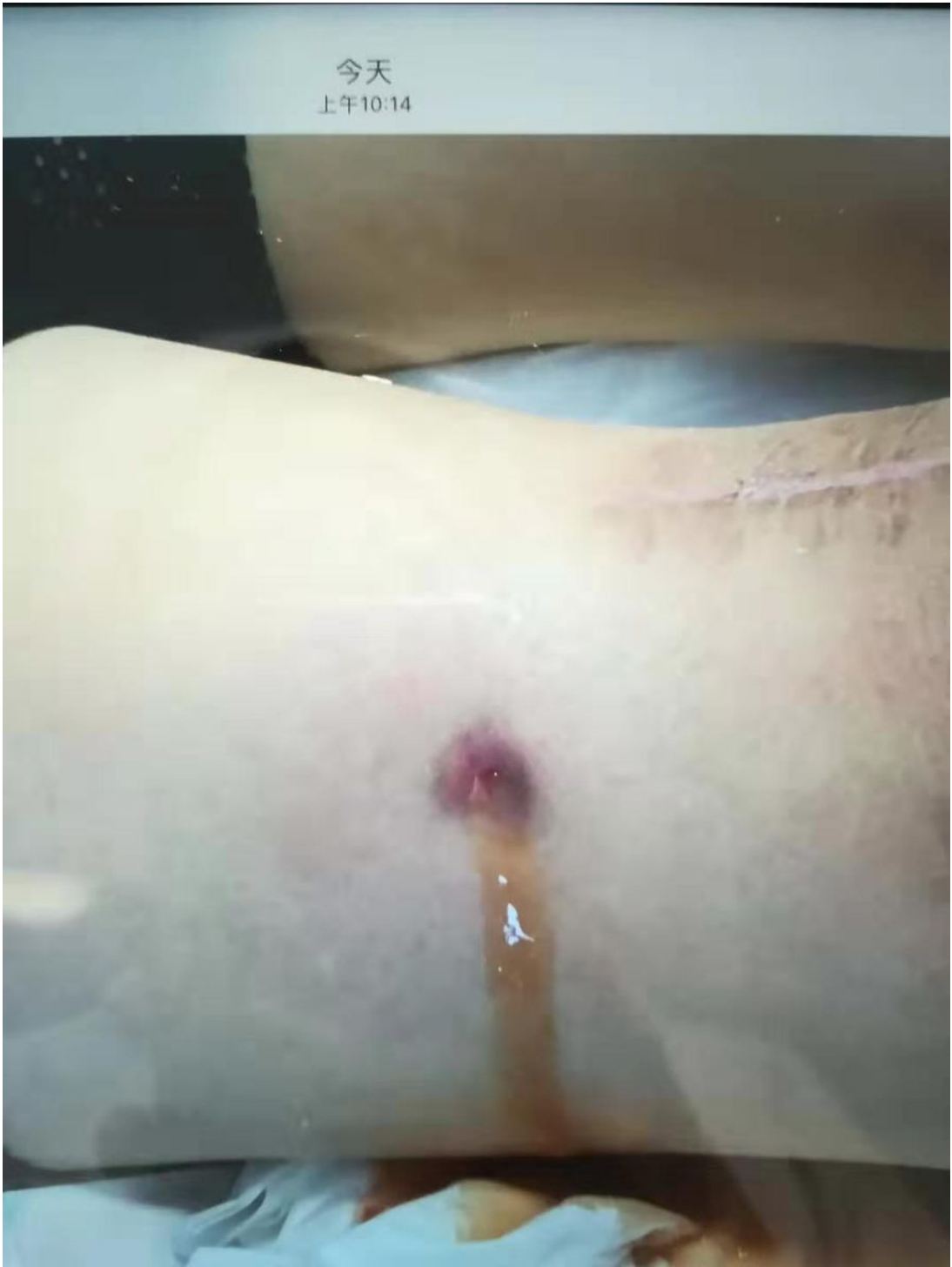Note: - No Breakpoint in CLSI M24-A2

Table 4. Published cases of Mycobacterium fortuitum group infection

Case No	Author	Country	Year	Sex/ Age	Cause of NTM infection	Infection location	Underlying diseases	Immune state	Treatment	Prognosis
1	Lei tian/China/2019[5]			Male/68-year-old	M. houstonense	Surgical wound infection	open humeral fracture	unknown	Levofloxacin and amikacin, surgical debridement	Recovery
2	Shih-Chen Tsai/China/2016[6]			Male/40-year-old	M. fortuitum	skin and soft tissue infection	a sebaceous cyst in the abdominal wall	immunocompetent	imipenem/cilastatin, amikacin, clarithromycin	Recovery
3	BhartI Chogtu/India/2017[7]			Male/51-year-old	M. fortuitum	wound infection	umbilical hernia	unknown	azithromycin, trimethoprim-sulfamethoxazole, ciprofloxacin	Recovery
4	Carlos A. Torres-Duque/Colombia/2010[8]			Female/seventeen-year-old	M. peregrinum	pulmonary infection	prosthetic aortic valve endocarditis	unknown	amikacin, imipenem, clarithromycin, trimethoprim-sulfamethoxazole, rifampicin, doxycycline	Recovery
5	T. Hod/ Israel/2008[9]			Male/65-year-old	M. fortuitum	peritonitis	diabetic nephropathy	unknown	Cefazolin, cephalixin, gentamycin	Recovery
6	T. Hod/ Israel/2008[9]			Male/59-year-old	M. fortuitum	catheter tunnel abscess	hypertensive nephrosclerosis	unknown	Doxycycline, surgical Treatment	Recovery
7	Miki Nagao/Japan/2008[10]			Female/58-year-old	M. peregrinum	Surgical site infection	lipoma	unknown	Cefazolin, amikacin and imipenem, levofloxacin	Recovery
8	Ian Cheung/Australia/2007[11]			c	M. fortuitum	Wound infection	knee arthroplasty	unknown	Meropenem, moxifloxacin	Recovery
9	Corrado Serra/Italy/2007[12]			Female/32-year-old	M. fortuitum	lumbar pain	ureteral colic and lithiasis	immunocompetent	ofloxacin	Recovery
10	MICHAEL SACCENTE/USA/2005[13]			Female/44-year-old	M. fortuitum	Wound infection	bilateral total knee arthroplasty	unknown	Imipenem, doxycycline, azithromycin, surgical debridement	Recovery

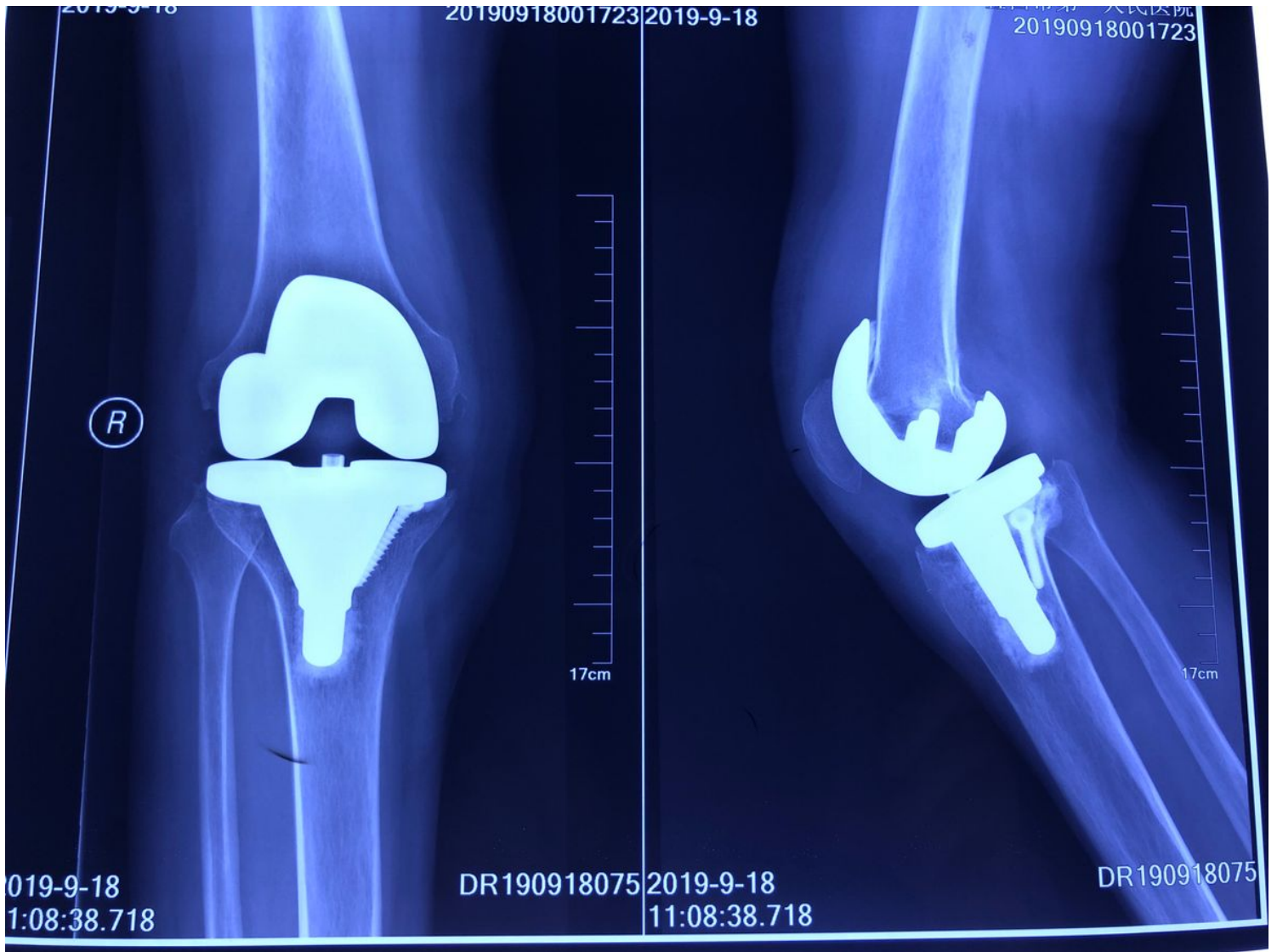
## Figures





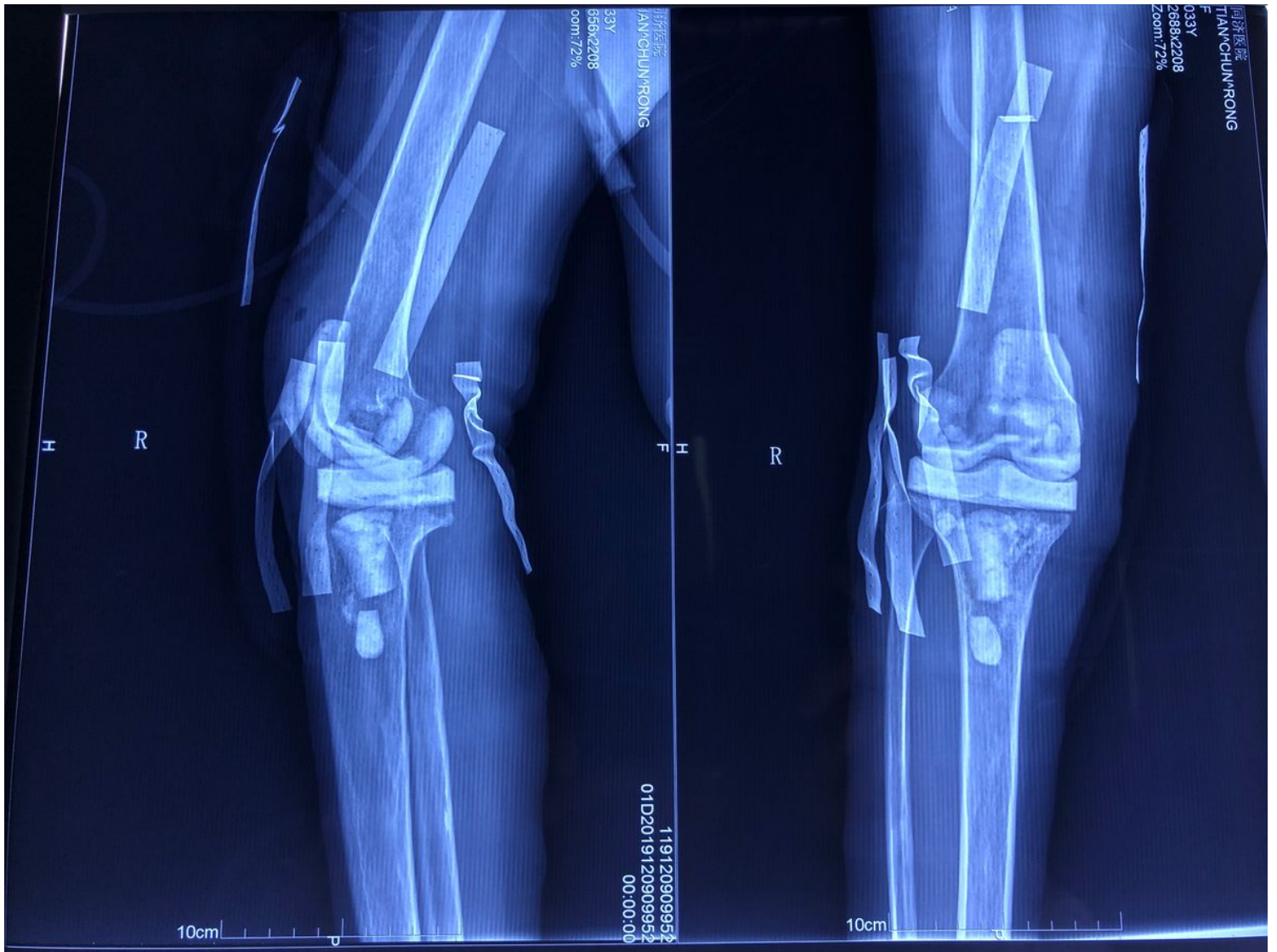
**Figure 1**

Continuous exudation of tawny secretion from the wound after operation



**Figure 2**

Imaging showed swelling of the implanted prosthesis joint and surrounding tissue.

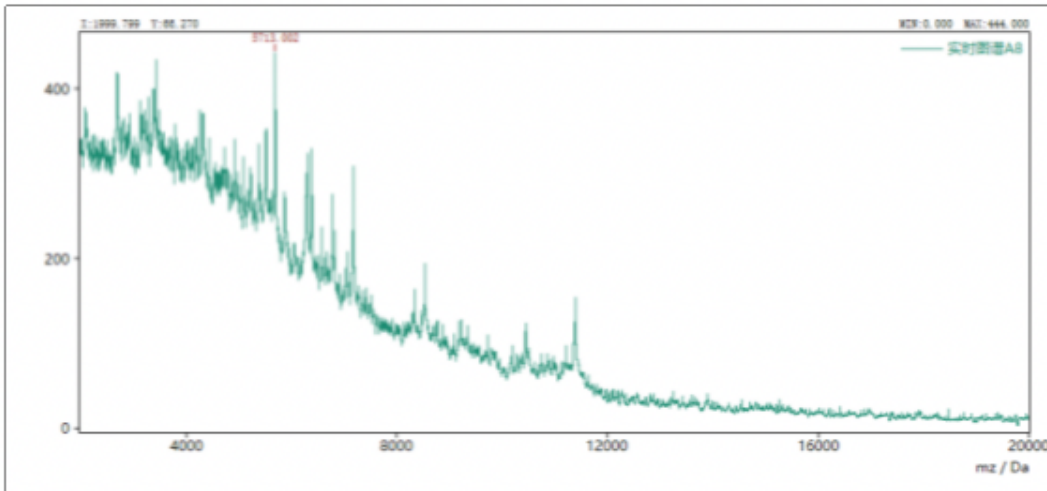


**Figure 3**

Imaging showed that the prosthesis tissue had been removed and implanted into the cement frame for fixation.

鉴定结果: 塞内加尔分枝杆菌 / *Mycobacterium senegalense* 9.146

### 质谱图



### 详细结果

序号	结果	得分
1	塞内加尔分枝杆菌 / <i>Mycobacterium senegalense</i>	9.146
2	塞内加尔分枝杆菌 / <i>Mycobacterium senegalense</i>	9.128
3	偶发分枝杆菌 / <i>Mycobacterium fortuitum</i>	9.044
4	塞内加尔分枝杆菌 / <i>Mycobacterium senegalense</i>	8.865
5	塞内加尔分枝杆菌 / <i>Mycobacterium senegalense</i>	8.810
6	塞内加尔分枝杆菌 / <i>Mycobacterium senegalense</i>	8.617
7	偶发分枝杆菌 / <i>Mycobacterium fortuitum</i>	7.730
8	塞内加尔分枝杆菌 / <i>Mycobacterium senegalense</i>	7.266
9	偶发分枝杆菌 / <i>Mycobacterium fortuitum</i>	7.107

Figure 4

The result of IVD-MALDIBIOTYPER showed that the strain was *Mycobacterium senegalense*.