Research Square

Preprints are preliminary reports that have not undergone peer review.
They should not be considered conclusive, used to inform clinical practice,
or referenced by the media as validated information.

[68Ga]Ga-Prostate-specific membrane antigen PET/CT in ovarian tumours: potential to differentiate benign and malignant tumours before surgery. A preliminary report

Jolanta Kunikowska
Medical University of Warsaw: Warszawski Uniwersytet Medyczny
Magdalena Bizoń (magdalena.bizon@wum.edu.pl)
Medical University of Warsaw: Warszawski Uniwersytet Medyczny https://orcid.org/0000-0001-9513-106X
Kacper Pełka
Medical University of Warsaw: Warszawski Uniwersytet Medyczny
Paweł Derlatka
Medical University of Warsaw: Warszawski Uniwersytet Medyczny
Maciej Olszewski
LUXMED Oncology Hospital, Warsaw
Leszek Królicki
Medical University of Warsaw: Warszawski Uniwersytet Medyczny

Short Report

Keywords: PSMA, ovarian cancer, pelvic tumour, [68Ga]Ga-PSMA PET/CT

Posted Date: August 22nd, 2022

DOI: https://doi.org/10.21203/rs.3.rs-1680227/v2

License: This work is licensed under a Creative Commons Attribution 4.0 International License.
Read Full License

[^{68}Ga]Ga-Prostate-specific membrane antigen PET/CT in ovarian tumours: potential to differentiate benign and malignant tumours before surgery. A preliminary report

Running title: [^{68}Ga]Ga-PSMA-11 PET/CT in ovarian cancer

Jolanta Kunikowska 1), Magdalena Bizoń 2) Kacper Pełka1)3) Paweł Derlatka 4), Maciej Olszewski 5) Leszek Królicki 1)

1. Nuclear Medicine Department, Medical University of Warsaw, Poland

2 Chair and Department of Obstetrics, Gynecology and Gynecological Oncology, Medical University of Warsaw, Poland

3 Department of Methodology, Laboratory of Center for Preclinical Research, Medical University of Warsaw, Warsaw, Poland

4 Second Department Obstetrics and Gynecology, Medical University of Warsaw, Poland

5. LUXMED Oncology Hospital, Warsaw, Poland

Corresponding author:

Magdalena Bizoń

magdalena.bizon@wum.edu.pl; tel. +48 697-722-894

Chair and Department of Obstetrics, Gynecology and Gynecological Oncology, Medical University of Warsaw, Poland

Abstract

Purpose Ovarian cancer is usually diagnosed in an advanced stage of disease due to the absence of specific symptoms and a lack of sensitive diagnostic methods. Prostate-specific membrane antigen (PSMA) is expressed on prostate cancer cells, but can be found in other tumours such as ovarian cancer.

The aim of this pilot study was to evaluate the feasibility of using [^{68}Ga]Ga-PSMA-11 PET/CT in detection of ovarian neoplasm before surgical treatment.

Material and methods: Eight women with mean age of 56.0±16.2 years were included in the study. All patients underwent transvaginal ultrasound followed by CT scan of the chest and abdomen as qualification for surgery. Within a 1-week interval, PET/CT was performed on a Siemens Biograph scanner, 60 min after injection of 2 MBq/kg [^{68}Ga]Ga-PSMA-11.

Results: In three cases (37.5%) the [^{68}Ga]Ga-PSMA-11 PET/CT was positive, whereas histological examination confirmed two serous ovarian cancer cases and one ovarian borderline tumour. The SUVmax in the serous ovarian cancer was 8.7 and 4.1, and in the borderline ovarian tumour it was 13.8. No correlation was found between antigen CA 125 level and [^{68}Ga]Ga-PSMA expression. Range of tumour SUVmax was not correlated with stage of disease. The remaining 62.5% (5/8) were negative in [^{68}Ga]Ga-PSMA-11 PET/CT and histopathology confirmed benign pelvic tumour.

Conclusion The initial experience supports the potential to use [^{68}Ga]Ga-PSMA-11 in ovarian cancer to differentiate malignant and benign tumours before surgery.

This study was approved by the Ethical Committee of the Medical University of Warsaw (KB/2/A/2018).

Keywords: PSMA; ovarian cancer; pelvic tumour; [^{68}Ga]Ga-PSMA PET/CT

Author contributions

Jolanta Kunikowska and Leszek Królicki contributed to the study conception and design. Material preparation and data collection were performed by Jolanta Kunikowska, Magdalena Bizoń and Kacper Pełka. Paweł Derlatka and Maciej Olszewski – clinical data collection and analysis. The first draft of the manuscript was written by Jolanta Kunikowska and Magdalena Bizoń, and all authors commented on previous versions of the manuscript. All authors read and approved the final manuscript

Availability of data and material (data transparency) Raw data are available from the corresponding author on reasonable request.

Code availability (software application or custom code) Calculations were performed on Excel for Windows 10 (version 16.60) and PQStat (version 1.8.4).

Introduction

Ovarian cancer is usually detected in an advanced stage and coexisted with ovarian or pelvic tumour firstly diagnosed by ultrasonography using special algorithms created by the International Ovarian Tumour Analysis (IOTA) group [1]. The sensitivity and specificity of transvaginal ultrasound are 86-94% and 94-96% respectively [2, 3].

According to the European Society of Gynaecological Oncology (ESGO) consensus the aim of the surgical procedure is to completely excise all visible disease. Voluntary use of incomplete surgery (in advance or at an interval) is discouraged [4,5]. In patients disqualified from primary cytoreduction, exploratory laparoscopy is recommenced to establish the diagnosis, followed by neoadjuvant chemotherapy [5].

For pre-surgery staging the ESGO recommends obligatory CT scan of the chest and abdominal cavity [4,5]. Prior knowledge of the stage and grade of disease allows for better assignment to surgical treatment or neoadjuvant chemotherapy. In pre-treatment diagnosis of ovarian cancer, magnetic resonance imaging (MRI) or [^{18}F]FDG PET/CT can yield more information than CT [5,6].

Kitjama et al. and Nam et al. compared CT scan with [^{18}F]FDG PET/CT of ovarian tumours suspected of cancer in preoperative assessment, with higher sensitivity of [^{18}F]FDG PET/CT than CT scan (69.4% vs 37.6%) [7,8].

Prostate-specific membrane antigen (PSMA) is a highly restricted prostate epithelial cell membrane glycoprotein showed strong immunohistochemical reactivity to prostate epithelia of prostate cancer [9]. It is used mainly for prostate cancer, but also overexpressed on other solid tumours, such as ovarian cancer, glioblastoma, primary hepatocellular carcinoma, clear cell renal cancer and pancreatic cancer [10].

Presence of positive PSMA expression in endothelium of tumour vascularization can be useful in diagnosis of ovarian cancer. According to our knowledge, to date there are no

published data about the possibility to use [^{68}Ga]Ga-PSMA-11 PET/CT in ovarian cancer, including pre-surgical differentiation of benign and malignant tumours.

The aim of the study was to perform a preliminary evaluation of the feasibility to use [^{68}Ga]Ga-PSMA-11 PET/CT in pelvic tumour suspected of ovarian cancer.

MATERIALS AND METHODS

This prospective study was conducted from July 2020 to February 2021. Eight women with mean age of 56±16.2 years were included in the study.

The inclusion criteria were:

- age over 18 years;
- tumour with diameter more than 4.5 cm located in the pelvis which was suspected to be an ovarian cancer;
- presence of clinical symptoms suggesting ovarian cancer.

Exclusion criteria were previous history of cancer, previous use of chemotherapy, hormone therapy or radiotherapy, renal dysfunction, contraindications or allergy to PSMA marker.

Diagnostic methods

Antigen CA 125, HE4, CEA and CA19-9 were measured in every case.

Each patient underwent a transvaginal ultrasound examination with IOTA algorithms (GE Voluson S8 RIC5-9D), then a contrast enhanced 64-slice CT (ceCT) scan of the abdomen and CT of the chest as qualification for surgery. The examinations were performed before inclusion in the study. Within a 1-week interval, [^{68}Ga]Ga-PSMA-11 PET/CT was performed.

[^{68}Ga]Ga-PSMA-11 PET/CT protocol and image interpretation

Radiopharmaceutical preparation of [^{68}Ga]Ga-PSMA-11 and the imaging protocol was performed as previously described [22].

In the visual evaluation of lesions, uptake of [^{68}Ga]Ga-PSMA-11 higher than that of the background was considered a positive result.

For quantitative analysis, the maximal standard uptake value (SUVmax) and mean standard uptake value (SUVmean) of a positive lesion were measured on [^{68}Ga]Ga-PSMA-11 PET/CT images with spherical volumes of interest (VOIs).

Histological examination

All patients underwent laparoscopy with intraoperative histopathological examination of the ovarian tumor (including immunohistochemistry marker panel for CK7, CK20, CA 125, CDX2 and Ki 67).

Statistical methods

Means and standard deviations were calculated in Microsoft Excel (version 16.60). Statistical analysis was performed in PQStat (version 1.8.4).

RESULTS

[^{68}Ga]Ga-PSMA-11 PET/CT imaging and ceCT

No adverse events related to the use of the diagnostic radiopharmaceutical were recorded.

Five patients were negative in [^{68}Ga]Ga-PSMA-11 PET/CT (62.5%) and histopathology confirmed the benign nature of the pelvic tumour. However, 4 of them (4/5)

apart from the ovarian mass, had suspected lesions in ceCT. The detailed data are presented in Table 1.

Three cases (37.5%) were positive in [^{68}Ga]Ga-PSMA-11 PET/CT: two cases of high-grade serous ovarian cancer (No. 4 and 6) and one of borderline serous ovarian tumour (No 7). [^{68}Ga]Ga-PSMA-11 PET/CT in patients No. 4 and 6 additionally revealed metastatic lesions in the peritoneal cavity and distant metastases corresponded to those described in contrast-enhanced CT lesions. The semiquantitative asses of primary tumours and targeted metastases are presented in Table 2.

There was a statistically significant correlation of histological result and presence of PSMA expression (p=0.038). Patient-based sensitivity of [^{68}Ga]Ga-PSMA-11 for ovarian malignancy was 100% (95%CI 31-100%) and specificity was 100% (95CI 46.3%-100%).

Examples of [^{68}Ga]Ga-PSMA-11 PET/CT imaging are shown in Figures 1-3.

There was no statistical correlation between [^{68}Ga]Ga-PSMA-11 and tumor markers.

All data of values of tumor markers, ceCT suspected lesions, [^{68}Ga]Ga-PSMA-11 expression and histological result are presented in Table 1.

Clinical impact of [^{68}Ga]Ga-PSMA-11 PET CT

All patients qualified for exploratory laparoscopy.

However, after ceCT and [^{68}Ga]Ga-PSMA-11 PET/CT due to high probability of distant metastases, two of eight patients (patients no. 4 and 6) underwent only diagnostic laparoscopy with biopsy of the suspicious area. Intraoperative histological examination confirmed presence of an ovarian cancer, and the surgical procedure was discontinued. These patients underwent neoadjuvant chemotherapy (3 courses of chemotherapy based on carboplatin and paclitaxel), and then were operated on. One patient is still alive with overall survival (OS) of 18 months, while one patient died with OS of 14 months.

Patient no. 7 underwent laparotomy with intraoperative and final histological examination of borderline ovarian tumor and was operated on conservatively according to the protocol for this type of tumor. During the operation no suspicious area was observed.

In the remaining patients without expression of [^{68}Ga]Ga-PSMA-11 PET/CT, intraoperative examination did not confirm ovarian cancer. The patients underwent tumour removal without further surgical treatment.

DISCUSSION

[^{68}Ga]Ga-PSMA-11 was recently introduced for the PET/CT imaging of patients with prostate cancer, but incidental uptake has been described in other cancers, including ovarian cancer [11, 12].

This pilot study showed encouraging preliminary results confirming the clinical utility of [^{68}Ga]Ga-PSMA-11 PET/CT in patients with pre-surgical differentiation of benign and malignant ovarian tumours. All histopathologically proven cases of ovarian cancer showed increased tracer uptake, corresponding with ceCT. [^{68}Ga]Ga-PSMA-11 expression was also detected in the borderline tumour. In the benign tumours expression of [^{68}Ga]Ga-PSMA-11 PET/CT was negative.

There are only a few studies investigating PSMA expression in immunohistochemical staining in ovarian cancer. Zhang et al. observed no expression of PSMA in the ovary [13].

Wernicke et al., Santoro et al. and Salas-Fragomeni et al. detected PSMA expression on endothelial cells of tumour-associated neovasculature [11, 14, 15]

Wernicke et al. has been noticed PSMA staining associated with histological type. High-grade serous ovarian cancer showed up to 100% staining of capillaries, low-grade serous type was positive in 26-50% and 76-100%, and the same percentages were observed in

clear cell carcinoma [11]. In our study values of SUVmax were different in primary and metastatic lesions of two cases of high-grade ovarian cancer.

On the other hand, in study with only five normal ovaries and one ovarian cancer Kinoshita et al. detected expression of PSMA in ovary stromal cells, but did not detect it in tissue of ovarian cancer [12].

Aide et al. analysed the largest cohort regarding PSMA expression, with 57 histological samples, before and after chemotherapy, and observed no correlation between PSMA expression and chemotherapy response. The results of their study showed that PSMA expression is not useful as a prognostic marker in monitoring treatment of ovarian cancer [16]. Even though our cohort is small, we observed the same tendency with in vivo PSMA expression: two patients with disseminated disease in [^{68}Ga]Ga-PSMA-11 PET/CT showed different survival parameters after neoadjuvant chemotherapy.

As we mentioned, to our knowledge there are no published data about the possibility to use [^{68}Ga]Ga-PSMA-11 PET/CT in ovarian cancer. However, there are several ongoing clinical trials which assess the role of [^{68}Ga]Ga-PSMA-11 PET/CT in diagnosing ovarian cancer patients: NCT03857087, NCT03811899, NCT03302156 and NCT04147494.

In our study there was no influence of tumor markers level on expression of PSMA.

The current pilot study has some major limitations. First of all, relatively small number of cases limits the power of the analysis.

Overall, we observed increased uptake of [^{68}Ga]Ga-PSMA-11 in all patients with histopathologically proven ovarian carcinoma, and no uptake in cases of benign ovarian tumours, even tumour markers and/or ceCT suspected malignancy. So it seems that [^{68}Ga]Ga-PSMA-11 could be used preoperatively to assess the character of tumours. However, these promising results need further evaluation to confirm the observed dependency.

The knowledge about the possibility to use [^{68}Ga]Ga-PSMA-11 in ovarian cancer will open the way not only for differentiation of primary tumours, but also for its use in suspicion of disease recurrence. As the therapeutic agent [^{177}Lu]Lu-PSMA has just been registered for prostate cancer patients, it raises the question of its future use in metastatic ovarian cancer.

Conclusion

The initial experience supports the potential to use [^{68}Ga]Ga-PSMA-11 in ovarian cancer, to differentiate malignant and benign tumours before surgery, with specificity higher in comparison to routine ones and deserve further investigation.

Figure legends

Fig. 1

PET/CT scan with [^{68}Ga]Ga-PSMA-11 a 40-year-old woman (Patient 7)

A – MIP (maximum intensity projection) – arrow indicates the lesion with abnormal tracer accumulation. B – CT arrow indicates the lesion in the right ovary. C – Fusion PET/CT– arrow indicates the high tracer accumulation in the right ovary lesion visible on CT with SUVmax 13.8.

Final histopathology revealed borderline ovarian tumour.

Fig. 2

PET/CT scan with [^{68}Ga]Ga-PSMA-11 in a 72-year-old woman (Patient 4)

A – MIP (maximum intensity projection) – arrows indicate the lesions with abnormal tracer accumulation – corresponding images, lower arrows – in pelvis, upper arrows – in thorax. B – CT left arrow indicates the lesion in the left adnexa area, with the corresponding metastases in

the right area of the pelvis (right arrow). C – Fusion PET/CT– arrows indicate the high tracer accumulation in the lesions visible on CT – left adnexa area (SUVmax 8.7) and metastases in the right area of the pelvis (SUVmax 7.8) . D – arrows indicate the distant metastases in the thorax E – Fusion PET/CT– arrows indicate the high tracer accumulation in the distant metastases with SUVmax 3.9 and SUVmax 4.6.

Final histopathology revealed high-grade serous ovarian cancer.

Fig. 3

PET/CT scan with [^{68}Ga]Ga-PSMA-11 in a 79-year-old woman (Patient 5)

A – MIP (maximum intensity projection) – only physiological traces accumulation is visible

B – CT arrow indicates the lesion in the left ovary. C – Fusion PET/CT– arrow indicates the lesion visible in the CT scan, which has no tracer accumulation in the PET scan.

Final histopathology revealed pedunculated uterine fibroid.

Compliance with Ethical Standards:

Funding none

Conflicts of interest/Competing interests

There is no conflict of interests regarding the present work.

Outside the submitted work: JK reports an unrestricted grant from Janssen, consulting fees from Telix and Novartis, LK consulting fees from Bayer.

Ethics approval: This study was approved by the Ethical Committee of the Medical University of Warsaw (KB/2/A/2018).

All authors declare that he/she has no conflict of interest according to this article.

This article does not contain any studies with animals performed by any of the authors.

All procedures performed in studies involving human participants were in accordance with the ethical standards of the institutional and/or national research committee and with the 1964 Helsinki declaration and its later amendments or comparable ethical standards.

Informed consent was obtained from all individual participants included in the study.

Consent to participate Written informed consent was obtained from all patients.

Consent for publication All authors gave their written consent for publication.

Acknowledgements:

We thank the patients who participated in the study, the Radiochemistry Group in the Department of Nuclear Medicine, the nursing staff, and the nuclear medicine technologists of the Medical University of Warsaw for their support.

References

1. Kaijser J, Bourne T, Valentin L, Sayasneh A, Van Holsbeke C, Vergote I, et al. Improving strategies for diagnosing ovarian cancer: a summary of the International Ovarian Tumor Analysis (IOTA) studies, Ultrasound Obstet. Gynecol.2013;41:9–20. https://doi.org/10.1002/uog.12323

2. Ameye L, Timmerman D, Valentin L, Paladini D, Zhang J, Van Holsbeke C, et al. Clinically oriented three-step strategy for assessment of adnexal pathology. Ultrasound Obstet Gynecol. 2012;40:582-591. https://doi.org/10.1002/uog.11177

3. Timmerman D, Ameye L, Fischerova D, Epstein E, Melis GB, Guerriero S, et al. Simple ultrasound rules to distinguish between benign and malignant adnexal masses before surgery: prospective validation by IOTA group. BMJ. 2010;14;341:c6839. https://doi.org/10.1136/bmj.c6839.

4. Querleu D, Planchamp F, Chiva L, Fotopoulou C, Barton D, Cibula D, et al. European Society of Gynaecological Oncology (ESGO) Guidelines for Ovarian Cancer Surgery. Int J Gynecol Cancer 2017;27:1534-1542. https://doi.org/10.1097/igc.0000000000001041

5. Timmerman D, Planchamp F, Bourne T, Landolfo C, duBois A, Chiva L, et al ESGO/ISUOG/IOTA/ESGE Consensus Statement on pre-operative diagnosis of ovarian tumors. Int J Gynecol Cancer 2021;31:961-982. https://doi.org/10.1136/ijgc-2021-002565

6. Elsherif SB, Bhosale PR, Lall C, Menias CO, Itani M, Butler KA, Ganeshan D. Current update on malignant epithelial ovarian tumors. Abdom Radiol 2021;46:2264–2280. https://doi.org/10.1007/s00261-021-03081-0

7. Nam EJ, Yun MJ, Oh YT, Kim JW, Kim JH, Kim S, et al. Diagnosis and staging of primary ovarian cancer: correlation between PET/CT, Doppler US, and CT or MRI. Gynecol Oncol. 2010: 116:389-394. https://doi.org/10.1016/j.ygyno.2009.10.059

8. Kitajima K, Murakami K, Yamasaki E, Kaji Y, Fukasawa I, Inaba N, Sugimura K. Diagnostic accurracy of integrated FDG-PET/contrast-enhanced CT in staging ovarian cancer: comparison with enhanced CT. Eur. J. Nucl. Med. Mol. Imaging 2008:35:1912-1920. https://doi.org/10.1007/s00259-008-0890-2

9.Liu H, Moy P, Kim S, Xia Y, Rajasekaran A, Navarro V, et al. Monoclonal antibodies to the extracellular domain of Prostate-specific Membrane Antigen also react with tumor vascular endothelium. Cancer Research 1997;57:3629-3634.

10. Kunikowska J, Cieślak B, Gierej B, Patkowski W, Kraj L, Kotulski M, et al. [68Ga]Ga-Prostate-Specific Membrane Antigen PET/CT: a novel method for imaging patients with hepatocellular carcinoma. Eur J Nucl Med Mol Imaging. 2021;48:883-892. https://doi.org/10.1007/s00259-020-05017-0

11. Wernicke AG, Kim S, Liu H, Bander NH, Pirog EC. Prostate-specific Membrane Antigen (PSMA) Expression in the Neovasculature of Gynecologic Malignancies: Implications for PSMA-targeted Therapy. Appl Immunohistochem Mol Morphol. 2017; 25:271-276. https://doi.org/10.1097/pai.0000000000000297

12. Kinoshita Y, Kuratsukuri K, Landas S, Imaida K, Rovito PM, Wang CY, Haas GP. Expression of Prostate-Specific Membrane Antigen in normal and malignant human tissues. World J Surg. 2006;30:628-636. https://doi.org/10.1007/s00268-005-0544-5

13. Zhang S, Zhang H, Cordon-Cardo C, Ragupathi G, Livingston P. Selection of tumor antigens as targets for immune attack using immunohistochemistry: protein antigens. Clin Cancer Res. 1998;4:2669-2676.

14. Santoro SP, Kim S, Motz GT, Alatzoglou D, Li C, Irving M, et al. T cells bearing a chimeric antigen receptor against prostate-specific membrane antigen mediate vascular disruption and result in tumor regression. Cancer Immunol Res. 2015;3:68-84. https://doi.org/10.1158/2326-6066.cir-14-0192

15. Salas Fragomeni RA, Amir T, Sheikhbahaei S, Harvey S, Javadi MS, Solnes LB, et al. Imaging of nonprostate cancer using PSMA-targeted radiotracers: rationale, current state of the field, and a call to arms. J Nucl Med 2018;59:871-877. https://doi.org/10.2967/jnumed.117.203570

16.Aide N, Poulain L, Elie N, Briand M, Giffard F, Blanc-Fournier C, et al. A PSMA-targeted theranostic approach is unlikely to be efficient in serous ovarian cancers. EJNMMI Res. 2021;11:11. https://doi.org/10.1186/s13550-021-00756-z

Figures

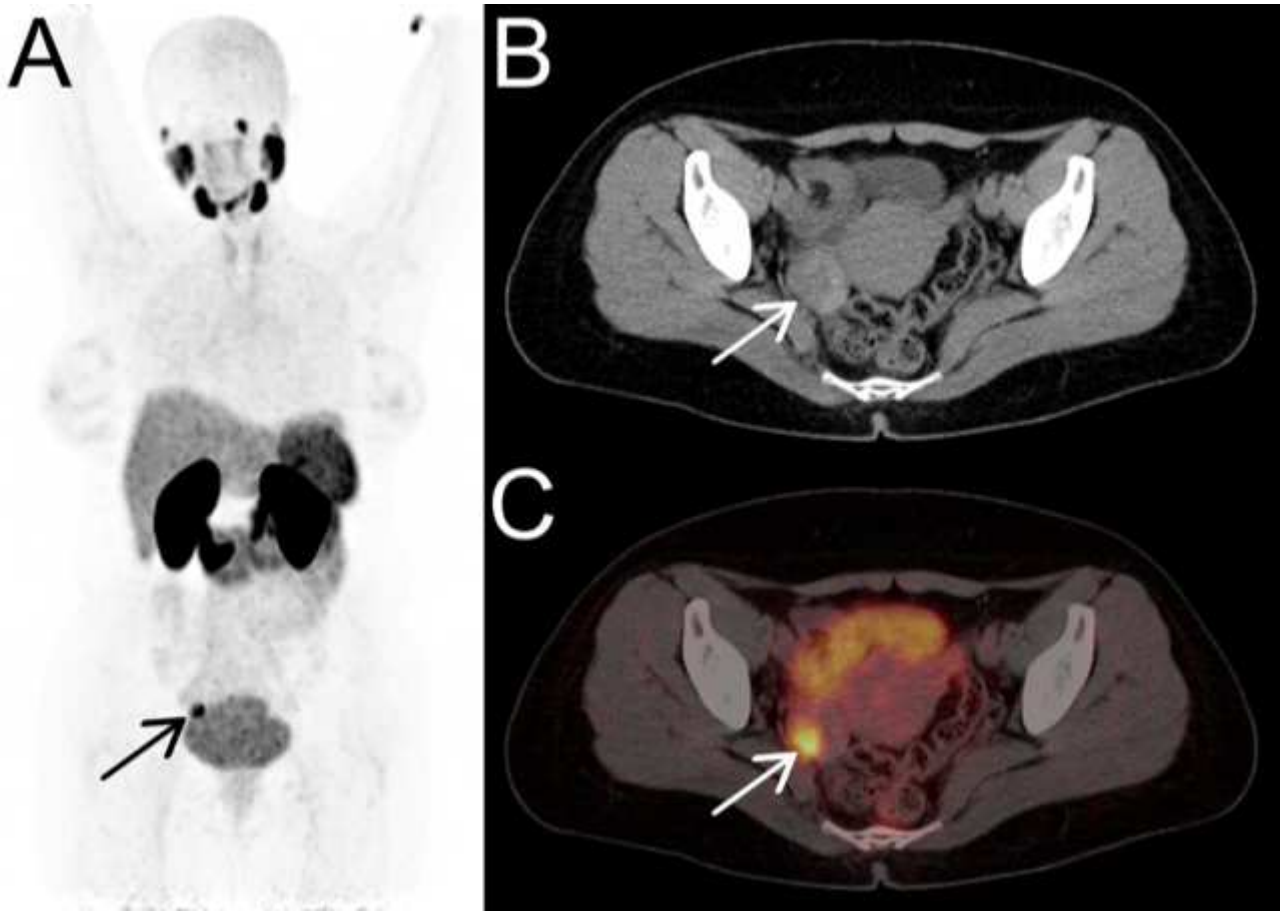

Figure 1

PET/CT scan with [68Ga]Ga-PSMA-11 a 40-year-old woman (Patient 7)

A – MIP (maximum intensity projection) – arrow indicates the lesion with abnormal tracer accumulation. B – CT arrow indicates the lesion in the right ovary. C – Fusion PET/CT– arrow indicates the high tracer accumulation in the right ovary lesion visible on CT with SUVmax 13.8.

Final histopathology revealed borderline ovarian tumour.

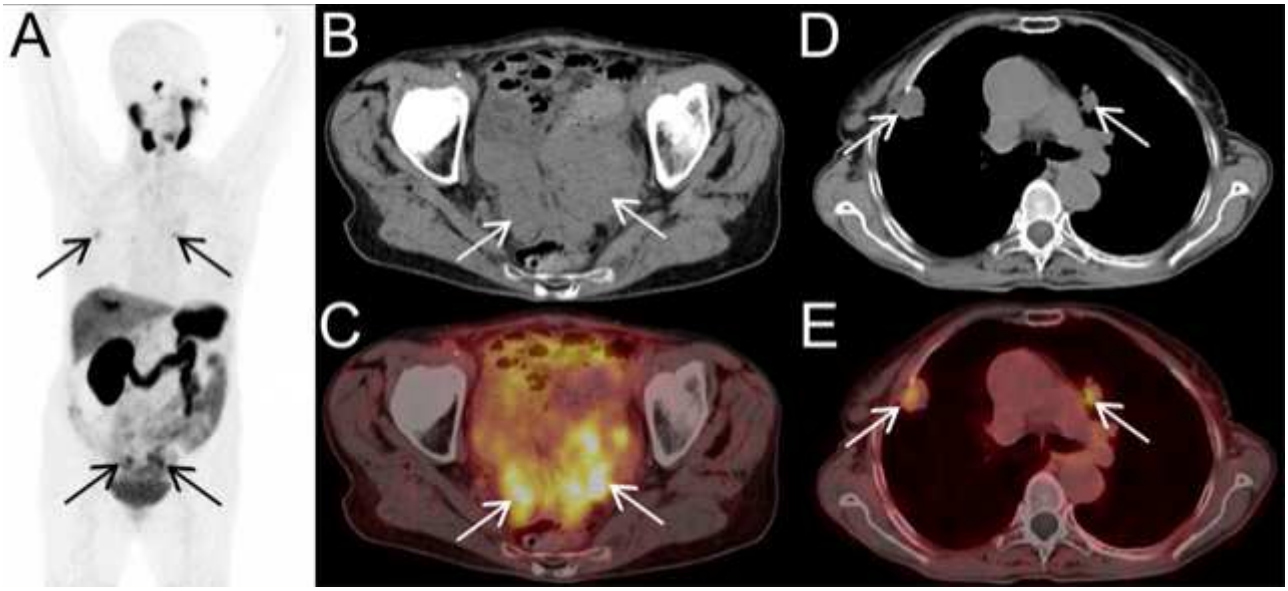

Figure 2

PET/CT scan with [68Ga]Ga-PSMA-11 in a 72-year-old woman (Patient 4)

A – MIP (maximum intensity projection) – arrows indicate the lesions with abnormal tracer accumulation – corresponding images, lower arrows – in pelvis, upper arrows – in thorax. B – CT left arrow indicates the lesion in the left adnexa area, with the corresponding metastases in

the right area of the pelvis (right arrow). C – Fusion PET/CT– arrows indicate the high tracer accumulation in the lesions visible on CT – left adnexa area (SUVmax 8.7) and metastases in the right area of the pelvis (SUVmax 7.8) . D – arrows indicate the distant metastases in the thorax E – Fusion PET/CT– arrows indicate the high tracer accumulation in the distant metastases with SUVmax 3.9 and SUVmax 4.6.

Final histopathology revealed high-grade serous ovarian cancer.

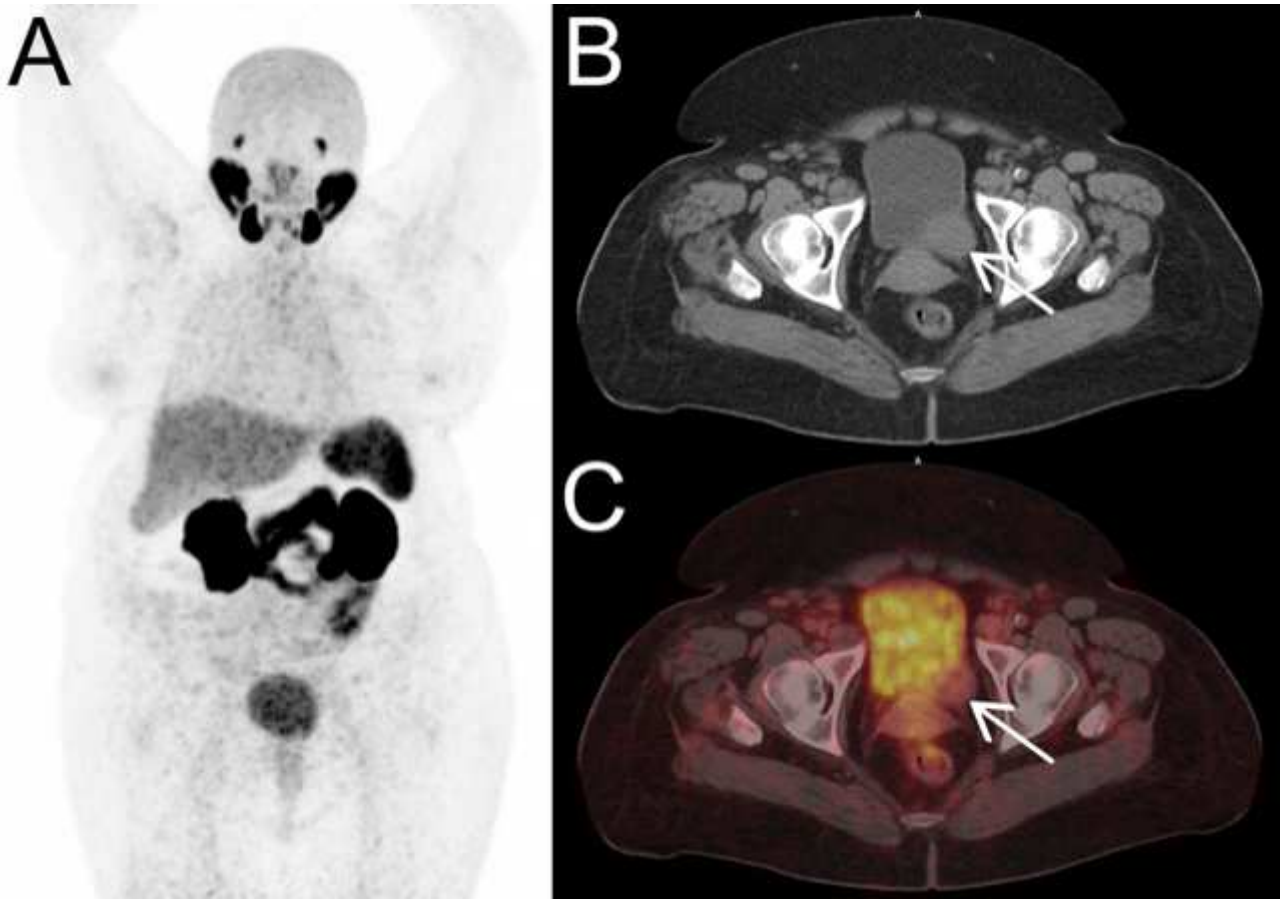

Figure 3

PET/CT scan with [68Ga]Ga-PSMA-11 in a 79-year-old woman (Patient 5)

A – MIP (maximum intensity projection) – only physiological traces accumulation is visible B – CT arrow indicates the lesion in the left ovary. C – Fusion PET/CT– arrow indicates the lesion visible in the CT scan, which has no tracer accumulation in the PET scan.

Final histopathology revealed pedunculated uterine fibroid.

Supplementary Files

This is a list of supplementary files associated with this preprint. Click to download.

- Table1.pdf
- Table2.pdf