

# Preserving left colic artery in anterior resection reduce the incidence of anastomotic leakage in rectal cancer patients: A prospective cohort study

**Huichao Zheng**

Daping Hospital, Army Medical University

**Jingwang Ye**

Daping Hospital, Army Medical University

**Yue Tian**

Daping Hospital, Army Medical University

**Yong Zhang**

Daping Hospital, Army Medical University

**Haode Shen**

Daping Hospital, Army Medical University

**Fan Li**

Daping Hospital, Army Medical University

**Baohua Liu**

Daping Hospital, Army Medical University

**Wei-Dong Tong** (✉ [vdtong@163.com](mailto:vdtong@163.com))

Daping hospital, Third Military Medical University <https://orcid.org/0000-0001-6150-9941>

---

## Research

**Keywords:** Rectal cancer, Left colic artery, Anterior resection, Inferior mesenteric artery, Anastomotic leakage.

**Posted Date:** March 5th, 2020

**DOI:** <https://doi.org/10.21203/rs.3.rs-16171/v1>

**License:** © ⓘ This work is licensed under a Creative Commons Attribution 4.0 International License.

[Read Full License](#)

---

# Abstract

**Background** Whether or not to preserving left colic artery(LCA) in anterior resection for rectal cancer and its effect on anastomotic leakage are remains controversial. The aim of this study was to investigate the clinical outcomes of preserving the LCA during anterior resection for rectal cancer. We further explored branching types of the inferior mesenteric artery(IMA) based on the three-dimensional computed tomography reconstruction images. **Methods** Between January 2017 and October 2019, patients who underwent anterior resection for rectal cancer were allocated to preservation LCA or non-preservation LCA. Evaluation parameters including intraoperative conditions, pathological outcomes, postoperative complications, and short-term results. Furthermore, preoperative three-dimensional computer tomography reconstruction were performed to assess types of IMA. **Results** 160 patients with rectal cancer were enrolled in this study, 56 were arranged to preservation LCA and 104 to non-preservation LCA. The incidence of anastomotic leakage and overall early complications were significantly( $P<0.05$ ) decreased in the preservation LCA group. The reoperation rate of the preservation LCA group (1.8%) was lower than that of the non-preservation LCA group (10.6%), but the difference was not statistically significant ( $P>0.05$ ). The two groups did not significantly( $P>0.05$ ) differ in blood loss, intraoperative complications, total number of harvested lymph nodes, and number of positive lymph nodes. The three-dimensional computer tomography reconstruction images of 108 patients with rectal cancer were evaluated, the IMA was divided into four types, of which 53(49.1%) were type I, 24 (22.2%) were type II, 18 (16.7%) were type III, and 13 (12%) were type IV. **Conclusions** The preservation of LCA in anterior resection for rectal cancer could help reducing the incidence of anastomotic leakage, overall early complications and without increasing other known risks. The three-dimensional computer tomography reconstruction technique was useful for evaluating the IMA types to facilitate make intraoperative surgical decisions and preservation of LCA during rectal cancer surgery.

## Introduction

Anterior resection with total mesorectal excision (TME) is performed most commonly for rectal cancer. With the improvement of stapler and anastomosis technology, the proportion of the surgical methods increases year by year. But unfortunately, compared with these advance, the incidence of anastomotic leakage after anterior resection for rectal cancer did not decrease[1]. Anastomotic leakage is a common and serious postoperative complication in patients with rectal cancer, severe cases require reoperation. Moreover, anastomotic leakage was associated with high local recurrence and poor survival[2]. Previous studies have shown that anastomotic leakage is related to gender, anastomotic blood supply, anastomotic tension, distance of the tumor from the anal verge, and neoadjuvant therapy[3–5]. Good blood supply of anastomosis is the key factor to ensure the normal healing of anastomosis after anterior resection[3].

The inferior mesenteric artery (IMA) needs to be exposed and ligated during rectal cancer surgery. There are two ways for ligation of the IMA: 1)high ligation, the IMA was ligated at 1 cm from its origin, with non-preservation left colic artery (LCA), and 2)low ligation, the IMA was ligated at below the origin of LCA, with

preservation LCA. The controversy regarding the level of IMA ligation has persisted.[6] It has been suggested that the incidence of anastomotic leakage after rectal cancer surgery is related to the level of ligation of the IMA[7]. Several studies[8–11] have conflicting reports on the impact of LCA preservation on anastomotic leakage in anterior resection for rectal cancer. The use of the high ligation may provide a greater number of lymph nodes(LNs) available for histopathological examination. This, in turn, could increase the accuracy of tumor staging, allowing more accurate prognosis predictions[12]. However, there is no strong evidence to suggest that high ligation of IMA can improve survival and the number of harvested LNs[13]. Sorelius et al reported that high ligation of IMA disrupted LCA blood supply, resulting in decreased mesenteric blood supply and increased risk of colonic necrosis after rectal cancer surgery[14]. It has been suggested that atherosclerotic risk assessment and IMA length were useful predictors of the mesenteric hypoperfusion status following IMA ligation during laparoscopic rectosigmoid colon surgery[15]. In other words, mesenteric hypoperfusion is more likely to occur in patients with short IMA length or high risk of atherosclerosis after IMA ligation during laparoscopic rectosigmoid surgery. Generally, high ligation of IMA during anterior resection for rectal cancer may reduce the blood supply to the proximal anastomosis, which is not conducive to anastomotic healing.

In recent years, preservation of the LCA during radical resection of rectal cancer has attracted increasing attention[11, 16]. Low ligation with apical LNs dissection in rectal cancer treatment provides better anastomotic blood supply but is not associated with differences in LNs retrieval rate and operation time[17]. Previous studies have suggested that colonic blood flow at the proximal site of the anastomosis was significantly decreased by either IMA or LCA clamping, the aging and male gender were the predictive factors of high blood flow reduction upon IMA clamping[18]. The elderly people make up the majority of rectal cancer patients who may also have atherosclerosis, so relying solely on the marginal artery may lead to insufficient blood supply at the proximal site of the anastomosis. Therefore, we believe that preserving the LCA can increase blood supply to promote normal healing of the anastomotic stoma, which may be of great significance in reducing anastomotic leakage after anterior resection for rectal cancer. Previous studies on whether to preserve the LCA in rectal cancer surgery are mostly retrospective controlled studies, and whether or not to preserve the LCA in anterior resection for rectal cancer and its effect on anastomotic leakage remains controversial. Therefore, the aim of this study was to investigate the clinical outcomes of preserving the LCA during anterior resection for rectal cancer. We further explored branching types of the IMA based on the three-dimensional computed tomography(CT) reconstruction images.

## Method

### Patient selection

This study was a prospective clinical trial conducted at a single institute, Army Medical University DaPing hospital (China). Between January 2017 and October 2019, rectal cancer patients were recruited to compare clinical outcomes of preservation or non-preservation of the LCA during rectal cancer surgery.

Whether the LCA is preserved during rectal cancer surgery depends on the surgeon's experience and habits.

Inclusion criteria: 1) The rectal cancer was less than 15 cm away from the anal verge, and the rectal adenocarcinoma was confirmed by biopsy; 2) preoperative evaluation of the patient's systemic conditions can tolerate surgery; 3) the primary tumor can be completely resected; 4) the surgical method was laparoscopic or Da Vinci robot-assisted anterior resection for rectal cancer. Exclusion criteria: 1) Miles, Hartmann, open surgery, emergency surgery, palliative resection; 2) previous history of colorectal surgery; 3) acute bowel obstruction or perforation due to rectal cancer; 4) recurrent rectal cancer or multiple primary colorectal cancer; 4) patients can't tolerate surgery. CONSORT flow diagram for the trial show in Fig. 1. According to National Comprehensive Cancer Network guidelines, preoperative neoadjuvant therapy is recommended for patients with T3 or LNs positive determined by magnetic resonance imaging(MRI). The interval between the end of neoadjuvant therapy and surgery was 6–8 weeks.

## Date collection

Primary endpoint was the incidence of anastomotic leakage. According to the definition proposed by the International Study Group of Rectal Cancer (ISREC) in 2010[19], Grade A: Anastomotic leakage presents had no clinical symptom or abnormal laboratory tests, and do not require active therapeutic intervention. Grade B: Anastomotic leakage patients have obvious clinical symptoms and require non-surgical therapeutic intervention. Grade C: Anastomotic leakage patients are often quite ill and require operative re-laparotomy. The total number of harvested LNs, the number of positive LNs, operative time, blood loss, indwelling catheter dwell time, peritoneal drainage tube dwell time, intraoperative complications, postoperative early complication, postoperative hospital stay were recorded in the two groups. Pathological results were based on the TNM staging system for colorectal cancer of the American joint committee on cancer (AJCC) and the Union International Against Cancer(UICC) (2017, edition 8).

## Surgical Technique

Each patient was placed in the lithotomy position and general anesthesia was implemented, following conventional laparoscopic, transanal total mesorectal excision (TaTME) or robotic-assisted anterior resection for rectal cancer was performed. Further detail of the procedures are described in previous reports[9, 20, 21]. For LCA preservation group, the IMA, LCA, sigmoid Artery (SA) and superior rectal artery(SRA)were identified, and then the LCA preserved simultaneously with ligations of the SA, SRA and inferior mesenteric vein(IMV). Then, lymphadenectomy around the IMA was performed. For LCA non-preservation group, the IMA was ligated at 1 cm from its origin with lymphadenectomy around the IMA simultaneously with the IMV was ligated at the same level. Preservation or non-preservation of the LCA in anterior resection for rectal cancer show in Fig. 2. According to the results of colonoscopy or magnetic resonance imaging, the location of rectal cancer was defined as upper(10.1-15cm), middle(5.1-10cm) and lower (below 5 cm). Patients with middle and low rectal cancer received TME, while upper rectal cancer patients underwent tumor-specific mesorectal excision. The specimen was removed through a small

abdominal incision of about 5 cm. Reconstruction was performed by either end-to-end double stapling technique or manual anastomosis. After the reconstruction, pelvic cavity was washed with normal saline and air leakage test was performed. The patient's medical history and intraoperative conditions were taken into consideration to determine whether protective ileostomy was performed. Finally, the abdominal drainage tube was placed in the pelvic cavity and fixed through the abdominal wall.

## **Three-dimensional CT reconstruction protocol**

The clinical data and imaging data of the patients who underwent three-dimensional CT reconstruction from January 2017 to November 2018 were retrospectively analyzed. Specific parameters and procedures of 64-slice abdominal CT and vascular reconstruction are as follows: The scanning parameters were adjusted (voltage was 120 kV, current was 400 mAs, layer thickness was 0.625 mm, layer spacing was 0.625 mm, detector collimation was 0.625 mm × 64 mm). All patients fasted for 8 hour before examination. The scanning area was from the top of the diaphragm to the level of the ischial tuberosity. After routine plain scanning, iopamidol was injected into the cubital vein at a concentration of 350 mg(I)/mL, injection volume (mL) = 400 × weight (kg) /350, injection speed (mL/s) = injection volume (mL) /20, and then enhanced scanning was performed. The delay time of arterial scan was 20 ~ 30 s. The resulting data is uploaded to the image processing platform (General Electric aw4.5, Boston, USA), where vascular three-dimensional CT reconstruction is performed.

## **Statistical Analysis**

Statistical analysis was performed with IBM, SPSS Statistics, Version 21.0.0, SPSS Inc. (New York, USA). Continuous variables with normal distribution are presented as mean ± standard deviation, and comparison between groups was analyzed by the Student's t test. Continuous variables with skewed distribution are described as median and ranges, and comparison between groups was analyzed by Mann–Whitney U test. Categorical variables were defined as absolute numbers of cases and percentages. Chi square test was used to compare categorical variables, and Mann–Whitney U test was used to evaluate the significance of differences in rank variable. P values are derived from two-tailed tests, and P < 0.05 was considered statistically significant.

## **Results**

Between January 2017 and October 2019, a total of 160 patients were enrolled in this study; 56 patients were arranged to the preservation LCA and 104 to non-preservation LCA. There were no differences in age, sex, body mass index(BMI), tumor location, American Society of Anesthesiologists (ASA) classification, and neoadjuvant therapy between the two groups. Patients and tumor characteristics are shown in Table 1.

Table 1  
Patients and tumor characteristics

Characteristics	LCA preservation (n = 56)	LCA non-preservation (n = 104)	P value
Age, y	60.1 ± 11.3	60 ± 10.5	0.938
Sex	30 (53.6)	57 (54.8)	0.881
Male	26 (46.4)	47 (45.2)	
Female			
ASA classification			0.316
I	25(44.6)	59(56.7)	
II	24(42.9)	33(31.7)	
III	7(12.5)	12(11.6)	
BMI	23 ± 3.3	23 ± 2.5	0.923
Tumor location			0.145
Lower	9(16.1)	17(16.3)	
Middle	41(73.2)	63(60.6)	
Upper	6(10.7)	24(23.1)	
Pathological stage			0.248
Stage 0	4(7.1)	3(2.9)	
Stage 1	16(28.6)	20(19.2)	
Stage 2	16(28.6)	35(33.7)	
Stage 3	13(23.2)	42(40.4)	
Stage 4	7(12.5)	4(3.8)	
Tumor differentiation			1.000
Low	3(5.35)	4(3.85)	
Middle	50(89.3)	96(92.3)	
High	3(5.35)	4(3.85)	
Preoperative CRT	11(19.6)	20(19.2)	0.950
LCA, left colic artery; ASA, American society of anesthesiologists; BMI, body mass index; CRT, chemoradiation therapy			

Among the 160 patients underwent laparoscopic or robotic surgery, no ureteral injury, intestinal perforation, bladder injury, urethral injury or other complications occurred during the surgery. No significant differences were found in surgical approach, type of surgery, ileostomy rate, blood loss, total number of harvested LNs, and number of positive LNs between the two groups. The operation time was longer in the LCA preservation group than in the non-preservation LCA group (P = 0.002). Surgical parameters are listed in Table 2.

Table 2  
Surgical parameters

Characteristics	LCA preservation (n = 56)	LCA non-preservation (n = 104)	P value
Surgical approach			0.105
Laparoscope/Robot	37/19	81/23	
TaTME			0.268
YES/NO	10/46	12/92	
Ileostomy			0.446
YES/NO	31/25	51/53	
Operation time, min	194.1 ± 62.2	161.9 ± 59.4	0.002*
Estimated blood loss, ml	78 ± 70.4	63.7 ± 70	0.219
Number of harvested LNs	12.5(2–33)	12(0–23)	0.705
Number of Positive LNs	0(0–10)	0(0–18)	0.100
LCA, left colic Artery; TaTME, transanal total mesorectal excision; LNs, lymph nodes; * Statistical significance			

Table 3 summarizes the postoperative short-term outcomes. There were no significant difference in ileus, anastomotic bleeding, urinary tract infection, urinary dysfunction, postoperative hospital stay, and postoperative diarrhea between the two groups. The reoperation rate of the preservation LCA group (1.8%) was lower than that of the non-preservation LCA group (10.6%), but the difference was not statistically significant (P > 0.05). However, the overall early complications and in the preservation LCA group were significantly (P < 0.05) lower than in the non-preservation LCA group. Anastomotic leakage occurred in 16 of the 160 (10%) patients who underwent anterior resection for rectal cancer. Two cases of anastomotic leakage were diagnosed in the LCA preservation group (2 of 56, 3.6%), while 14 cases of anastomotic leakage were diagnosed in the non-preservation LCA group (14 of 104, 13.5%) (P = 0.047). The two cases of anastomotic leakage in the preservation LCA group including 1 case of grade B leakage and 1 case of grade C leakage. The 14 cases of anastomotic leakage in the non-preservation LCA group, there are 4 cases of grade B leakage and 10 cases of grade C leakage. All patients with grade C leakage received

reoperation with abdominal washing combined with ileostomy, while patients with grade B leakage received non-surgical therapeutic intervention (e.g. anti-infection).

Table 3  
Short-term outcomes

Characteristics	LCA preservation (n = 56)	LCA non-preservation (n = 104)	P value
Overall early complications	5(8.9)	28(26.9)	0.007*
Anastomotic leakage	2(3.6)	14(13.5)	0.047*
Ileus	1(1.8)	4(3.8)	0.812
Surgical site infection	0(0)	1(1)	1.000
Anastomotic bleeding	0(0)	2(1.9)	0.765
Urinary tract infection	1(1.8)	1(1)	1.000
Urinary dysfunction	0(0)	3(2.9)	0.502
Postoperative diarrhea	2(3.6)	6(5.8)	0.820
Reoperation	1(1.8)	11(10.6)	0.089
Postoperative hospital stay, day	8(5–28)	8(4–56)	0.120
Indwelling catheter dwell time, day	5.1 ± 1.7	6.2 ± 3.8	0.059
Peritoneal drainage tube dwell time, day	6 (4–21)	7 (2–25)	0.241
LCA, left colic artery; *Statistical significance			

The clinical and imaging data of 108 rectal cancer patients who received abdominal enhanced CT before operation were retrospectively analyzed. Bifurcations of the IMA were divided into four patterns based on the definition reported by Murono, K[22]: 1) In type I, the LCA first branched from the IMA trunk, regardless of the sigmoid artery; 2) In type II, the LCA and SA branched from the common branch of the IMA trunk; 3) In type III, the LCA, SA and SRA (superior rectal artery) branched from the same point of the IMA; 4) In type IV, there was a deficit of the LCA. According to the three-dimensional CT reconstruction image, the IMA of 108 patients was divided into four types, of which 53(49.1%) were type I, 24 (22.2%) were type II, 18 (16.7%) were type III, and 13 (12%) were type IV. The diagram of the IMA type show in Fig. 3. The three-dimensional CT reconstruction image of IMA type show in Fig. 4.

## Discussion



Anastomotic leakage is a common and serious postoperative complication in patients with rectal cancer, with an incidence of 5–20%[23–25], and the mortality rate after anastomotic leakage can be as high as 16%.[26–28] Anastomotic leakage not only affects the postoperative recovery of patients, the medical costs, but also increases the local recurrence and decreases the overall survival rate[2]. Once the anastomotic leakage occurs, both the patient and the doctor will pay a huge price in the process of treatment. Therefore, surgeons are doing what they can do to prevent anastomotic leakage after rectal cancer surgery.

Many risk factors have been revealed for anastomotic leakage after rectal cancer surgery including male, obese, malnutrition, preoperative chemoradiotherapy, and diabetes, etc. However, the insufficient blood perfusion and technical factors are still considered to be the key factors in the development of anastomotic leakage [29, 30]. Blood supply at the proximal end of the anastomosis after high ligation of IMA is only from the marginal artery, which may lead to insufficient anastomotic perfusion, especially in elderly patients and atherosclerosis patients. Dworkin et al. and Seike et al. concluded that high ligation of IMA interrupted the blood supply of LCA, and the blood supply to the proximal colon of the anastomosis was only dependent on the marginal artery, thus significantly reduces blood flow to the proximal colon of anastomosis[18, 31]. If the LCA is preserved during anterior resection for rectal cancer, the blood supply of the anastomosis is derived from the dual supply of the marginal artery and the LCA, thus may contributing to increased blood perfusion of anastomosis and reducing the incidence of anastomotic leakage.

Yang, X et al.[10] suggested that preservation of LCA resulted in a significantly decreased incidence of anastomotic leakage. Our study revealed that the incidence of anastomotic leakage was significantly lower in the LCA preservation group than in that of the non-preservation of the LCA group, which was consistent with the previous studies[32]. In contrast, Fujii S et al.[8] found that the level of IMA ligation does not significantly influence the incidence of anastomotic leakage. The total number of harvested LNs and the number of positive LNs show no differences between the two groups, which was similar to the results of previous study[33, 34]. Furthermore, previous studies have confirmed that low ligation of IMA in laparoscopic anterior resection for rectal cancer reduces genitourinary dysfunction[35]. However, this outcome was not observed in this study, possibly because dissection of the IMA root LNs inevitably injured the superior hypogastric plexus.

The type of IMA and its position relationship with LCA varies among individuals[22, 36], may lead to the blindness of intraoperative dissection of IMA and LCA. The preservation of LCA during anterior resection for rectal cancer requires exposing IMA and LCA, which is of technical difficulties. Thus, preoperative evaluation of the IMA type based on three-dimensional CT reconstruction results is beneficial[15, 37]. In this study, the IMA of 108 patients was divided into four types according to the three-dimensional CT reconstruction image. Furthermore, the position relationships of LCA, SA and SRA can be obtained by three-dimensional CT reconstruction. If preoperative three-dimensional CT reconstruction results indicates absence of LCA, high ligation of IMA should be performed without the need to expose LCA. However, preservation of the LCA cannot be mechanically performed according to IMA types. Personalized surgical

strategies should be adopted to combine the IMA types, IMA length and the position relationship among LCA, SA, and SRA obtained by three-dimensional CT reconstruction image before surgery, which can be of guiding value for the preservation of LCA during rectal cancer surgery. Previous study have shown that robotic low ligation of the IMA with real-time identification of the vascular system for rectal cancer using the firefly technique is safe and feasible, which facilitate the identification of the branch of the IMA[38]. This technique can provide navigation for the exposure and ligation of vascular, which is of great value for accurate and safe implemented IMA root lymph node dissection combine with the preservation of the LCA. It has been reported that the LCA ascended to the splenic flexure together with the IMV in 71.4% patients[22]. Because of this anatomical structure, the LCA may be injured or cut off when IMV is exposed during rectal cancer surgery and the purpose of preserving LCA may not be achieved. Preoperative three-dimensional CT and intraoperative fluorescence imaging can provide guidance for surgeons in the treatment of LCA and IMV during rectal cancer surgery. However, high-quality randomized controlled studies are needed to further confirm whether the use of these two techniques will reduce intraoperative vascular injury, blood loss and operative time.

This single-center prospective cohort study has several limitations. Preservation of the LCA during anterior resection for rectal cancer has not been widely carried out in our department, so the sample accumulation is slow and the sample size is small. This study was a non-randomized controlled trial, which affected the reliability of the results at least to some extent. Due to insufficient follow-up time, this study did not compare the oncology efficacy and long-term prognosis between the two groups. Postoperative functions, such as defecation, postoperative exhaust recovery, sexual function, bladder function, and postoperative quality of life, were not evaluated in this study. To overcome these limitations, further multi-center, large-sample, randomized controlled trials are needed.

## Conclusions

This study has shown that preservation of the LCA during anterior resection for rectal cancer is safe and feasible, which can reduce anastomotic leakage, reoperation rate, and overall early complications. Furthermore, preoperative assessment of the IMA types and the position relationship among LCA, SA and SRA potentially facilitate the exposure and preservation of LCA during rectal cancer surgery.

## Abbreviations

**ASA:** American Society of Anesthesiologists

**BMI:** Body Mass Index

**CT:** Computed tomography

**IMA:** Inferior Mesenteric Artery

**IMV:** Inferior Mesenteric Vein

**LCA:** Left Colic Artery

**LNs:** lymph nodes

**SA:** Sigmoid Artery

**SRA:** Superior Rectal Artery

**TME:** Total Mesorectal Excision

**TaTME:** Transanal Total Mesorectal Excision

## **Declarations**

### **Ethics approval and consent to participate**

This study was approved by the ethical committee of Army Medical University DaPing hospital (Project ID: 201855).

### **Consent for publication**

Not applicable.

### **Availability of data and materials**

The datasets used and/or analysed during the current study are available from the corresponding author on reasonable request.

### **Competing interests**

The authors declare that they have no competing interests.

### **Funding**

This work was supported by the National Natural Science Foundation of China (81570483, 81770541) and the National Key R&D Program of China (2017YFC0908200).

### **Authors' contributions**

Huichao Zheng design of the work and wrote the manuscript. Yue Tian and Jingwang Ye used statistical software for analysis. Yong Zhang collected the data. Fan Li and Baohua Liu provided clinical advice. Weidong Tong revised and polished the manuscript. All authors read and approved the final manuscript.

### **Acknowledgements**

Not applicable

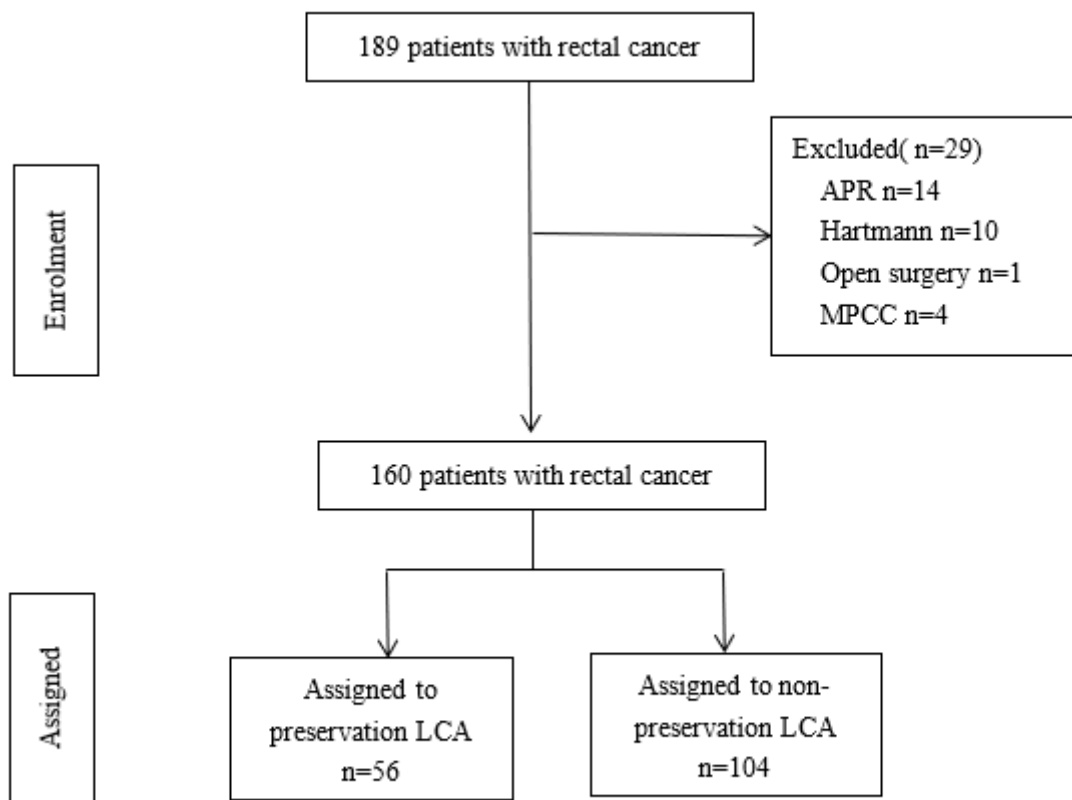
## References

1. Chen H, Cai HK, Tang YH. An updated meta-analysis of transanal drainage tube for prevention of anastomotic leak in anterior resection for rectal cancer. *Surgical oncology*. 2018;27(3):333-40.
2. Wang S, Liu J, Wang S, Zhao H, Ge S, Wang W. Adverse Effects of Anastomotic Leakage on Local Recurrence and Survival After Curative Anterior Resection for Rectal Cancer: A Systematic Review and Meta-analysis. *World J Surg*. 2017;41(1):277-84.
3. Kawada K, Sakai Y. Preoperative, intraoperative and postoperative risk factors for anastomotic leakage after laparoscopic low anterior resection with double stapling technique anastomosis. *World J Gastroenterol*. 2016;22(25):5718-27.
4. Parthasarathy M, Greensmith M, Bowers D, Groot-Wassink T. Risk factors for anastomotic leakage after colorectal resection: a retrospective analysis of 17 518 patients. *Colorectal Dis*. 2017;19(3):288-98.
5. Qu H, Liu Y, Bi DS. Clinical risk factors for anastomotic leakage after laparoscopic anterior resection for rectal cancer: a systematic review and meta-analysis. *Surg Endosc*. 2015;29(12):3608-17.
6. Cirocchi R, Farinella E, Trastulli S, Desiderio J, Di Rocco G, Covarelli P, et al. High tie versus low tie of the inferior mesenteric artery: a protocol for a systematic review. *World journal of surgical oncology*. 2011;9:147.
7. Allison AS, Bloor C, Faux W, Arumugam P, Widdison A, Lloyd-Davies E, et al. The angiographic anatomy of the small arteries and their collaterals in colorectal resections: some insights into anastomotic perfusion. *Ann Surg*. 2010;251(6):1092-7.
8. Fujii S, Ishibe A, Ota M, Watanabe K, Watanabe J, Kunisaki C, et al. Randomized clinical trial of high versus low inferior mesenteric artery ligation during anterior resection for rectal cancer. *BJS open*. 2018;2(4):195-202.
9. Matsuda K, Hotta T, Takifuji K, Yokoyama S, Oku Y, Watanabe T, et al. Randomized clinical trial of defaecatory function after anterior resection for rectal cancer with high versus low ligation of the inferior mesenteric artery. *The British journal of surgery*. 2015;102(5):501-8.
10. Yang X, Ma P, Zhang X, Wei M, He Y, Gu C, et al. Preservation versus non-preservation of left colic artery in colorectal cancer surgery: An updated systematic review and meta-analysis. *Medicine*. 2019;98(5):e13720.
11. Kato H, Munakata S, Sakamoto K, Sugimoto K, Yamamoto R, Ueda S, et al. Impact of Left Colonic Artery Preservation on Anastomotic Leakage in Laparoscopic Sigmoid Resection and Anterior Resection for Sigmoid and Rectosigmoid Colon Cancer. *J Gastrointest Cancer*. 2018.
12. Titu LV, Tweedle E, Rooney PS. High tie of the inferior mesenteric artery in curative surgery for left colonic and rectal cancers: a systematic review. *Dig Surg*. 2008;25(2):148-57.
13. Yang Y, Wang G, He J, Zhang J, Xi J, Wang F. High tie versus low tie of the inferior mesenteric artery in colorectal cancer: A meta-analysis. *Int J Surg*. 2018;52:20-4.

14. Sorelius K, Svensson J, Matthiessen P, Rutegard J, Rutegard M. A nationwide study on the incidence of mesenteric ischaemia after surgery for rectal cancer demonstrates an association with high arterial ligation. *Colorectal Dis.* 2019;21(8):925-31.
15. Son GM, Kim TU, Park BS, Jung HJ, Lee SS, Yoon JU, et al. Colonic hypoperfusion following ligation of the inferior mesenteric artery in rectosigmoid colon cancer patients. *Ann Surg Treat Res.* 2019;97(2):74-82.
16. Crocetti D, Cavallaro G, Tarallo MR, Chiappini A, Polistena A, Sapienza P, et al. Preservation of left colic artery with lymph node dissection of IMA root during laparoscopic surgery for rectosigmoid cancer. Results of a retrospective analysis. *Clin Ter.* 2019;170(2):e124-e8.
17. Guo Y, Wang D, He L, Zhang Y, Zhao S, Zhang L, et al. Marginal artery stump pressure in left colic artery-preserving rectal cancer surgery: a clinical trial. *ANZ J Surg.* 2017;87(7-8):576-81.
18. Seike K, Koda K, Saito N, Oda K, Kosugi C, Shimizu K, et al. Laser Doppler assessment of the influence of division at the root of the inferior mesenteric artery on anastomotic blood flow in rectosigmoid cancer surgery. *Int J Colorectal Dis.* 2007;22(6):689-97.
19. Rahbari NN, Weitz J, Hohenberger W, Heald RJ, Moran B, Ulrich A, et al. Definition and grading of anastomotic leakage following anterior resection of the rectum: a proposal by the International Study Group of Rectal Cancer. *Surgery.* 2010;147(3):339-51.
20. Penna M, Hompes R, Arnold S, Wynn G, Austin R, Warusavitarne J, et al. Transanal Total Mesorectal Excision: International Registry Results of the First 720 Cases. *Annals of surgery.* 2017;266(1):111-7.
21. Morelli L, Di Franco G, Lorenzoni V, Guadagni S, Palmeri M, Furbetta N, et al. Structured cost analysis of robotic TME resection for rectal cancer: a comparison between the da Vinci Si and Xi in a single surgeon's experience. *Surg Endosc.* 2019;33(6):1858-69.
22. Murono K, Kawai K, Kazama S, Ishihara S, Yamaguchi H, Sunami E, et al. Anatomy of the inferior mesenteric artery evaluated using 3-dimensional CT angiography. *Dis Colon Rectum.* 2015;58(2):214-9.
23. Fazio VW, Zutshi M, Remzi FH, Parc Y, Ruppert R, Furst A, et al. A randomized multicenter trial to compare long-term functional outcome, quality of life, and complications of surgical procedures for low rectal cancers. *Ann Surg.* 2007;246(3):481-8; discussion 8-90.
24. Ptok H, Steinert R, Meyer F, Kroll KP, Scheele C, Kockerling F, et al. [Long-term oncological results after laparoscopic, converted and primary open procedures for rectal carcinoma. Results of a multicenter observational study]. *Chirurg.* 2006;77(8):709-17.
25. Kang CY, Halabi WJ, Chaudhry OO, Nguyen V, Pigazzi A, Carmichael JC, et al. Risk factors for anastomotic leakage after anterior resection for rectal cancer. *JAMA Surg.* 2013;148(1):65-71.
26. Platell C, Barwood N, Dorfmann G, Makin G. The incidence of anastomotic leaks in patients undergoing colorectal surgery. *Colorectal Dis.* 2007;9(1):71-9.
27. Damen N, Spilsbury K, Levitt M, Makin G, Salama P, Tan P, et al. Anastomotic leaks in colorectal surgery. *ANZ J Surg.* 2014;84(10):763-8.

28. Davis B, Rivadeneira DE. Complications of colorectal anastomoses: leaks, strictures, and bleeding. *Surg Clin North Am.* 2013;93(1):61-87.
29. Vignali A, Gianotti L, Braga M, Radaelli G, Malvezzi L, Di Carlo V. Altered microperfusion at the rectal stump is predictive for rectal anastomotic leak. *Dis Colon Rectum.* 2000;43(1):76-82.
30. Sheridan WG, Lowndes RH, Young HL. Tissue oxygen tension as a predictor of colonic anastomotic healing. *Dis Colon Rectum.* 1987;30(11):867-71.
31. Dworkin MJ, Allen-Mersh TG. Effect of inferior mesenteric artery ligation on blood flow in the marginal artery-dependent sigmoid colon. *J Am Coll Surg.* 1996;183(4):357-60.
32. Hinoi T, Okajima M, Shimomura M, Egi H, Ohdan H, Konishi F, et al. Effect of left colonic artery preservation on anastomotic leakage in laparoscopic anterior resection for middle and low rectal cancer. *World J Surg.* 2013;37(12):2935-43.
33. Yamamoto M, Okuda J, Tanaka K, Ishii M, Hamamoto H, Uchiyama K. Oncological impact of laparoscopic lymphadenectomy with preservation of the left colic artery for advanced sigmoid and rectosigmoid colon cancer. *Dig Surg.* 2014;31(6):452-8.
34. Fan D, Zhang C, Li X, Yao C, Yao T. Evaluation of the clinical efficacy of preserving the left colic artery in laparoscopic resection for rectal cancer: A meta-analysis. *Mol Clin Oncol.* 2018;9(5):553-60.
35. Mari GM, Crippa J, Cocozza E, Berselli M, Livraghi L, Carzaniga P, et al. Low Ligation of Inferior Mesenteric Artery in Laparoscopic Anterior Resection for Rectal Cancer Reduces Genitourinary Dysfunction: Results From a Randomized Controlled Trial (HIGHLOW Trial). *Ann Surg.* 2019;269(6):1018-24.
36. Yada H, Sawai K, Taniguchi H, Hoshima M, Katoh M, Takahashi T. Analysis of vascular anatomy and lymph node metastases warrants radical segmental bowel resection for colon cancer. *World J Surg.* 1997;21(1):109-15.
37. Ke J, Cai J, Wen X, Wu X, He Z, Zou Y, et al. Anatomic variations of inferior mesenteric artery and left colic artery evaluated by 3-dimensional CT angiography: Insights into rectal cancer surgery - A retrospective observational study. *Int J Surg.* 2017;41:106-11.
38. Bae SU, Min BS, Kim NK. Robotic Low Ligation of the Inferior Mesenteric Artery for Rectal Cancer Using the Firefly Technique. *Yonsei Med J.* 2015;56(4):1028-35.

## Figures



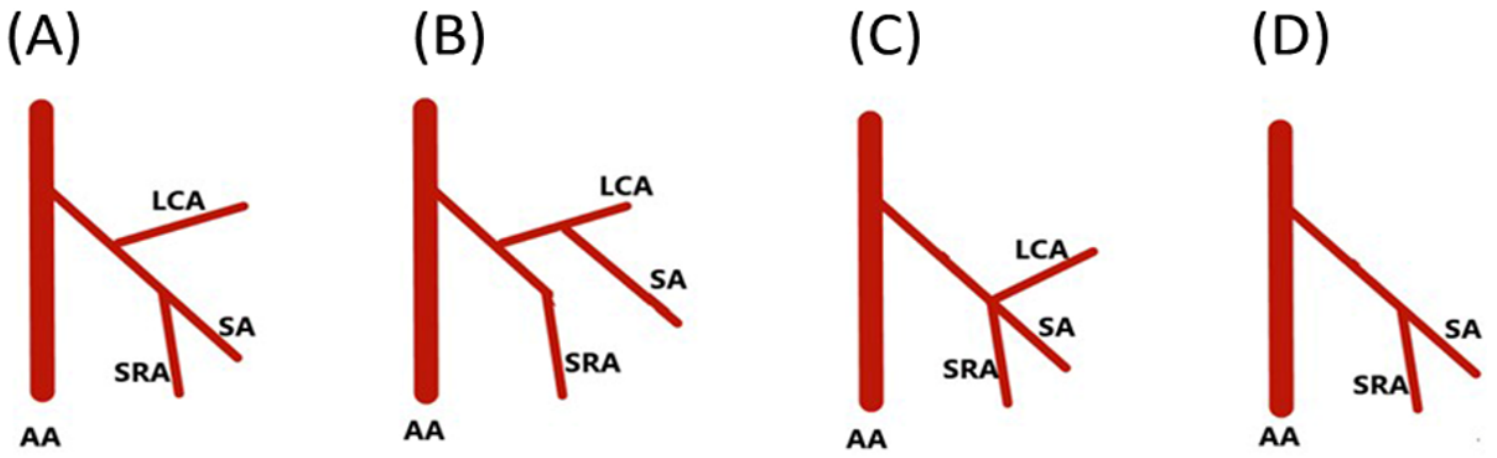
**Figure 1**

CONSORT flow diagram for the trial. Legends: LCA, left colic artery; APR, abdominoperineal resection; MPCC, multiple primary colorectal cancer.



**Figure 2**

Preservation or non-preservation of the left colic artery in anterior resection for rectal cancer. Legends: a, preservation left colic artery: the IMA was ligated at below the origin of LCA; b, non-preservation left colic artery: the IMA was ligated at 1cm from its origin.



**Figure 3**

The diagram of the IMA type. Legends: a, type I; b, type II; c, type III; d, type IV. LCA, left colic artery; SA, sigmoid artery; SRA, superior rectal artery; AA, abdominal aorta



**Figure 4**

The three dimensional CT reconstruction image of IMA type. Legends: a, type I; b, type II; c, type III; d, type IV. LCA, left colic artery; SA, sigmoid artery; SRA, superior rectal artery.