

# Pigmented villonodular synovitis does not influence the outcomes following cruciate-retaining total knee arthroplasty: a case-control study with minimum five year follow-up

**Wei Lin**

Hebei Medical University Third Affiliated Hospital

**Yike Dai**

Hebei Medical University Third Affiliated Hospital

**Jinghui Niu**

Hebei Medical University Third Affiliated Hospital

**Guangmin Yang**

Hebei Medical University Third Affiliated Hospital

**Ming Li**

Hebei Medical University Third Affiliated Hospital

**Fei Wang** (✉ [doctorlinw@163.com](mailto:doctorlinw@163.com))

Hebei Medical University Third Affiliated Hospital

---

## Research article

**Keywords:** Pigmented villonodular synovitis, Osteoarthritis, Cruciate-retaining, Total knee arthroplasty

**DOI:** <https://doi.org/10.21203/rs.3.rs-16062/v2>

**License:**  This work is licensed under a Creative Commons Attribution 4.0 International License.

[Read Full License](#)

---

# Abstract

**Background:** Pigmented villonodular synovitis (PVNS) is a rare synovial disease with benign hyperplasia, which has been successfully treated with total knee arthroplasty (TKA). The purpose of this study was to investigate the middle-term follow-up outcomes of cruciate-retaining (CR) TKA in patients with PVNS.

**Methods:** From January 2012 to December 2014, a retrospective study was conducted in 17 patients with PVNS who underwent CR TKA as PVNS group. During this period, we also selected 68 patients with osteoarthritis who underwent CR TKA (control group) for comparison. The two groups matched in a 1:4 ratio based on age, sex, body mass index and follow-up time. The range of motion, Knee Society Score, revision rate, disease recurrence, wound complications and the survivorship curve of Kaplan-Meier implant were assessed between the two groups.

**Results:** All patients were followed up at least five years. There were no difference in range of motion, and Knee Society Score between the two groups before surgery and at last follow-up after surgery ( $p > 0.05$ ). In the PVNS group, no patients with the recurrence of PVNS were found at the last follow-up, one patient underwent revision surgery due to periprosthetic fracture, and three patients had stiffness one year after surgery (17.6% vs 1.5%,  $p = 0.005$ ; ROM:16°- 81°), but no revision was needed. At seven years, the implant survivorship was 90.0% in the PVNS group and 96.6% in the control group ( $p = 0.54$ ).

**Conclusions:** This study demonstrated that the function of patients with PVNS who underwent CR TKA had been significantly improved, and the survival rate of implants in these patients were similar to the patients with OA. Consequently, the patients with PVNS who underwent CR TKA might be an achievable option. However, these patients should pay more attention to the occurrence of postoperative stiffness complication.

## Background

Pigmented villonodular synovitis (PVNS) was initially described by Jaffe in 1941 as a benign, locally aggressive disease characterized by excessive proliferation of histiocytes in the synovium [1,2]. It is characterized by mechanical symptoms, local recurrence and knee stiffness which can lead to severe joint destruction [3]. PVNS mainly affects young people aged 30-40, and there is no difference in gender preference [4]. The knee is the most common diseased joint [5,6]. Prior to joint destruction, arthroscopic or open surgery is the main treatment. However, once the joint destruction occurs, there are few options for pain relief and functional improvement [3,7,8].

Total knee arthroplasty (TKA) has been successfully used to improve the function and relieve pain in patients with PVNS. According to some articles, the survival rate of prosthesis ranges from 80% to 85% in patients with PVNS who have been followed up for more than 10 years [9]. In addition, the incidence of postoperative complications of TKA also provided acceptable results in a large number of patients

diagnosed with PVNS [10]. However, it is still controversial to retain or substitute posterior cruciate ligament (PCL) in TKA when treated with patients with PVNS. Due to limited case studies of the knee PVNS, there were few data have been available on the clinical outcomes of patients with PVNS who underwent cruciate-retaining (CR) TKA. Moreover, in previous studies, there was a lack of evaluation of the results of control and middle-term study.

Therefore, the purpose of this study was to investigate the disease recurrence rate and the middle-term clinical outcomes of patients with PVNS who underwent CR TKA, and compared with a group of patients with knee osteoarthritis (OA) who underwent CR TKA.

## Methods

### *Study cohort*

With the approval of the Institutional Review Committee, we conducted a retrospective study from January 2012 to December 2014. We included 17 patients who were diagnosed as knee PVNS in the PVNS group. To improve the reliability of this research, we used a 1:4 ratio with regard to age, sex, body mass index (BMI), and follow-up time to select 68 patients with knee OA who underwent CR TKA (Control group) for comparison. In the PVNS group, according to Jaffe's classification, all patients were diagnosed as diffuse PVNS by pathology [11]. The inclusion criteria were: (□) patients with unilateral knee PVNS in the PVNS group; (□) patients with unilateral knee OA in the control group; (□) varus or valgus deformity < 20°; (□) flexion-contracture deformity < 20°. Patients who had neurological problems, anticoagulant therapy, revision TKA were excluded.

### *Clinical and radiographic features of patients with PVNS before CR TKA*

All patients with PVNS had knee pain before receiving CR TKA. In our study, seven patients (41%) underwent at least one synovectomy, five patients (29.4%) were associated with patella dislocation or subluxation, and ten patients (59%) had limited knee mobility with an average range of motion (ROM) of 89° (range 78°-101°). The X-ray showed typical features of the end-stage knee joint in patients with PVNS, including narrowing of joint space and cystic destruction (Figure. 1).

### *Surgical treatment*

All surgeries were performed by the same surgeon and accomplished through the standard midline skin incisions and medial parapatellar arthrotomy. For patients with PVNS, the pathological synovium was radically resected and histopathologically assessed. Firstly, the proximal tibia was resected on the coronal plane perpendicular to the tibial axis, and the sagittal plane was inclined backwards by 6-8°, preserving the PCL. The distal femur was excised with 5-7° valgus, for patients with poor patella track,

we appropriately increased the external rotation osteotomy of the femur. Provide sufficient space between the femur and tibia for synovectomy. All patients received the same type of CR prosthesis (LINK, Germany, Gemini MK II). There were no restrictions placed on ROM, activity postoperatively or weight-bearing status.

### ***Outcome measures***

Assessments were performed by a senior orthopaedic surgeon who did not attend the treatments. The demographics in regard to age, sex, BMI, follow-up time, disease recurrence, revision rate, and wound complications were examined.

The ROM, Knee Society Scores (KSS) [12], and the survivorship curve of Kaplan-Meier implant were compared between the two groups. All data were assessed before surgery and last follow up after surgery.

The standard anteroposterior and lateral radiographs were used for all preoperative and postoperative radiologic evaluations.

### ***Statistical analysis***

The normality of the continuous variables was checked with the Shapiro-Wilk test. If the data were normally distributed, the variables were checked with Student's t test; if not, a non-parametric test was selected. Categorical variables were checked with Fisher's exact test or chi-square test. The implant survivorship was generated with 95% confidence intervals (CI) by Kaplan-Meier method. The data were analyzed with the SPSS 19.0 (IBM, Chicago, IL, USA). A  $p < 0.05$  was considered significant.

## **Results**

All patients were followed up at least five years (Table 1). During the last follow-up, no clinical or radiological signs of prosthetic loosening were found in the PVNS group, indicating no recurrence of PVNS (Figure 2). There were no significantly difference in ROM, knee society clinical and functional scores between the two groups before surgery and at last follow-up after surgery (Table 2). All patients were able to exercise moderately without crutches. In the PVNS group, one patient underwent revision surgery because of periprosthetic fracture, and three patients had stiffness one year after surgery (17.6% vs 1.5%,  $p = 0.005$ ; ROM:16°- 81°), but no revision was needed. In the control group, two patients underwent revision (one unstable revisions and one infection) ( $p = 0.56$ ). At seven years, the implant survivorship without any revision was 90.0% in the PVNS group and 96.6% in the control group, however, there was no significant difference between the two groups ( $p = 0.54$ ) (Figure 3).

## Discussion

This study showed that the patients with PVNS who underwent CR TKA had similar survival rate and functional outcomes as the patients with OA who underwent CR TKA. In the minimum five years follow-up, no infection, osteolysis, and knee instability were found in the patients with PVNS. Furthermore, there was no evidence of the PVNS recurrence. However, these patients should pay more attention to the occurrence of postoperative stiffness complication.

The PVNS is a rare benign proliferative knee joint disease. Although the pathogenesis of PVNS remains unclear, some researchers believe that traumatic bleeding may be one of the causative factors [13,14]. In a previously case report, the localized pigmented villonodular synovitis presenting as recurrent dislocation of the patella [15]. This is consistent with our study, in our study, five patients (29.4%) with PVNS had a history of patella dislocation or subluxation. And, we appropriately increased the external rotation osteotomy of the femur in surgery for those patients. In the postoperative follow-up, these patients achieved good postoperative clinical outcomes, no abnormal patella track and only one patient with anterior knee pain was found. Therefore, we believed that the patella dislocation or subluxation may be a susceptible factor for the knee PVNS. In the future, we should pay more attention to these patients.

The local knee PVNS is widely present in the anterior chamber of the knee, and the patients who have symptomatic are usually treated with arthroscopic debridement. However, the diffuse PVNS require combined surgery, either through arthroscopy or open surgery [3,16]. If the PVNS extends beyond the joint, an open surgery is required [16]. Although open surgery can reduce the local recurrence rate of diffuse PVNS, these procedures may lead to a high incidence of knee stiffness after surgery [17]. The ROM after TKA is associated with preoperative knee ROM [18], and in our study, we found that the patients with PVNS who underwent open synovectomy, the knee ROM was poor after CR TKA. In addition, we also found that the incidence of postoperative knee stiffness in patients with PVNS was higher than the patients with OA, even if they have not received other surgery before TKA, so we should pay more attention to the postoperative rehabilitation of patients with PVNS.

It is generally known that TKA is the most effective treatment for end-stage PVNS in patients who have severe OA due to PVNS progression, and the recurrence and revision rate of PVNS are lower than that with simple synovectomy [9]. The long-term results of TKA treatment with PVNS have been well recorded, and some studies have reported excellent long-term survival of TKA in patients with PVNS [9,10]. However, it is still controversial to retain or substitute the PCL in TKA when treated with the patients with PVNS, and due to limited case studies of the knee PVNS, there is currently little data on the results of CR TKA in these patients.

During primary TKA, two principal designs are used: CR TKA and posterior-stabilized (PS) TKA. Compared with PS TKA, the CR TKA has been widely used because it improves the knee's ability to exercise, preserves the knee's proprioception, and increases the knee ROM and stability during knee extension and flexion [19,20]. Although the PVNS and the rheumatoid arthritis have different types of inflammation and mechanisms of joint destruction, they all produce chronic inflammation environment in joints, so the two

diseases have some comparability to some extent [21]. Scott and his colleagues [22] pointed out that 95% of rheumatoid arthritis patients had complete PCL during TKA surgery and believed that the PCL should be preserved during surgery to maximize femoral rollback. In addition, it has been informed that satisfactory clinical and radiological outcomes have been obtained in the rheumatoid arthritis patients who were followed up for an average of 10.5 years with CR TKA [23]. Miller [24] evaluated long-term outcomes of patients with rheumatoid arthritis who were followed up for 20 years after CR TKA, for any reason, the 20-year implant survival rate was 69%. They believe that the PCL dysfunction is rarely the cause of surgical failure [24]. This is consistent with our present study. In our study, the patients with PVNS who underwent CR TKA achieved excellent mid-term follow-up outcomes.

The PVNS most frequently affects the knee, although there were long-term follow-up studies and short-term complications in the previous literature with the evaluation of PVNS in arthroplasty, there was no clear middle-term follow-up control study. The previous TKA treatment in patients with PVNS was a minor cohort study, primarily to assess implant survival and function, and did not quantify the risk of postoperative complications, which may be due to the fewer patients [9,25]. Although Houdek et al [9] did not compare the incidence of complications to the control group, their most common complication in their study was the loss of knee ROM, which was similar with our study. According to the previous reports, the revision rate of the patients with PVNS was as high as 21%, which was significantly higher than the incidence of published primary TKA for OA [9,26]. In our study, only one patient underwent revision because of periprosthetic fracture. In addition, the implant survivalship without any correction for 7 years after CR TKA was 90.0%, and we did not find any local recurrence. These clinical outcomes were similar to the patients with OA who underwent CR TKA. However, the revision rate may become inconsistent with additional long-term follow-up.

Radiotherapy and chemotherapy may be a viable option when surgery fails to eradicate PVNS or recurrence. Medium-dose external irradiation (30-35 Gy) combined with surgical resection can reduce the recurrence rate in patients with extensive or invasive diseases [27, 28]. In recent years, significant advances have been made in the treatment of diffuse PVNS [29,30]. Since PVNS often overexpress colony-stimulating factor 1 (csf1), receptor-targeted chemotherapeutic drugs (csf1r) may be an effective treatment [29,30]. Although these drugs were not used in patients in this series of study, it was believed that the young patients should consider using them to alleviate symptoms and delay TKA for as long as possible.

Our study had several limitations. First, this was a small sample retrospective study, which had its potential bias and weaknesses. A prospective study should be established to objectify these findings. Second, because the patients with PVNS in our study were treated with CR TKA, we were unable to compare the efficacy of different prostheses, such as PS TKA, semi-constrained or rotating hinge prostheses.

## Conclusions

In conclusion, our study provided encouraging results for the middle-term survival of patients with PVNS who received CR TKA. Compared to OA patients, end-stage PVNS of knee treated with CR TKA had similar restoration of function outcome and implant survivorship. Our results suggested that PVNS patients who treated with CR TKA may be a achievable option. However, patients with PVNS should pay more attention to the occurrence of postoperative stiffness complications.

## Declarations

### Ethics approval

This study was approved by the Third Hospital of Hebei Medical University and followed the Declaration of Helsinki. Informed consent was received from all patients.

### Consent for publication

Not applicable.

### Availability of data and materials

The detailed data and materials of this study were available from the corresponding author through emails on reasonable request.

### Competing interests

The authors declare that they have no competing interests.

### Funding

Not applicable.

### Authors' contributions

FW designed the study. WL, JHN and YKD performed the experimental work. GMY, ML, WL evaluated the data. WL wrote the manuscript. All authors read and approved the final manuscript.

### Acknowledgments

The authors thank all colleagues in the department of orthopedic surgery of the third hospital of Hebei medical university.

## Abbreviations

PVNS: pigmented villonodular synovitis; OA: osteoarthritis; TKA: total knee arthroplasty; CR: cruciate retaining; cruciate-substituting (PS); BMI: body mass index; ROM: range of motion; KSS: knee society score; PCL: posterior cruciate ligament.

## References

1. Mankin H, Trahan C, Hornicek F. Pigmented villonodular synovitis of joints. *J Surg Oncol*. 2011;103:386e9.
2. Myers BW, Masi AT. Pigmented villonodular synovitis and tenosynovitis: a clinical epidemiologic study of 166 cases and literature review. *Medicine*. 1980;59:223e38.
3. Tyler WK, Vidal AF, Williams RJ, Healey JH. Pigmented villonodular synovitis. *J Am Acad Orthop Surg*. 2006;14:376–85.
4. Chi Xu, Heng Guo, Kerri L. Bell, Feng-Chih Kuo and Ji-Ying Chen. Pigmented villonodular synovitis does not influence the outcome following cementless total hip arthroplasty using ceramic-on-ceramic articulation: a case-control study with middle-term follow-up. *J Orthop Surg Res*. 2018V13N1:294.
5. Dorwart R, Genant H, Johnston W, Morris J. Pigmented villonodular synovitis of synovial joints: clinical, pathologic, and radiologic features. *Am J Roentgenol*. 1984; 143:877e85.
6. Mahieu X, Chaouat G, Blin J-L, Frank A, Hardy P, Byers P, et al. Arthroscopic treatment of pigmented villonodular synovitis of the shoulder. *Arthroscopy*. 2001; 17:81e7.
7. Flandry F, McCann SB, Hughston JC, Kurtz DM. Roentgenographic findings in pigmented villonodular synovitis of the knee. *Clin Orthop Relat Res*. 1989:208–19.
8. Hamlin BR, Duffy GP, Trousdale RT, Morrey BF. Total knee arthroplasty in patients who have pigmented villonodular synovitis. *J Bone Joint Surg Am*. 1998;80:76–82.
9. Houdek MT, et al. Long-term outcome of knee arthroplasty in the setting of pigmented villonodular synovitis, *Knee*. 2017V24N4:851-855.
10. Aaron J. Casp, James A. Browne, Nicole E. Durig, Brian C. Werner. Complications After Total Knee Arthroplasty in Patients With Pigmented Villonodular Synovitis, *J Arthroplasty*. 2019V34N1:36-39.
11. JAFFE H. Pigmented villonodular synovitis, bursitis, and tenosynovitis. *Arch Pathol*. 1941;31:731–65.
12. Insall JN, Dorr LD, Scott RD, Scott WN. Rationale of the knee Society clinical rating system. *Clin Orthop Relat Res*. 1989:13–4.
13. Ma X, Shi G, Xia C, Liu H, He J, Jin W. Pigmented villonodular synovitis: a retrospective study of seventy five cases (eighty one joints). *Int Orthop*. 2013; 37: 1165–70.
14. Baba S, Motomura G, Fukushi J, Ikemura S, Sonoda K, Kubo Y, et al. Osteonecrosis of the femoral head associated with pigmented villonodular synovitis. *Rheumatol Int*. 2017;37:841–5.
15. Matthew J. Bartlett, B.A., F.R.C.S., and Jonathon Lavelle, F.R.C.S. Localized Pigmented Villonodular Synovitis Presenting as Recurrent Dislocation of the Patella. *Arthroscopy*. 2000V16N7:767-9.



16. Chin KR, Brick GW. Extraarticular pigmented villonodular synovitis: a cause for failed knee arthroscopy. *Clin Orthop Relat Res.* 2002;330–8.
17. Zvijac JE, Lau AC, Hechtman KS, Uribe JW, Tjin ATEW. Arthroscopic treatment of pigmented villonodular synovitis of the knee. *Arthroscopy.* 1999;15:613–7.
18. IssaK, KapadiaBH, KesterM, KhanujaHS, DelanoisRE, MontMA. Clinical, objective, and functional outcomes of manipulation under an esthesiato treat knee stiffness following total knee arthroplasty. *J Arthroplasty.* 2014;29:548–52.
19. Tsuji S, Tomita T, Hashimoto H, Fujii M, Yoshikawa H, Sugamoto K. Effect of posterior design changes on postoperative flexion angle in cruciate retaining mobile-bearing total knee arthroplasty. *Int Orthop.* 2011; 35: 689-695.
20. Matthews J, Chong A, McQueen D, O’Guinn J, Wooley P. Flexion-extension gap in cruciate-retaining versus posterior-stabilized total knee arthroplasty: a cadaveric study. *J Orthop Res.* 2014;32: 627-632.
21. Oehler S, Fassbender HG, Neureiter D, Meyer-Scholten C, Kirchner T, Aigner T. Cell populations involved in pigmented villonodular synovitis of the knee. *J Rheumatol.* 2000;27:463e70.
22. Scott RD, Sarokhan AJ, Dalziel R. Total hip and total knee arthroplasty in juvenile rheumatoid arthritis. *Clin Orthop Relat Res.* 1984; (182):90-8.
23. Archibeck MJ, Berger RA, Barden RM, et al. Posterior cruciate ligament-retaining total knee arthroplasty in patients with rheumatoid arthritis. *J Bone Joint Surg Am.* 2001; 83-A:1231-6.
24. Miller MD, Brown NM, Della Valle CJ, et al. Posterior cruciate ligament-retaining total knee arthroplasty in patients with rheumatoid arthritis: a concise follow-up of a previous report. *J Bone Joint Surg Am.* 2011;93:e130(1-6).
25. Tibbo ME, Wyles CC, Rose PS, Sim FH, Houdek MT, Taunton MJ. Long-term outcome of hip arthroplasty in the setting of pigmented villonodular synovitis. *J Arthroplasty.* 2018;33:1467e71.
26. Pabinger C, Berghold A, Boehler N, Labek G. Revision rates after knee replacement. Cumulative results from worldwide clinical studies versus joint registers. *Osteoarthr Cartil.* 2013;21:263e8.
27. O’Sullivan B, Cummings B, Catton C, Bell R, Davis A, Fornasier V, Goldberg R. Outcome following radiation treatment for high-risk pigmented villonodular synovitis. *International journal of radiation oncology, biology, physics.* 1995;32(3): 777.
28. Brien EW, Sacoman DM, Mirra JM. Pigmented villonodular synovitis of the foot and ankle. *Foot & ankle international.* 25(12):2004;908.
29. Cassier PA, Gelderblom H, Stacchiotti S, Thomas D, Maki RG, Kroep JR, et al. Efficacy of imatinib mesylate for the treatment of locally advanced and/or metastatic tenosynovial giant cell tumor/pigmented villonodular synovitis. *Cancer.* 2012; 118: 1649–55.
30. CassierPA, ItalianoA, Gomez-RocaCA, LeTourneauC, ToulmondeM, CannarileMA, ,et al. CSF1R inhibition with emactuzumab in locally advanced diffuse-type tenosynovial giant cell tumours of the soft tissue: a dose-escalation and dose-expansion phase 1 study. *Lancet Oncol.* 2015;16:949–56.

# Tables

Table 1 Patients demographics in the two groups

	PVNS (n = 17)	Controls (n = 68)	<i>p</i> value
Age (years)	58.6 ± 7.2	59.2 ± 6.8	0.87
Sex, n (%)			0.80
Female	13 (76.5%)	50 (73.5%)	
Male	4 (23.5%)	18 (26.5%)	
BMI (kg/m <sup>2</sup> )	25.4 ± 3.3	25.7 ± 3.1	0.76
Follow-up (years)	7.2 ± 1.7	7.3 ± 1.8	0.86

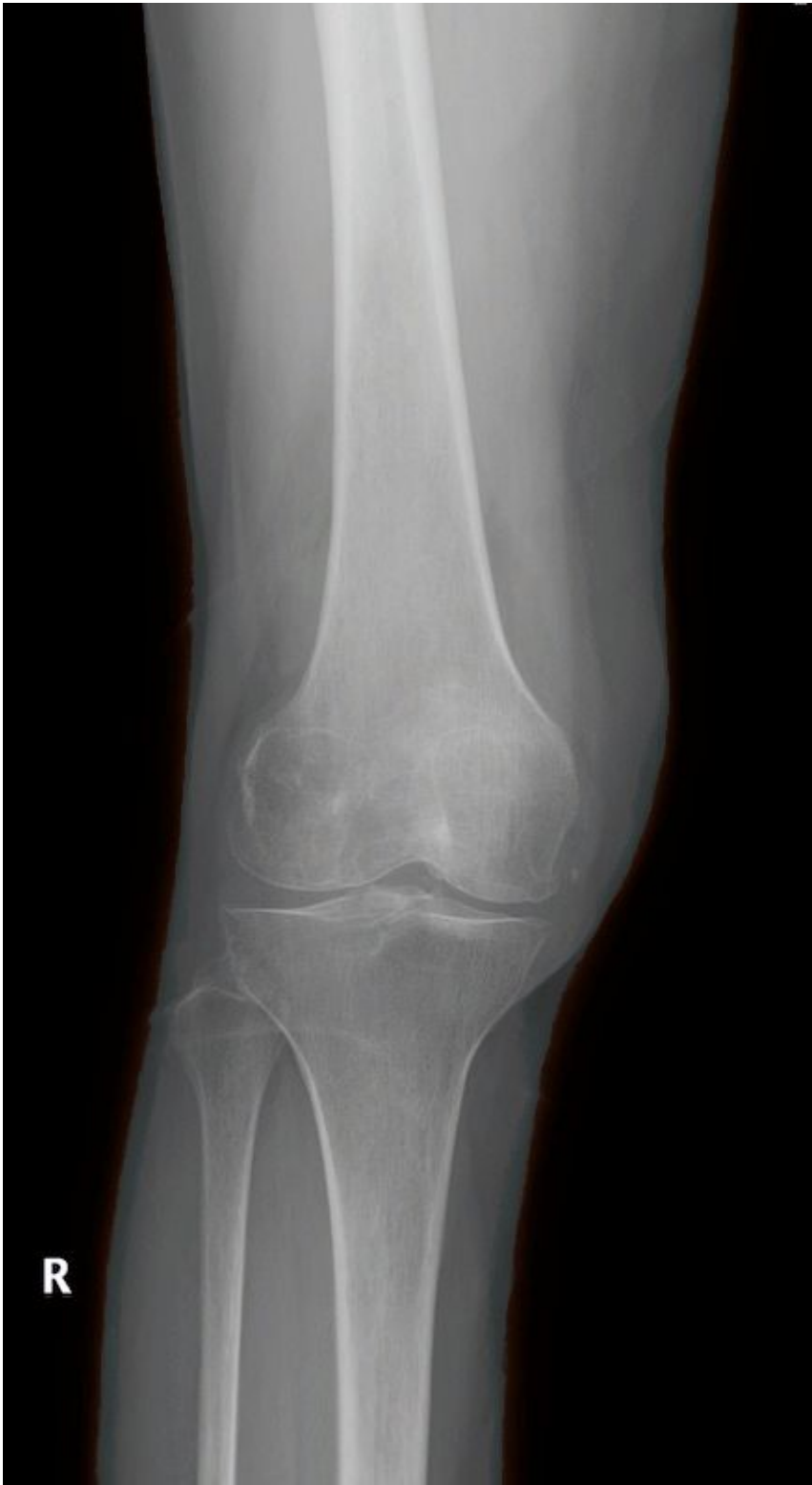PVNS, pigmented villonodular synovitis; BMI, body mass index; mean±standard deviation.

Table 2 The outcomes following CR TKA in the two groups

	PVNS (n = 17)	Controls (n = 68)	<i>p</i> value
pre-operative ROM	96 ± 5.2	97 ± 5.4	0.81
Last follow-up ROM	106 ± 9.7	107 ± 8.9	0.63
pre-operative Knee Society Clinical Score	36 ± 3.2	37.9 ± 2.7	0.43
Last follow-up Knee Society Clinical Score	93.5 ± 3.8	93.6 ± 1.9	0.82
pre-operative Knee Society Functional Score	37.9 ± 2.7	36.7 ± 3.3	0.50
Last follow-up Knee Society Functional Score	88.2 ± 1.4	88.1 ± 1.6	0.78
Recurrence, n (%)	0 (0%)	0 (0%)	-
Infection, n (%)	0 (0%)	1 (1.5%)	0.61
Chronic soft tissue pain, n (%)	1 (5.9%)	2 (2.9%)	0.56
Stiffness, n (%)	3 (17.6%)	1 (1.5%)	0.005
Abnormal patella track, n (%)	0 (0%)	1 (1.5%)	0.61
Any revision, n (%)	1 (5.9%)	2 (2.9%)	0.56

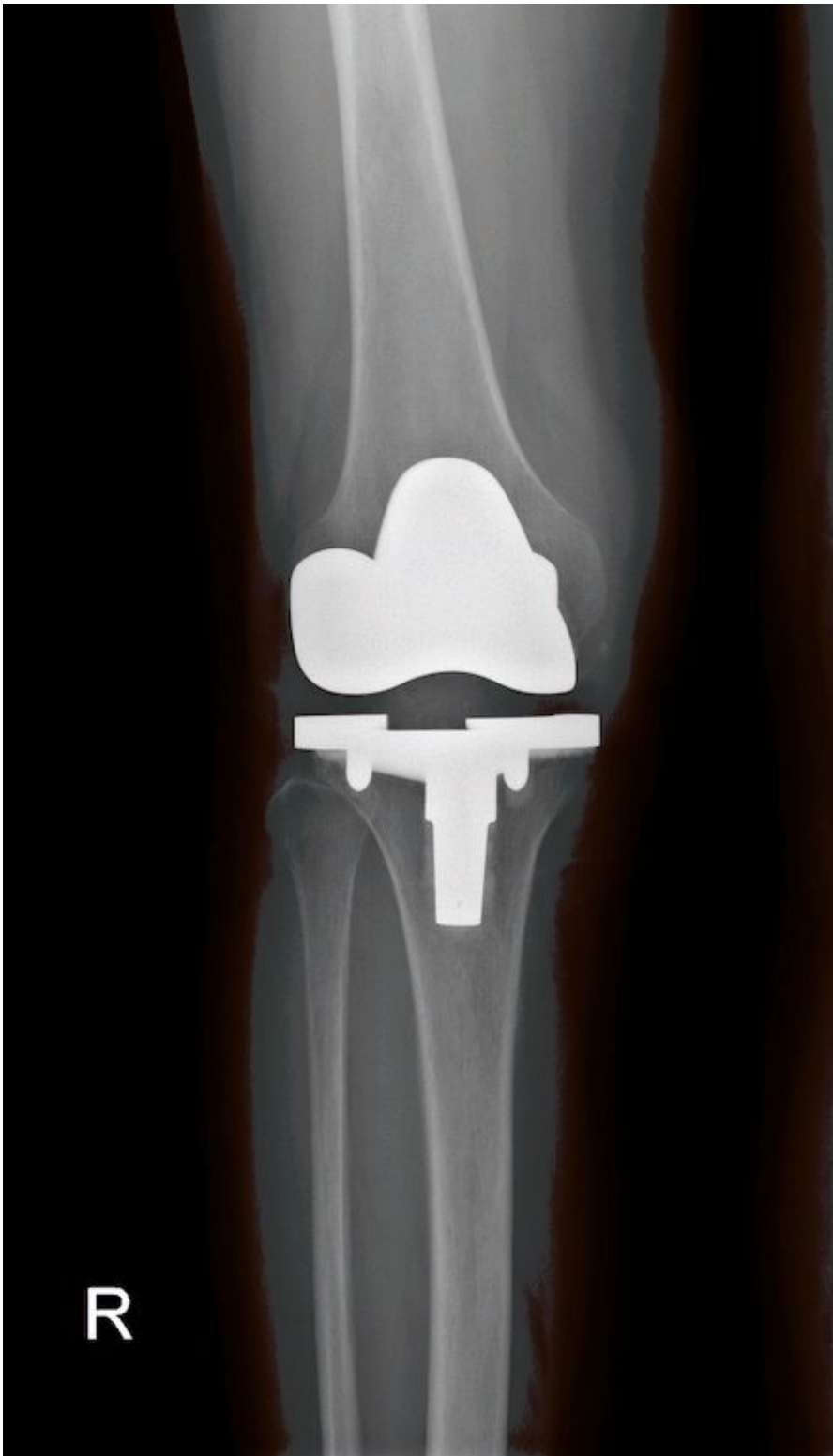PVNS, pigmented villonodular synovitis; ROM, range of motion; mean±standard deviation.

## Figures



**Figure 1**

Typical X-ray findings of PVNS in the knee



**Figure 2**

A radiograph was taken 6.2 years after TKA showed well-fixed prosthesis

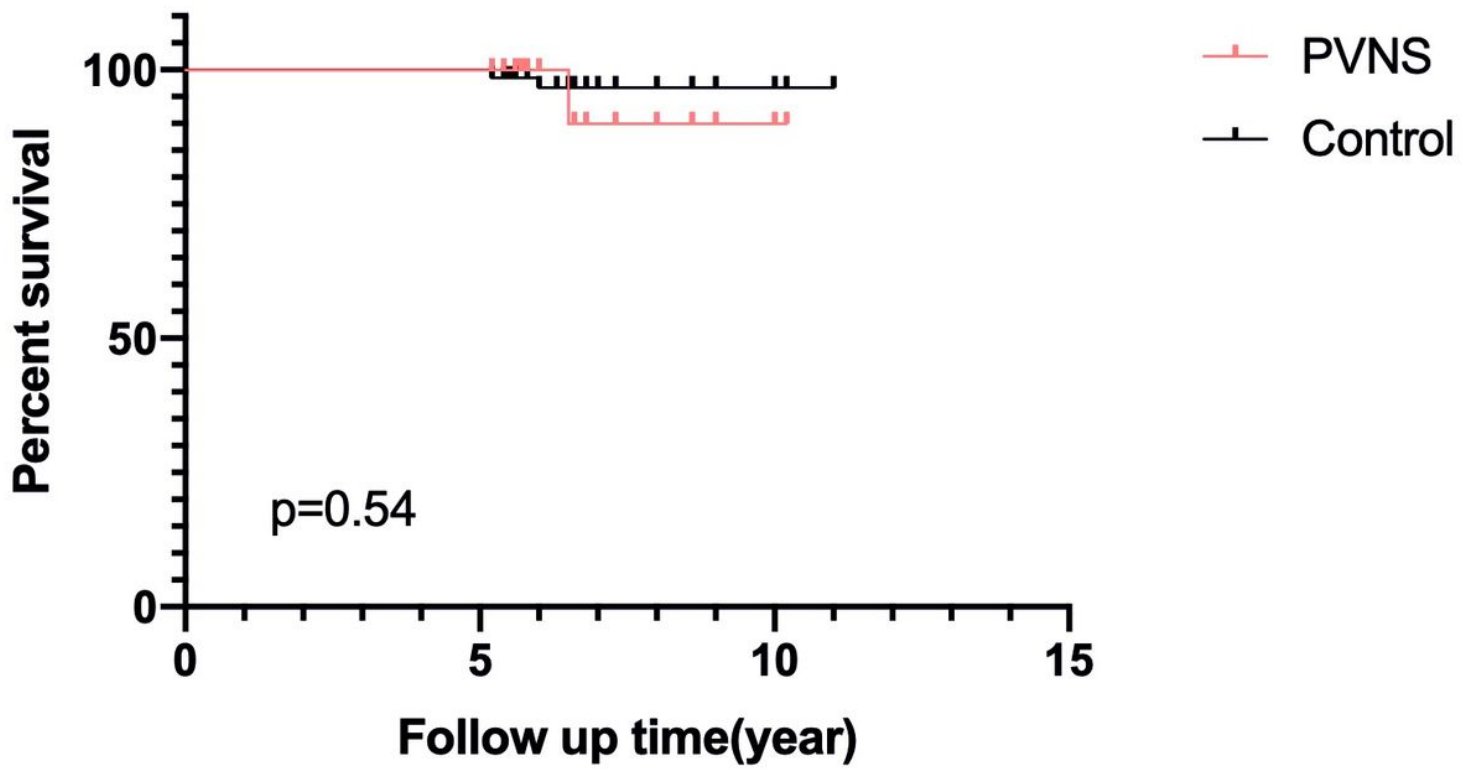


Figure 3

Kaplan-Meier implant survivorship curve of patients between the two groups