

# Nontuberculous Mycobacterial Endophthalmitis: Case Series and Review Literature

**Warinyupa Pinitpuwadol**

Mahidol University Faculty of Medicine Siriraj Hospital

**Nattaporn Tesavibul**

Mahidol University Faculty of Medicine Siriraj Hospital

**Sutasinee Boonsophon**

Mahidol University Faculty of Medicine Siriraj Hospital

**Darin Sakiyalak**

Mahidol University Faculty of Medicine Siriraj Hospital

**Sucheera Sarunket**

Mahidol University Faculty of Medicine Siriraj Hospital

**Pitipol Choopong** (✉ [pitipol.cho@mahidol.edu](mailto:pitipol.cho@mahidol.edu))

Faculty of Medicine Siriraj Hospital, Mahidol University <https://orcid.org/0000-0001-8857-8488>

---

## Research article

**Keywords:** atypical mycobacteria, non-tuberculous mycobacteria, endophthalmitis, Mycobacterium haemophilum, Mycobacterium fortuitum, Mycobacterium abscessus

**Posted Date:** March 3rd, 2020

**DOI:** <https://doi.org/10.21203/rs.3.rs-15739/v1>

**License:** © ⓘ This work is licensed under a Creative Commons Attribution 4.0 International License.

[Read Full License](#)

---

**Version of Record:** A version of this preprint was published on November 23rd, 2020. See the published version at <https://doi.org/10.1186/s12879-020-05606-2>.

# Abstract

**Background :** To report three cases of nontuberculous mycobacterial (NTM) endophthalmitis following multiple ocular surgeries and to review previous literature of NTM endophthalmitis. **Methods :** Clinical manifestation and management of patients with NTM endophthalmitis in the Department of Ophthalmology, Faculty of Medicine, Siriraj hospital, Mahidol University, Bangkok, Thailand were described. In addition, a review of previously reported cases and case series from MEDLINE was performed. The clinical information and type of NTM from the previous studies and our cases were summarized. **Results :** We reported three cases of NTM endophthalmitis caused by *M. haemophilum*, *M. fortuitum* and *M. abscessus* and a summarized review of 95 additional cases previously published. Of 98 patients, there were 85 exogenous endophthalmitis (86.7%) and 13 endogenous endophthalmitis (13.3%). The patients' age ranged from 13 to 89 years with mean of  $61.1 \pm 18.7$  years with no gender predominance. Exogenous endophthalmitis occurred in both healthy and immunocompromised hosts, mainly caused by cataract surgery (62.4%). In contrast, almost all endogenous endophthalmitis patients were either primary or secondary immunocompromised, previous history of disseminated NTM infection was identified in 38.5% of cases. Rapid growing NTMs were responsible for exogenous endophthalmitis, while endogenous endophthalmitis were commonly caused by slow growers. Initial and final vision were generally worse than 6/60. There were no significant differences of initial and final vision between exogenous and endogenous causes ( $p=1.000$ ,  $0.446$ , respectively). **Conclusions :** NTM endophthalmitis is a serious intraocular infection that leads to irreversible loss of vision. The presentation can mimic a chronic recurrent or persistent intraocular inflammation. History of multiple intraocular surgeries or immune-deficiency in patient with chronic panuveitis should raise the practitioner's suspicion of NTM endophthalmitis. Appropriate diagnosis and treatment are important to optimize visual outcome.

## Background

Nontuberculous mycobacteria (NTM) are aerobic, gram-positive bacilli found in the soil, dust, and water. NTM infection in human can be both acquired from the environment and nosocomial [1]. Based on in vitro culture properties, NTM have been divided into 4 groups by Runyon in 1959 [2]. The photochromogens (Runyon group I) grow slowly over 2–4 weeks and produce yellow pigment after light exposure. *M. marinum*, *M. kansasii*, *M. simiae*, *M. asiaticum* are majority members in this group. The scotochromogens (Runyon group II) also grow over 2–4 weeks and produce yellow-orange pigment. They include *M. scrofulaceum*, *M. szulgai*, *M. gordonae*, *M. xenophi* and *M. flavescens*. The nonphotochromogens (Runyon group III) grow over 2–4 weeks without producing pigment. The members in this group are *M. Avium*, *M. malmoense*, *M. intracellulare*, *M. terrae*, *M. haemophilum*, *M. triviale*, *M. paratuberculosis*, *M. gastri*, *M. nonchromogenicum*. The Rapid growers (Runyon group IV) include 3 subgroups; the *M. fortuitum* group, the *M. chelonae/abscessus* group, and the *M. smegmatis* group. They colony within 5 days and do not produce pigment [2].

NTM ocular infections were first reported in a case of *M. fortuitum* keratitis after corneal foreign body removal in 1965. Since then, the infections have been increasingly reported in a variety of ocular

infections range from periocular, conjunctival, scleral, corneal, orbital and intraocular infections [1, 3, 4]. Rapid growers especially *M. chelonae*, *M. fortuitum* and *M. abscessus* are the most common causes of ocular infections and generally associated with poor visual outcomes [4–11].

Being a rare intraocular infection, NTM endophthalmitis is a diagnostic and therapeutic challenge in clinical practice and the prognosis is usually poor accordingly. Herein, we reported three cases of postoperative endophthalmitis caused by different types of NTM at the Department of Ophthalmology, Faculty of Medicine, Siriraj hospital, Mahidol University, Bangkok, Thailand from January 2006 to September 2019. The first case was *M. abscessus* endophthalmitis after a cataract surgery. The second patient developed *M. fortuitum* endophthalmitis after Baerveldt shunt implantation. The third patient was *M. haemophilum* endophthalmitis following multiple trabeculectomy surgeries. The last case was also previously reported in February 2018 [12]. In addition, the literature review and summary of previous NTM endophthalmitis was performed.

## Case 1

A 55-year-old man with a previous history of pulmonary tuberculosis (TB) which was treated with a standard 6-month anti-tuberculosis treatment underwent an uneventful cataract surgery with intraocular lens (IOL) implantation of the left eye. One year postoperatively, he experienced painless visual loss in the operated eye. His vision was 6/36 in the left eye. Slit-lamp examination showed ciliary injection, 2+ cells in the anterior chamber, and posterior synechiae. There was white plaque deposited on the posterior capsule which was noted as posterior capsule opacity. The fundus examination was normal. There was no other systemic abnormality identified from the physical examination.

Initially, chronic ocular inflammation was suspected so topical corticosteroid was prescribed, and laser capsulotomy was performed. One month later, his vision decreased to hand motion. The anterior chamber showed plasmoid reaction with 4+ cells and a 1.7-mm hypopyon. Fundus examination was obscured by grade 3 vitreous haze. The B-scan ultrasound revealed heterogenous vitreous echogenicity. As a result, pars plana vitrectomy (PPV) with intravitreal injection of vancomycin was performed followed by topical vancomycin, ceftazidime, amikacin and oral ciprofloxacin. The inflammation was gradually improved. Six weeks later, the vitreous culture was identified as *M. abscessus*. The treatment regimen was changed to intravenous injection of ceftazidime and intravitreal amikacin. After 14 days of intravenous antibiotics, the treatment was changed to a 6-month course of oral clarithromycin and ciprofloxacin. The final best-corrected visual acuity (BCVA) was 6/9 in the left eye and intraocular pressure (IOP) became normal without antiglaucoma medications.

## Case 2

A 61-year-old man with uncontrolled diabetes underwent Baerveldt shunt implantation in his left eye after failures from four trabeculectomy surgeries. One year later, tube shunt exposure was found and successfully repaired with scleral and buccal mucosal graft. One month after the reparation, he

developed non-granulomatous anterior uveitis which partially responded to topical prednisolone. The investigations showed positive Quantiferon-TB gold result. He was treated as TB anterior uveitis with a standard anti-TB regimen and the inflammation improved. Three months later, he complained of blurred vision and periocular pain in the left eye. The BCVA was 6/30. The anterior segment examination demonstrated marked circumcorneal injection, however there was no sign of blebitis. There were fibrinous material occluded in the tube and 4+ cells in the anterior chamber. Fundus examination revealed prominent anterior vitreous cells and vitreous opacity.

Since these findings suggested either endophthalmitis or a progression of ocular tuberculosis, the patient underwent a diagnostic aqueous tapping. Aqueous cultures showed no organisms and the direct polymerase chain reaction (PCR) was negative for TB. Due to persistent intraocular inflammation, PPV was performed followed by multiple intravitreal injections of vancomycin and ceftazidime. Despite these treatments, the inflammation worsened with a development of hypopyon and subconjunctival pus around the tube (Fig. 1). The Baerveldt shunt was removed. Three weeks later, cultures from the aqueous were identified as *M. fortuitum*. The treatment regimen was switched to topical, subconjunctival, and intravitreal amikacin combined with intravenous amikacin, cefoxitin, levofloxacin, and oral clarithromycin. Home medication consisted of oral levofloxacin and clarithromycin for 6 months. The patient showed a good response to the treatment with the final BCVA of 6/18.

### Case 3

A 66-year-old man with uncontrolled diabetes had undergone three trabeculectomies in the left eye; the last surgery performing five years ago. Four months before this presentation, he complained of blurred vision and pain in the left eye. The condition was treated with topical and systemic corticosteroids at a local hospital. The intraocular inflammation subsided but recurred after drug discontinuation. After 4-month intermittent treatments, the patient stopped medications and sought for our opinion. At presentation, the left eye showed a poor response to light projection with plasmoid reaction in aqueous, mutton-fat keratic precipitates, and 4+ cells in the anterior chamber. The conjunctiva was injected with three flat trabeculectomy blebs. Severe vitritis with a string-of-pearls appearance was seen from a fundus examination. A diagnosis of severe panuveitis was made. Oral prednisolone was started, and the inflammation subsided.

One month later, the inferior filtering bleb became inflamed and iris fibrinous membrane and hypopyon were observed in the left eye (Fig. 2). Aqueous and vitreous aspirations were performed along with 2 intravitreal injections of vancomycin and amikacin. Due to unsuccessful results, PPV was carried out. The additional intravenous vancomycin and amikacin were given. Two days later, vitreous staining from vitrectomy sample demonstrated positive for acid-fast bacilli, however the PCR was negative for TB. The treatment was changed to intravenous imipenem, levofloxacin, and amikacin for two weeks combined with intravitreal, intracameral, and subconjunctival injections of amikacin and imipenem. The inflammation gradually improved but the vision worsened to no light perception. There was uveal tissue prolapsed through a scleral window of trabeculectomy wound. Eventually, vitreous cultures revealed *M.*

haemophilum three months later. The treatment was changed to oral azithromycin, doxycycline, and rifampicin for 12 months. Over a follow-up period, the eye gradually became phthisical (Fig. 3).

## Methods

The literature review and summary of previous NTM endophthalmitis was performed in this study. We searched in MEDLINE for related articles by using the search terms “atypical mycobacteria”, “non-tuberculous mycobacteria”, “endophthalmitis”, and “intraocular infection”. All relevant articles published in English were reviewed and summarized. Our last search was performed on September 2019.

If available, demographic data including sex, age, systemic diseases, previous ocular trauma and surgery was collected. The information about detectable NTM species, medical and surgical treatment was obtained, as well as the BCVA and complications.

All data analyses were performed using SPSS Statistics version 23 (SPSS, Inc.). Demographic data were summarized in descriptive statistics. Categorical data was shown as number and percentage, and continuous data was reported as mean  $\pm$  standard deviation. Comparison between BCVA of NTM exogenous and endogenous endophthalmitis was analyzed using Chi-Square Test. P-value of less than 0.05 was defined as statistical significance.

## Results

Up to September 2019, there were 95 cases of culture positive NTM endophthalmitis reported in the literature apart from three cases of this current study [1, 5–7, 13–54]. Demographic data of all 98 cases were shown in table 1. The age ranged from 13 to 89 years with mean age of  $61.1 \pm 18.7$  years. There were 46 males (46.9%), 49 females (50%), and the data were unavailable in three cases. The common symptoms were pain, decreased vision and redness. The clinical signs are conjunctival injection, hypopyon, anterior chamber inflammation, granulomatous keratic precipitates, vitreous inflammation, and paradoxical deterioration after steroid therapy [3, 4, 35]. Of total, exogenous endophthalmitis and endogenous endophthalmitis occurred in 85 cases (86.7%) and 13 cases (13.3%), respectively.

In exogenous endophthalmitis cases, the mean age was  $64.1 \pm 17.4$  years (range 13–89 years) and 39 patients (47.6%) were male. Endogenous endophthalmitis patients had the mean age of  $42.7 \pm 16.2$  years (range 17–67 years) and 7 (53.8%) were male.

Table 1 Demographic information of patients with Non-tuberculous mycobacterium endophthalmitis			
	Exogenous (n = 85)	Endogenous (n = 13)	Total (n = 98)
Sex			
Male	39 (45.9)	7 (53.8)	46 (46.9)
Female	43 (50.6)	6 (46.2)	49 (50.0)
Mean age in years (SD)	64.1 (17.4)	42.7 (16.2)	61.1 (18.7)
Systemic disease			
None	24 (28.2)	1 (7.7)	25 (25.5)
Human Immunodeficiency Virus infection	0	4 (30.8)	4 (4.1)
Under immunosuppressants	9 (10.6)	4 (30.8)	13 (13.3)
Diabetes mellitus	7 (8.2)	2 (15.4)	9 (9.2)
Post-organ transplantation	1 (1.2)	2 (15.4)	3 (3.1)
Immunological diseases	5 (5.9)	1 (7.7)	6 (6.1)
Cancers	4 (4.7)	1 (7.7)	5 (5.1)
SD; Standard Deviation			
<p>Exogeneous endophthalmitis occurred in 53 patients underwent cataract surgery (62.4%). Other causes of exogenous endophthalmitis included post-glaucoma drainage implant (12 cases, 14.1%), post-corneal transplantation (6 cases, 7.1%), post-intravitreal injection (2 cases, 2.4%), post-scleral buckling exposure (2 cases, 2.4%), post-vitrectomy in (2 cases, 2.4%), ocular trauma (2 cases, 2.4%), corneal ulcer (2 cases, 2.4%), post-keratoprosthesis (1 case, 1.2%), post-trabeculectomy (1 case, 1.2%), and post-laser-assisted in situ keratomileusis (LASIK) (1 case, 1.2%). The presentation started from 1 day to 60 months with a median interval of 1 month after the surgery. From available information on systemic immunological conditions, 16 (18.8%) of exogenous endophthalmitis patients were immunocompromised.</p>			
<p>Of 13 endogenous endophthalmitis patients, 4 (30.8%) were HIV infected and 2 (15.4%) had diabetes mellitus. Four of them (30.8%) received immunosuppressive agents due to autoimmune disease, organ transplantations, or cancers. Only one case (7.7%) was a healthy host. Among endogenous endophthalmitis cases, 5 (38.5%) had history of disseminated mycobacterial infection prior to intraocular infection. One patient (7.7%) had previous history of lymph node tuberculosis. There were 4 patients (30.8%) who had unknown source of primary infection. The others (23.1%) did not have data of previous systemic illness. The median duration between the onset of systemic infection and ocular presentation was 3 months which ranged from 15 days to 3 months. (Table 2)</p>			

<b>Table 2 Primary source of infection of Non-tuberculous mycobacterium endophthalmitis</b>		
	Exogenous (n = 85)	Endogenous (n = 13)
Systemic infections		
Previously disseminated mycobacterial infection	-	5 (38.5%)
Lymph node tuberculosis	-	1 (7.7%)
Unknown source	-	4 (30.8%)
Not mentioned	-	3 (23.1%)
Ocular diseases or injuries		
Cataract surgery	53 (62.4)	-
Glaucoma drainage device	12 (14.1)	-
Corneal transplantation	6 (7.1)	-
Corneal ulcer	2 (2.4)	-
Intravitreal injection	2 (2.4)	-
Scleral buckling	2 (2.4)	-
Trauma	2 (2.4)	-
Vitrectomy	2 (2.4)	-
Keratoprosthesis	1 (1.2)	-
Laser-assisted in situ keratomileusis (LASIK)	1 (1.2)	-
Trabeculectomy	1 (1.2)	-
Not mentioned	1 (1.2)	-

From our reviewed data, positive cultures were found in vitreous (38/98, 38.8%), aqueous (56/98, 57.1%), corneal tissue (8/98, 8.2%), or eviscerated tissue (4/98, 4.1%). In cases of post-operative endophthalmitis, NTM was also found in the removed intraocular devices (6/85, 7.1%). The duration between the onsets of ocular infection to final diagnosis varied from 3 days to 12 months with a median of 18 days. The causative organism in exogenous endophthalmitis was mainly identified as rapid growers; *M. chelonae-abscessus* group in 65 patients (76.5%), *M. fortuitum* in 10 patients (11.8%), *M. manitobense* in 2 patients (2.4%), and *M. goodii* in 1 patient (1.2%). The rests were slow growers; *M. gordonae* in 1 patient (1.2%), *M. haemophilum* in 1 patient (1.2%), and *M. terrae* in 1 patient (1.2%). On the other hand, the majority of pathogen in endogenous endophthalmitis was slow growers; *M. avium* in 4 patients (30.8%), *M. kansasii* in 1 patient (7.7%), *M. haemophilum* in 1 patient (7.7%), and *M. triplex* in 1 patient (7.7%).

There was 1 patient (7.7%) with mixed infection of *M. fortuitum* and *M. bovis*. The only rapid grower, *M. chelonae*, was identified in 1 patient (7.7%). (Table 3)

<b>Table 3 Non-tuberculous mycobacterium species identified in endophthalmitis</b>		
	Exogenous (n = 85)	Endogenous (n = 13)
Rapid growers		
<i>M. chelonae</i> /abscessus group	65 (76.5)	1 (7.7)
<i>M. fortuitum</i>	10 (11.8)	0
<i>M. goodii</i>	1 (1.2)	0
<i>M. manitobense</i>	2 (2.4)	0
Slow growers		
<i>M. avium</i>	0	4 (30.8)
<i>M. kansasii</i>	0	1 (7.7)
<i>M. triplex</i>	0	1 (7.7)
<i>M. haemophilum</i>	1 (1.2)	1 (7.7)
<i>M. gordonae</i>	1 (1.2)	0
<i>M. terrae</i>	1 (1.2)	0
Mixed infection		
<i>M. fortuitum</i> and <i>M. bovis</i>	0	1 (7.7)
Unspecified species	4 (4.7)	4 (30.8)

The treatment information was retrieved from 75 exogenous and 8 endogenous endophthalmitis patients. In exogenous endophthalmitis, systemic treatment was given in 51 patients (68.0%) including macrolides (40 patients), aminoglycosides (19 patients), fluoroquinolones (13 patients), cephalosporins (8 patients), beta-lactams (3 patients), vancomycin (3 patients), and clindamycin (1 patient). Local antibiotics (subconjunctival, intracameral, or intravitreal injection) were administered in 65 cases (86.7%) including aminoglycosides (56 patients), vancomycin (49 patients), cephalosporins (31 patients), fluoroquinolones (2 patients), and beta-lactams (1 patients). The final regimens were mainly macrolides, fluoroquinolones and aminoglycosides with a duration ranged from 1 week to 12 months.

Of 8 endogenous endophthalmitis patients, systemic treatment was administered in 6 patients (75.0%) included macrolides (4 patients), fluoroquinolones (4 patients), beta-lactams (2 patients), and aminoglycosides (1 patients). Local antibiotics were given in 4 cases (50.0%). All of them received



aminoglycosides. Cephalosporins were used in 1 patient. The final regimen was either macrolides or fluoroquinolones with a duration ranged from 3 weeks to 9 months.

Additional surgeries were performed to get rid of infection in several cases. PPV was done in 52 exogenous endophthalmitis patients (61.2%) and 4 endogenous endophthalmitis patients (30.8%). Enucleation was performed in 17 exogenous endophthalmitis patients (20.0%) and 3 endogenous endophthalmitis patients (23.1%). In exogenous endophthalmitis cases, 39 of them (45.9%) underwent implant removal. (Table 4)

<b>Table 4 Treatment summary of Non-tuberculous mycobacterium endophthalmitis</b>		
	Exogenous n (%)	Endogenous n (%)
Medical treatments		
Systemic	51 (68.0)	6 (75.0)
Local*	65 (86.7)	4 (50.0)
Surgical treatments		
Pars plana vitrectomy	52 (61.2)	4 (30.8)
Enucleation, evisceration	17 (20.0)	3 (23.1)
Device removal	39 (45.9)	-
*Local antibiotics; intravitreal, subconjunctival, and intracameral injection		

In exogenous endophthalmitis, median of initial and final BCVA were finger counting and hand movement, respectively. The initial BCVA were better than 6/60 in 20 patients (29.9%) and worse than 6/60 in 47 patients (70.1%). The final BCVA were better than 6/60 in 21 patients (25.6%) and worse than 6/60 in 61 patients (74.4%). Complications occurred in 30 patients (30.6%); hypotony or phthisis in 18 patients (21.2%), retinal detachment in 5 patients (5.9%), secondary glaucoma in 3 patients (3.5%), corneal perforation in 3 patients (3.5%), and optic atrophy in 2 patients (2.4%).

In endogenous endophthalmitis, median of initial BCVA was 6/60 and median of final BCVA was no light perception. There were 2 patients (33.3%) with BCVA better than 6/60 and 4 patients (66.7%) with BCVA worse than 6/60 at the beginning. At the final visit, 1 patient (11.1%) gained BCVA better than 6/60 and 8 patients (88.9%) had BCVA worse than 6/60. Complications occurred in 5 patients (38.5%); hypotony or phthisis in 3 patients (23.1%), retinal detachment in 1 patient (7.7%), secondary glaucoma in 1 patient (7.7%), and corneal perforation in 1 patient (7.7%). There were no significant differences of initial and final BCVA between both types of NTM endophthalmitis ( $p = 1.000, 0.446$ , respectively). (Table 5)

<b>Table 5 Clinical outcome of Non-tuberculous mycobacterium endophthalmitis</b>			
	Exogenous n (%)	Endogenous n (%)	p-value*
Initial best-corrected visual acuity			1.000
6/6–6/60	20 (29.9)	2 (33.3)	
> 6/60	47 (70.1)	4 (66.7)	
Final best-corrected visual acuity			0.446
6/6–6/60	21 (25.6)	1 (11.1)	
> 6/60	61 (74.4)	8 (88.9)	
Complications	30 (30.6)	5 (38.5)	
Hypotony, phthisis	18 (21.2)	3 (23.1)	
Retinal detachment	5 (5.9)	1 (7.7)	
Glaucoma	3 (3.5)	1 (7.7)	
Corneal perforation	3 (3.5)	1 (7.7)	
Optic atrophy	2 (2.4)	0	
*Chi-square test			

## Discussion

Since the first reported case of NTM endophthalmitis in 1973, the organism had been increasingly reported because of improved microbiological diagnostic methods and enlarged immunocompromised hosts in recent years [39].

In this review, endophthalmitis caused by NTM equally occurred in both males and females. The age of onset was approximately in the fourth to sixth decades of life. NTM exogenous endophthalmitis could occur after uneventful ocular surgery, even in healthy hosts. The infection often occurred within 1 month after ocular surgery. Cataract surgery was accounted for the most common procedure related to the infection. On the other hand, NTM endogenous endophthalmitis mainly took place in immunocompromised patients especially those with history of mycobacterial systemic infection.

Overall demographic data did not change from previous reviews of ocular NTM infections. In 2015, Kheir et al reported that NTM endophthalmitis had no gender differences and the median age of presentation was 44 years. Among all exogenous endophthalmitis patients, the infection usually occurred after ocular intervention which 48.6% was cataract surgery with an average time of 11.5 weeks after ocular surgery [3]. In 2012, Moorthy et al reported an average period of 1 month after a procedure, while all endogenous

endophthalmitis cases were either iatrogenic or acquired immunosuppression [4]. Likewise, Kheir et al reported that more than half (60.0%) of endogenous endophthalmitis cases was associated with immunodeficiency status and previous disseminated mycobacterial infection [3].

The most common causative pathogens of ocular infections are rapidly growing NTMs. *M. abscessus*, *M. chelonae*, and *M. fortuitum* are responsible for the majority of cases [3, 4]. However, in this review, we found that most of exogenous endophthalmitis cases were caused by rapid growers, while slow growing NTMs were leading causes of endogenous endophthalmitis. According to different natures of NTMs, slow growers are generally found in pulmonary and lymph node diseases [55]. Along with immunocompromised state of hosts leading to susceptibility for systemic spreading, this could explain why slow growing NTMs were apparently related with endogenous endophthalmitis in this study.

In addition to the published literature, there were three exogenous endophthalmitis cases reported from our hospital; *M. abscessus*, *M. fortuitum*, and *M. haemophilum* endophthalmitis. All of them were male in fifth to sixth decade similar to previously reported cases. Two rapid growers (*M. abscessus* and *M. fortuitum*) were identified early after laser capsulotomy and reparation of exposed tube shunt respectively, while a slow grower NTM, *M. haemophilum*, was found late in a case with multiple trabeculectomies. Despite the types of organism, the onset of these cases was gradual, and the clinical manifestation was subtle at the beginning mimicking chronic uveitis. Their presentation misled the ophthalmologists resulting in delayed investigation and treatment.

*M. abscessus* belongs to *M. Chelonae/abscessus* group. Its identification was relying on identification methods, such as PCR restriction analysis and DNA sequencing [56]. Among the NTMs, *M. chelonae-abscessus* group was known as having the highest resistant rate to antibiotics and anti-tuberculous drugs due to the formation of biofilm [37, 56].

The onset of *M. chelonae/abscessus* endophthalmitis varied from immediate to 3 years after operation and the infection generally presented with chronic granulomatous inflammation. In post-cataract surgery, corneal infiltration around the cataract wound and white plaque-like material on the intraocular lens implant had been observed [5]. The same pattern was observed in our patient. In the previous literature, *M. chelonae/abscessus* group was generally associated with poor visual outcomes [5]. Total of 82.3% of cases ended up with visual impairment, evisceration, enucleation, or phthisis. The poor prognosis is due to delay diagnosis and treatment and the organism's ability to form a biofilm [1, 6, 9]. The diagnosis of our case was made within 6 weeks after capsulotomy which caused acute active inflammation. This presentation led to early vitrectomy resulting in a successful treatment. From literature review, there were only 11 eyes that showed final BCVA of 6/60 or better [7, 20, 29, 31, 38, 40, 42, 46, 51]. Stewart et al reported a case of *M. abscessus* endophthalmitis with a full visual recovery [49].

*M. fortuitum* endophthalmitis was reported in 11 cases previously. The incubation period ranged from 10 days to 20 months [1, 7, 21, 27, 40, 43, 44]. As a rapid growing nature, our patient had the onset of 1 month postoperatively. The progression of disease and the clinical findings were similar to almost all reported cases. At early stage, with surgical repair of exposed shunt, infectious uveitis could not be

excluded. However, the treatment of this patient was misled by false positive Quantiferon-TB test and treated partially with standard anti-tuberculosis drugs. The suspicion of NTM infection was made after clinical worsening despite anti-tuberculosis and anti-bacterial treatment, and the organism was identified 3 weeks after aqueous aspiration. Despite the delay in diagnosis, the patient ended with favorable vision. Similarly, from a review, 6 eyes (54.5%) of *M. fortuitum* endophthalmitis gained final BCVA of 6/60 or better [7, 27, 40, 43].

*M. haemophilum* endophthalmitis in our patient was previously reported to be the first case of postoperative endophthalmitis in the literature [12]. In 2007, Modi et al reported the first case of disseminated *M. haemophilum* infection in a patient with immunosuppressive medication after a cardiac transplantation [41, 57, 58]. He had the gradual course of ocular infection with multiple skin nodules before turning into a suppurative endophthalmitis and finally enucleated. Our patient also had similar clinical course which ended up with purulent endophthalmitis and visual loss despite combination of intraocular and systemic antimicrobial treatment.

NTM endophthalmitis has a variable of clinical syndrome which can mimic chronic intraocular inflammation and makes initial confusion with other low virulent bacterial and fungal infection [10]. Misdiagnosis with other organisms has been commonly reported before the final diagnosis [33]. Clinical suspicion of NTM infections is necessary especially in immunocompromised patients, with chronic granulomatous intraocular inflammation and intermittent response with anti-inflammatory drugs. Repeat vitreous and aqueous cultures are required to identify the causative organism in which determines the choice of antibiotics. The treatment of NTM endophthalmitis includes the combination of local and systemic antibiotic therapy with or without surgical removal of the implants. The patient who does not response to medical treatment or has an ocular implant is considered surgical therapeutic interventions [3, 10].

Specific guidelines for antibiotics and duration of treatment are still unestablished. The regimen is based on drug sensitivity information and clinical response. Standard anti-tuberculosis drugs such as isoniazid, rifabutin, rifampin, ethambutol, and streptomycin are commonly prescribed. However, NTM are often resistant to these regimens and alternative antimicrobials have emerging roles for NTMs infection due to the potency, pharmacokinetic property, and safety. Especially among rapidly growing NTM, a combination of aminoglycosides, fluoroquinolones and macrolides has shown successful outcome [3, 8, 10]. On the other hand, slow growers are more sensitive to anti-tuberculosis drugs [4].

There are some mentionable limitations. As NTM endophthalmitis is an uncommon condition, this review was a collection of case reports and case series. Nevertheless, we summarized all available information and demonstrated the characteristics as well as the causative pathogens and the outcomes of NTM endophthalmitis. Lack of required details from the literature review and inaccessibility of non-English data could miss some incomplete information.

## Conclusions

NTM endophthalmitis is rare but can lead to vision-threatening complications. It can imitate chronic intraocular inflammation, so it usually is misdiagnosed as inflammatory uveitis or endophthalmitis caused by other common pathogens. Although the prognosis for NTM endophthalmitis is poor despite invasive treatment, appropriate samples for microbiological identification and suitable treatment regimen are required for preventing the infections from progression to detrimental outcomes. The recommended therapy is a combination of two or more antibiotics based on culture susceptibility. Surgical intervention can be done in case of failure medical treatment or infection control. However, the precise diagnostic yields and therapeutic managements for NTM are still challenging.

## List Of Abbreviations

NTM: Non-tuberculous mycobacteria, M. haemophilum: Mycobacterium haemophilum, M. fortuitum: Mycobacterium fortuitum, M. abscessus: Mycobacterium abscessus, TB: tuberculosis, IOL: intraocular lens, IOP: intraocular pressure, HIV: human immunodeficiency virus, DM: diabetes mellitus, LASIK: laser-assisted in situ keratomileusis, PPV: pars plana vitrectomy, PCR: polymerase chain reaction, BCVA: best-corrected visual acuity

## Declarations

### Ethics approval and consent to participate

The study was in accordance with the tenets of the Declaration of Helsinki and was approved by the Committee for the Protection of Human Participants in Research of the Faculty of Medicine Siriraj Hospital, Mahidol University (COA no. Si 419/2017).

### Consent for publication

Written informed consent was obtained from the patient for publication of the case report. A copy of the written consent is available for review by the Editor of this journal.

### Availability of data and materials

The data that support the findings of this study are available from the corresponding author (PC) upon reasonable request.

### Competing interests

The authors declare that they have no competing interests.

### Funding

No funding to declare in this study.

### Authors' contributions

SS, WP, and PC collected medical information and drafted the article. WP and PC did the literature review and wrote the manuscript. All authors revised the manuscript and approved the final version of the manuscript.

## Acknowledgements

The authors acknowledge Wilawan Sanpan from Research Division, Faculty of Medicine Siriraj Hospital, Mahidol University, Bangkok, Thailand; for preparing the manuscript.

## References

1. Paulose RM, Joseph J, Narayanan R, Sharma S. Clinical and microbiological profile of non-tuberculous mycobacterial endophthalmitis-experience in a tertiary eye care centre in Southern India. *J Ophthalmic Inflamm Infect*. 2016;6:27.
2. Runyon EH. Anonymous mycobacteria in pulmonary disease. *Med Clin North Am*. 1959;43:273-90.
3. Kheir WJ, Sheheitli H, Abdul Fattah M, Hamam RN. Nontuberculous Mycobacterial Ocular Infections: A Systematic Review of the Literature. *Biomed Res Int*. 2015;2015:164989.
4. Moorthy RS, Valluri S, Rao NA. Nontuberculous mycobacterial ocular and adnexal infections. *Surv Ophthalmol*. 2012;57:202-35.
5. Matieli LC, De Freitas D, Sampaio J, Moraes NS, Yu MC, Hofling-Lima AL. Mycobacterium abscessus endophthalmitis: treatment dilemma and review of the literature. *Retina*. 2006;26:826-9.
6. Rolfe NE, Garcia C, Widen RH, Taylor SP. Rapid diagnosis of Mycobacterium abscessus endophthalmitis. *J Med Microbiol*. 2013;62:1089-91.
7. Shah M, Relhan N, Kuriyan AE, Davis JL, Albini TA, Pathengay A, et al. Endophthalmitis Caused by Nontuberculous Mycobacterium: Clinical Features, Antimicrobial Susceptibilities, and Treatment Outcomes. *Am J Ophthalmol*. 2016;168:150-6.
8. Brown-Elliott BA, Mann LB, Hail D, Whitney C, Wallace RJ, Jr. Antimicrobial susceptibility of nontuberculous mycobacteria from eye infections. *Cornea*. 2012;31:900-6.
9. Faria S, Joao I, Jordao L. General Overview on Nontuberculous Mycobacteria, Biofilms, and Human Infection. *J Pathog*. 2015;2015:809014.
10. Garg P. Fungal, Mycobacterial, and Nocardia infections and the eye: an update. *Eye (Lond)*. 2012;26:245-51.
11. Girgis DO, Karp CL, Miller D. Ocular infections caused by non-tuberculous mycobacteria: update on epidemiology and management. *Clin Exp Ophthalmol*. 2012;40:467-75.
12. Pinitpuwadol W, Sarunket S, Boonsopon S, Tesavibul N, Choopong P. Late-onset postoperative Mycobacterium haemophilum endophthalmitis masquerading as inflammatory uveitis: a case report. *BMC Infect Dis*. 2018;18:70.
13. Ambler JS, Meisler DM, Zakov ZN, Hall GS, Spech TJ. Endogenous Mycobacterium chelonae endophthalmitis. *Am J Ophthalmol*. 1989;108:338-9.

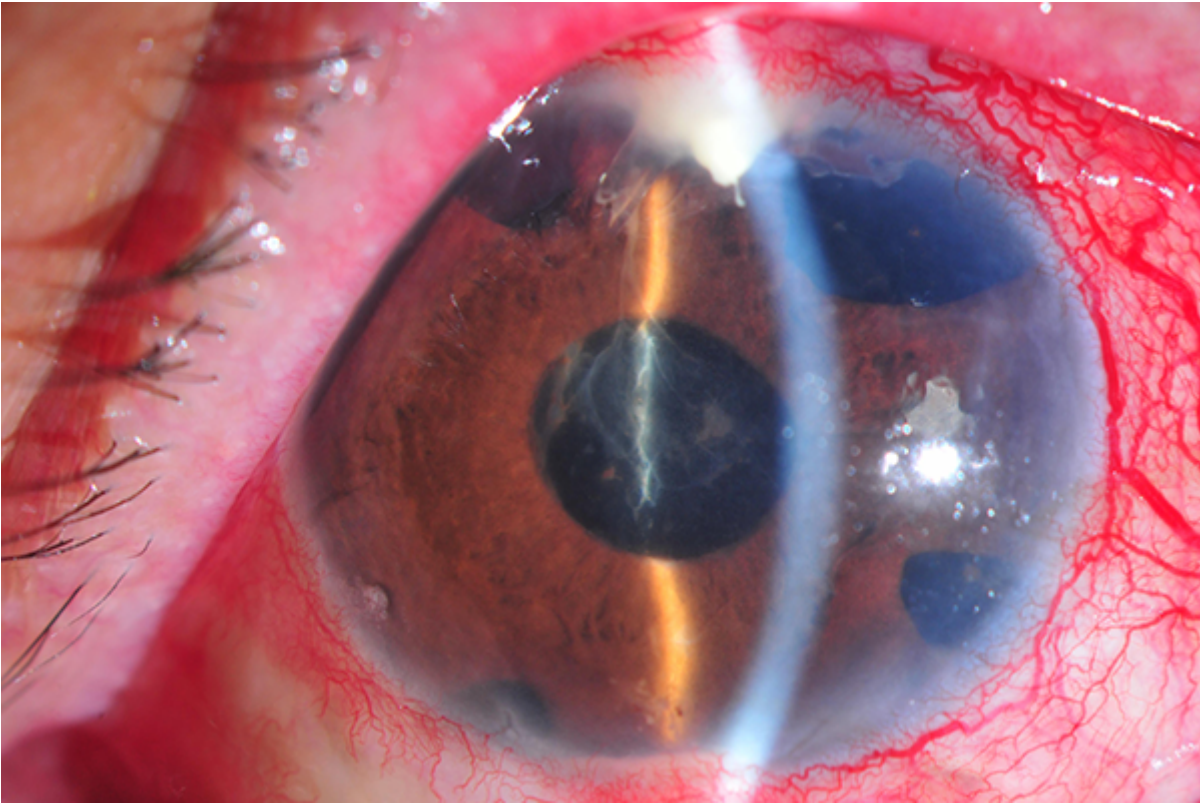
14. Benz MS, Murray TG, Dubovy SR, Katz RS, Eifrig CW. Endophthalmitis caused by *Mycobacterium chelonae* abscessus after intravitreal injection of triamcinolone. *Arch Ophthalmol*. 2003;121:271-3.
15. Cohen JI, Saragas SJ. Endophthalmitis due to *Mycobacterium avium* in a patient with AIDS. *Ann Ophthalmol*. 1990;22:47-51.
16. El-Asrar AMA, Tabbara KF. Chronic endophthalmitis after extracapsular cataract extraction caused by *Mycobacterium chelonae* subspecies abscessus. *Eye*. 1995;9:798-801.
17. Gedde SJ, Scott IU, Tabandeh H, Luu KK, Budenz DL, Greenfield DS, et al. Late endophthalmitis associated with glaucoma drainage implants. *Ophthalmology*. 2001;108:1323-7.
18. Gobels K, Best J, Oette M, MacKenzie CR, Hemker J, Wenning M, et al. Ocular infection caused by *Mycobacterium kansasii* in an AIDS patient. *AIDS*. 2002;16:2501-2.
19. Grenzebach UH, Busse H, Totsch M, Dockhorn-Dworniczak B. Endophthalmitis induced by atypical mycobacterial infection. *Ger J Ophthalmol*. 1996;5:202-6.
20. Marin-Casanova P, Calandria Amiguetti JL, Garcia-Martos P, Lozano Dominguez C, Sanabria BH, Puerto Alonso JL, et al. Endophthalmitis caused by *Mycobacterium abscessus*. *Eur J Ophthalmol*. 2003;13:800-
21. Mutyala S, Dieckert JP, Papasian CJ. *Mycobacterium fortuitum* endophthalmitis. *Retina*. 1996;16:122-4.
22. Ramaswamy AA, Biswas J, Bhaskar V, Gopal L, Rajagopal R, Madhavan HN. Postoperative *Mycobacterium chelonae* endophthalmitis after extracapsular cataract extraction and posterior chamber intraocular lens implantation. *Ophthalmology*. 2000;107:1283-6.
23. Rosenbaum PS, Mbekeani JN, Kress Y. Atypical mycobacterial panophthalmitis seen with iris nodules. *Arch Ophthalmol*. 1998;116:1524-7.
24. Roussel TJ, Stern WH, Goodman DF, Whitcher JP. Postoperative mycobacterial endophthalmitis. *Am J Ophthalmol*. 1989;107:403-6.
25. Stephenson G, Sanders J, Breazeale R, DiStefano D. Mycobacterial Endophthalmitis after LASIK. *Investigative Ophthalmology & Visual Science*. 2002;43:4442-.
26. Uy HS, Nguyen QD, Durand ML, Paton B, Foster CS. Infectious crystalline keratopathy and endophthalmitis secondary to *Mycobacterium abscessus* in a monocular patient with Stevens-Johnson syndrome. *Am J Ophthalmol*. 1999;127:209-10.
27. Valenton M. Wound infection after cataract surgery. *Jpn J Ophthalmol*. 1996;40:447-55.
28. Wassermann HE. Avian tuberculosis endophthalmitis. *Arch Ophthalmol*. 1973;89:321-3.
29. Barkmeier AJ, Salomao DM, Baratz KH. Management of *Mycobacterium Chelonae* Endophthalmitis with Complete Surgical Debridement. *Retina*. 2016;36:2440-2.
30. Benz MS, Scott IU, Flynn HW, Jr., Unonius N, Miller D. Endophthalmitis isolates and antibiotic sensitivities: a 6-year review of culture-proven cases. *Am J Ophthalmol*. 2004;137:38-42.
31. Chang V, Karp CL, Yoo SH, Ide T, Budenz DL, Kovach JL, et al. *Mycobacterium abscessus* endophthalmitis after Descemet's stripping with automated endothelial keratoplasty. *Cornea*.

- 2010;29:586-9.
32. Couto C, Rossetti S, Schlaen A, Hurtado E, D'Alessandro L, Goldstein DA. Chronic postoperative *Mycobacterium gordonae* endophthalmitis in a patient with phakic intraocular lens. *Ocul Immunol Inflamm.* 2013;21:491-4.
  33. Dave VP, Ambiya V, Nirmalkar K, Reddy GS, Sharma S. *Mycobacterium* *Manitobense* Masquerading as *Corynebacterium Pseudodiphtheriticum* in a Case of Postcataract Surgery Endophthalmitis. *Retin Cases Brief Rep.* 2016;10:316-9.
  34. Deobhakta AA, Young R, Banitt M, Albin TA, Smiddy WE, Flynn Jr HW. Endophthalmitis associated with Baerveldt Glaucoma Drainage Devices. *Investigative Ophthalmology & Visual Science.* 2012;53:1686.
  35. Durand ML, Dohlman CH. Successful prevention of bacterial endophthalmitis in eyes with the Boston keratoprosthesis. *Cornea.* 2009;28:896-901.
  36. Henry CR, Flynn HW, Jr., Miller D, Forster RK, Alfonso EC. Infectious keratitis progressing to endophthalmitis: a 15-year study of microbiology, associated factors, and clinical outcomes. *Ophthalmology.* 2012;119:2443-9.
  37. Hung JH, Huang YH, Chang TC, Tseng SH, Shih MH, Wu JJ, et al. A cluster of endophthalmitis caused by *Mycobacterium abscessus* after cataract surgery. *J Microbiol Immunol Infect.* 2016;49:799-803.
  38. Jain V, Garg P, Sharma S, Vemuganti GK. Sutureless wound infection by unusual acid-fast organisms. *Cornea.* 2008;27:615-8.
  39. Lalitha P, Rathinam SR, Srinivasan M. Ocular infections due to non-tuberculous mycobacteria. *Indian J Med Microbiol.* 2004;22:231-7.
  40. Medina CA, Butler MR, Deobhakta AA, Banitt MR, Albin TA, Smiddy WE, et al. Endophthalmitis Associated With Glaucoma Drainage Implants. *Ophthalmic Surg Lasers Imaging Retina.* 2016;47:563-9.
  41. Modi D, Pyatetsky D, Edward DP, Ulanski LJ, Pursell KJ, Tessler HH, et al. *Mycobacterium haemophilum*: a rare cause of endophthalmitis. *Retina.* 2007;27:1148-51.
  42. Mohan N, Kar S, Padhi TR, Basu S, Sharma S, Das TP. Changing profile of organisms causing scleral buckle infections: a clinico-microbiological case series. *Retina.* 2014;34:247-53.
  43. Palani D, Kulandai LT, Naraharirao MH, Guruswami S, Ramendra B. Application of polymerase chain reaction-based restriction fragment length polymorphism in typing ocular rapid-growing nontuberculous mycobacterial isolates from three patients with postoperative endophthalmitis. *Cornea.* 2007;26:729-35.
  44. Rao A, Wallang B, Padhy TR, Mittal R, Sharma S. Dual infection by streptococcus and atypical mycobacteria following Ahmed glaucoma valve surgery. *Semin Ophthalmol.* 2013;28:233-5.
  45. Scott IU, Lieb DF, Flynn HW, Jr., Dessouki A, Murray TG, Miller D. Endophthalmitis caused by *Mycobacterium chelonae*: selection of antibiotics and outcomes of treatment. *Arch Ophthalmol.* 2003;121:573-6.



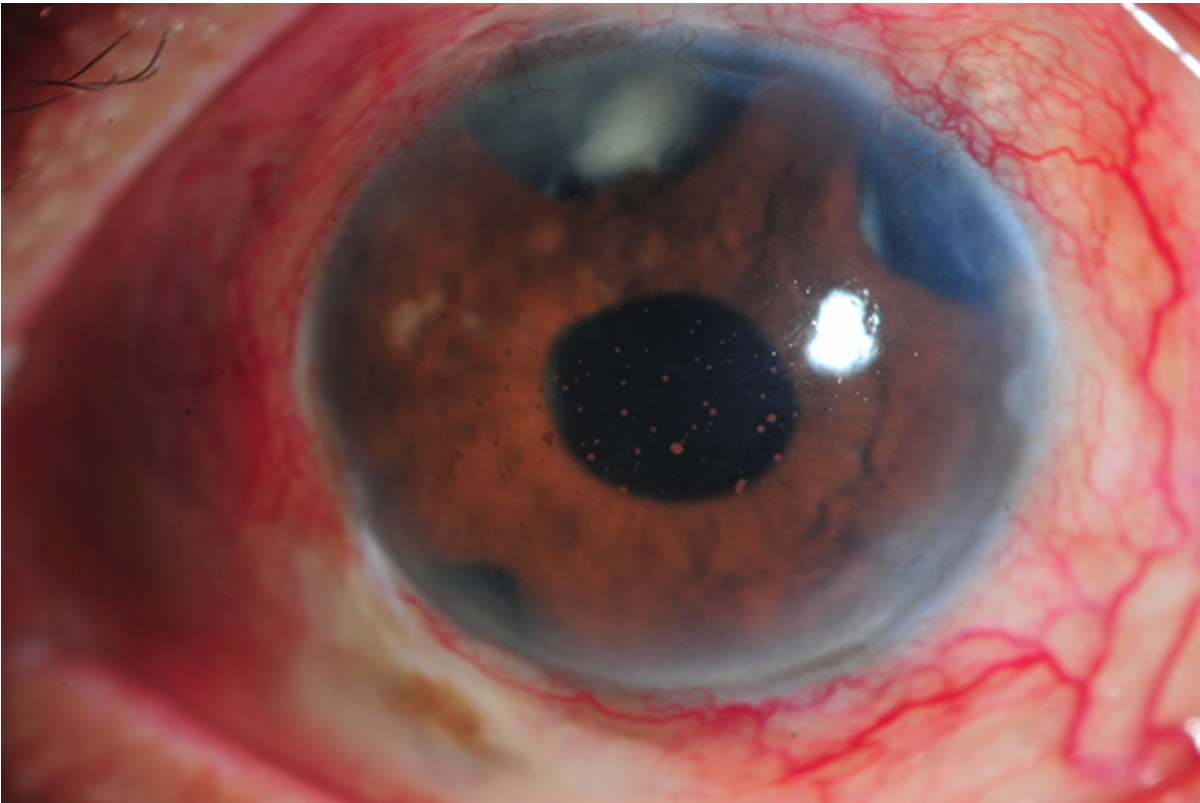
46. Shirodkar AR, Pathengay A, Flynn HW, Jr., Albini TA, Berrocal AM, Davis JL, et al. Delayed- versus acute-onset endophthalmitis after cataract surgery. *Am J Ophthalmol*. 2012;153:391-8 e2.
47. Sinawat S, Yospaiboon Y, Sinawat S. Bilateral endogenous endophthalmitis in disseminated NTM infection: a case report. *J Med Assoc Thai*. 2011;94:632-6.
48. Spencer TS, Teske MP, Bernstein PS. Postcataract endophthalmitis caused by *Mycobacterium goodii*. *J Cataract Refract Surg*. 2005;31:1252-3.
49. Stewart MW, Alvarez S, Ginsburg WW, Shetty R, McLain WC, Sleater JP. Visual recovery following *Mycobacterium chelonae* endophthalmitis. *Ocul Immunol Inflamm*. 2006;14:181-3.
50. Sungkanuparph S, Sathapatayavongs B, Prachartam R. Infections with rapidly growing mycobacteria: report of 20 cases. *Int J Infect Dis*. 2003;7:198-205.
51. Venkateswaran N, Yeane G, Chung M, Hindman HB. Recurrent nontuberculous mycobacterial endophthalmitis: a diagnostic conundrum. *Clin Ophthalmol*. 2014;8:837-42.
52. Wilhelmus KR. Nontuberculous mycobacterial endophthalmitis. *Arch Ophthalmol*. 2003;121:1663.
53. Hsu CR, Chen JT, Yeh KM, Hsu CK, Tai MC, Chen YJ, et al. A cluster of nontuberculous mycobacterial endophthalmitis (NTME) cases after cataract surgery: clinical features and treatment outcomes. *Eye (Lond)*. 2018;32:1504-11.
54. Hung JH, Ko WC, Chen CY, Lin SH, Wu CL, Hsu SM, et al. Postoperative *Mycobacteroides abscessus* subsp. *abscessus* endophthalmitis: Clinical analysis of 12 clustered adults and a proposed therapeutic algorithm. *J Microbiol Immunol Infect*. 2019.
55. Tortoli E. Clinical manifestations of nontuberculous mycobacteria infections. *Clin Microbiol Infect*. 2009;15:906-10.
56. Yakus MA, Hernandez SM, Floyd MM, Sikes D, Butler WR, Metchock B. Comparison of methods for Identification of *Mycobacterium abscessus* and *M. chelonae* isolates. *J Clin Microbiol*. 2001;39:4103-10.
57. Kelley CF, Armstrong WS, Eaton ME. Disseminated *Mycobacterium haemophilum* infection. *The Lancet infectious diseases*. 2011;11:571-8.
58. Lindeboom JA, van Coppenraet LEB, van Soolingen D, Prins JM, Kuijper EJ. Clinical manifestations, diagnosis, and treatment of *Mycobacterium haemophilum* infections. *Clinical microbiology reviews*. 2011;24:701-17.

## Figures



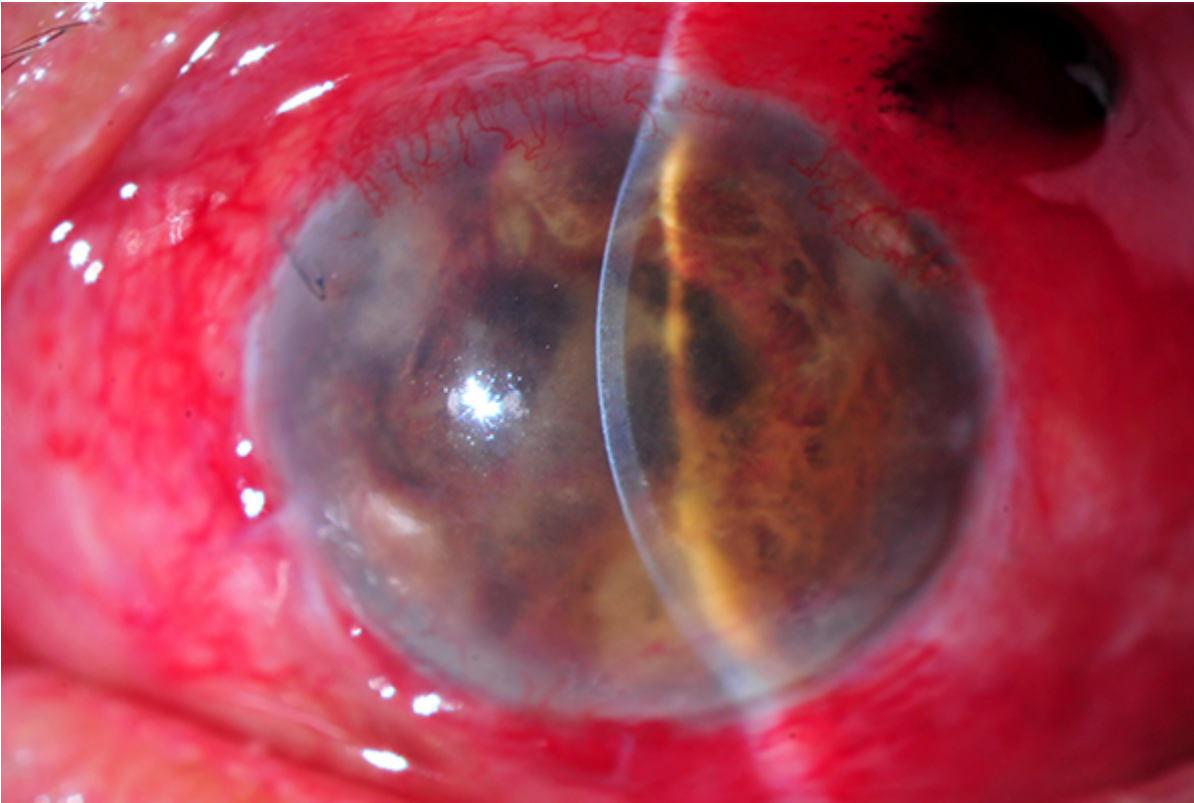
**Figure 1**

Slit lamp examination of *Mycobacterium fortuitum* endophthalmitis (case 2) demonstrating fibrinous material in the anterior chamber with subconjunctival pus around the tube.



**Figure 2**

Slit lamp examination of *Mycobacterium haemophilum* endophthalmitis (case 3) at initial presentation demonstrating three flat trabeculectomy blebs with plasmoid aqueous and large mutton fat keratic precipitates in the anterior chamber.



**Figure 3**

Slit lamp examination of *Mycobacterium haemophilum* endophthalmitis (case 3) at three months after initial presentation revealed phthisic eye with prolapsed uveal tissue through a superotemporal area of trabeculectomy wound.