

An improved morphological staging method of midpalatal suture and its relationship with cervical vertebra maturation (CVM) method

Lu Gao

Peking University School of Stomatology

Yan Gu (✉ guyan96@126.com)

Peking University School and Hospital of Stomatology <https://orcid.org/0000-0003-0108-4325>

Research article

Keywords: Midpalatal Suture; Cervical Vertebra Maturation (CVM) method; Rapid Maxillary Expansion

Posted Date: February 28th, 2020

DOI: <https://doi.org/10.21203/rs.2.24815/v1>

License:   This work is licensed under a Creative Commons Attribution 4.0 International License.

[Read Full License](#)

Abstract

Background (1) Establish an improved morphological staging method of midpalatal suture. (2) Investigate the correlation between morphological stages of midpalatal suture (MPS stage) and cervical vertebrae maturation (CVM) stages. (3) Compare effects of traditional tooth-borne rapid maxillary expansion (RME) at different MPS stages. Methods 1076 CBCT images (675 females, 401 males, 6.0 to 21.0 years old) are included. MPS stages are classified based on observation of horizontal view. Correlation between MPS stage and CVM stage are investigated by Spearman correlation coefficient and diagnostic test analysis. Effects of traditional tooth-borne RME at different MPS stages were analyzed based on pre- and post-expansion dental casts. Results Five stages of midpalatal suture are established. Spearman coefficient between MPS stage and CVM stage is 0.803. Diagnostic pairs with the largest area under ROC curve (AUC) value are: CS 6 - MPS 5, CS 5 - MPS 4s2, CS 1 - MPS 1, CS 4 - MPS 4s1, CS 2 - MPS 1, CS 3 - MPS 3. 309/340 (90.9%) of individuals at CS 1-3 are at MPS 1-3, 31/340 (9.1%) are at MPS 4s1. 107/324 (31.2%) of individuals at CS 4 are at MPS 3, 151/324 (46.6%) are at MPS 4s1. Conclusion (1) An improved morphological staging method of midpalatal suture is established. (2) MPS stages have close relationship with CVM stages. (3) Pre-treatment CBCT is recommended for individuals at CS 4 to estimate the possibility of skeletal expansion with traditional tooth-borne RME.

Background

Midpalatal suture ossifies and fuses from posterior to anterior with aging [1]. Melsen et al. used autopsy material and reported that chronological ages of midpalatal suture fusion are different among individuals [2]. Persson et al. indicated that starting time of midpalatal suture fusion is strongly relevant with skeletal growth and development status [3].

Skeletal effects of tooth-borne rapid maxillary expansion (RME) highly depend on the ossification and fusion of midpalatal suture [4, 5]. For traditional tooth-borne RME, skeletal effects (include opening of midpalatal suture and maxillary alveolar bone remodeling) decrease and dental effects (buccal tipping of maxillary molars) increase with aging [6]. Furthermore, clinical experience has proved the complications of traditional tooth-borne RME in matured adolescents, including external root resorption, excessive tipping of maxillary teeth, and alveolar bone resorption et al [7-9].

Cervical vertebrae maturation (CVM) method established and optimized by Baccetti et al. is a commonly used indicator to predict individual growth stage [10-11]. Baccetti et al. preliminarily observed relation between CVM stages and RME effects by dividing samples into early RME group (CS 1-3) and late RME group (CS 4-6), indicating that early RME group got larger proportion of skeletal expansion effect compared with late RME group [5]. Although using CVM stage to indicate optimal timing for maxillary expansion has some clinical significance, it is still indirect evidence due to unknown ossification and fusion status of midpalatal suture at specific CVM stage.

Surgical assisted or bone-borne RME currently used in orthodontic practice improve the possibility of skeletal expansion for individuals with partial or complete ossification and fusion of midpalatal suture [12]. Due to their invasive characteristics and complicated operation, traditional tooth-borne maxillary expansion is still regarded as regular therapy in orthodontic practice, especially for adolescents. Therefore, evaluation of midpalatal suture's ossification and fusion status is important when predicting the optimal timing for traditional tooth-borne maxillary expansion. Angelieri et al., as a pioneer study, classified five morphological stages to describe continuous process of ossification and fusion of midpalatal suture based on horizontal view of 140 CBCT images [13]. The relationship between midpalatal suture stages based on their study and CVM stages was also investigated and the most reliable diagnostic pairs are (CS 1-2) - (stage A-B), CS 3 - stage C and CS 5 - (stage D-E) [14]. Researchers assessed reliability, repeatability, intra- and inter- observer agreement of this classification method to evaluate its clinical prediction capability and found that prediction capability of this method is not optimistic. Clinicians should be cautious in interpretation of this classification method, and more studies are needed for improvement [15-17].

The aims of this study include: (1) Establish an improved staging method to describe the morphological characteristics of midpalatal suture. (2) Investigate the correlation between MPS stage and CVM stage. (3) Case analysis to compare effects of traditional tooth-borne RME at different MPS stages.

Methods

Samples collection

1076 CBCT images taken from January 2013 to April 2018 were collected from Department of oral and maxillofacial radiology, Peking University School and Hospital of Stomatology. Inclusion and exclusion criteria are shown in Table 1. The sample included 675 females and 401 males (6.0 to 21.0 years old) and CBCT images were taken as regular examination for different purposes of diagnosis.

9 patients were chosen from April 2019 to September 2019, from Department of orthodontics, Peking University School and Hospital of Stomatology. The sample included 5 females and 4 males (9.7-13.8 years old). Treatment plans included traditional tooth-borne RME as initial step. Inclusion and exclusion criteria are shown in Table 1.

Biomedical Ethics Committee of Peking University School and Hospital of Stomatology has approved this study (Protocol No: PKUSSIRB-20180739147).

Morphological stage of midpalatal suture and cervical stage

CBCT images were taken with NewTom VGi (Quantitative Radiology, Verona, Italy), at 2.81 mA, 110 kV, 3.6-second exposure, 15*15 cm field of view, with axial slice thickness of 0.3 mm, and isotropic voxels. Patients sat upright with natural head position and jaws immobilized using a chin holder, keeping

Frankfort plane horizontal to ground. Teeth were occluded at intercuspal position, with facial muscles relaxed.

Head orientation: Firstly in horizontal view, put anterior nasal spine (ANS)-posterior nasal spine (PNS) line as axis line. Then in coronal view, put septum line as axis line. In this way, sagittal orientation is already identified (Figure 1).

Observation plane: (1) Subjects with medial thickness of hard palate, observe the central plane of hard palate from upper to lower cortical bone lamella. (2) For subjects with obviously thicker hard palate, observe upper 1/3 and lower 1/3 planes of full thickness instead only the central plane [13]. (3) For subjects with overarched palatal vault, observe central plane of anterior 1/2 and posterior 1/2 instead only one central plane.

CVM stage was recorded according to CVM method by Baccetti et al [10, 11].

Dental casts measurements

9 patients took CBCT before traditional tooth-borne RME (T1) to record their MPS stage. Then maxillary dental cast was obtained and later Hyrax-type RME was delivered with 1-2 turns a day (0.25 mm per turn) until the orthodontist decided to stop activating (Figure 2). Maxillary dental cast was obtained immediately after active expansion ended (T2).

Dental casts were scanned with 3Shape R700 3D scanner (3Shape, Copenhagen, Denmark), saved as three-dimensional digital files (.STL format). Digital casts were then measured with 3D Slicer 4.10.2 digital imaging system (open source: <https://www.slicer.org/>). Accuracy of digital cast size from original plaster cast is no larger than 20 micrometers (Mitutoyo measurer, Mitutoyo Corp., Tokyo, Japan).

Diagram of digital dental cast, landmarks identification and measurements are shown in Figure 3. Lingual point on the maxillary first molar is located at the junction of the lingual groove with the palatal mucosa. Arch width at first molar level is defined as the distance between the lingual points of bilateral maxillary first molars. Arch width at second premolar, first premolar and canine level are also defined in this way [4]. Angulation of maxillary first molars defined by measuring the angle formed by the intersection lines passing through the mesio-buccal and mesio-lingual cusps. Angulation less than 180° indicates the possibility of molars' buccal tipping, while larger than 180° implies the possibility of molars' lingual tipping [4].

When analyzing expansion effects, total effect and average effect per activation were calculated.

$$\text{Average effect of per activation} = \frac{\text{total effect}}{\text{Total activation times}}$$

Statistical analysis

SPSS 19.0 (IBM Corp., Armonk, New York, USA) was used for Spearman correlation analysis.

Python 3.6 software (Mac, Continuum Analytics 5.3.0 Anaconda Inc. New York, USA) was used for diagnostic test analysis. Diagnostic efficacy indexes include sensitivity, specificity, positive likelihood ratio (PLR) and area under ROC curve (AUC). PLR ≥ 10 or ≥ 0.1 indicates significantly better diagnostic efficacy. AUC reflects comprehensive performance of sensitivity and specificity [18].

Results

1. Morphological stages of maxillary midpalatal suture

Five typical stages are classified to describe the continuous ossification and fusion process of midpalatal suture, with Stage 4 divided into Stage 4s1 and Stage 4s2.

Characteristics of different stages on horizontal view are summarized in Table 2. CBCT images of each stage are shown in Figure 4. Diagrams to illustrate detailed characteristics of each stage are shown in Figure 5.

2. Frequency distribution of MPS stage and CVM stage

Frequency distributions of MPS stage and CVM stage are shown in Table 3.

For females, 80.6% (25/31) of CS 1 individuals are at MPS 1-2, with another 19.4% (6/31) at MPS 3. 60.4% (26/43) of CS 2 individuals are at MPS 1-2, with another 34.9% (15/43) at MPS 3. 54.6% (48/88) of CS 3 individuals are at MPS 3, with 35.2% (31/88) at MPS 1-2 and 10.2% (9/88) at MPS 4s1. 35.6% (80/225) of CS 4 individuals are at MPS 3, with 44.9% (101/225) at MPS 4s1 and 14.2% (32/225) at MPS 4s2. More than 90% of CS 5-6 individuals are at MPS 4s2-MPS5.

For males, 78.3% (36/46) of CS 1 individuals are at MPS 1-2, with another 21.7% (10/46) at MPS 3. 40.6% (26/64) of CS 2 individuals are at MPS 1-2, with another 46.9% (30/64) at MPS 3. 61.8% (42/68) of CS 3 individuals are at MPS 3, with 20.6% (14/68) at MPS 1-2 and 17.6% (12/68) at MPS 4s1. 50.5% (50/99) of CS 4 individuals are at MPS 4s1, with 27.3% (27/99) at MPS 3 and 18.2% (18/99) at MPS 4s2. More than 90% of CS 5-6 individuals are at MPS 4s2- MPS 5.

3. Spearman correlation coefficient and diagnostic efficacy indicators

Spearman coefficient between MPS stage and CVM stage is 0.803 in total, 0.790 in females and 0.813 in males (Table 3). Diagnostic test results are shown in Table 4. We placed the AUC value on priority when evaluating all diagnostic efficacy indexes. Diagnostic pairs for each CVM stage and MPS stages are: CS 6 - MPS 5 (AUC=0.769) CS 5 - MPS 4s2 (AUC=0.746) CS 1 - MPS 1 (AUC=0.686), CS 4 - MPS 4s1 (AUC=0.686), CS 2 - MPS 1 (AUC=0.628), CS 3 - MPS 3 (AUC=0.616). In each pair, specificity is obviously larger than its sensitivity.

4. Effect of RME at different MPS stages

Growth status, RME activation and measurements at pre-expansion (T1) and post-expansion (T2) are shown in Table 5. Total RME effects are shown in Table 6 (A), and average effects per activation are shown in Table 6 (B).

Average effects per activation Table 6 (B): (1) For cases at MPS 2, maxillary arch width increase at canine level are between 0.16-0.18 mm, at first premolar level are between 0.15-0.29 mm, at second premolar level are between 0.13-0.26 mm, at first molar level are between 0.16-0.27 mm. Angulations of maxillary first molars decrease are between 0.03-0.05°. (2) For cases at MPS 3, maxillary arch width increase at canine level are between 0.13-0.19 mm, at first premolar level are between 0.15-0.25 mm, at second premolar level are between 0.11-0.26 mm, at first molar level are between 0.15-0.21 mm. Angulations of maxillary first molars decrease are between 0.03-0.04°. (3) For case at MPS 4s1, maxillary arch width increase at canine level is 0.01 mm, at first premolar level is 0.10 mm, at second premolar level is 0.12 mm, at first molar level is 0.10 mm, while the angulations of maxillary first molars decreases is 0.12°.

Discussion

1. Improved morphological staging method of maxillary midpalatal suture

In this study, we established an improved morphological staging method of midpalatal suture based on observation of horizontal view of 1076 CBCT images. We divided Stage 4 into two sub-stages for precisely indicating fusion status of midpalatal suture in molar, premolar and incisor areas, and providing more detailed clinical interpretation. MPS stages are defined as early stages (Stage 1-2), midterm stage (Stage 3-Stage 4s1) and late stages (Stage 4s2-5) with distinguished morphological characteristics.

2. Correlation between MPS stage and CVM stage

It is reported that growth velocity and the occurrence of growth peak for maxilla and mandible are at different timing [19]. In our study, 90.9% of total individuals at CVM 1-3 are at MPS 1-3, indicating unfusion of midpalatal suture; The other 9.1% individuals are at MPS 4s1. This is in accordance with the previous observation in a clinical study, in which Baccetti et al. preliminarily observed early RME group (CS 1-3) got larger proportion of skeletal expansion effect comparing with late RME group (CS 4-6) [5].

Angelieri et al., based on their established midpalatal suture method, concluded that individuals at CS 4-5 had better take pre-treatment CBCT, since 13.5% individuals at CS 5 are still at stage C, thus have potential possibility of getting skeletal expansion effects with traditional tooth-borne RME [14].

Compared with Angelieri et al., population, sample size and morphological staging method of midpalatal suture are different in our study. However, Spearman correlation coefficient of 0.803 indicates a close relationship between CVM stages and MPS stages. Diagnostic pairs based on descending AUC value for each CVM stage are: CS 6 - MPS 5, CS 5 - MPS 4s2, CS 1 - MPS 1, CS 4 - MPS 4s1, CS 2 - MPS 1, CS 3 - MPS 3. We concern more on individuals at CS 4 for the feasibility of skeletal expansion with traditional tooth-borne RME. In the our study, 31.2% of individuals at CS 4 are at MPS 3, another 46.6% at MPS 4s1.

This is obviously different for individuals at CS 3, in which 57.7% are at MPS 3, another 13.5% at MPS 4s1. Therefore, when growing from CS 3 to CS 4, quite a few individuals may go through start of midpalatal suture fusion from posterior to anterior. Therefore, for patients at CS4, it is recommended to take pre-treatment CBCT to observe the fusion and maturation status of midpalatal suture before including traditional tooth-borne RME into treatment plan.

3. Effects of traditional tooth-borne RME at different MPS stages

Angelieri et al. studied relations between traditional tooth-borne RME effects and midpalatal suture method their established. By reporting of traditional tooth-borne RME treated patients, they concluded that individuals at Stage A-B are more suitable for traditional tooth-borne RME, while Stage C individuals may confront with increased skeletal obstacles. Stage D-E individuals are suggested to take surgical-assisted RME for safety and obvious skeletal effect [20].

When analyzing 9 cases in our study, increase in maxillary arch width and decrease in angulation of the maxillary first molars didn't show remarkable difference either at MPS stage 2 (9.7-10.8 years old) or stage 3 (12.3-13.3 years old). However, when comparing Case 8 at MPS 3 (13.3 years old) with Case 9 at MPS 4s1 (13.8 years old), it is noted that even at similar chronological age, Case 9 (MPS 4s1) got obviously less maxillary arch width increase and more obvious maxillary first molar buccal tipping than that of Case 8 (Table 5). Since Case 8 and Case 9 are both at CS 4, variation in expansion effects might be contributed to the different MPS stages and potentially suggested that maxillary arch width increase at MPS 2-3 are larger than that at MPS 4s1. This is also in accordance with the assumption that maturation status of midpalatal suture is uncertain for individuals at CS 4, thus pre-treatment CBCT is recommended. The results also indicate that buccal tipping of anchorage molars with RME appliance is inevitable in RME treatment, even in younger patients. And there would be less buccal tipping of maxillary molars at MPS 2-3 than that at MPS 4s1. Due to limited cases in the verification of expansion effects in the current study, enlarged samples should be collected in the future to investigate the underlying clinic significance of this improved midpalatal suture staging method.

Conclusions

- (1) An improved morphological staging method of midpalatal suture based on observation of 1076 CBCT images is established.
- (2) MPS stages have close relationship with CVM stages with Spearman correlation coefficient of 0.803. Diagnostic pairs based on AUC value for each CVM stage are: CS 6 - MPS 5, CS 5 - MPS 4s2, CS 1 - MPS 1, CS 4 - MPS 4s1, CS 2 - MPS 1, CS 3 - MPS 3.
- (3) Pre-treatment CBCT is recommended to identify skeletal expansion feasibility with traditional tooth-borne RME for individuals at CS 4.

Abbreviations

MPS stage: morphological stages of midpalatal suture; CVM stage: cervical vertebrae maturation stage; CS: CVM stage; RME: rapid maxillary expansion; CBCT: cone-beam computed tomography; ANS: anterior nasal spine; PNS: posterior nasal spine; ROC curve: receiver operating characteristic curve; AUC: area under ROC curve; PLR: positive likelihood ratio

Declarations

Ethics approval and consent to participate

This study was approved by Biomedical Ethics Committee of Peking University School and Hospital of Stomatology (Protocol No: PKUSSIRB-20180739147).

We declare that written informed consent was obtained from all participants included in the study (participants under 16 years old were obtained from their parent or guardian).

Consent for publication

Not applicable.

Availability of data and materials

The datasets used and/or analysed during the current study are available from the corresponding author on reasonable request.

Competing interests

The authors declare that they have no competing interests.

Funding

Data collection, evaluation and statistic analysis in this project was partially supported by research fund from National Natural Science Foundation of China (NSFC 81970979) and by research fund from Ministry of Science and Technology of the People's Republic of China (2018FY101005).

Authors' contributions

LG observed the CBCT images, established midpalatal suture morphological staging method and was a major contributor in writing the manuscript. YG conceived of the study, made a critical revision of the manuscript, and was a corresponding author. All authors have reviewed and agreed to the submission of the final manuscript.

Acknowledgements

Not applicable.

Authors' information

1. Department of orthodontics, Peking University School and Hospital of Stomatology, No. 22 Zhongguancun Avenue South, Haidian District, Beijing, 100081, China;
2. National Engineering Laboratory for Digital and Material Technology of Stomatology, Beijing Key Laboratory of Digital Stomatology, Peking University School and Hospital of Stomatology, No. 22 Zhongguancun Avenue South, Haidian District, Beijing, 100081, China

References

1. Bjork A. Sutural growth of the upper face studied by the implant method. *Acta Odontol Scand.* 1966; 24: 109-27. ☒
2. Melsen B. Palatal growth studied on human autopsy material. *Am J Orthod.* 1975; 68: 42-54.
3. Persson M, Thilander B. Palatal suture closure in man from 15 to 35 years of age. *Am J Orthod.* 1977; 72: 42-52.
4. McNamara JA Jr, Baccetti T, Franchi L, Herberger TA. Rapid maxillary expansion followed by fixed appliances: a long-term evaluation of changes in arch dimensions. *Angle Orthod.* 2003; 73: 344-53.
5. Baccetti T, Franchi L, Cameron CG, McNamara JA Jr. Treatment timing for rapid maxillary expansion. *Angle Orthod.* 2001; 71: 343-50.
6. Rungcharassaeng K, Caruso JM, Kan JY, Kim J, Taylor G. Factors affecting buccal bone changes of maxillary posterior teeth after rapid maxillary expansion. *Am J Orthod Dentofacial Orthop.* 2007; 132: 428.e1-8.
7. Barber AF, Sims MR. Rapid maxillary expansion and external root resorption in man: a scanning electron microscope study. *Am J Orthod.* 1981; 79: 630-52.
8. Rinaldi MRL, Azeredo F, de Lima EM, Rizzato SMD, Sameshima G, de Menezes LM. Cone-beam computed tomography evaluation of bone plate and root length after maxillary expansion using tooth-borne and tooth-tissue-borne banded expanders. *Am J Orthod Dentofacial Orthop.* 2018; 154: 504-16.
9. Garib DG, Henriques JF, Janson G, Freitas MR, Coelho RA. Rapid maxillary expansion–tooth tissue-borne versus tooth-borne expanders: a computed tomography evaluation of dentoskeletal effects. *Angle Orthod.* 2005; 75: 548-557.
10. Baccetti T, Franchi L, McNamara JA Jr. An improved version of the cervical vertebral maturation (CVM) method for the assessment of mandibular growth. *Angle Orthod.* 2002; 72: 316–23.
11. Baccetti T, Franchi L, McNamara JA Jr. The cervical vertebral maturation (CVM) method for the assessment of optimal treatment timing in dentofacial orthopedics. *Sem Orthod.* 2005; 11: 119–129.
12. Bortolotti F, Solidoro L, Bartolucci ML, Incerti Parenti S, Paganelli C, Alessandri-Bonetti G. Skeletal and dental effects of surgically assisted rapid palatal expansion: a systematic review of randomized controlled trials. *Eur J Orthod.* 2019; cjz057. doi: 10.1093/ejo/cjz057

13. Angelieri F, Cevdanes LH, Franchi L, Gonçalves JR, Benavides E, McNamara JA Jr. Midpalatal suture maturation: classification method for individual assessment before rapid maxillary expansion. *Am J Orthod Dentofacial Orthop.* 2013; 144: 759-69.
14. Angelieri F, Franchi L, Cevdanes LH, McNamara JA Jr. Diagnostic performance of skeletal maturity for the assessment of midpalatal suture maturation. *Am J Orthod Dentofacial Orthop.* 2015; 148: 1010-6.
15. Barbosa NMV, Castro ACD, Conti F, Capelozza-Filho L, Almeida-Pedrin RRD, Cardoso MDA. Reliability and reproducibility of the method of assessment of midpalatal suture maturation: A tomographic study. *Angle Orthod.* 2018; 89: 71-7.
16. Sayar G, Kılınç DD. Rapid maxillary expansion outcomes according to midpalatal suture maturation levels. *Prog Orthod.* 2019; 20: 27.
17. Isfeld D, Flores-Mir C, Leon-Salazar V, Lagravère M. Evaluation of a novel palatal suture maturation classification as assessed by cone-beam computed tomography imaging of a pre- and postexpansion treatment cohort. *Angle Orthod.* 2018; 89: 252-61.
18. Hajian-Tilaki K. Receiver operating characteristic (ROC) curve analysis for medical diagnostic test evaluation. *Caspian J Intern Med.* 2013; 4: 627-35.
19. Ochoa BK, Nanda RS. Comparison of maxillary and mandibular growth. *Am J Orthod Dentofacial Orthop.* 2004; 125: 148-59.
20. Angelieri F, Franchi L, Cevdanes LH, Bueno-Silva B, McNamara JA Jr. Prediction of rapid maxillary expansion by assessing the maturation of the midpalatal suture on cone beam CT. *Dental Press J Orthod.* 2016; 21: 115-25.

Tables

Due to technical limitations the Tables are available as a download in the Supplementary Files.

Figures

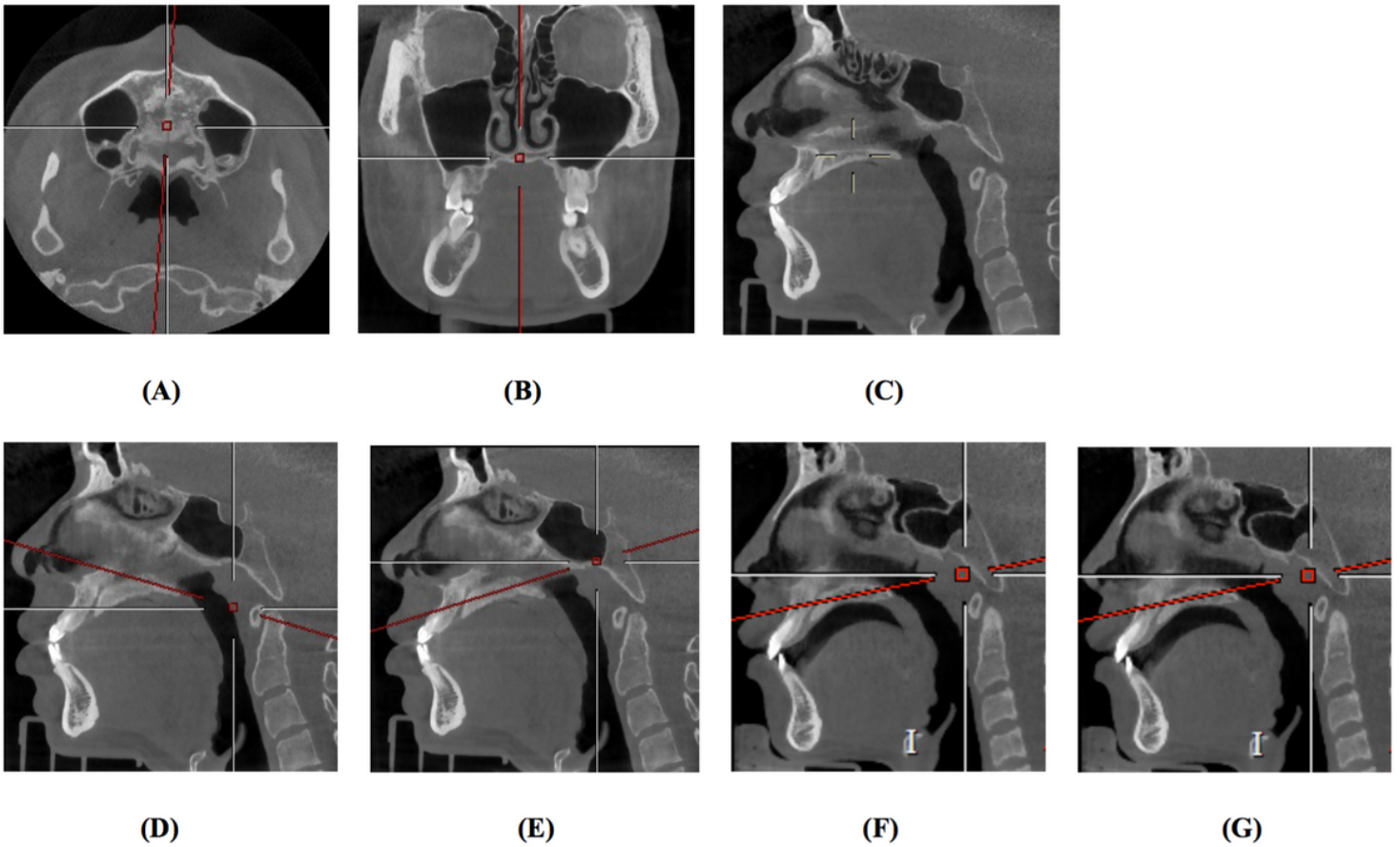


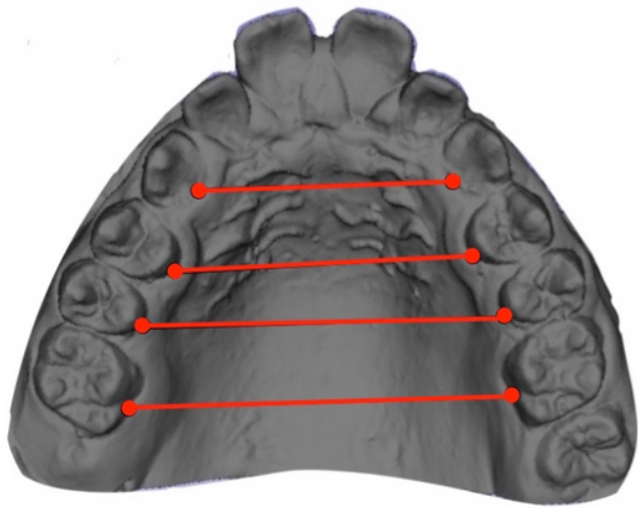
Figure 1

Head orientation. (A) Horizontal: put ANS-PNS line as axis line. (B) Coronal: put septum line as axis line. (C) Sagittal: already uniquely identified. (D)-(E) For subjects with overarching palatal vault, observe central planes of anterior 1/2 and posterior 1/2 instead only one central plane. (F)-(G) For subjects with obviously thicker hard palate, observe upper 1/3 and lower 1/3 planes of full thickness instead only the central plane [13].

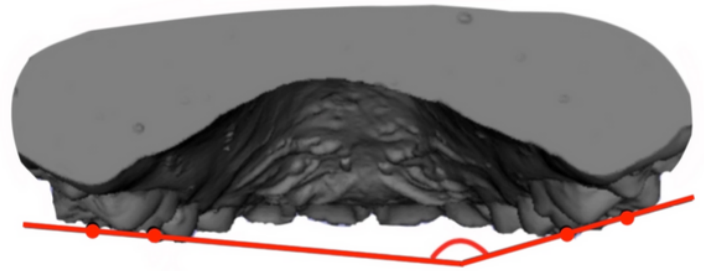


Figure 2

Occlusal view of Hyrax-type rapid maxillary expansion. (A) Pre-expansion. (B) Post-expansion.



(A)



(B)

Figure 3

Diagram of three-dimensional digital maxillary cast and measurement. (A) Arch width. (B) Angulation of maxillary first molar.

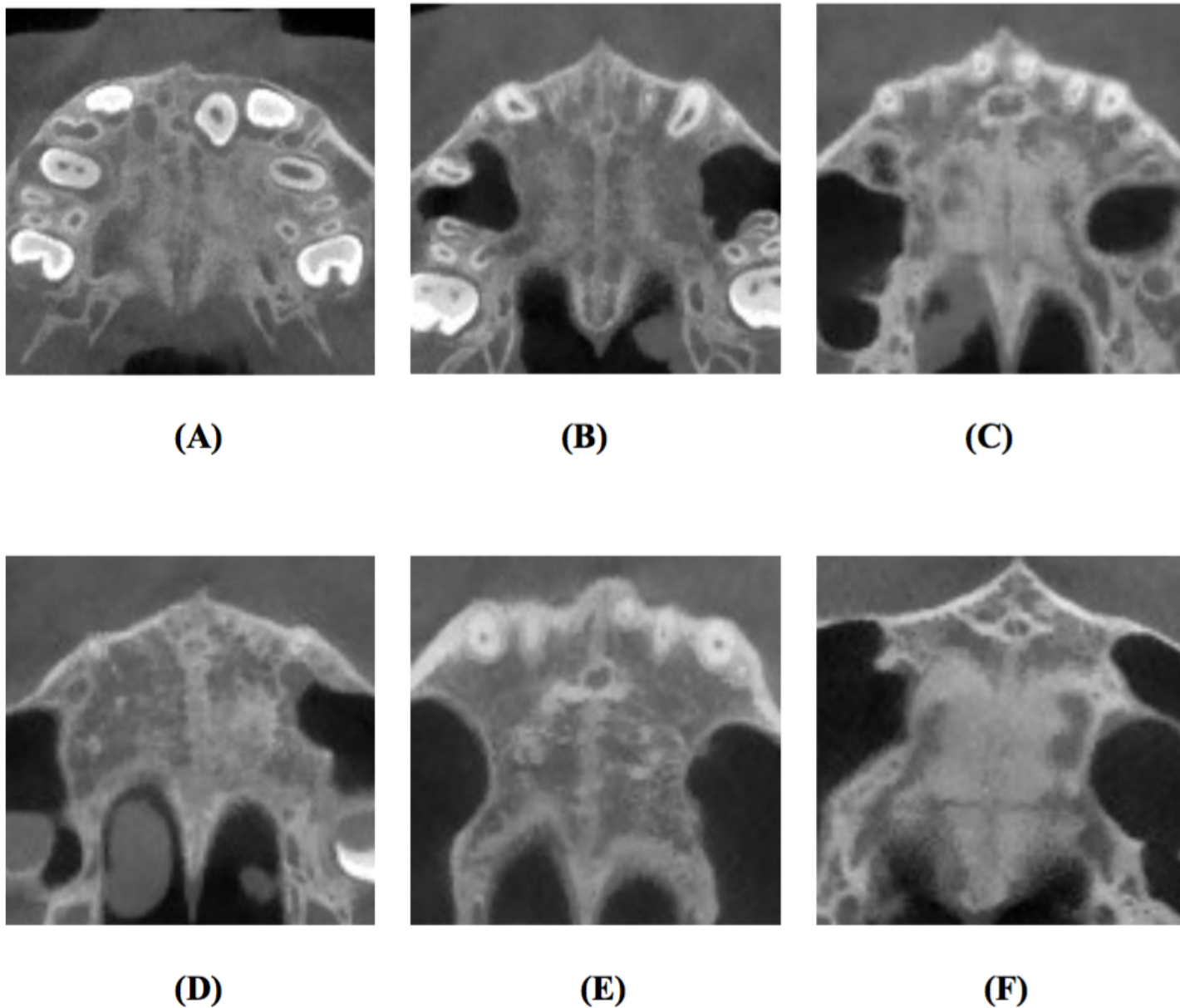


Figure 4

Typical CBCT images of morphological stages of midpalatal suture on horizontal view. (A) Stage 1. (B) Stage 2. (C) Stage 3. (D) Stage 4s1. (E) Stage 4s2. (F) Stage 5.

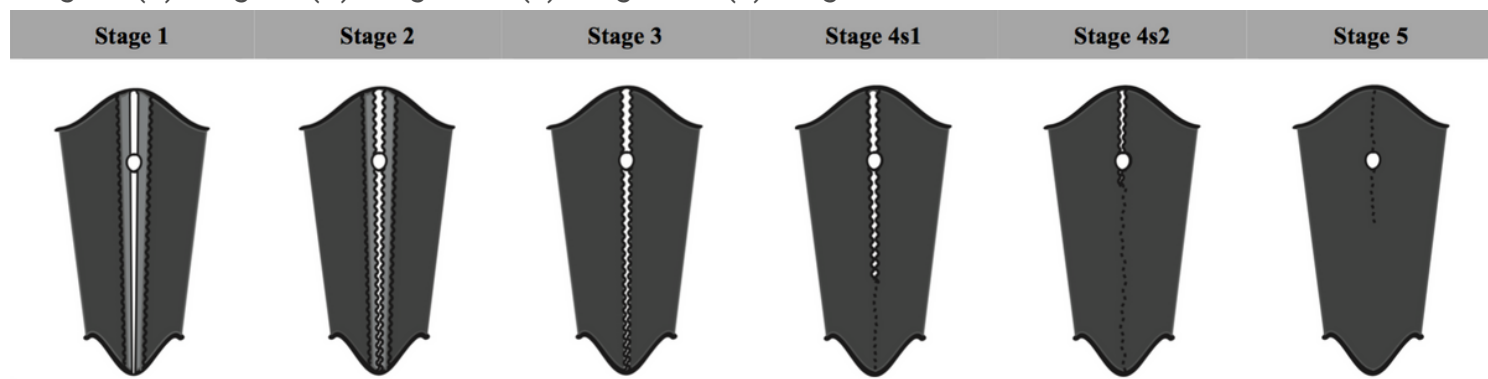


Figure 5

Diagrams of morphological stages of midpalatal suture morphological characteristics. White: Low-density tissue. Light grey: Transitional area. Deep grey: High-density area.

Supplementary Files

This is a list of supplementary files associated with this preprint. Click to download.

- [Tables.pdf](#)