

# Althaea officinalis extracts heal skin wounds in second- and third-degree burns in mice

**Ali Mohammad Ranjbar**

Shahid Sadoughi University of Medical Sciences and Health Services

**Arefeh Sojaemehr**

Shahid Sadoughi University of Medical Sciences and Health Services

**Mohsen Zabihi** (✉ [mzabihi100@gmail.com](mailto:mzabihi100@gmail.com))

Shahid Sadoughi University of Medical Sciences and Health Services

**Fatemeh Shishehbor**

Shahid Sadoughi University of Medical Sciences and Health Services

**Vahid Ramezani**

Shahid Sadoughi University of Medical Sciences and Health Services

---

## Research Article

**Keywords:** Althaea, second- and third-degree burn, wound healing, mice

**DOI:** <https://doi.org/10.21203/rs.3.rs-145872/v1>

**License:** © ⓘ This work is licensed under a Creative Commons Attribution 4.0 International License.

[Read Full License](#)

---

# Abstract

**Background and Purpose:** Burns are one of the most common injuries. There are few medications to repair skin in burns. Although antibacterial drugs such as topical silver sulfadiazine may prevent wound infections, they usually can't attenuate skin healing. Marshmallow is used in Iranian traditional medicine to improve skin burns. We aimed to evaluate the effect of hydroalcoholic and aqueous extract of *Althaea officinalis* on the histopathologic parameters of second- and third-degree burns in mice.

**Experimental approach:** The mice were randomly divided into 9 groups (n=6) including control and treatment groups. Experimental second- and third-degree burns were induced on dorsal skin of the mice by a metal plate (2 cm in diameter) under general anesthesia. Control and treatment groups were treated twice daily for 21 days topically. Normal saline was used for control group and hydroalcoholic and aqueous extracts of *Althaea officinalis* in three concentrations (1%, 2% and 4%) were used for the treatment groups. All of the preparations were made in hydrogel base. Finally, the histopathological parameters of the burned skin including polymorphonuclear (PMN) migration, epithelialization, angiogenesis and collagenization were scored and total score of wound healing was calculated.

**Key Results:** The findings showed that topical application of both hydroalcoholic and aqueous extracts of *Althaea officinalis* attenuates the wound healing process. they reduce PMN migration, collagenization, epithelialization and angiogenesis scores compared to control group.

**Conclusions & Implications:** *Althaea officinalis* can be used as an adjunct medication to attenuate wound healing in skin burns.

## Introduction

Burns are one of the most common injuries. More than 6.6 million people are estimated to suffer from burns worldwide (1). Burns are usually classified according to their severity and weakness. When skin damage involves the dermis in addition to the epidermis, it causes second-degree burns, and when all layers of the skin are damaged, third-degree burns occur (2). Skin is a protective barrier against microorganisms and harmful substances (3). This barrier is most effective when it is not damaged. The skin is constantly renewed by shedding dead cells and producing new cells. Superficial cells that are lost due to wear, damage, or disease are rapidly replaced. Following damage to skin, the lower layer cells of the dermis begin to build collagen and repair the epithelial cells (4). Injured skin may be infected by [cutaneous flora](#) and other pathogens. Although antibacterial medications such as topical silver sulfadiazine may prevent wound infections, they usually can't attenuate skin healing (5). Accordingly, it is important to find therapeutic agents for a faster repair of the dermis and epidermis against skin damage. Nowadays, the use of medicinal plants has been welcomed to medicine for therapeutic purposes (6). Pectin in *Althaea officinalis* has an immune-stimulating and wound-healing effect (7). Its use in the treatment of skin diseases such as eczema has been reported to be attributed to its phagocytosis and macrophage activation (8).

We investigated the effects of aqueous and hydroalcoholic extracts of *Althaea officinalis* for reduction of inflammation and attenuation of the wound healing process.

## Materials And Methods

### *Animals*

Male mice (25-30 g, 2 months old) were purchased from of the animal house of the School of Pharmacy, Shahid Sadoughi University of Medical Sciences, Yazd, Iran. The animals were housed in groups of 6 in standard laboratory conditions at 20-25 °C and 65-75% humidity, and they were kept in separated cages for 12 hours light/dark cycle and free access to standard food and tap water. All mice were observed according to the animal rights ethics protocol of Yazd Shahid Sadoughi University of Medical Sciences (IR.SSU.MEDICINE.REC.1398.055).

### *Preparation of Althaea officinalis Extracts*

The dried *Althaea officinalis* flowers were obtained from Yazd medicinal plants market. The scientific name and the quality were confirmed with a quality assurance number was obtained from the Faculty of Pharmacy, Shahid Sadoughi University of Medical Sciences (SSU0042). The flowers were grinded and powdered, then the hydroalcoholic extract was performed during several week percolation. The aqueous extract was performed by infusion method for 20 minutes at 80 °C. The total hydroalcoholic and aqueous extracts were dried and standardized.

The dried aqueous and hydroalcoholic extracts were used to prepare the hydrogels (1, 2 and 4 percent) containing 2% polymeric dry matters including 40% hydroxypropyl methylcellulose, 40% methylcellulose and 20% hydroxyethyl cellulose as. Five percent propylene glycol was added to the hydrogel to improve its rheological properties.

### *Standardization*

Total phenolic compounds were measured by folin-ciocalteu method. Three concentrations of the hydroalcoholic extract were prepared in distilled water including 0.1, 0.01 and 0.001 µg/ml. Then 200 µl of each concentration was poured into separated test tubes and 400 µl of distilled water was poured into the blank tube. Then, 3 ml and 1.5 ml of folin-ciocalteu reagent was added into the blank and test tubes respectively and all of them were incubated at 22 °C for 5 minutes. Then 3 ml and 1.5 ml sodium bicarbonate 0.6% was added into the blank and test tubes respectively and were incubated at 22 °C for 5 minutes. The absorbances were observed at 725 nm by a spectrophotometer device (Figure 1).

Total phenolic content was calculated by below formula.

$$Y=0.0561 X + 0.0267$$

$$Y=0.067, X=7.183 \mu\text{g} /\text{ml}, R^2=0.9996$$

Total flavonoid compounds were measured by catechin method. Three concentrations of the hydroalcoholic extract were prepared in distilled water including 0.1, 0.01 and 0.001 µg/ml in three separated tubes (1.5 ml). Then 300 µl of sodium nitrite 5% was added into the blank and test tubes. After 5 minutes, 300 µl aluminum chloride 10% and Then 2 cc NaOH 1 M was added and distilled to 100 ml. The absorbances were observed at 510 nm by a spectrophotometer device (Figure 2).

Total flavonoid content was calculated by below formula.

$$Y=0.0003 X +0.0129$$

$$Y=0.0137, X=26.66 \mu\text{g/ml}, R^2=0.9865$$

### ***Burn induction***

Burn induction was performed according to Shanmoga method with some modifications (9). The dorsal skin of the mice was burned by a metal plate (2 cm in diameter) under general anesthesia following i.p. injection of ketamine (50 mg/kg) and xylazine (10 mg/kg). According to the histopathological parameters, the best temperature for induction the second- and third-degree burns was determined as 120 °C for 3- and 7-seconds contact time, respectively (Figure 3).

The mice were randomly divided into two main groups including the second- and the third-degree burns groups. Each main group was randomly divided into 9 groups (n=6) including control group (received topical normal saline), topical hydroalcoholic and aqueous Althaea extract groups (1, 2 and 4 percent), topical phenytoin 1% group and topical hydrogel group. Following the burn induction, the animals were kept in separated cages with free access to food and water and treated twice daily for 20 days. They were weighted weekly. Finally, the mice were sacrificed and the entire layer of the burned skin was separated and maintained in formalin 10% solution for histopathological evaluations.

### ***Histopathological evaluations***

The tissue was fixed in Bouin's solution (7.5 mL saturated picric acid, 2.65 mL glacial acetic acid, and 2.5 mL 7% formaldehyde), post-fixed in 70% alcohol, and embedded in paraffin blocks. A full thickness tissue section was obtained, deparaffinized, and stained with hematoxylin eosin.

The histopathological parameters including epithelialization, PMN migration, collagen formation and angiogenesis were scored under a optic microscope double blindly.

### ***Statistical analysis***

Data are expressed as mean ± S.E.M which were analyzed by one-way ANOVA followed by Tukey's post hoc test. All statistical analyses were made by using SPSS software (version 19).

# Results

There wasn't any significant variation in animal's weight during the study. Their behaviors since the second day of burn induction were normal in all of the groups.

## *Second-degree burn*

### *Polymorphonuclear migration*

Polymorphonuclear migration was scored according to: PMN count $\geq$ 40, score=0; 10 $\leq$ PMN $<$ 40, score=1 and PMN count $<$ 10, score=2.

Polymorphonuclear migration in the hydroalcoholic extract 4% and the aqueous extract 4% were significantly decreased compared to control group ( $P<0.05$ ) (figure 5).

### **Collagen formation**

Collagenization in the treated groups with the hydroalcoholic extracts (1%, 2% and 4%) and the aqueous extracts (1% and 4%) were equal. There was a significant difference in collagen formation between these groups and control group ( $P<0.01$ ) (figure 6).

### **Epithelialization**

The highest epithelialization was observed in both the hydroalcoholic extract 2% and 4% groups. The score of epithelialization in the hydroalcoholic extract 2% and 4% groups and control group was significantly different ( $P <0.05$ ) (figure 7).

### **Angiogenesis**

The two groups treated with the hydroalcoholic extract 4% and the aqueous extract 2% and 4% showed the highest angiogenesis respectively. Angiogenesis was significantly increased in the hydroalcoholic extract 4% group in comparison with control group ( $P<0.05$ ) (figure 8).

### **Total score**

Total score was calculated as summation of the scores of all of the parameters including collagen formation, PMNs migration, angiogenesis and epithelialization.

Total score in the second-degree burn showed a significant difference between the hydroalcoholic extract 4% group and normal saline group ( $p <0.05$ ) (figure 9).

## *Third-degree burn*

## **Polymorphonuclear migration**

Polymorphonuclear migration was scored according to: PMN count $\geq$ 40, score=0; 10= $\leq$ PMN $\leq$ 40, score=1 and PMN count $\leq$ 10, score=2.

There was no significant difference in PMN migration between the groups ( $P<0.05$ ) (figure 11).

## **Collagen formation**

There was a significant difference in collagen formation between the aqueous extract 1% group and control group ( $P<0.05$ ) (figure 12). It was not observed any difference between the other groups ( $P<0.05$ ).

## **Epithelialization**

The highest epithelialization was observed in both the aqueous extract 1% and 2% groups and it was significant compared to control group ( $P<0.05$ ) (figure 13).

## **Angiogenesis**

Angiogenesis was significantly increased in the aqueous extract 1% and 4% groups compared to control group ( $P<0.05$ ) (figure 14).

## **Total score**

Total score was calculated as summation of the scores of all of the parameters including collagen formation, PMNs migration, angiogenesis and epithelialization.

Total score in the third-degree burns showed a significant difference between both the aqueous extract 1% and 2% groups and normal saline group ( $P<0.05$ ) (figure 15).

## **Discussion**

We investigated the histopathologic effects of topical hydroalcoholic and aqueous extracts of *Althaea officinalis* flowers (1%, 2%, and 4%) in second- and third-degree skin burns in mice. The effects of the extracts were compared to hydrogel base and control (normal saline) groups. Phenytoin 1% cream chose as a standard group. To follow the wound healing process, histopathologic variables of PMN migration, collagen formation, angiogenesis and epithelialization were measured.

The results showed that hydroalcoholic and aqueous extracts of *Althaea officinalis* repair skin injury in the second- and third- degree burns. Hydroalcoholic extract (4%) showed significant effectiveness in second-degree burns while aqueous extracts (1% and 2%) showed significant effectiveness in third-degree burns.

Phenolic compounds and flavonoids are secondary metabolites in plants that have important properties such as antioxidant, anti-inflammatory and antimicrobial effects (10). These features are effective in the

wound healing process. The effect of phenols in the treatment of skin diseases, skin aging and skin injuries including scars and burns has been proven. They reduce the duration of wound healing (11). Flavonoids facilitate the regeneration of epithelial cells by inducing a contraction in the wound site. Flavonoids are also considered to be a factor in collagenization (12). Previous studies have shown that *Althaea officinalis* has antimicrobial effects due to its phenolic compounds and flavonoids, which inhibit the growth of microorganisms and infection (12). *Althaea officinalis* has strong anti-inflammatory and antioxidant effects due to its alpha-tocopherol content and increased mucin secretion (13). Therefore, it can be concluded that hydroalcoholic extract of this plant has improved the healing process of non-infectious wounds by reducing the inflammation by removing free radicals and oxidants (12). The aqueous extract of this plant stimulates phagocytosis and releases oxygen radicals and leukotriene from human neutrophils. These features improve the wound healing process. *Althaea officinalis* increases production of interleukin-6, which results the proliferation of epidermal cells (13). The antioxidant properties of the *Althaea officinalis* have been attributed to its some compounds such as flavonoids, mucilage and pectin (14). On this basis, it is predicted that the wound healing process at epidermis and dermis level is related to the presence of the aforementioned traits in the flower extract (11). However, this study showed that *Althaea officinalis* extract significantly reduced the dermis and epidermis damage compared to the control group.

## Conclusion

The findings showed that *Althaea officinalis* extract induces positive effects on the wound healing process in both second- and third-degree burns. Hydroalcoholic extract (4%) showed significant effectiveness in second-degree burns while aqueous extracts (1% and 2%) showed significant effectiveness in third- degree burns. Considering the antibacterial effects of *Althaea officinalis*, it can be promise to use it in skin burns.

## References

1. Nasiri E, Hosseinimehr SJ, Azadbakht M, Akbari J, Enayati-fard R, Azizi S. Effect of *Malva sylvestris* cream on burn injury and wounds in rats. *Avicenna journal of phytomedicine*. 2015;5(4):341.
2. Tintinalli J. *Tintinallis emergency medicine A comprehensive study guide*: McGraw-Hill Education; 2015.
3. Pivarcsi A, Nagy I, Kemeny L. Innate immunity in the skin: how keratinocytes fight against pathogens. *Current immunology reviews*. 2005;1(1):29-42.
4. DeHaven C. Mechanisms of exfoliation. *Science of Skincare*. 2015.
5. Caruso DM, Foster KN, Blome-Eberwein SA, Twomey JA, Herndon DN, Luterman A, et al. Randomized clinical study of Hydrofiber dressing with silver or silver sulfadiazine in the management of partial-thickness burns. *Journal of burn care & research*. 2006;27(3):298-309.
6. Jamshidi-Kia F, Lorigooini Z, Amini-Khoei H. Medicinal plants: Past history and future perspective. *Journal of herbmed pharmacology*. 2018;7(1).

7. Anne McIntyre F. Herbal treatment of children: Western and Ayurvedic perspectives: Elsevier Health Sciences; 2005.
8. Yamada H. Contributions of pectins on health care, Pectins and pectinases: proceedings of an international symposium, Wageningen, The Netherlands, December 3-7, 1995. Edited by Visser J, Voragen AGJ. Amsterdam, Elsevier; 1996.
9. Priya KS, Gnanamani A, Radhakrishnan N, Babu M. Healing potential of *Datura alba* on burn wounds in albino rats. *Journal of ethnopharmacology*. 2002;83(3):193-9.
10. Duke JA. Handbook of medicinal herbs: CRC press; 2002.
11. Phan T-T, Wang L, See P, Grayer RJ, Chan S-Y, Lee ST. Phenolic compounds of *Chromolaena odorata* protect cultured skin cells from oxidative damage: implication for cutaneous wound healing. *Biological and Pharmaceutical Bulletin*. 2001;24(12):1373-9.
12. Yang D, Liu X, Liu M, Chi H, Liu J, Han H. Protective effects of quercetin and taraxasterol against H<sub>2</sub>O<sub>2</sub>-induced human umbilical vein endothelial cell injury in vitro. *Experimental and therapeutic medicine*. 2015;10(4):1253-60.
13. Scheffer J, König W, editors. Einfluss von *Radix althaeae* und *Flores chamomillae* Extrakten auf Entzündungsreaktionen humaner neutrophiler Granulozyten, Monozyten und Rattenmastzellen. 3rd Phytotherapie-Kongress; 1991.
14. Fukai T, Marumo A, Kaitou K, Kanda T, Terada S, Nomura T. Anti-*Helicobacter pylori* flavonoids from licorice extract. *Life sciences*. 2002;71(12):1449-63.

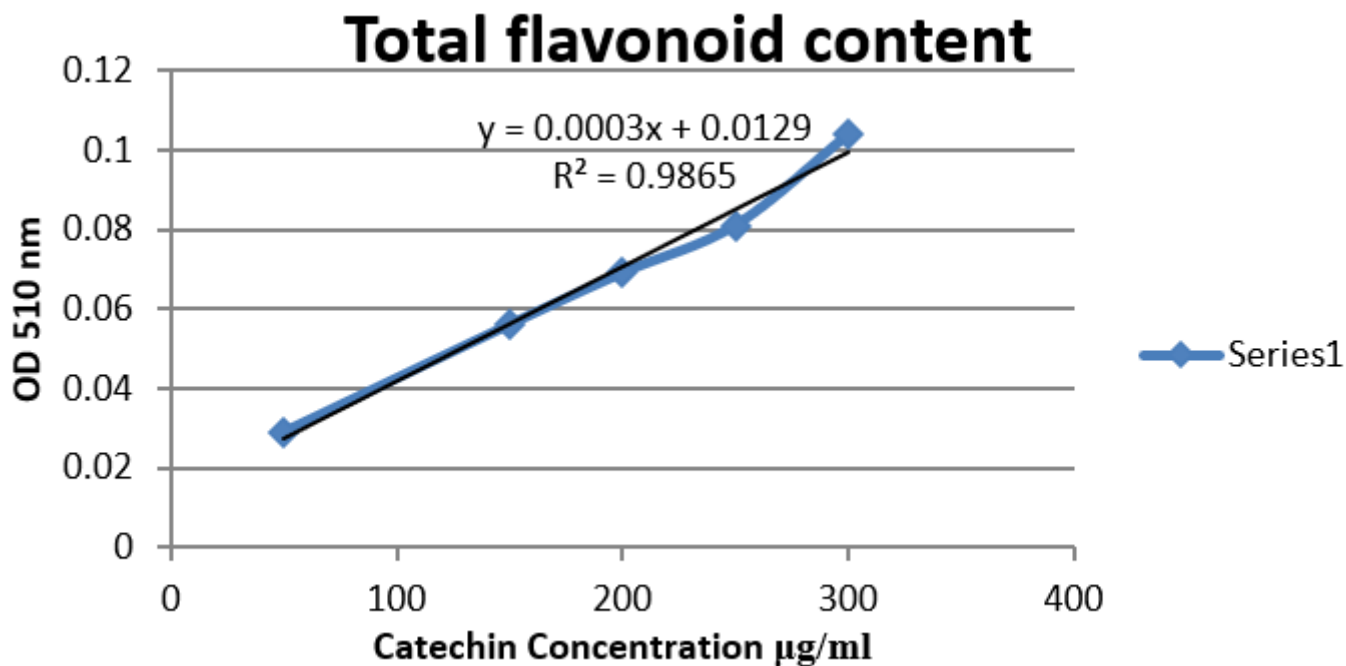
## Declarations

### Conflicts of interest

The authors declare that there is no conflict of interest regarding the publication of this article.

## Figures





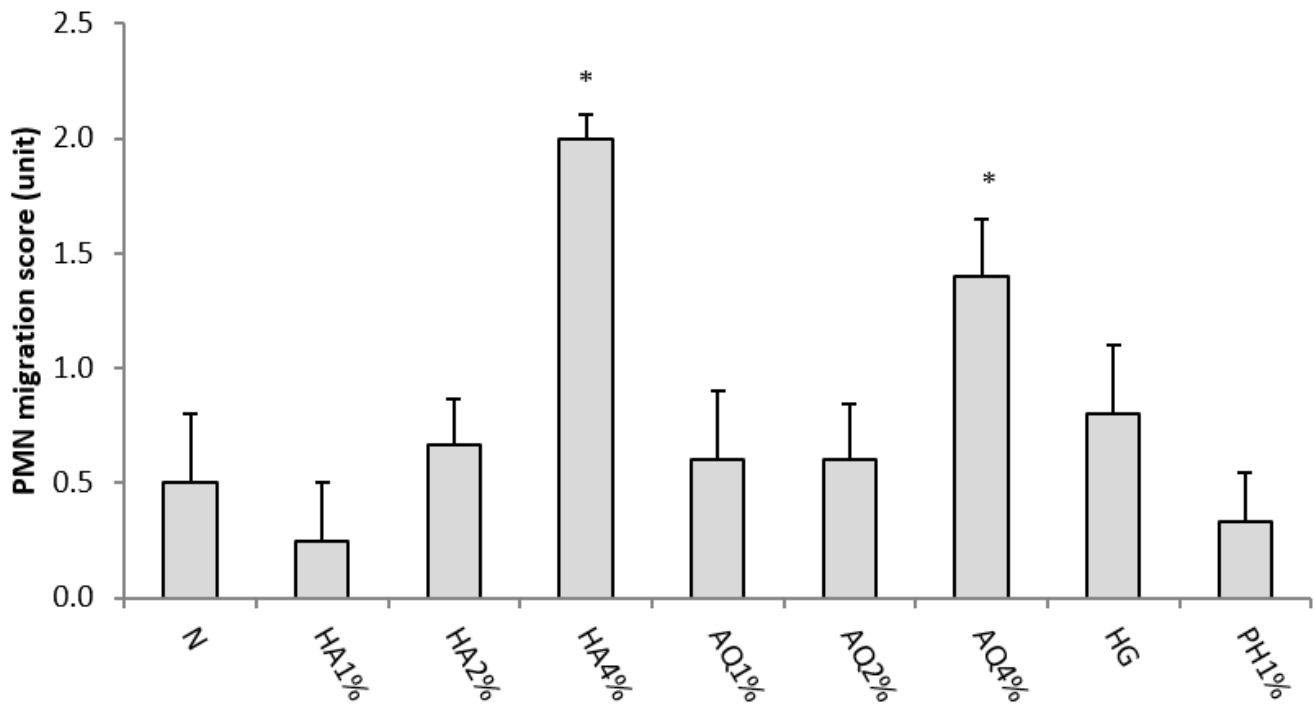
**Figure 2**

Catechin standard curve



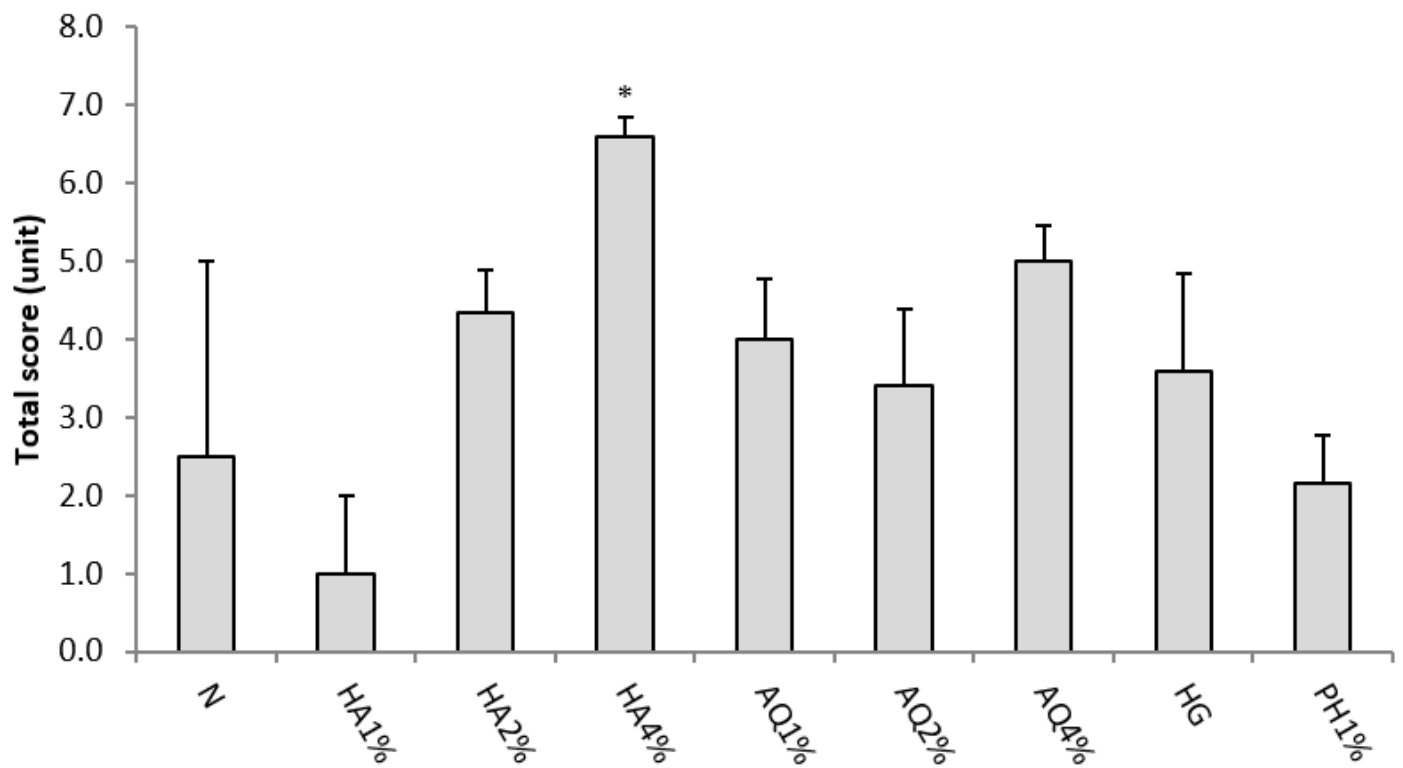
**Figure 4**

Histopathological presentation of mice second-degree burned skin in treatment groups after 21 days treatment. (A) appearance of a skin sample in *Althaea officinalis* aqueous extract 4% group, mild angiogenesis, thick epidermis and small number of PMNs. (B) in *Althaea officinalis* hydroalcoholic extract 4% group, low angiogenesis, thick epidermis and low inflammatory cells. (C and D) in control group, thin epidermis and large number of PMNs.



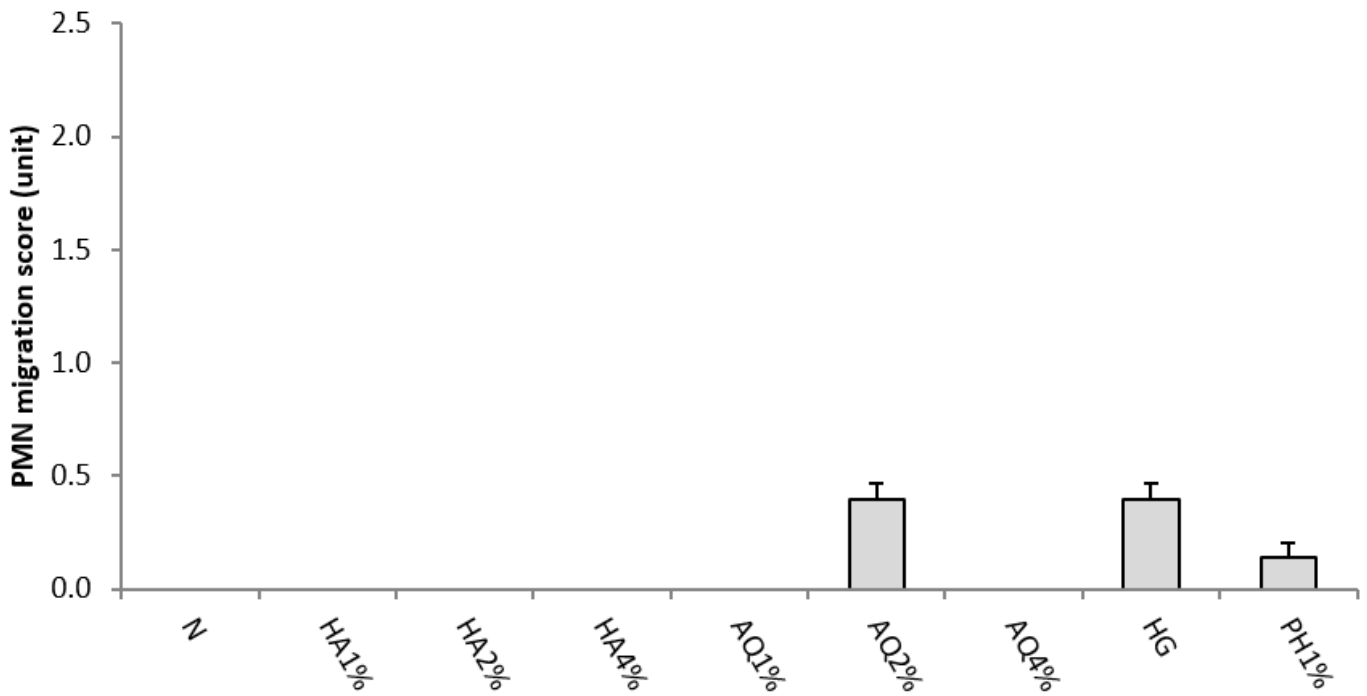
**Figure 5**

effects of hydroalcoholic (HA) and aqueous (AQ) extract of *Althaea officinalis* flowers (1, 2 and 4%, topical), phenytoin 1% cream (PH1%), hydrogel (HG) and normal saline (N, control group) on PMN migration in second-degree burn. Data are analyzed as mean  $\pm$  S.E.M, (n=6). \*P<0.05 in comparison with control group, one-way ANOVA followed by Tukey's post hoc test.



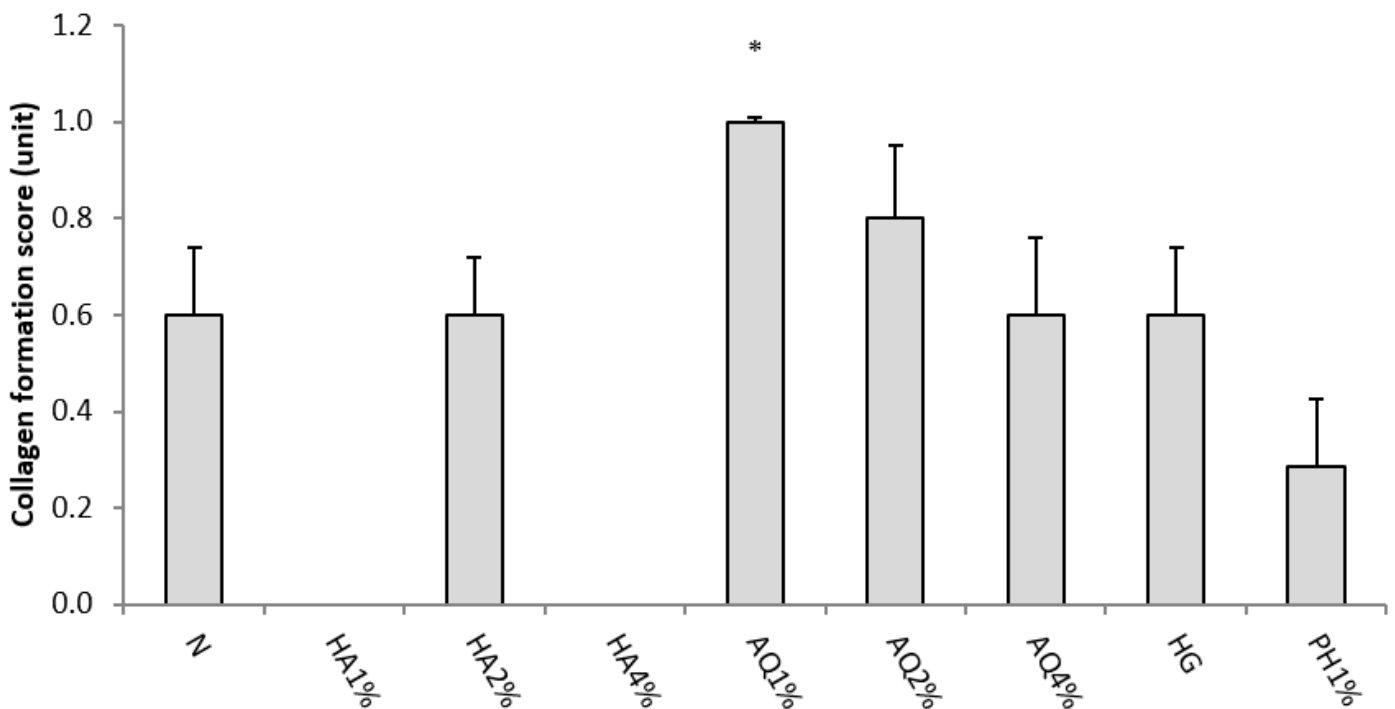
**Figure 9**

effects of hydroalcoholic (HA) and aqueous (AQ) extract of *Althaea officinalis* flowers (1, 2 and 4%, topical), phenytoin 1% cream (PH1%), hydrogel (HG) and normal saline (N, control group) on total score in second-degree burn. Data are analyzed as mean  $\pm$  S.E.M, (n=6). \*P<0.05 in comparison with control group, one-way ANOVA followed by Tukey's post hoc test.



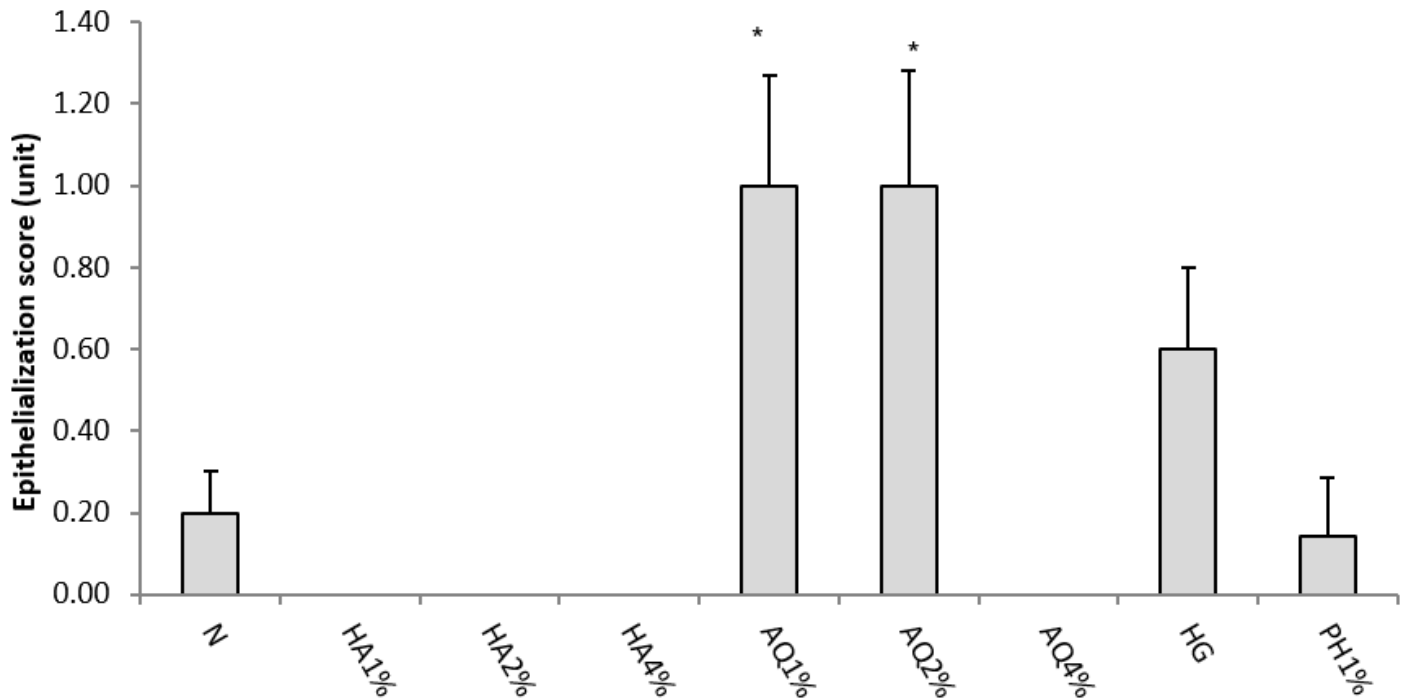
**Figure 11**

effects of hydroalcoholic (HA) and aqueous (AQ) extract of *Althaea officinalis* flowers (1, 2 and 4%, topical), phenytoin 1% cream (PH1%), hydrogel (HG) and normal saline (N, control group) on PMN migration in third-degree burn. Data are analyzed as mean  $\pm$  S.E.M, (n=6). \*P<0.05 in comparison with control group, one-way ANOVA followed by Tukey's post hoc test.



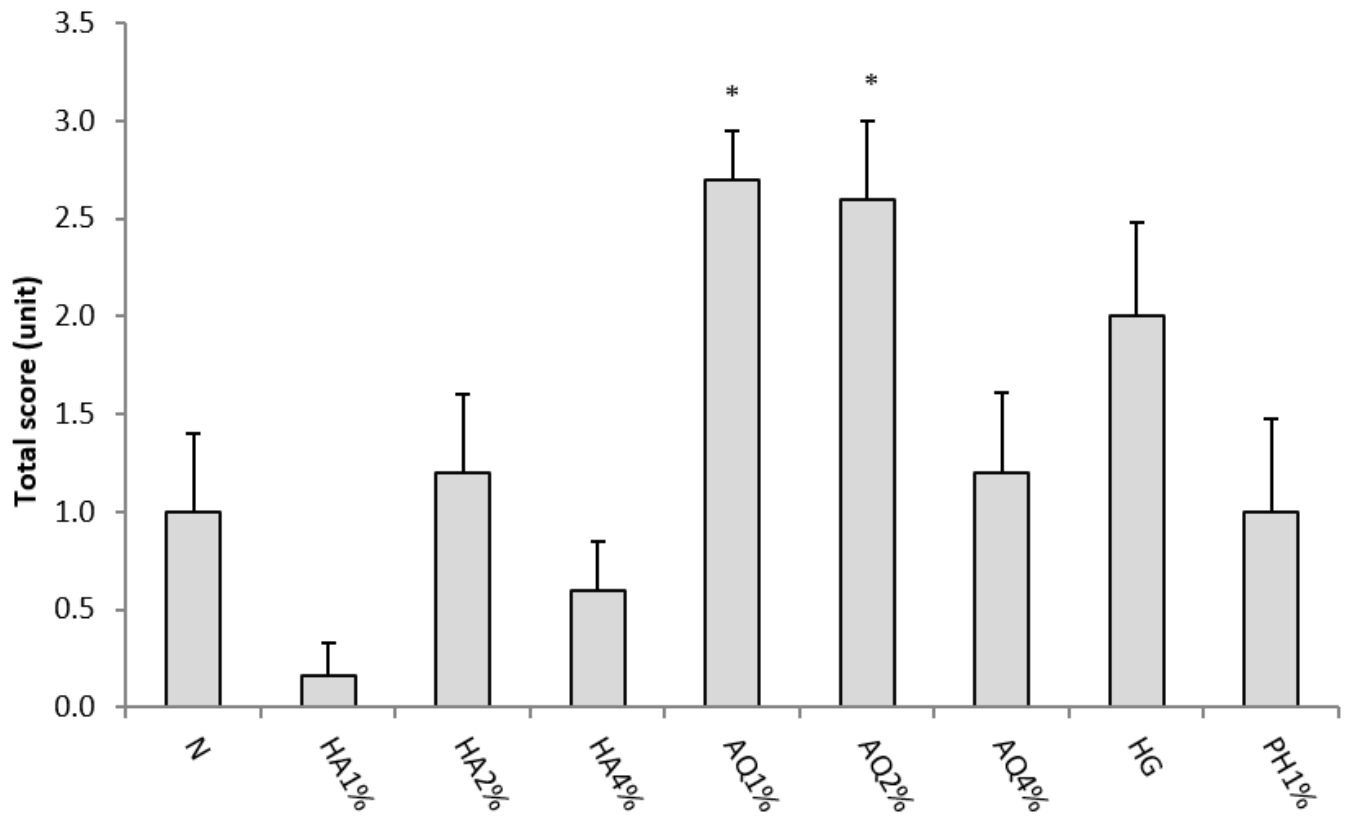
**Figure 12**

effects of hydroalcoholic (HA) and aqueous (AQ) extract of *Althaea officinalis* flowers (1, 2 and 4%, topical), phenytoin 1% cream (PH1%), hydrogel (HG) and normal saline (N, control group) on collagen formation in third-degree burn. Data are analyzed as mean  $\pm$  S.E.M, (n=6). \*P<0.05 in comparison with control group, one-way ANOVA followed by Tukey's post hoc test.



**Figure 13**

effects of hydroalcoholic (HA) and aqueous (AQ) extract of *Althaea officinalis* flowers (1, 2 and 4%, topical), phenytoin 1% cream (PH1%), hydrogel (HG) and normal saline (N, control group) on epithelialization in third-degree burn. Data are analyzed as mean  $\pm$  S.E.M, (n=6). \*P<0.05 in comparison with control group, one-way ANOVA followed by Tukey's post hoc test.



**Figure 15**

effects of hydroalcoholic (HA) and aqueous (AQ) extract of *Althaea officinalis* flowers (1, 2 and 4%, topical), phenytoin 1% cream (PH1%), hydrogel (HG) and normal saline (N, control group) on total score in third-degree burn. Data are analyzed as mean  $\pm$  S.E.M, (n=6). \*P<0.05 in comparison with control group, one-way ANOVA followed by Tukey's post hoc test.