Acupuncture in multidisciplinary treatment of post-COVID-19 Syndrome: A Case Report

Robert J. Trager (Robert.Trager@UHhospitals.org)
Connor Whole Health, University Hospitals Cleveland Medical Center, 11000 Euclid Ave, Cleveland OH 44106, USA https://orcid.org/0000-0002-4714-1076

Elise C. Brewka
Connor Whole Health, University Hospitals Cleveland Medical Center, 11000 Euclid Ave, Cleveland OH 44106, USA

Christine M. Kaiser
Connor Whole Health, University Hospitals Cleveland Medical Center, 11000 Euclid Ave, Cleveland OH 44106, USA

Andrew J. Patterson
University Hospitals Harrington Heart and Vascular Institute, University Hospitals Cleveland Medical Center, 11000 Euclid Ave, Cleveland OH 44106, USA

Jeffery A. Dusek
Connor Whole Health, University Hospitals Cleveland Medical Center, 11000 Euclid Ave, Cleveland OH 44106, USA https://orcid.org/0000-0001-9581-0564

Case Report

Keywords: Acupuncture, COVID-19, Fatigue, Complementary Therapies, Traditional Chinese Medicine, Pericardial Effusion, Exercise

Posted Date: March 8th, 2022

DOI: https://doi.org/10.21203/rs.3.rs-1421933/v1

Abstract

Background: Post-COVID syndrome (PCS) is a complex, multisystem illness that may follow SARS-CoV-2/COVID-19 infection. As there is limited evidence for individual therapies and no singular treatment for PCS, guidelines endorse a multidisciplinary approach. This case describes a post-COVID patient benefiting from acupuncture within a comprehensive approach alongside symptom-titrated physical activity (STPA).

Case: A 50-year-old woman presented upon Long-COVID Clinic referral to an outpatient hospital-affiliated acupuncturist with 8 months of fatigue, anosmia, chest pressure, palpitations, and other symptoms following mild assay-confirmed COVID-19. Prior/concurrent medical testing demonstrated multisystem-inflammatory involvement (pericardial effusion, thyroid dysfunction, elevated D-dimers). Cardiology/pulmonology cleared the patient for exercise to tolerance considering serious pathology was absent. The acupuncturist's Traditional Chinese Medicine impression was of Qi deficiency of the Heart, Lung, Spleen, and Kidney. The patient received 7 sessions of scalp, auricular, and body acupuncture. Physical therapist (PT) led STPA began 1-week post-acupuncture, involving six 30-minute exercise sessions while monitoring heart rate, with as-needed rest.

Results: Chest pressure and palpitations resolved after 1 acupuncture treatment. With 6 additional treatments spanning 9 weeks, overlapping with physical therapist-led SPTA, the patient completely recovered and resumed normal exercise habits.

Conclusions: In this case, acupuncture appeared to facilitate PCS recovery. However, the independent effects of acupuncture are less clear given the concurrent STPA/exercise therapy, and should be explored using larger study designs. Acupuncture is an attractive potential PCS therapy, considering its holistic approach and that it may be added to a multidisciplinary, guideline-concordant regimen.

Introduction

Post-COVID syndrome (PCS), also called long-COVID syndrome/condition, is a complex, multisystem illness,[1] diagnosed when symptoms persist 1–3 months post-COVID-19/SARS-CoV-2.[2] Given there is no singular PCS treatment, guidelines and expert panels recommend a multidisciplinary approach.[1–3] PCS is common, with 37% of COVID patients having at least 1 symptom 3 months' post-COVID.[4] Potential PCS risk factors include female sex, worse initial COVID-19 severity, and more initial symptoms.[5]

The most common PCS symptom is fatigue, affecting 58% of patients,[6] followed by headache, attention disorder, hair loss, and dyspnea, and others, with life-threatening conditions being rare (e.g. stroke, myocarditis).[6] Multiple-organ imaging abnormalities are found in 29% of PCS patients (i.e. lung, heart, kidney, liver, spleen, or pancreas).[7]

Evidence for PCS treatments is limited. Our literature search of PubMed and Google Scholar (November 1, 2021) identified few cases discussing acupuncture for PCS.[8,9] Despite limited evidence, guidelines consider symptom-titrated physical exercise (STPA) an option for PCS, with caution to not exacerbate symptoms.[10]

Materials And Methods

Patient information

A 50 year-old Caucasian woman (69 kg, 1.66 m, BMI 25), never-smoker, non-diabetic, who consumed ≤ 5 alcoholic drinks/week presented via Long-COVID Clinic referral to an Integrative Medicine outpatient clinic-based acupuncturist with fatigue, anosmia, ageusia, anxiety, dyspnea on exertion, chest pressure, dry cough, brain fog, and palpitations in August 2021, 35 weeks post-SARS-CoV-2 positivity/COVID-19 illness (Fig. 1). The patient reported fatigue for 1 month preceding this test, however her initial SARS-CoV-2 nasal swab was negative (November, 2020).

Post-COVID-19 to presentation, the patient became fatigued with everyday tasks (e.g. cooking). Pre-COVID-19, she exercised regularly without issue (Zumba®). Upon attempting returning to this 16 weeks-post-COVID she had to stop due to dyspnea, and “felt like [she] was going to have a heart attack.” Motivated to overcome fatigue, she would walk for 2-minute intervals to tolerance, later attempting brief periods of yardwork.

Pre-COVID-19, the patient had long-standing anxiety, managed successfully with citalopram and buspirone, however anxiety became exacerbated post-COVID-19. Pre-COVID she also had chronic, occasional temporal headaches, and remote appendectomy. Family history was significant for cerebrovascular accident and aortic aneurysm (father), and arthritis and colonic polyps (mother). Pre-COVID-19 to current she took an oral estrogen-progestin contraceptive, and over-the-counter multivitamin and calcium/vitamin D.

Her COVID-19 course involved no acute/major complications, with a 2-week home-quarantine, and no hospitalization, supplemental oxygen, or antiviral/antibiotic treatments. She received a 2-dose COVID-19 mRNA vaccination (Moderna, Inc.) 6/10 weeks post-COVID-19 which did not change PCS symptoms.

Medical care

The patient’s primary care internal medicine specialist evaluated her persistent COVID-19 symptoms (Fig. 1): Echocardiogram showed no acute findings, normal ejection fraction (55–60%), and small, inconsequential patent foramen ovale. Thyroid stimulating hormone (TSH) was serially elevated (6.55 and 4.10 mU/L) with reflex fT4 borderline-low (1.00 and 0.96 ng/dL). Complete blood count, urinalysis, and comprehensive metabolic panel were largely normal [mild hypoglycemia (70 mg/dL)]. Electrocardiogram, chest radiograph, and coronary calcium scan were normal.

Primary care referred her to a cardiologist, whose examination revealed no abnormalities. Blood pressure was 121/73 with a resting heart rate (HR) of 58 beats-per-minute (bpm). Brain natriuretic peptide (46 pg/mL) and troponin-I (< 0.02 ng/mL) were normal; a lipid panel was slightly abnormal (total cholesterol 224 mg/dL). D-dimers were elevated (815 ng/mL, normal ≤ 500). The cardiologist recommended self-directed-STPA with as-needed rest.

Primary care later consulted a pulmonologist via the hospital's "Long-COVID Clinic," who evaluated for myocarditis, pulmonary embolism, and reactive airway disease. Respiratory allergen profiles (ImmunoCAP™ IgE), pulmonary function tests, and computed tomography chest angiography were normal. Cardiac MRI revealed normal biventricular size/function without gadolinium enhancement to suggest prior infarct or infiltrative process. There was no aberration in T1/T2-weighted images to suggest underlying inflammation. A nonspecific small, circumferential pericardial effusion was appreciated, without pericardial hyperenhancement (Fig. 2). Six-minute walk testing provoked 4/10 dyspnea and 7/10 fatigue over normal-for-age distance. Overnight pulse oximetry (Virtuox, Inc.) revealed no nocturnal desaturation, indicating no need for supplemental oxygen. The pulmonologist referred her for a physical therapist (PT) led SPTA exercise program.

Acupuncture

The initial TCM impression based on patient symptoms and tongue/pulse examination (Table 1) was of Qi deficiency of the Heart, Lung, Spleen, and Kidney. The goal was to move Qi and tonify these Organs. The patient was treated by 2 Traditional Chinese Medicine (TCM) licensed acupuncturists (LAcs), the second treating visits 2–7, and recommended weekly treatments. Acupuncture needles (Seirin, Weymouth, MA, USA) were 0.20x30 mm (Meridian acupoints), 0.16x15 mm (ear), and 0.18x30 mm (scalp). Auricular needles were inserted before body needles, insertion depth varying from 0.1-1.0 cun. Thirty-minute needle retention with De Qi twisting and lifting techniques was well-tolerated.

Table 1
Acupuncture diagnosis, examination findings, and treatment

Visit	1	2	3	4	5	6	7
Diagnosis	NR	LU Qi xu, HT/SP Qi xu	LU Qi xu, HT/SP Qi xu, KI yang and yin xu	LR yang rising, LU Qi xu, SP Qi xu, KI yang and yin xu	LR yang rising, LU Qi xu, SP Qi xu, KI yang and yin xu	LR yang rising, LU Qi xu, SP Qi xu	LR yang rising, LU Qi xu
Tongue	NR	Thin white coating, red pink body, dry	Thin white coating, red pink body, dry	Sticky white coating, dusky pink red body, dry	Thin white coating, dusky red, dry	Thin white coating, dusky red pink, moist, prickles	Thick white coating, dusky pink body, dry, no sublingual veins visible
Pulse	NR	(R) Wiry (L) Floating	(R) Soft (L) Taut Deep weak chi	Moderate	(R) Soggy (L) Thin wiry	(R) Soggy (L) Thin deep	(R) Floating (L) Deep wiry, thin deep chi
Acupoints	GV20 (B) PC6, ST36, SP6, LR3 Scalp: Head and (B) Thoracic Auricular: (L) NADA	GV20 (B) K3, ST36, LU7, P6 (R) LI4, GB41, (L) LR3, TE5, SP6 Auricular: (R) NADA	GV20 (B) K3, ST36, LU7, SP6, SP7, SP9, ST25, (R) GB41, PC6 (L) TE5	GV20, GV24 (B) SP10, SP9, SP6, K3, ST36, LU7 (R) GB41, LI5, LI11 (L) TE5, LR3, LI10	GV20, (B) GB8, LR3, ST36, PC6 (R) SP9, LI4 (L) TE5, LI11, GB34	GV20, (B) LR3, SP6, SP7, SP9, ST36, LI4, PC6, LU7 (L) LI11	GV20, (B) LR3, GB8, GB34, GB41, LI4, GB20 (L) PC6 (R) LU7
Auricular beads			(B) Shenmen, SanJiao	(B) Shenmen, MidBrain, Lung, Adrenal		(B) Shenmen and Hungry point	(B) Shenmen and Hungry point

Abbreviations: Bilateral (B); deficiency (xu); Five Auricular NADA points: Shenmen, Sympathetic, Liver, Kidney, Lung; Gallbladder (GB), Governor Vessel (Dumai, GV); Heart (HT); Kidney (KI); Large Intestine (LI); Liver (LR); Lung (LU); left (L); Lung (LU); Pericardium (PC); Right (R); Small Intestine (SI); Spleen (SP); Stomach (ST); Triple Energizer (TE); right (R)

Physical therapy

Exercise testing revealed greater-than-expected HR increase during 1-floor stair-climbing (95 bpm, Polar-H10 Sensor), with mild, transient decrease in SpO_2 (96%). STPA was delegated to a PT-assistant, targeting a HR 119–136 bpm (70–80% maximum for patient's age) for 30–40 minutes with as-needed rest. Intensity-per-session increased dependent on patient tolerance and HR stability (Table 2).

Table 2
Symptom-titrated physical activity program supervised via physical therapy. Note that the first physical therapy appointment at 35 weeks post-COVID-19 is not shown, as this was an evaluation with no exercise therapy performed.

Weeks post-COVID	**36**	**37**	**38**	**39**	**40**	**46**
Visit	**1**	**2**	**3**	**4**	**5**	**6**
NuStep ® cross-trainer (minutes)	7	10		10	10	10
Mini squats (reps)	60		60			
Standing hip abduction (reps per side)	15	15	15			
6 inch step-ups (reps per side)	60		60			
Standing hip extension (reps)	15	15	15			
Sets of stairs (reps)	3	3	3	6	6	6
Biceps curls (3 lbs, reps)	5	15	15			
Deltoid front raise (2 lbs, reps)	15		15			
Deltoid lateral raise (2 lbs, reps)	15		15			
Deltoid raises (reps)						
Forward lunges (reps)		60		60	60	60
Carioca steps (reps)		60				
Wall push-ups (reps)		30				
Squat with military press (3 lbs, reps)		60				
Side steps (yellow Thera-Band, reps)				60	60	60
Monster walk (yellow Thera-Band, reps)				60	60	60
Mini squats with military press (5 lbs, reps)				60	60	60
Lateral lunges with weights (2 lbs, reps)				60	60	60
Hip raise (reps)				60	60	60
Abbreviations: Pounds (lbs), Repetitions (reps). A yellow Thera-Band® provides 1–6 lbs resistance						

Results

The patient reported feeling relaxed immediately after her first acupuncture treatment, and later noticed an absence of chest pressure and palpitations. At acupuncture visit 2, which began a period of overlap with PT-led-STPA, she reported having more energy. At visit 3, she reported being able to partly mow her lawn without dyspnea, and noted olfactory improvement. At visit 4, she noted further improvements in energy and reduced cough. At visit 5 she reported feeling “awake again,” without brain fog. She did her first heavy yardwork since pre-COVID-19. At visit 6 she noted improved energy and had resumed usual exercise classes. Progress was maintained at visit 7, in which she was treated for a typical/pre-COVID-19 temporal headache. The patient was doing well without PCS relapse 1-month later.

Discussion

To our knowledge, this case is the first to highlight potential benefits of acupuncture within multidisciplinary PCS treatment. Limitations include a lack of standardized patient-reported outcome assessments. Repeat testing (e.g. MRI, D-dimers) could have evaluated sequential changes. Recovery could be explained by the natural history of PCS. Findings from this case may not be broadly generalizable.

This patient had multisystem involvement affecting the heart (pericardial effusion) and thyroid (TSH), while elevated D-dimers suggested systemic inflammation and hypercoagulability.[5] These findings are relatively common in PCS, with elevated D-dimers in 6–39% of cases,[6] pericardial effusion in 27%, and hypothyroidism in 5–12%.[11,12] Although confirmatory thyroid testing (e.g. fT3, anti-thyroid antibodies) was not conducted, PCS-related hypothyroidism/thyroiditis could explain her fatigue and anosmia.[13] PCS-related pericardial effusion alone is unlikely to explain chest pain, dyspnea, and palpitations.[14]

According to a theory from Wu You-ke (CE 1582–1652), illnesses may persist when pathogenic Qi becomes lodged in the *moyuan* (membrane source), an energetic-anatomic area between the heart and diaphragm, and is transmitted through the Triple Energizer.[15] Some TCM authors have viewed COVID-19 as a pathogen affecting the *moyuan*, and multiple *Zang* (Lung, Heart, Kidney, Liver, Spleen) via its association with the Triple Energizer.[16,17] This concept could apply to the current case, given the heart/lung symptoms, pericardial effusion, chronicity, and acupuncture pulse/tongue diagnosis of Qi deficiency.

Acupuncture is an intriguing prospective therapy for PCS given its holistic, individualized approach, which parallels the varying symptoms and organ involvement of PCS. However, there may be some commonalities in TCM approaches to COVID/PCS, as 2 acupoints used in this case are among those most commonly used in acute COVID-19 (LI4/ST36).[18] Generally, stimulation of ST36 has been found to increase deep circulation,[19] possibly through nitric oxide production.[20] Further, one manuscript proposed that acupuncture’s positive circulatory effects could benefit COVID patients with elevated D-dimers.[21]

While the effects of acupuncture are intermingled with those of STPA, the patient had already been exercising to tolerance preceding PT-led-exercise without changes in PCS symptoms. In addition, chest

pressure/palpitations were alleviated rapidly upon starting acupuncture, preceding PT-led-STPA. Conversely, formal STPA supervision plausibly provided the patient a beneficial environment to safely exercise to her HR capacity and progress in recovery. We suspect acupuncture and exercise were synergistic, with PT-led-STPA helping regain strength/endurance from months of reduced activity, and acupuncture conceivably facilitating abrupt improvement in PCS symptoms.

This case highlights the potential utility of acupuncture within a multidisciplinary approach to a PCS patient without serious underlying medical comorbidity. Initiation of acupuncture, coupled with STPA, coincided with surpassing a plateau in PCS recovery.

Conclusions

Acupuncture is an attractive treatment for PCS considering its individualized, holistic approach, and could be considered within a guideline-recommended multidisciplinary approach to PCS including other therapies such as STPA/exercise. Considering the limited research regarding PCS treatment, acupuncture warrants further study in observational or randomized trials.

Patient perspective

My post-COVID experience was frustrating until multiple medical tests cleared me to focus on recovery, which included acupuncture and physical therapy. I had never tried acupuncture but was open to any solution that might make me feel better. I was surprised at the immediate impact I felt after my first acupuncture treatment and how quickly I started to return to normal life. Acupuncture not only helped me feel better physically, it gave me hope I would finally recover from long-COVID.

Declarations

Acknowledgements

The authors wish to thank the providers affiliated with the Long-COVID Clinic at our hospital for monitoring of this patient and others. We thank Cliff Tao, DC, DACBR with assistance with the imaging results. We also thank the patient for revising this manuscript to ensure its accuracy.

Author disclosure statement

There are no financial conflicts of interest.

Funding statement

The authors received no specific funding or grant for this study.

Ethics

This case report was deemed Not Human Subjects Research by the University Hospitals Institutional Review Board. The authors obtained written consent from the patient for publication of this case report.

Author contribution statement

RT, EB, CK, and JD conceived of the case report. AP interpreted imaging findings. All authors drafted, provided intellectual content, critically revised, and approved of the publication of the final manuscript.

References

1. Nurek M, Rayner C, Freyer A, Taylor S, Järte L, MacDermott N, et al. Recommendations for the recognition, diagnosis, and management of long COVID: a Delphi study. Br J Gen Pract [Internet]. 2021 Aug 2 [cited 2021 Oct 26]; Available from: https://bjgp.org/content/early/2021/10/04/BJGP.2021.0265
2. Shah W, Hillman T, Playford ED, Hishmeh L. Managing the long term effects of covid-19: summary of NICE, SIGN, and RCGP rapid guideline. bmj. 2021;372.
3. Landi F, Gremese E, Bernabei R, Fantoni M, Gasbarrini A, Settanni CR, et al. Post-COVID-19 global health strategies: the need for an interdisciplinary approach. Aging Clin Exp Res. 2020 Aug 1;32(8):1613–20.
4. Taquet M, Dercon Q, Luciano S, Geddes JR, Husain M, Harrison PJ. Incidence, co-occurrence, and evolution of long-COVID features: A 6-month retrospective cohort study of 273,618 survivors of COVID-19. PLOS Med. 2021 Sep 28;18(9):e1003773.
5. Yong SJ. Long COVID or post-COVID-19 syndrome: putative pathophysiology, risk factors, and treatments. Infect Dis Lond Engl.:1–18.
6. Lopez-Leon S, Wegman-Ostrosky T, Perelman C, Sepulveda R, Rebolledo P, Cuapio A, et al. More Than 50 Long-Term Effects of COVID-19: A Systematic Review and Meta-Analysis. Res Sq. 2021 Mar 1;rs.3.rs-266574.
7. Dennis A, Wamil M, Alberts J, Oben J, Cuthbertson DJ, Wootton D, et al. Multiorgan impairment in low-risk individuals with post-COVID-19 syndrome: a prospective, community-based study. BMJ Open. 2021;11(3):e048391.
8. Jiang D. Guidelines for Patient-Practitioner Contact and TCM Management in Post-COVID Syndromes. J Chin Med. 2021 Feb;(125):71–9.
9. Jania C. The Treatment of Long COVID with Chinese Medicine: A Case Report. J Chin Med. 2021 Oct;(127):17–22.
10. Safe Rehabilitation Approaches For People Living With Long COVID: Physical Activity and Exercise [Internet]. London, UK: World Physiotherapy; 2021 [cited 2021 Nov 4]. Available from:

https://world.physio/covid-19-information-hub/long-covid
11. Lania A, Sandri MT, Cellini M, Mirani M, Lavezzi E, Mazziotti G. Thyrotoxicosis in patients with COVID-19: the THYRCOV study. Eur J Endocrinol. 2020 Oct 1;183(4):381–7.
12. Anaya J-M, Rojas M, Salinas ML, Rodríguez Y, Roa G, Lozano M, et al. Post-COVID syndrome. A case series and comprehensive review. Autoimmun Rev. 2021 Nov;20(11):102947.
13. Tsivgoulis G, Fragkou PC, Karofylakis E, Paneta M, Papathanasiou K, Palaiodimou L, et al. Hypothyroidism is associated with prolonged COVID-19-induced anosmia: a case–control study. J Neurol Neurosurg Psychiatry. 2021;
14. Carubbi F, Alunno A, Leone S, Di Gregorio N, Mancini B, Viscido A, et al. Pericarditis after SARS-CoV-2 Infection: Another Pebble in the Mosaic of Long COVID? Viruses. 2021;13(10):1997.
15. Buck C. The Qing Dynasty and the Early 20th Century. In: Acupuncture and Chinese Medicine: Roots of Modern Practice. 1st edition. London: Singing Dragon; 2014. p. 279–324.
16. Zhao J, Flanagan C. Approaching covid-19 as damp toxin. Lantern. 2020;17(2):16–23.
17. Zhou Z, Gao N, Wang Y, Chang P, Tong Y, Fu S. Clinical Studies on the Treatment of Novel Coronavirus Pneumonia With Traditional Chinese Medicine—A Literature Analysis. Front Pharmacol. 2020;11:1355.
18. Chen C, Zhan J, Wen H, Wei X, Ding L, Tao C, et al. Current state of research about Acupuncture for the treatment of COVID-19: a scoping review. Integr Med Res. 2021 Oct 14;100801.
19. Takayama S, Watanabe M, Kusuyama H, Nagase S, Seki T, Nakazawa T, et al. Evaluation of the Effects of Acupuncture on Blood Flow in Humans with Ultrasound Color Doppler Imaging. Evid Based Complement Alternat Med. 2012 Jun 21;2012:e513638.
20. Tsuchiya M, Sato EF, Inoue M, Asada A. Acupuncture Enhances Generation of Nitric Oxide and Increases Local Circulation. Anesth Analg. 2007 Feb;104(2):301–7.
21. Wang Q, Wang C, Mei J, He L, Li J, Liu S, et al. [Understanding and prevention of D-dimer elevation in coronavirus disease 2019 in traditional Chinese medicine]. Zhonghua Wei Zhong Bing Ji Jiu Yi Xue. 2020 May;32(5):622–4.

Figures

Figure 1

Clinical timeline, including year, month, and weeks post-COVID relative to first positive test; symptoms, activity levels, laboratory findings, and other tests. Abbreviations: 6-minute walk test (6MWT); acupuncturist (A); cardiology (Card); complete blood count (CBC); comprehensive metabolic panel (CMP); computed tomography (CT); echocardiogram (Echo); electrocardiogram (EKG); elevated (↑); exercise (ex.); free thyroxine (fT4); integrative medicine (IM); magnetic resonance imaging (MRI); massage (Ma); minute

(min); month (Mo.); physical therapist (P); polymerase chain reaction (PCR); positive (+); primary care/general practitioner (GP); pulmonary function testing (PFT); pulmonologist (Pulm); thyroid stimulating hormone (TSH); urinalysis (UA); weeks following positive COVID test (Week). Red text indicates abnormal laboratory or other test findings. Dotted line indicates the start of acupuncture.

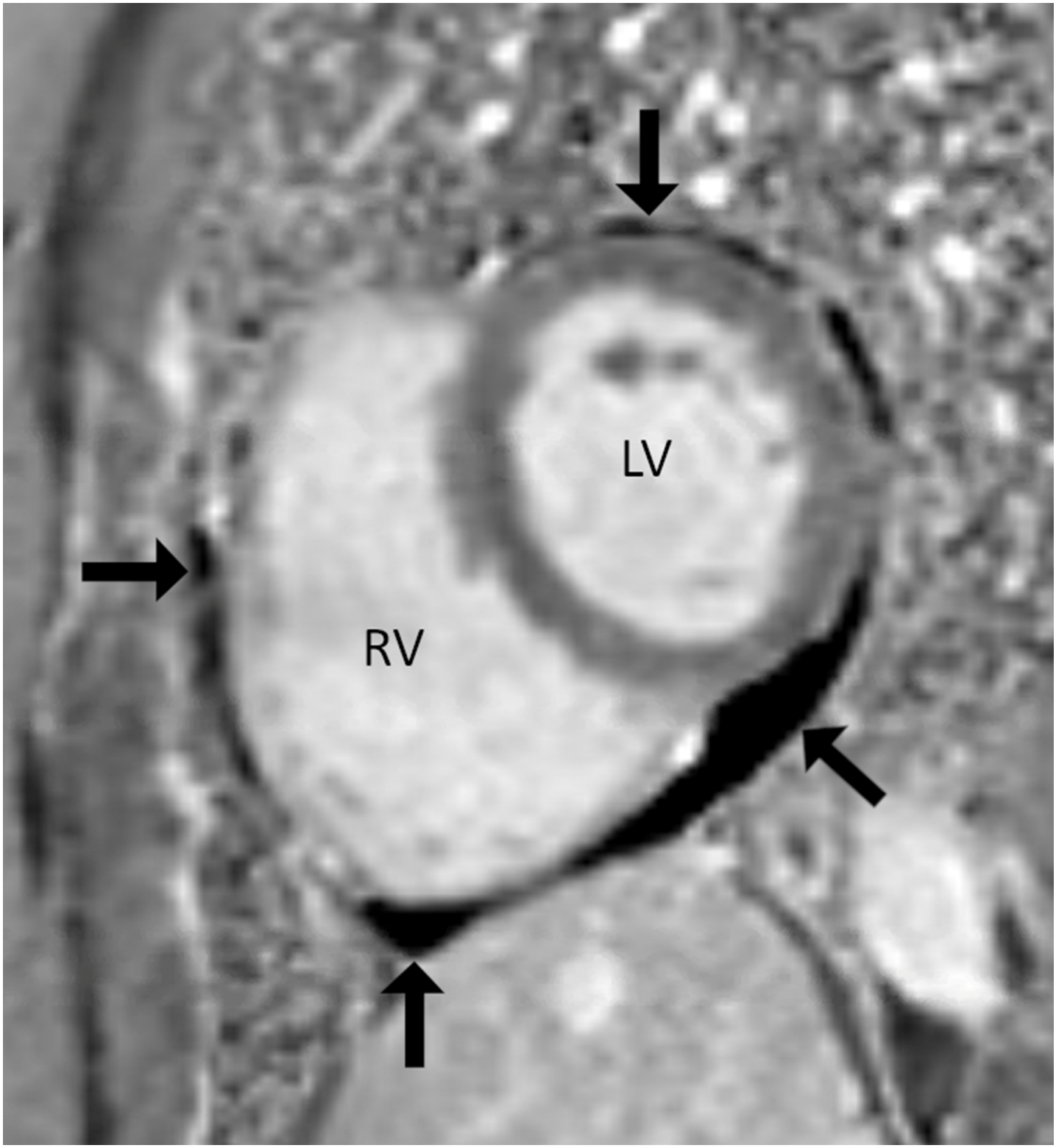

Figure 2

Pericardial effusion (arrows). Cardiac magnetic resonance image (MRI), short-axis view, phase-sensitive inversion recovery (PSIR) sequence. Arrows indicate a hypointense signal extending circumferentially around the heart, which represents a pericardial effusion. There is no pericardial thickening in this sequence, or enhancement with gadolinium in the other sequences, which are not shown. Abbreviations: left ventricle (LV), right ventricle (RV).