

Early Period Mitral Stenosis After Mitral Annuloplasty: Functional or Real Stenosis?

Serkan Asil (✉ dr_serkanasil@hotmail.com)

Gülhane Training and Research Hospital, Department of Cardiology, Ankara, Turkey

<https://orcid.org/0000-0002-6782-4237>

Veysel Özgür Barış

Dr Ersin Arslan Training and Research Hospital: Dr Ersin Arslan Eğitim ve Arastırma Hastanesi

Suat Görmel

Gülhane Training and Research Hospital: Ankara Gulhane Eğitim ve Arastırma Hastanesi

Murat Çelik

Gülhane Training and Research Hospital: Ankara Gulhane Eğitim ve Arastırma Hastanesi

Uygar Çağdaş Yüksel

Gülhane Training and Research Hospital: Ankara Gulhane Eğitim ve Arastırma Hastanesi

Case report

Keywords: Functional mitral stenosis, mitral annuloplasty stenosis, restrictive small ring annuloplasty

Posted Date: January 11th, 2021

DOI: <https://doi.org/10.21203/rs.3.rs-141458/v1>

License: © ⓘ This work is licensed under a Creative Commons Attribution 4.0 International License.

[Read Full License](#)

Abstract

Background:

Surgical repair of rheumatic mitral valve disease is technically more demanding however, mitral repair is preferred over mechanical valve implantation if possible. In this case report we presented the case of functional mitral stenosis after surgical mitral valve repair and annuloplasty ring implantation for rheumatic mitral regurgitation.

Case Report:

A 64-year-old female patient was admitted to our clinic with progressively worsening shortness of breath (New York Heart Association-Classification II-III), 6 months after surgical mitral valve repair and annuloplasty ring implantation for rheumatic mitral regurgitation. The 28/13 mmHg gradient was observed in the mitral valve annuloplasty ring in transthoracic echocardiography. TEE findings showed that motions of the mitral valve leaflet were fine, but in the mitral annuloplasty ring there was an extreme constriction and increased gradient.

Conclusion:

The development of mitral stenosis following mitral valve surgery is a condition associated with multiple mechanisms that are poorly understood. Mitral valve repair can be difficult and low success rate, especially in rheumatic mitral valve patients. The defect in the surgical technique and the application of restrictive small annuloplasty causes an increased gradient, leading to the development of severe functional mitral stenosis, especially when accompanied by a slight increase in pannus tissue.

Background

In primary MR, valve repair is the preferred treatment option (1, 2). Valve repair has lower left ventricular heart function impairment, lower complication rates, improved long-term outcomes, and no need for anticoagulation (1, 2). Most mitral valve repair techniques involve leaflet resection, suture repair, artificial chordae implantation and restrictive band or ring annuloplasty. These surgical manoeuvres may theoretically result in some degree of narrowing of the mitral valve orifice (3). However, surgical repair of rheumatic mitral valve disease is technically more demanding and has a higher potential failure rate compared with repair of degenerative disease. But especially, in the presence of less leaflet and subvalvular fibrosis, mitral repair can be the initial procedure of choice in rheumatic disease (4, 5). In this case report we presented the case of functional mitral stenosis after surgical mitral valve repair and annuloplasty ring implantation for rheumatic mitral regurgitation.

Case Report

A 64-year-old female patient was admitted to our clinic with progressively worsening shortness of breath (New York Heart Association-Classification II-III), 6 months after surgical mitral valve repair and annuloplasty ring implantation for rheumatic mitral regurgitation (28 mm Memo 3D Record Livonova®). The procedure reports reported to us that coronary artery bypass grafting (LAD-LIMA, AO-saphenous-OM1) and tricuspid annuloplasty ring were done in the same process.

The patient's physical examination showed apical diastolic murmur, mezocardiac systolic murmur and mild bilateral lower extremity oedema. Her laboratory parameters were near normal. She was using ramipril 2.5 mg 1 × 1, metoprolol 50 mg 1 × 1 and acetylsalicylic acid 100 mg 1 × 1. First of all, we performed transthoracic echocardiography (TTE) and the 28/13 mmHg gradient was observed in the mitral valve annuloplasty ring and increased systolic pulmonary artery pressure was also observed. After that, we decided to performed transoesophageal echocardiography (TEE). TEE findings showed that motions of the mitral valve leaflet were fine, but in the mitral annuloplasty ring there was an extreme constriction and increased gradient (Fig. 1A-D, **Video 1–2**). The case was addressed at the council of cardiology and cardiovascular surgery, and recommended redo mitral valve surgery for the case, but the patient refused.

Discussion

The development of mitral stenosis following mitral valve surgery is a condition associated with multiple mechanisms that are poorly understood. Currently, after mitral valve operation, functional mitral stenosis is defined as mean transmitral pressure gradient (TMPG) > 5 mmHg or mitral valve area (MVA) < 1.5 cm² regardless of aetiology. (6, 7). Also, effective orifice area indexed to body surface area (EOAi) < 0.9 cm²/m² defines severe prosthesis-patient mismatch (PPM) after MV replacement (8). Several factors have been associated with a higher risk for developing mitral stenosis after MV repair, including the use of flexible Duran annuloplasty rings versus rigid Carpentier Edwards rings, complete annuloplasty rings versus partial bands, small versus large anterior leaflet opening angle, and anterior leaflet tip opening length (9). In spite of all these reasons, mainly, early functional mitral stenosis after MV repair is thought to be a direct result of the restrictive small annuloplasty ring, late mitral stenosis is thought to be associated with the pannus overgrowth from the annuloplasty ring (7, 9).

Our patient's body mass index 32.9 kg/m², body surface area is 2.12 m² and when the TTE and TEE images of our patient were examined in detail, a restrictive small complete annuloplasty ring and mildly annular ring pannus formation were observed. In general, larger rings are recommended in treating rheumatic mitral disease, for example, 31 to 32 mm in men and 29 to 31 mm in women. If the body surface area is large, the larger annular ring should be implanted (10).

Like our patient, active obese individuals and high cardiac output state (anaemia, obesity, thyrotoxicosis) may cause an increase in the mitral pressure gradient. In such patients, the defect in the surgical technique and the application of restrictive small annuloplasty causes an increased gradient, leading to the development of severe functional mitral stenosis, especially when accompanied by a slight increase

in pannus tissue. In rheumatic mitral valve patients, repair surgery is more difficult and the results are worse than degenerative mitral valve repair surgery. So, the surgical technique, the diameter and structure of the annular ring to be used are very important.

Declarations

Conflict of Interest: None declared.

Ethical Approval and Consent to participate: Ethics committee approval is not required for case presentation, but informed consent was obtained from the patient.

Consent for publication: Not applicable

Availability of data and material: Not applicable

Competing interests: Not applicable

Funding/Supporting Institutions: None

Authors' contributions: The article was written by Serkan Asil and the other authors were help at the checking

Acknowledgements: Not applicable

Author's Information:

Serkan Asil¹ MD, Veysel Özgür Barış² MD, Suat Görmel¹ MD, Murat Çelik¹ MD Prof. Uygur Çağdaş Yüksel MD Prof.

¹Gülhane Training and Research Hospital, Department of Cardiology, Ankara, Turkey

²Gaziantep Ersin Arslan Training And Research Hospital Department of Cardiology, Gaziantep, Turkey

Corresponding Author: Serkan Asil, MD.

Gülhane Training and Research Hospital, Department of Cardiology, Ankara, Turkey

E-mail: dr_serkanasil@hotmail.com

References

1. Baumgartner H, Falk V, Bax JJ, De Bonis M, Hamm C, Holm PJ, et al. 2017 ESC/EACTS guidelines for the management of valvular heart disease. European heart journal. 2017;38(36):2739–91.
2. Nishimura RA, Otto CM, Bonow RO, Carabello BA, Erwin JP, Fleisher LA, et al. 2017 AHA/ACC focused update of the 2014 AHA/ACC guideline for the management of patients with valvular heart disease:

- a report of the American College of Cardiology/American Heart Association Task Force on Clinical Practice Guidelines. *J Am Coll Cardiol*. 2017;70(2):252–89.
3. Carpentier A. Cardiac valve surgery-the "French correction". *J Thorac Cardiovasc Surg*. 1983;86:323–37.
 4. Choudhary SK, Talwar S, Dubey B, Chopra A, Saxena A, Kumar AS. Mitral valve repair in a predominantly rheumatic population: long-term results. *Tex Heart Inst J*. 2001;28(1):8.
 5. Yau TM, El-Ghoneimi YAF, Armstrong S, Ivanov J, David TE. Mitral valve repair and replacement for rheumatic disease. *J Thorac Cardiovasc Surg*. 2000;119(1):53–61.
 6. Bertrand PB, Verbrugge FH, Verhaert D, Smeets CJ, Grieten L, Mullens W, et al. Mitral valve area during exercise after restrictive mitral valve annuloplasty: importance of diastolic anterior leaflet tethering. *J Am Coll Cardiol*. 2015;65(5):452–61.
 7. Kainuma S, Taniguchi K, Daimon T, Sakaguchi T, Funatsu T, Kondoh H, et al. Does stringent restrictive annuloplasty for functional mitral regurgitation cause functional mitral stenosis and pulmonary hypertension? *Circulation*. 2011;124(11_suppl_1):97–106.
 8. Dagenais F, Doyle D, Pibarot P. Impact of prosthesis-patient mismatch on survival after mitral valve replacement. *Circulation*. 2007.
 9. Shabsigh M, Lawrence C, Rosero-Britton BR, Kumar N, Kimura S, Durda MA, et al. Mitral valve stenosis after open repair surgery for non-rheumatic mitral valve regurgitation: a review. *Frontiers in cardiovascular medicine*. 2016;3:8.
 10. Antunes M, Magalhaes M, Colsen P, Kinsley R. Valvuloplasty for rheumatic mitral valve disease. A surgical challenge. *J Thorac Cardiovasc Surg*. 1987;94(1):44–56.

Figures

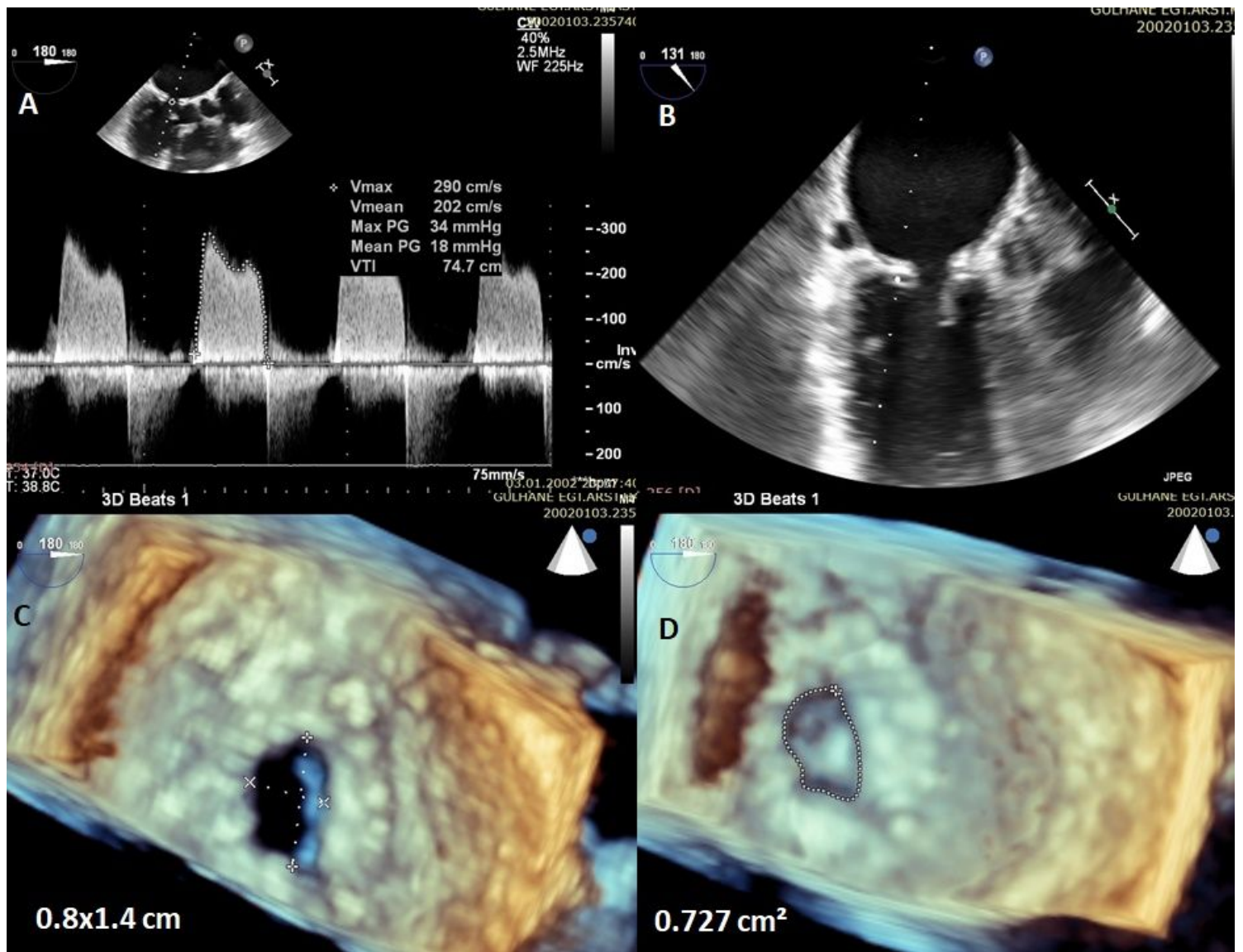


Figure 1

A-D: 2D and 3D image revealed restrictive small annuloplasty ring and increased gradient.

Supplementary Files

This is a list of supplementary files associated with this preprint. Click to download.

- [Video1.mp4](#)
- [Video2.mp4](#)