

# Treatment of Bronchial Anastomotic Fistula using Autologous Platelet-rich Plasma Post Lung Transplantation - A Case Report

**Aisha Siddique**

Alfaisal University

**Belal Nedal Sabbah**

Alfaisal University

**Tarek Ziad Arabi**

Alfaisal University

**Ismail Mohammed Shakir**

Alfaisal University

**Rayid Abdulqawi** (✉ [rabdulqawi@kfshrc.edu.sa](mailto:rabdulqawi@kfshrc.edu.sa))

King Faisal Specialist Hospital and Research Centre

**Khaled AlKattan**

King Faisal Specialist Hospital and Research Centre

**Mohamed Hussein Ahmed**

King Faisal Specialist Hospital and Research Centre

---

## Case Report

**Keywords:** Bronchial anastomosis, bronchial dehiscence, bronchopleural fistula, lung transplant, platelet-rich plasma, airway complications

**Posted Date:** March 7th, 2022

**DOI:** <https://doi.org/10.21203/rs.3.rs-1396724/v1>

**License:** © ⓘ This work is licensed under a Creative Commons Attribution 4.0 International License.

[Read Full License](#)

---

# Abstract

**Background:** Bronchial anastomotic dehiscence is considered one of the most catastrophic early airway complications post-transplant. The presence of a partial dehiscence can also cause further complications such as a fistula between the bronchus and the pleural membrane. Platelet-rich plasma (PRP) is known to significantly enhance the healing process and is being used in the treatment of various conditions, however, so far, there are no reports of the use of PRP in the treatment of bronchial anastomotic dehiscence fistula.

**Case Presentation:** We present a 37-year-old male, with non-cystic fibrosis bronchiectasis underwent bilateral lung transplantation. The patient developed partial dehiscence of the right bronchial anastomosis that was complicated by a small bronchopleural fistula. Two bronchoscopic applications of autologous platelet-rich plasma were carried out. Follow-up a few weeks later showed complete closure and healing of the fistula.

**Conclusions:** This case report suggests that the treatment of post-lung transplant small bronchial anastomotic partial dehiscence fistula with PRP is safe and effective.

## Introduction And Literature Review

Transplantation of the lungs is associated with significant post-surgical airway complications which contribute to increased morbidity and mortality. Since the first ever lung transplantation, efforts have been made to identify complications associated with transplant and streamline definitions, grading systems, and management aimed at reducing them. In addition, efforts have been directed towards exploring less invasive novel interventions to manage complications. Currently, the reported incidence for airway complications post-lung transplant ranges from 2-18% depending on the definition and grading system used.(1) The spectrum of bronchial complications includes bronchial stenosis, partial dehiscence, formation of granulation tissue, bronchopleural fistula, strictures, and tracheobronchial malacia. These complications may arise at either the anastomotic site or distal airways, with the right side being affected more than the left lung.(2)

Bronchial anastomotic partial dehiscence, which is essentially the splitting open of some sutures at the surgical anastomosis site, is considered one of the most catastrophic early airway complications post-transplant, with an incidence rate of 1-10%. Partial dehiscence of the airway most frequently occurs between 1 and 6 weeks post-transplant and may or may not be accompanied by mucosal necrosis. Partial anastomosis dehiscence may result in pneumothorax with persistent leakage and infection of the lungs and/or pleura. The usually asymptomatic nature and fatality associated with airway dehiscence has mandated the need for routine bronchoscopic surveillance.(1) Infection at the anastomotic site is one of the causes of delayed or poor healing and contributes to dehiscence. The most common pathogens are *Aspergillus*, *Candida*, *Rhizopus*, and *Mucor*.(1,3) The outcome of airway

dehiscence depends on various factors, including the severity of necrosis, extent of dehiscence, and any accompanying infections.

The presence of a partial airway dehiscence can also cause further complications, one of which is the formation of a fistula between the bronchus and the pleural membrane (i.e., bronchopleural fistula), which manifests as pneumothorax or subcutaneous empyema.<sup>(4)</sup> Anastomotic fistulas can expose the sterile pleural space to endobronchial bacterial flora. The resultant pleural effusion can leak into the major airways and spread to the peripheral alveolar spaces, which can cause severe aspiration pneumonia and/or empyema, which are potentially fatal.

Although there are a wide variety of treatment options available for anastomotic fistulas with varying therapeutic success, there is a lack of consensus regarding the ideal treatment option.

This report presents, for the first time, the successful treatment of a partial bronchial anastomosis dehiscence complicated by bronchopleural fistula in a bilateral lung transplant patient with autologous platelet-rich plasma (PRP). PRP consists of plasma with platelets and growth factors at concentrations much higher than those typically present in blood and is known to accelerate healing and regeneration.

## Case Description

### Case Presentation

A 37-year-old male, underwent bilateral lung transplantation for non-cystic fibrosis bronchiectasis. The patient developed partial dehiscence of the right bronchial anastomosis complicated by a bronchopleural fistula 29 days post-transplant. Upon assessment there was no evidence of pneumothorax, however, the presence of a small fistula was identified and confirmed both by bronchoscopy and CT imaging. The fistula was found to cause empyema in the right lung. Two bronchoscopic applications of autologous platelet-rich plasma of 40 mL and 10 mL were carried out on post-op days 36 and 43, respectively. Follow-up showed complete closure and healing of the fistula on post-op day 50 (Fig. 1).

### Post-transplant Infectious Events and Complications

The patient underwent a double lung transplant while on central ECMO support and was mechanically ventilated for two days. The ischemia times were 5 hours 22 minutes and 7 hours 14 minutes for the right and left lung, respectively. Six days after extubation, the patient developed hypoxic respiratory failure, so he was intubated again and extubated successfully two days later. During his ICU stay, the patient developed right sided loculated pleural effusion and empyema; pleural fluid culture grew *Klebsiella pneumoniae*. In addition, he developed donor-derived pneumonia with multidrug-resistant *Pseudomonas aeruginosa* and a carbapenemase-producing *Klebsiella pneumoniae* OXA-48 gene that was complicated by secondary bacteremia. Initially, he was placed on a broad-spectrum antibiotic with colistin that was later changed to ceftazidime-avibactam for six weeks. He was also treated with a course of tobramycin

for decolonization of MDR *Pseudomonas aeruginosa*. To control the empyema, a right chest tube was inserted for drainage.

Surveillance bronchoscopy one month post-op showed mucosal sloughing at the areas of anastomosis with possible dehiscence in the right bronchus forming a bronchopleural fistula (Fig. 2). The transbronchial biopsies did not reveal any acute cellular rejection. Chest CT 6 days later showed left-sided empyema with partial dehiscence of the right bronchial anastomosis forming a bronchopleural fistula (Fig. 3). The patient was then scheduled for left-sided chest drain insertion and autologous PRP application at the site of dehiscence using bronchoscopy.

## Preparation of platelet-rich plasma (PRP)

The platelet-rich plasma was prepared after harvesting plasma from a sample of the patient's blood (whole blood concentration:  $238 \pm 38 \times 10^3/\mu\text{L}$ , mean  $\pm$  SD) using the Arthrex ACP Double Syringe System (ACP, Arthrex concentration:  $470 \times 10^3/\mu\text{L}$ ).

## Treatment with platelet-rich plasma

Autologous PRP was applied via bronchoscopy to the right bronchial dehiscence on two occasions one week apart. The first application took place 36 days post-op; 40 mL of PRP was applied to the site of the anastomotic dehiscence fistula via bronchoscopy until completely covered. The second bronchoscopic application of 10 mL was carried out on postoperative day 43, when the old anastomotic fistula was nearly closed. Bronchoscopy performed on postoperative day 50 showed complete closure and healing of the anastomotic fistula, so no further PRP was applied (Fig. 4). Long-term follow-up and surveillance bronchoscopy, postop day 162, revealed resolution of the anastomotic fistula (Fig. 5). Overall, there were no complications, and the patient tolerated all the procedures well.

## Discussion

Post-lung transplantation airway complications contribute significantly to the morbidity and mortality of patients, with ischemia of the donor bronchi being the primary cause of such complications.(1) Bronchi obtain their blood supply from both the bronchial and pulmonary circulations; therefore, they are supplied by well-oxygenated blood from the aorta and/or intercostal arteries, whereas the pulmonary artery circulation contains deoxygenated blood. In lung transplantation, donor bronchial vessels are not connected to the recipient bronchial vessels, leaving the donor bronchi dependent on the low oxygenated pulmonary arterial supply. Vascularization of donor bronchi by the recipient bronchial circulation occurs 2–6 weeks post-transplant. Therefore, low perfusion of the pulmonary circulation in the first 6 weeks may result in airway complications. The main risk factors contributing to airway complications are poor lung preservation, prolonged ischemia times, long donor bronchus, certain surgical techniques, primary graft dysfunction, acute rejection, infection, hypotension, donor-recipient height mismatch, mTOR inhibitors, and prolonged mechanical ventilation/high PEEP.(1)

In the management of a partial bronchial dehiscence, deployment of airway stents, both covered and uncovered, has been used through flexible or rigid bronchoscopy. However, their use remains controversial due to the associated risks of infection, migration and bronchial injury. The use of fibrin glue through bronchoscopy has been described in cases of partial dehiscence. Surgical repair of the anastomosis is reserved for severe cases or failure to improve cases. In addition, management includes treating associated complications such as pneumothorax and pleural infection.

In the case presented here, the development of a partial anastomotic dehiscence and subsequent bronchopleural fistula 29 days (intermediate-onset) post-bilateral lung transplant could have been due to predisposition to any of the risk factors, including prolonged use of mechanical ventilation, prolonged hospital stay, donor-derived pneumonia with multidrug-resistant *Pseudomonas aeruginosa*, carbapenemase-producing *Klebsiella pneumonia*, and secondary bacteremia. A recent study showed that carbapenemase-producing *Klebsiella pneumonia* significantly increased the risk of developing bronchial anastomotic dehiscence in post-lung transplant patients.(3)

Platelet-rich plasma (PRP) is an autologous serum preparation that contains a high level of platelets.(5) PRP is easily obtainable and has been reported as an effective tool to promote wound healing. This wound healing property is explained by the fact that PRP releases abundant growth factors after application to tissues(6) and enhances healing by increasing the production of collagen and fibroblasts. (7) PRP can be easily prepared, and the storage cost is minimal; however, the potential for clinical use is limited to within 5–8 days of preparation. The use of PRP is steadily increasing and has been employed to treat various pathologies, including but not limited to, perianal fistulas in Crohn's disease, recurrent vesicovaginal fistulas, oro-antral fistulas, and musculoskeletal pathologies.(8) One recent study reported 3 successful cases of autologous PRP injections to resolve one tracheobronchial fistula and two BPFs varying in size (4–8 mm), all post-lobectomies following different pathologies other than post-lung transplant.(9) Another study conducted on PRP usage as adjuvant therapy for the resolution of vesicovaginal fistulas reported resolution of the fistula with no complications or adverse effects.(10) Additionally, PRP treatment has been studied in porcine models with tracheal resection, where healing of end-to-end anastomosis was accelerated by promoting the release of platelet-derived growth factors (PDGF) and stimulating trans-anastomotic vessel formation.(11)

To the authors' knowledge, there have been no previous case reports describing the use of PRP in the management of anastomosis fistula post-lung transplant. The innovative application of platelet-rich plasma in the treatment of anastomotic fistulas, particularly in patients with challenging presentations, seems to be an intervention with favorable surgical outcomes. Moreover, the technique discussed in this report is effective, relatively safe, reproducible, and requires minimal resources at least for small bronchial anastomotic dehiscence fistulas. However, further studies are required to confirm the effectiveness of PRP in the healing of bronchial anastomotic fistulas of larger sizes. Additional studies comparing traditional management methods with PRP treatment for bronchial anastomotic dehiscence fistula are also warranted. In addition, the optimal number, quantity, method, and timing of PRP applications or injections in the context of favorable surgical outcomes must also be determined.

# Declarations

**Funding:** This study did not receive funding from any source.

**Conflicts of interest/Competing interests:** The authors declare no conflict of interest.

Availability of data and material: Not applicable

Code availability: Not applicable

**Authors' contributions:** AS, BNS, TZA, IMS, RA, and MHA drafted the manuscript. KK contributed to reviewing and finalizing the manuscript. MHA and KK also provided the imaging findings and their interpretation for the case. All authors reviewed the manuscript for intellectual content and approved the submission.

**Ethics approval:** Approval to publish this case report was given by the King Faisal Specialist Hospital and Research Center IRB. Patient anonymity is maintained throughout this manuscript, and consent was obtained for publication from the patient. All methods were performed in accordance with the Declaration of Helsinki.

**Consent to participate:** Not applicable

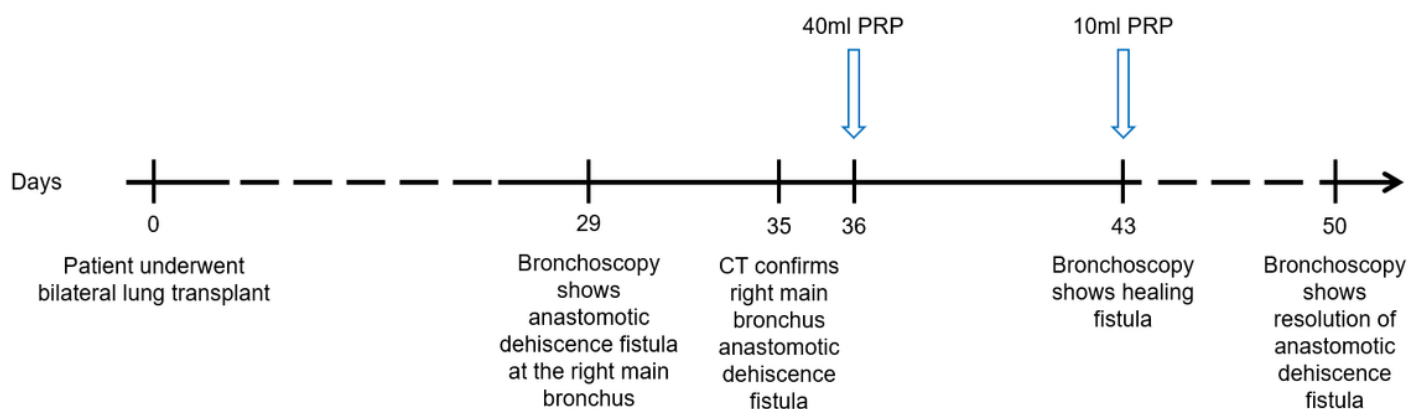
**Consent for publication:** Patient anonymity is maintained throughout this manuscript and approval to publish this case report was given by the King Faisal Specialist Hospital and Research Center IRB. All methods were performed in accordance with the Declaration of Helsinki.

# References

1. Crespo MM, McCarthy DP, Hopkins PM, Clark SC, Budev M, Bermudez CA, et al. ISHLT Consensus Statement on adult and pediatric airway complications after lung transplantation: Definitions, grading system, and therapeutics. *Journal of Heart and Lung Transplantation*. 2018 May 1;37(5):548–63.
2. Santacruz JF, Mehta AC. Airway complications and management after lung transplantation: ischemia, dehiscence, and stenosis. *Proceedings of the American Thoracic Society*. 2009 Jan;6(1):79–93.
3. Suh JW, Lee JG, Jeong SJ, Park MS, Kim SY, Paik HC. Risk of Bronchial Dehiscence in Lung Transplant Recipients With Carbapenemase-producing *Klebsiella*. *The Annals of Thoracic Surgery*. 2020 Jul 1;110(1):265–71.
4. Marczin N, de Waal EEC, Hopkins PMA, Mulligan MS, Simon A, Shaw AD, et al. International consensus recommendations for anesthetic and intensive care management of lung transplantation. An EACTAIC, SCA, ISHLT, ESOT, ESTS, and AST approved document. *The Journal of heart and lung*

- transplantation: the official publication of the International Society for Heart Transplantation. 2021 Nov 1;40(11):1327–48.
5. Wu PIK, Diaz R, Borg-Stein J. Platelet-Rich Plasma. Physical medicine and rehabilitation clinics of North America. 2016 Nov 1;27(4):825–53.
  6. Eppley BL, Woodell JE, Higgins J. Platelet quantification and growth factor analysis from platelet-rich plasma: implications for wound healing. Plastic and reconstructive surgery. 2004 Nov;114(6):1502–8.
  7. Marx RE. Platelet-rich plasma: evidence to support its use. Journal of oral and maxillofacial surgery: official journal of the American Association of Oral and Maxillofacial Surgeons. 2004;62(4):489–96.
  8. Yilmaz G, Tanrikulu Y. Short-term Results of Platelet-Rich Plasma in the Treatment of Chronic Anal Fissure: Randomized Controlled Clinical Study. Diseases of the colon and rectum. 2021;64(6):714–23.
  9. Wu M, Lin H, Shi L, Huang L, Zhuang Y, Zeng Y. Bronchoscopic Treatment of Tracheobronchial Fistula With Autologous Platelet-Rich Plasma. The Annals of thoracic surgery. 2021 Feb 1;111(2):e129–31.
  10. Streit–ciećkiewicz D, Futyma K, Miotła P, Grzybowska ME, Rechberger T. Platelet-Rich Plasma as Adjuvant Therapy for Recurrent Vesicovaginal Fistula: A Prospective Case Series. Journal of Clinical Medicine 2019, Vol 8, Page 2122. 2019 Dec 2;8(12):2122.
  11. Gómez-Caro A, Ausin P, Boada M. Platelet rich plasma improves the healing process after airway anastomosis. Interactive Cardiovascular and Thoracic Surgery. 2011 Dec 1;13(6):552–6.

## Figures



**Figure 1**

A graphic representation of the timeline of the case. The blue arrows depict the time of PRP application.

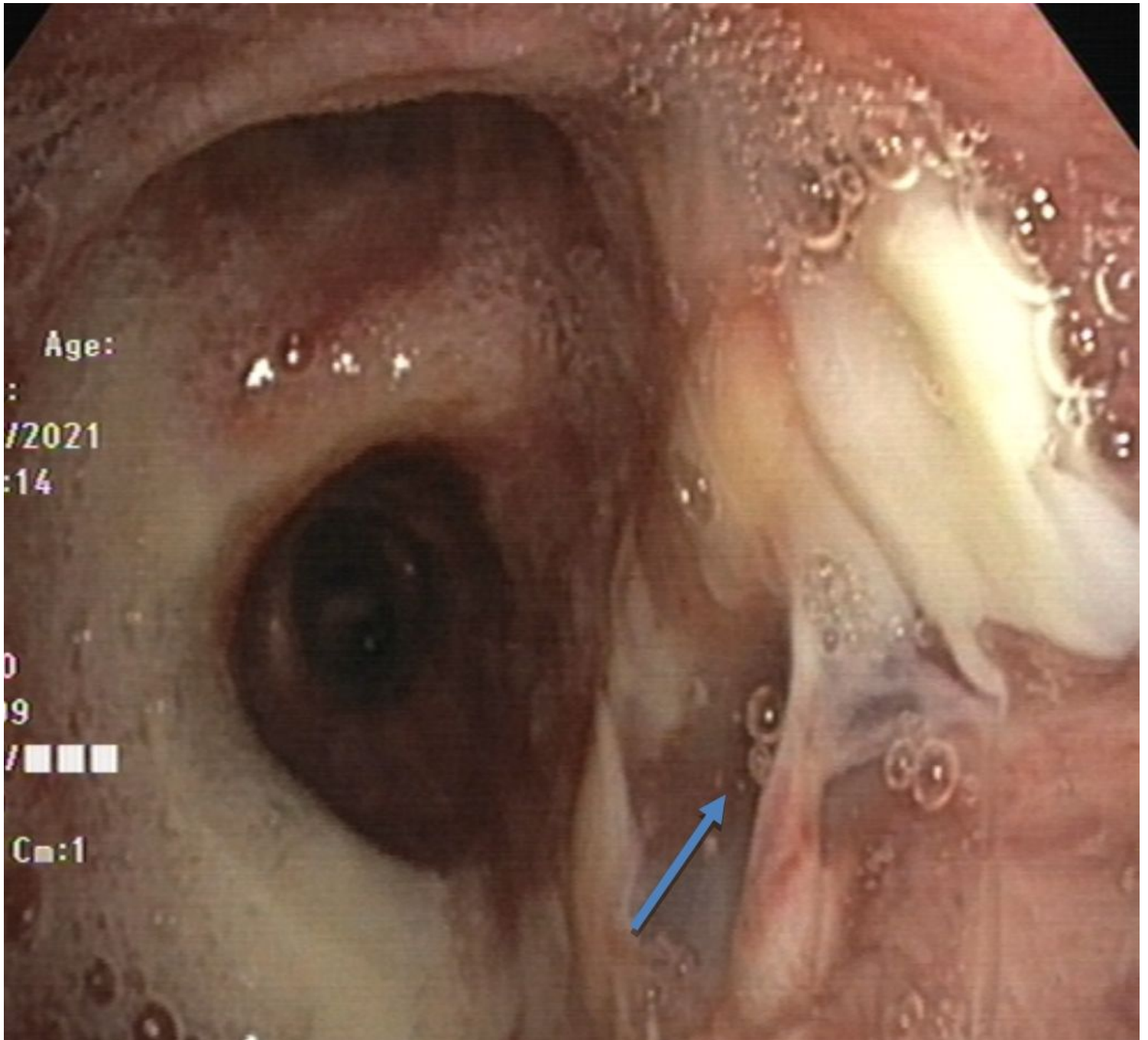
## Figure 2

Surveillance bronchoscopy showing the bronchopleural fistula (arrow) at the right main bronchus as the result of partial dehiscence of the anastomosis.

## Figure 3

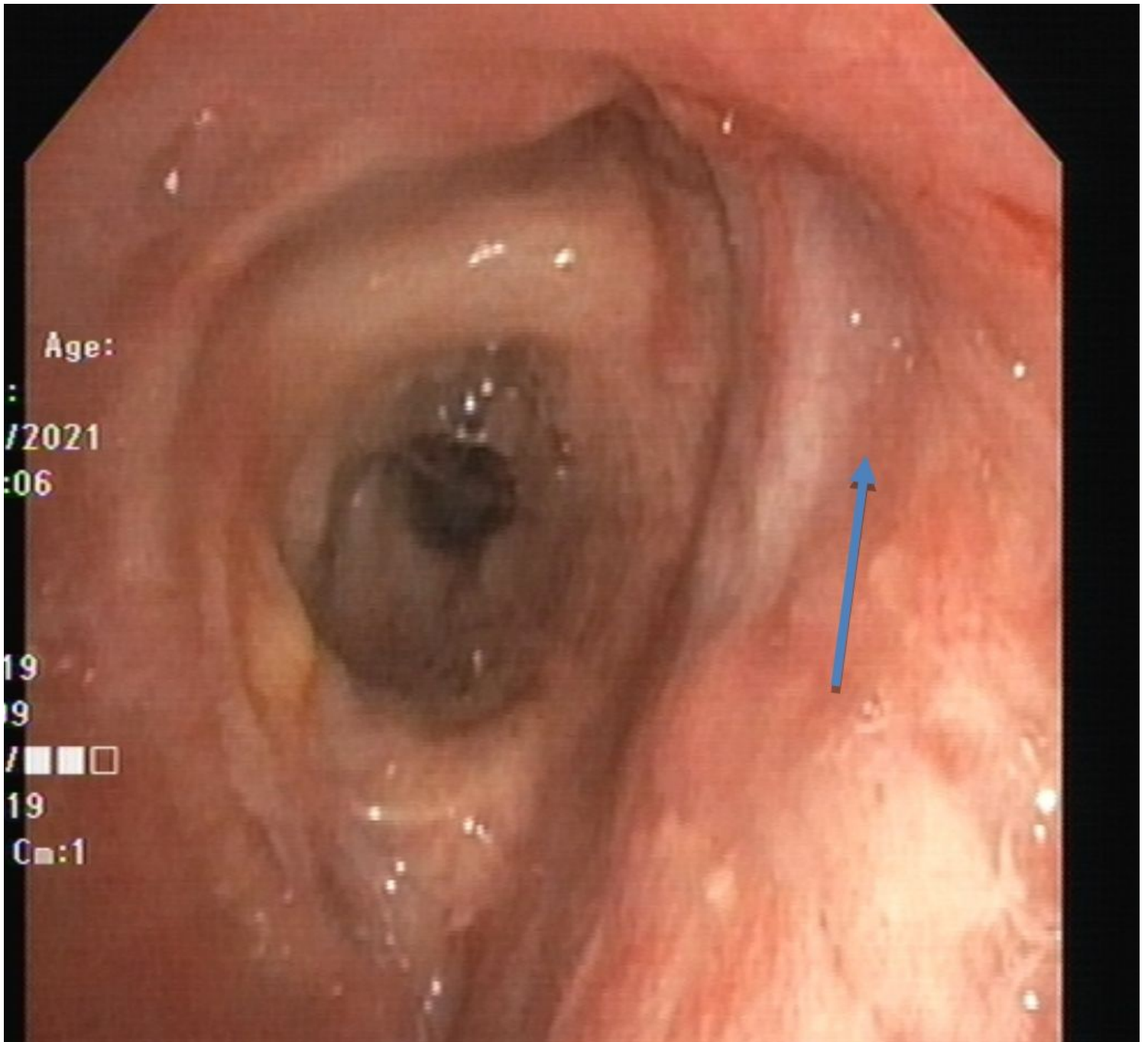
Day 35 post-transplant chest CT showing partial dehiscence and a small bulging contour along the posterior aspect of the right bronchial anastomosis with adjacent tiny air foci (arrow) concerning a partial dehiscence.





**Figure 4**

Bronchoscopy on post-op day 50. Previous fistula at the right main stem bronchus completely closed (arrow) after the previous PRP applications.



**Figure 5**

Bronchoscopy on post-op day 162 showing resolution of the fistula (arrow)