

Choroidal Thickening in Patients with Coronavirus Disease – 2019

Mojtaba Abrishami

Mashhad University of Medical Sciences

Zahra Emamverdian

Mashhad University of Medical Sciences

Ramin Daneshvar (✉ radaneshvar@gmail.com)

Mashhad University of Medical Sciences Khatam-al-Anbia Hospital <https://orcid.org/0000-0002-0884-0907>

Neda Saeedian

Mashhad University of Medical Sciences

Fariba Tohidinezhad

Mashhad University of Medical Sciences

Mohsen Seddigh-Shamsi

Mashhad University of Medical Sciences

Mehdi Mazlumi

Wills Eye Hospital

Saeid Eslami

Mashhad University of Medical Sciences

Original research

Keywords: SARS-CoV-2, Coronavirus Disease 2019, COVID-19, Optical Coherence Tomography, Retina, Choroid, Macula

Posted Date: January 5th, 2021

DOI: <https://doi.org/10.21203/rs.3.rs-137661/v1>

License: (cc) (i) This work is licensed under a Creative Commons Attribution 4.0 International License.

[Read Full License](#)

Abstract

Objective: To evaluate choroidal thickness in the macular region of patients with coronavirus disease 2019 (COVID-19).

Methods: Patients recovered from COVID-19 were included in this cross-sectional study. Macular imaging with an SD-OCT device was performed at least 2 weeks after recovery from systemic COVID-19 and choroidal thickness was measured as the main outcome measure.

Results: Thirty-four subjects were included in this study. One patient was monocular and high-quality SD-OCT images were available for the remaining 67 eyes. Dilated choroidal vessels were observed in 55 eyes (82%) and retinal pigment epitheliopathy was noticeable in 4 eyes (6%); these findings resemble those of the pachychoroid spectrum. The mean subfoveal choroidal thickness (SFCT) in our patients was $380.3 \pm 12.40 \mu\text{m}$, which was significantly thicker than the previously reported SFCT in the normal population ($310.7 \pm 57.5 \mu\text{m}$) ($p < 0.001$).

Conclusion: Patients with COVID-19 demonstrate remarkable changes in the choroid of the macular region.

Introduction

Severe acute respiratory syndrome coronavirus 2 (SARS-CoV-2) is a highly contagious and pathogenic human coronavirus. The virus can cause a spectrum of diseases from mild asymptomatic cases to severe, fatal conditions with multiorgan failure. Although the majority of cases have a good prognosis, the number of cases and the death toll is still rising sharply worldwide.[1] The first cluster of cases was reported by China health authority from Wuhan city, Hubei province, China to the World Health Organization (WHO) on December 31, 2019. Thereafter, the WHO declared the COVID-19 outbreak as a Public Health Emergency of International Concern (PHEIC) on January 30, 2020, and recognized it as a global pandemic on March 11, 2020.[2, 3]

Coronaviruses have already been shown to cause ocular infection in mammals and it seems reasonable to anticipate ocular manifestations with SARS-CoV-2 infection;[4] however, no significant ocular finding was previously reported in the Middle East Respiratory Syndrome Coronavirus (MERS-CoV) and SARS-CoV infections.[5] There are few publications on ocular manifestations of COVID-19 and the majority of them originate in Eastern Asia.[4, 6–9]. Most frequent ocular findings were in the anterior segment and included conjunctival hyperemia, chemosis, epiphora, and increased ocular secretions.[6] We recently published an article on ocular findings in hospitalized patients with COVID-19, and found conjunctival congestion and hyperemia as the most frequent anterior segment findings, followed by chemosis.[10] Ocular findings were observed in more than half of our cases.[10]

Recently, Casagrande and coworkers detected SARS-CoV-2 viral RNA in retinal biopsy specimens of 3 patients out of 14 cases deceased with COVID-19 and underwent autopsy.[11] Furthermore, Marinho and

associates presented SD-OCT findings in 12 patients with COVID-19 and reported hyperreflective lesions at the level of ganglion cell and inner plexiform layers in all cases.[12] However, the significance of their findings was questioned in a later editorial by Vavvas and coworkers who suggest that the findings could be normal retinal vessels.[13] As vascular involvement is a well-identified aspect of COVID-19 and peripapillary vascular changes have been reported recently, it is not surprising to expect chorioretinal involvement in these patients.[14] Hereby, we presented detailed SD-OCT findings of the macular region in a prospective cohort of 67 eyes of 34 patients recovered from COVID-19. We aimed to investigate the choroidal changes and the chronological relationship between SD-OCT findings and the disease course.

Methods

Study Participants

A cross-sectional study was conducted in Imam Reza General Hospital, a tertiary referral center, devoted to COVID-19 patients in Northeast Iran. Patients recovered from COVID-19 in this center were included in the study. All included subjects had a definite diagnosis of COVID-19, confirmed by a positive test result of real-time, reverse transcription-polymerase chain reaction (RT-PCR) of nasopharyngeal swab sample, and had at least a two-week recovery period. Patients with a past medical history of diabetes mellitus, systemic hypertension, or dementia, and those with a history of any intraocular surgery, were excluded. Comprehensive medical history with a special focus on manifestations and course of COVID-19 were obtained. “Disease Duration” was defined as the time interval between the initiation of systemic manifestations and the complete recovery of these findings. “Recovered Period” was defined as the time interval between the termination of systemic symptoms and the time of image acquisition. “Diseased Interval” was used to specify the time interval between the initiation of systemic symptoms and the time of image acquisition (i.e., ‘Disease Duration’ + ‘Recovered Period’). Oxygen saturation at the time of examination was measured by a portable pulse oximeter (Nonin 7500 Pulse oximeter, Nonin Medical Inc, Plymouth, MN) and refraction was evaluated by an automated keratorefractometer (KR-1 Auto-Kerato-Refractometer, Topcon Medical Systems, Inc. Tokyo, Japan).

OCT Image acquisition

The macular area of eligible subjects was imaged on an SD-OCT device (AngioVue, Optovue RTVue XR Avanti, Optovue, Fremont, CA). The device uses a laser beam with a wavelength of 840 nm and a scan rate of 70 kHz to obtain the images. Raster, Cross Line, Enhanced HD Line, and Retina Map protocols were used to evaluate the retina and choroid in the macular region of the patients. A panel of three experienced examiners (MA, MM, RD) evaluated each SD-OCT image to pinpoint any retinal or choroidal finding and measure the subfoveal choroidal thickness (SFCT). Any disagreement was resolved by discussion and consensus of all examiners. The SFCT was measured using the ‘Crossline Images’. Briefly, each horizontal or vertical foveal scan of the device is an average of at least twenty B-scan of the macular area with a width of 10 mm; these horizontal and vertical ‘crosslines’ are centered at the fovea and perpendicular to each other. To measure the SFCT, we used the ‘Caliper tool’ within OptoVue machine

software (version 2018.0.0.14) to determine the minimum distance between the outer aspect of Bruch's membrane (identified as a hyperreflective line) and the border of the sclera (i.e., the innermost hyperreflective line of the choriocleral interface). The measurement was repeated in both horizontal and vertical scans and the average was considered as the SFCT.

Statistical Analysis

Statistical analysis was performed using the SPSS program for Windows, version 20 (IBM SPSS Statistics, IBM Corporation, Chicago, IL, USA). Descriptive statistics were used to describe the main variables by providing central tendency measures for continuous variables and frequencies for categorical variables. The normal distribution of variables was evaluated through the Shapiro-Wilk test and normality plots. One sample t-test was used to compare the mean of SFCT with the previously reported mean SFCT in the same background population.[15] Independent sample t-test and Fisher's exact test were respectively used to compare continuous and categorical variables between any two subgroups defined within the study population. Pearson correlation test was used to find any possible correlation between continuous variables. For all tests, a *p*-value less than or equal to 0.05 was considered statistically significant.

Ethical Considerations

The study protocol adhered to the tenets of the 1964 Declaration of Helsinki and its later amendments. All subjects participated in the study voluntarily at their convenience and provided written informed consent at the enrolment. The researchers had no superiority to the participants and worked in a separate institution. The study protocol was approved and supervised by the Regional Medical Ethics Committee at Mashhad University of Medical Sciences, Mashhad, Iran (IR.MUMS.REC.1399.104).

Results

Sixty-seven eyes of 34 patients were included in this study. The mean age of participants was 39.6 ± 1.7 years and eighteen (52.9%) were male. All included subjects had a positive RT-PCR test result of the nasopharyngeal swab sample in at least one examination. Fifteen cases were paramedics/ nurses and eight were physicians (six residents, two faculty members). Ten out of 34 patients were hospitalized, but none required intensive care. One hospitalized patient was monocular and lost his left eye because of an open globe injury in childhood.

Dilated choroidal vessels were observed in 55 eyes (82%) and retinal pigment epitheliopathy ($n = 4$ eyes, 6%) (Fig. 1). The SFCT ($380.3 \pm 12.40 \mu\text{m}$) was significantly thicker than the previously reported SFCT in normal background population ($310.7 \pm 57.5 \mu\text{m}$) ($p < 0.001$).[15]

There was a significant positive correlation between the "Disease Duration" and the SFCT (Pearson correlation test, $r = 0.48$, $p = 0.004$). Nor "Disease Interval", neither "Recovered Period" demonstrated a statistically significant correlation with SFCT. Patients who had a "Recovered Period" of more than 30 days, were more likely to display hyperreflective lesions in choriocapillaris compared to the patients with

a shorter period since recovery (Fisher's Exact Test, $p = 0.01$). No other difference was noted between these two groups in terms of abnormal SD-OCT findings. No difference was noted in the frequency or type of abnormal SD-OCT findings between hospitalized and outpatient cases.

Discussion

In this study, we evaluated the macular SD-OCT findings in retinal and choroidal layers of patients recovered from COVID-19 and found some features of the pachychoroid disorder spectrum including pachyvessels and retinal pigment epitheliopathy along with significantly thicker SFCT in these patients.

Since Li Wenliang, a glaucoma surgeon in Wuhan, described emerging cases of severe pneumonia with unknown etiology, COVID-19 has received significant global attention, and various aspects of its epidemiology, pathophysiology, different kind of disease presentations, and potential treatment were widely investigated.[1] Worldwide, the total number of cases reached almost 75 million patients with near 1.7 million death as November 22, 2020.[16] Initial reports were mainly focused on life-threatening consequences including pneumonia, acute respiratory distress syndrome (ARDS), multiorgan failure, and septic shock.[17, 18] Specific organ involvement studies are being rapidly emerged by many investigators throughout the world. However, there is a paucity of data on ocular involvement, and most of them are limited to the external eye and conjunctival manifestations and tear film viral load.[5, 6, 10, 19]

Marinho and associates were the first investigators who reported abnormal retinal OCT findings in 12 patients with COVID-10.[12] They noticed hyperreflective lesions at the level of GCL and IPL, but not at any other retinal or choroidal layers. The authors proposed that the GCL and IPL findings might be correlated with the central nervous system manifestations that have been described in animal studies of COVID-19 and patients with neurological sequels of the disease. In a recent editorial, Vavvas and colleagues questioned the significance of OCT findings in the Marinho *et al*/report and proposed that the hyperreflective bands may be normal retinal vessels.[13] We observed some hyperreflective lesions in all retinal layers as reported by Marinho and colleagues; however, similar to Vavvas and colleagues, we believe that these hyperreflective bands are probable the retinal vessels and the prominence of these findings in COVID-19 patients could be due to the vascular involvement (i.e., micro thrombosis and vasodilation) associated with this infection. Besides, we noted some features of the pachychoroid spectrum of disorders, including increased SFCT, presence of pachyvessels, and retinal pigment epitheliopathy. In a recent report, Savastano and associates highlighted peripapillary vascular changes in patients recovered from COVID-19, which indicate the involvement of ocular vasculature in this disease.[14]

SARS-CoV-2 uses the angiotensin-converting enzyme (ACE) 2 receptor to enter the host cells and downregulates the ACE2.[20, 21] The ACE2 is a major role player in the renin-angiotensin-aldosterone system (RAAS). This system has fundamental roles in several biological and pathological processes, including fluid and electrolytes hemostasis, regulation of blood pressure, fibrosis, cell migration and proliferation, inflammation, neovascularization, and oxidative damage.[22–24] RAAS is a highly complex

system with multiple components. The first detected component was renin which was identified in 1898. [25] ACE2 was cloned in 2000 and has since been identified in multiple organs such as kidney, heart, brain, liver, intestine, and lung. [25, 24] ACE2 is a potent regulator of RAAS, which is critical in maintaining the homeostasis of RAAS and counter-balancing the ACE. [26, 27] ACE2 is also a facilitator of amino-acid transport in the kidney and intestine. [20] ACE2 expression is increased by aging, [24] smoking, [28], and several chronic diseases, [24] which partially explains higher COVID-19 frequency in these groups.

Besides the systemic RAAS, there are accumulating pieces of evidence that there is a local RAAS in the retina with components most frequently detected on retinal microvessels, glia (e.g. Müller cells), and neurons (ganglion cells). [29] Components of the RAAS have also been found in other ocular structures such as the uveal tract. [29] ACE2 was detected in aqueous humor, retina, and retinal pigmented epithelium (RPE) of humans. [30] It has also been identified in INL and Müller cells of rodent retina. [31] Notably, RAAS dysfunction has been contributed in several ocular pathologies, [32] including diabetic retinopathy, [33–35] central serous chorioretinopathy (CSC), [36, 37] age-related macular degeneration, [38] and retinopathy of prematurity. [39, 40]

With this background in the mind, there are several hypothetical explanations for the SD-OCT findings in our patients. Pulmonary dysfunction and multiorgan failure due to ischemia are fundamental findings in COVID-19. [20] It is well expected that tissues with high oxygen demand have greater damage and the retinochoroidal findings can be due to these ischemic events. Moreover, loss of ACE2 regulatory functions, result in increased RAAS pathologic process including inflammation, fibrosis, vascular damage, and leakage. It has been demonstrated that ACE2 dysfunction is accompanied by impaired migration and function of hematopoietic stem/progenitor cells, [35] retinal leukostasis, and upregulation of adhesion molecules. [29, 40, 39] As the SARS-CoV-2 RNA has been identified in the retinal layers of infected patients, [11] the source of retinal and choroidal vasculopathy can be the involvement of vascular endothelial cells by the virus. Müller cells and blood vessels are a potential target of the virus and their processes/branches cross all retinal layers which potentially explain the pan-retinal findings in COVID-19. Also, it has been shown that the virus interacts with hemoglobin molecules and alter iron homeostasis. [41] Indeed, patients with COVID-19 can have hyper-ferritinemia and it has been suggested as an indicator of more severe disease. [41, 42] Tissue damage by free iron and its deposition in retinal layers can be another explanation for our observations in macular SD-OCT. Finally, the retinal findings can be attributed to the side effects of treatments. As an instance, ritonavir is one of the antiviral treatments suggested for COVID-19. [43, 44] Retinal toxicity of ritonavir has been previously reported in a patient with human immune deficiency virus (HIV) infection under treatment with this drug. [45] The authors reported thickened and irregular RPE with loss of integrity in overlying inner-segment/outer-segment (IS/OS) junction at fovea along with ELM irregularity. [45] The drug has also been reported to cause bull's eye maculopathy. [46] In a recent report, Savastano and colleagues also reported a correlation between antiviral therapy and peripapillary vascular changes in COVID-19 patients.

We also noticed some features of pachychoroid, [47] including increased choroidal thickness, abnormal dilation of Haller's layer vessels, and irregular elevation of RPE in our patients. In a recent article by

Savastano and colleagues, the authors reported a higher choroidal thickness in patients recovered from COVID-19; however, the difference was not statistically significant.[14] The average SFCT in our patients was almost 70 μm higher than the previously reported thickness in normal subjects with the same ethnic background. Rahman and coworkers reported that a change in SFCT more than 32 μm is more than interobserver variability and could be a true change;[48] however, they used the enhanced depth imaging (EDI) protocol on a different machine (Spectralis; Heidelberg Engineering, Heidelberg, Germany) to measure SFCT.[48] Interestingly, aldosterone contributes to the maintenance of normal retinal function by regulating ion/water channels in the Müller cells.[36, 29] As mentioned earlier, CSC is a well-known example of pachychoroidal disease caused by a disturbance in RAAS function,[36] and the same pathogenic process can result in choroidal thickening in COVID-19 patients.

Our study had some limitations, including a small sample size and minimal diversity of COVID-19 severity, a short follow-up period, and a lack of a control group. In addition, our OCT machine had a limited resolution, especially for the evaluation of choroidal changes. Using swept-source OCT devices can potentially yield more useful information. Despite these, to the best of our knowledge, this is the first report on remarkable choroidal thickening and involvement in COVID-19 patients.

In conclusion, we found that in COVID-19, patients can demonstrate choroidal changes that resemble those in the pachychoroid spectrum and choroidal vascular changes may be a prominent clinical finding in this infection.

Abbreviations

ACE, Angiotensin-Converting Enzyme; ARDS, Acute Respiratory Distress Syndrome; COVID-19, Coronavirus Disease 2019; CSC, Central Serous Chorioretinopathy; ELM, External Limiting Membrane; GCL, Ganglion Cell Layer; INL, Inner Nuclear Layer; IPL, Inner Plexiform Layer; IS/OS, Inner-Segment/Outer-Segment; MERS-CoV, Middle East Respiratory Syndrome Coronavirus; ONL, Outer Nuclear Layer; OPL, Outer Plexiform Layer; PHEIC, Public Health Emergency Of International Concern; RAAS, Renin-Angiotensin-Aldosterone System; RNFL, Retinal Nerve Fiber Layer; RPE, And Retinal Pigmented Epithelium; RT-PCR, Reverse Transcription-Polymerase Chain Reaction; SARS-CoV-2, Severe Acute Respiratory Syndrome Coronavirus 2; SD-OCT, Spectral-Domain Optical Coherence Tomography; SFCT, Subfoveal Choroidal Thickness; WHO, World Health Organization

Declarations

Availability of data and material:

The datasets used and analyzed during the current study are available from the corresponding author on reasonable request.

Funding:

The authors would like to acknowledge the financial support of the Vice-Chancellor of Research, Mashhad University of Medical Sciences, Mashhad, Iran for this research project (Grant Number: 990069).

Consent for publication:

Informed consent for images and data publication and identifying clinical details was obtained from the patients.

Financial Disclosure:

None of the authors has a conflicting financial or propriety interest to disclose.

Authors' contributions:

All authors contributed to conception and study design. All authors agreed to be accountable for all aspects of the work. All authors made critical revision and final approval of the manuscript.

Acknowledgment:

We would like to thank Minoo Armand, Soosan Helmi, Mitra Mahsouli, and Masoumeh Mizban for their kind assistance with this research project. The authors also would like to thank Amir Reza Samad Zadeh and Azam Sadat Salehnezhad for providing the necessary equipment.

Ethics approval and consent to participate:

All participants were informed about the study protocols and objectives and provided their consent. The study was approved by the Reginal Medical Ethics Committee at Mashhad University of Medical Sciences (IR.MUMS.REC.1399.104).

References

1. Ahn DG, Shin HJ, Kim MH, Lee S, Kim HS, Myoung J, Kim BT, Kim SJ (2020) Current Status of Epidemiology, Diagnosis, Therapeutics, and Vaccines for Novel Coronavirus Disease 2019 (COVID-19). J Microbiol Biotechnol 30 (3):313-324. doi:10.4014/jmb.2003.03011
2. Sun J, He WT, Wang L, Lai A, Ji X, Zhai X, Li G, Suchard MA, Tian J, Zhou J, Veit M, Su S (2020) COVID-19: Epidemiology, Evolution, and Cross-Disciplinary Perspectives. Trends Mol Med 26 (5):483-495. doi:10.1016/j.molmed.2020.02.008

3. Huang C, Wang Y, Li X, Ren L, Zhao J, Hu Y, Zhang L, Fan G, Xu J, Gu X, Cheng Z, Yu T, Xia J, Wei Y, Wu W, Xie X, Yin W, Li H, Liu M, Xiao Y, Gao H, Guo L, Xie J, Wang G, Jiang R, Gao Z, Jin Q, Wang J, Cao B (2020) Clinical features of patients infected with 2019 novel coronavirus in Wuhan, China. *Lancet* 395 (10223):497-506. doi:10.1016/S0140-6736(20)30183-5
4. Seah I, Agrawal R (2020) Can the Coronavirus Disease 2019 (COVID-19) Affect the Eyes? A Review of Coronaviruses and Ocular Implications in Humans and Animals. *Ocul Immunol Inflamm* 28 (3):391-395. doi:10.1080/09273948.2020.1738501
5. Yuen KS, Chan WM, Fan DS, Chong KK, Sung JJ, Lam DS (2004) Ocular screening in severe acute respiratory syndrome. *Am J Ophthalmol* 137 (4):773-774. doi:10.1016/j.ajo.2003.09.060
6. Wu P, Duan F, Luo C, Liu Q, Qu X, Liang L, Wu K (2020) Characteristics of Ocular Findings of Patients With Coronavirus Disease 2019 (COVID-19) in Hubei Province, China. *JAMA Ophthalmol*. doi:10.1001/jamaophthalmol.2020.1291
7. Seah IYJ, Anderson DE, Kang AEZ, Wang L, Rao P, Young BE, Lye DC, Agrawal R (2020) Assessing Viral Shedding and Infectivity of Tears in Coronavirus Disease 2019 (COVID-19) Patients. *Ophthalmology*. doi:10.1016/j.ophtha.2020.03.026
8. Mungmungpantipantip R, Wiwanitkit V (2020) Ocular manifestation, eye protection, and COVID-19. *Graefes Arch Clin Exp Ophthalmol* 258 (6):1339. doi:10.1007/s00417-020-04662-3
9. Li JO, Lam DSC, Chen Y, Ting DSW (2020) Novel Coronavirus disease 2019 (COVID-19): The importance of recognising possible early ocular manifestation and using protective eyewear. *Br J Ophthalmol* 104 (3):297-298. doi:10.1136/bjophthalmol-2020-315994
10. Abrishami M, Tohidinezhad F, Daneshvar R, Omidtabrizi A, Amini M, Sedaghat A, Amini S, Reihani H, Allahyari A, Seddigh-Shamsi M, Tayyebi M, Naderi H, Bojdi A, Khodashahi R, Eslami S (2020) Ocular Manifestations of Hospitalized Patients with COVID-19 in Northeast of Iran. *Ocul Immunol Inflamm*. doi:https://doi.org/10.1080/09273948.2020.1773868
11. Casagrande M, Fitzek A, Puschel K, Aleshcheva G, Schultheiss HP, Berneking L, Spitzer MS, Schultheiss M (2020) Detection of SARS-CoV-2 in Human Retinal Biopsies of Deceased COVID-19 Patients. *Ocul Immunol Inflamm*:1-5. doi:10.1080/09273948.2020.1770301
12. Marinho PM, Marcos AAA, Romano AC, Nascimento H, Belfort R, Jr. (2020) Retinal findings in patients with COVID-19. *Lancet* 395 (10237):1610. doi:10.1016/S0140-6736(20)31014-X
13. Vavvas DG, Sarraf D, Sadda SR, Elliott D, Ehlers JP, Waheed NK, Morizane Y, Sakamoto T, Tsilimbaris M, Miller JB (2020) Concerns about the interpretation of OCT and fundus findings in COVID-19 patients in recent Lancet publication. *Eye (Lond)*. doi:10.1038/s41433-020-1084-9
14. Savastano A, Crincoli E, Savastano MC, Younis S, Gambini G, De Vico U, Cozzupoli GM, Culiersi C, Rizzo S, Group. GAC-P-ACS (2020) Peripapillary Retinal Vascular Involvement in Early Post-COVID-19 Patients. *J Clin Med* 9:2895
15. Moghimi S, Mazloumi M, Johari MK, Fard MA, Chen R, Weinreb R, Nouri-Mahdavi K (2017) Comparison of macular choroidal thickness in patients with pseudoexfoliation syndrome to normal

- control subjects with enhanced depth SD-OCT imaging. *J Curr Ophthalmol* 29 (4):258-263. doi:10.1016/j.joco.2017.06.009
16. WHO (2020): Coronavirus disease (COVID-19); Weekly Epidemiological Update and Weekly Operational Update. <https://www.who.int/publications/m/item/weekly-epidemiological-update—22-december-2020>. Accessed December 27, 2020.
 17. Murthy S, Gomersall CD, Fowler RA (2020) Care for Critically Ill Patients With COVID-19. *JAMA*. doi:10.1001/jama.2020.3633
 18. Ting DSJ, Deshmukh R, Said DG, Dua HS (2020) Care for critically ill patients with COVID-19: don't forget the eyes. *Eye (Lond)*. doi:10.1038/s41433-020-0959-0
 19. Karimi S, Arabi A, Shahraki T, Safi S (2020) Detection of severe acute respiratory syndrome Coronavirus-2 in the tears of patients with Coronavirus disease 2019. *Eye (Lond)*. doi:10.1038/s41433-020-0965-2
 20. Gheblawi M, Wang K, Viveiros A, Nguyen Q, Zhong JC, Turner AJ, Raizada MK, Grant MB, Oudit GY (2020) Angiotensin-Converting Enzyme 2: SARS-CoV-2 Receptor and Regulator of the Renin-Angiotensin System: Celebrating the 20th Anniversary of the Discovery of ACE2. *Circ Res* 126 (10):1456-1474. doi:10.1161/CIRCRESAHA.120.317015
 21. Lan J, Ge J, Yu J, Shan S, Zhou H, Fan S, Zhang Q, Shi X, Wang Q, Zhang L, Wang X (2020) Structure of the SARS-CoV-2 spike receptor-binding domain bound to the ACE2 receptor. *Nature* 581 (7807):215-220. doi:10.1038/s41586-020-2180-5
 22. Barrera-Chimal J, Girerd S, Jaisser F (2019) Mineralocorticoid receptor antagonists and kidney diseases: pathophysiological basis. *Kidney Int* 96 (2):302-319. doi:10.1016/j.kint.2019.02.030
 23. Cannavo A, Elia A, Liccardo D, Rengo G, Koch WJ (2019) Aldosterone and Myocardial Pathology. *Vitam Horm* 109:387-406. doi:10.1016/bs.vh.2018.09.005
 24. Li Y, Zhou W, Yang L, You R (2020) Physiological and pathological regulation of ACE2, the SARS-CoV-2 receptor. *Pharmacol Res* 157:104833. doi:10.1016/j.phrs.2020.104833
 25. Holappa M, Vapaatalo H, Vaajanen A (2017) Many Faces of Renin-angiotensin System - Focus on Eye. *Open Ophthalmol J* 11:122-142. doi:10.2174/1874364101711010122
 26. Kuba K, Imai Y, Ohto-Nakanishi T, Penninger JM (2010) Trilogy of ACE2: a peptidase in the renin-angiotensin system, a SARS receptor, and a partner for amino acid transporters. *Pharmacol Ther* 128 (1):119-128. doi:10.1016/j.pharmthera.2010.06.003
 27. Hamming I, Cooper ME, Haagmans BL, Hooper NM, Korstanje R, Osterhaus AD, Timens W, Turner AJ, Navis G, van Goor H (2007) The emerging role of ACE2 in physiology and disease. *J Pathol* 212 (1):1-11. doi:10.1002/path.2162
 28. Brake SJ, Barnsley K, Lu W, McAlinden KD, Eapen MS, Sohal SS (2020) Smoking Upregulates Angiotensin-Converting Enzyme-2 Receptor: A Potential Adhesion Site for Novel Coronavirus SARS-CoV-2 (Covid-19). *J Clin Med* 9 (3). doi:10.3390/jcm9030841
 29. Wilkinson-Berka JL, Agrotis A, Deliyanti D (2012) The retinal renin-angiotensin system: roles of angiotensin II and aldosterone. *Peptides* 36 (1):142-150. doi:10.1016/j.peptides.2012.04.008

30. Senanayake P, Drazba J, Shadrach K, Milsted A, Rungger-Brandle E, Nishiyama K, Miura S, Karnik S, Sears JE, Hollyfield JG (2007) Angiotensin II and its receptor subtypes in the human retina. *Invest Ophthalmol Vis Sci* 48 (7):3301-3311. doi:10.1167/iovs.06-1024
31. Tikellis C, Johnston CI, Forbes JM, Burns WC, Thomas MC, Lew RA, Yarski M, Smith AI, Cooper ME (2004) Identification of angiotensin converting enzyme 2 in the rodent retina. *Curr Eye Res* 29 (6):419-427. doi:10.1080/02713680490517944
32. Wilkinson-Berka JL, Suphachimol V, Jerome JR, Deliyanti D, Allingham MJ (2019) Angiotensin II and aldosterone in retinal vasculopathy and inflammation. *Exp Eye Res* 187:107766. doi:10.1016/j.exer.2019.107766
33. Chaturvedi N, Porta M, Klein R, Orchard T, Fuller J, Parving HH, Bilous R, Sjolie AK, Group DPS (2008) Effect of candesartan on prevention (DIRECT-Prevent 1) and progression (DIRECT-Protect 1) of retinopathy in type 1 diabetes: randomised, placebo-controlled trials. *Lancet* 372 (9647):1394-1402. doi:10.1016/S0140-6736(08)61412-9
34. Chaturvedi N, Sjolie AK, Stephenson JM, Abrahamian H, Keipes M, Castellarin A, Rogulja-Pepeonik Z, Fuller JH (1998) Effect of lisinopril on progression of retinopathy in normotensive people with type 1 diabetes. The EUCLID Study Group. EURODIAB Controlled Trial of Lisinopril in Insulin-Dependent Diabetes Mellitus. *Lancet* 351 (9095):28-31. doi:10.1016/s0140-6736(97)06209-0
35. Duan Y, Beli E, Li Calzi S, Quigley JL, Miller RC, Moldovan L, Feng D, Salazar TE, Hazra S, Al-Sabah J, Chalam KV, Phuong Trinh TL, Meroueh M, Markel TA, Murray MC, Vyas RJ, Boulton ME, Parsons-Wingerter P, Oudit GY, Obukhov AG, Grant MB (2018) Loss of Angiotensin-Converting Enzyme 2 Exacerbates Diabetic Retinopathy by Promoting Bone Marrow Dysfunction. *Stem Cells* 36 (9):1430-1440. doi:10.1002/stem.2848
36. Zhao M, Celerier I, Bousquet E, Jeanny JC, Jonet L, Savoldelli M, Offret O, Curan A, Farman N, Jaisser F, Behar-Cohen F (2012) Mineralocorticoid receptor is involved in rat and human ocular chorioretinopathy. *J Clin Invest* 122 (7):2672-2679. doi:10.1172/JCI61427
37. Daruich A, Matet A, Moulin A, Kowalczyk L, Nicolas M, Sellam A, Rothschild PR, Omri S, Gelize E, Jonet L, Delaunay K, De Kozak Y, Berdugo M, Zhao M, Crisanti P, Behar-Cohen F (2018) Mechanisms of macular edema: Beyond the surface. *Prog Retin Eye Res* 63:20-68. doi:10.1016/j.preteyeres.2017.10.006
38. Zhao M, Mantel I, Gelize E, Li X, Xie X, Arboleda A, Seminel M, Levy-Boukris R, Dernigoghossian M, Prunotto A, Andrieu-Soler C, Rivolta C, Canonica J, Naud MC, Lechner S, Farman N, Bravo-Osuna I, Herrero-Vanrell R, Jaisser F, Behar-Cohen F (2019) Mineralocorticoid receptor antagonism limits experimental choroidal neovascularization and structural changes associated with neovascular age-related macular degeneration. *Nat Commun* 10 (1):369. doi:10.1038/s41467-018-08125-6
39. Chen P, Scicli GM, Guo M, Fenstermacher JD, Dahl D, Edwards PA, Scicli AG (2006) Role of angiotensin II in retinal leukostasis in the diabetic rat. *Exp Eye Res* 83 (5):1041-1051. doi:10.1016/j.exer.2006.05.009

40. Wilkinson-Berka JL, Tan G, Jaworski K, Harbig J, Miller AG (2009) Identification of a retinal aldosterone system and the protective effects of mineralocorticoid receptor antagonism on retinal vascular pathology. *Circ Res* 104 (1):124-133. doi:10.1161/CIRCRESAHA.108.176008
41. Edeas M, Saleh J, Peyssonnaud C (2020) Iron: Innocent bystander or vicious culprit in COVID-19 pathogenesis? *Int J Infect Dis*. doi:10.1016/j.ijid.2020.05.110
42. Cavezzi A, Troiani E, Corrao S (2020) COVID-19: hemoglobin, iron, and hypoxia beyond inflammation. A narrative review. *Clin Pract* 10 (2):1271. doi:10.4081/cp.2020.1271
43. Cao B, Wang Y, Wen D, Liu W, Wang J, Fan G, Ruan L, Song B, Cai Y, Wei M, Li X, Xia J, Chen N, Xiang J, Yu T, Bai T, Xie X, Zhang L, Li C, Yuan Y, Chen H, Li H, Huang H, Tu S, Gong F, Liu Y, Wei Y, Dong C, Zhou F, Gu X, Xu J, Liu Z, Zhang Y, Li H, Shang L, Wang K, Li K, Zhou X, Dong X, Qu Z, Lu S, Hu X, Ruan S, Luo S, Wu J, Peng L, Cheng F, Pan L, Zou J, Jia C, Wang J, Liu X, Wang S, Wu X, Ge Q, He J, Zhan H, Qiu F, Guo L, Huang C, Jaki T, Hayden FG, Horby PW, Zhang D, Wang C (2020) A Trial of Lopinavir-Ritonavir in Adults Hospitalized with Severe Covid-19. *N Engl J Med* 382 (19):1787-1799. doi:10.1056/NEJMoa2001282
44. Alhazzani W, Moller MH, Arabi YM, Loeb M, Gong MN, Fan E, Oczkowski S, Levy MM, Derde L, Dziera A, Du B, Aboodi M, Wunsch H, Cecconi M, Koh Y, Chertow DS, Maitland K, Alshamsi F, Belley-Cote E, Greco M, Laundry M, Morgan JS, Kesecioglu J, McGeer A, Mermel L, Mammen MJ, Alexander PE, Arrington A, Centofanti JE, Citerio G, Baw B, Memish ZA, Hammond N, Hayden FG, Evans L, Rhodes A (2020) Surviving Sepsis Campaign: guidelines on the management of critically ill adults with Coronavirus Disease 2019 (COVID-19). *Intensive Care Med* 46 (5):854-887. doi:10.1007/s00134-020-06022-5
45. Tu Y, Poblete RJ, Freilich BD, Zarbin MA, Bhagat N (2016) Retinal toxicity with Ritonavir. *Int J Ophthalmol* 9 (4):640-642. doi:10.18240/ijo.2016.04.29
46. Pinto R, Vila-Franca M, Oliveira Afonso C, Ornelas C, Santos L (2013) Ritonavir and bull's eye maculopathy: case report. *GMS Ophthalmol Cases* 3:Doc01. doi:10.3205/oc000011
47. Cheung CMG, Lee WK, Koizumi H, Dansingani K, Lai TYY, Freund KB (2019) Pachychoroid disease. *Eye (Lond)* 33 (1):14-33. doi:10.1038/s41433-018-0158-4
48. Rahman W, Chen FK, Yeoh J, Patel P, Tufail A, Da Cruz L (2011) Repeatability of manual subfoveal choroidal thickness measurements in healthy subjects using the technique of enhanced depth imaging optical coherence tomography. *Invest Ophthalmol Vis Sci* 52 (5):2267-2271. doi:10.1167/iovs.10-6024

Figures

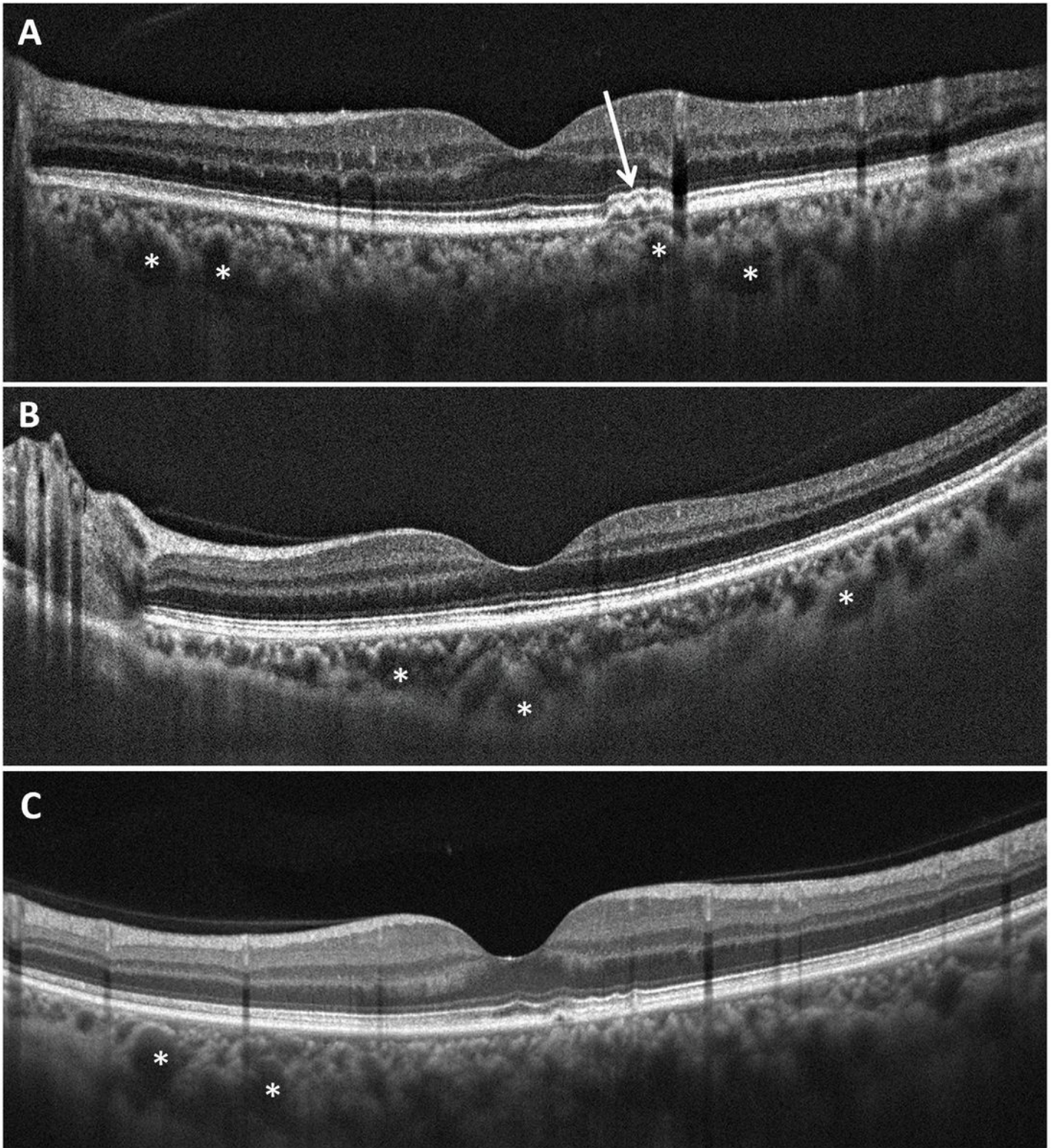


Figure 1

Spectral-domain optical coherence tomography finding of macular area in three representative patients, recovered from the coronavirus disease 2019. Note the dilated choroidal vessels (asterisks) and overlying retinal pigment epitheliopathy (white arrows).