

Staged surgical strategy of symptomatic lumbar adjacent-segment degeneration: full-endoscopic decompression versus extended posterior interbody fusion

Tong Li

Peking University Third Hospital

Bin Zhu

Peking University Third Hospital



Xiaoguang Liu (✉ lxg_pku@outlook.com)

Research article

Keywords: Adjacent-segment degeneration (ASD), Full-endoscopic lumbar decompression (FELD), Posterior lumbar interbody fusion (PLIF), Revision strategy Segmental instability

Posted Date: February 20th, 2020

DOI: <https://doi.org/10.21203/rs.2.21687/v2>

License:   This work is licensed under a Creative Commons Attribution 4.0 International License. [Read Full License](#)

Abstract

Background Symptomatic adjacent-segment degeneration (ASD) is a common complication after lumbar fusion surgery. We want to evaluate the clinical and imaging outcome of full-endoscopic lumbar decompression (FELD) in comparison with extended posterior lumbar interbody fusion (PLIF) for ASD after lumbar fusion surgeries and develop a staged revision strategy. **Methods** This retrospective study enrolled 65 patients with ASD who treated with FELD (n=31) or extended PLIF (n=34) between January 2014 and January 2018. Clinical outcome evaluations were performed preoperatively, at 3, 12, 24 months postoperatively, including Oswestry Disability Index (ODI) score and Japanese Orthopaedic Association (JOA) scores for function assessment, visual analog scale (VAS) scores for low-back pain and leg pain. Imaging outcome evaluations were performed preoperatively, immediately after surgery and at the last follow up, including disc height (DH) and lumbar lordosis (LL). **Results** The ratio of patients with adjacent segmental instability in the PLIF group was significantly higher than that in the FELD group ($p < 0.05$). There was no significant difference in other baseline data for FELD and PLIF groups ($p > 0.05$). Mean operative time, blood loss and length of hospital stay were significantly decreased for the FELD group ($p < 0.001$). For patients with stable adjacent segments, there was no significant difference in preoperative and postoperative low-back pain, leg pain and function between 2 groups ($p > 0.05$). The patients in PLIF group had restored DH after surgery, which was significantly higher than FELD group ($p < 0.05$). For patients with unstable adjacent segments, the low-back and leg pain of PLIF group were significantly relieved than that in FELD group within 24 and 3 months after surgery ($p < 0.05$). The function of PLIF group was significantly improved within 12 months after surgery ($p < 0.05$). The DH was only significantly restored within 3 months after surgery ($p < 0.05$). Recurrence was found in 2 (6.5%, $p > 0.05$) patients in FELD group, while no patient in PLIF group had recurrence. **Conclusions** FELD could achieve satisfactory safety and efficacy for the treatment of stable ASD, which was not worse than PLIF. With less trauma and faster recovery, FELD may be an alternative surgical treatment for stable ASD.

Introduction

Symptomatic adjacent-segment degeneration (ASD) is a common complication after lumbar fusion surgery, with a high rate ranging from 5.2% to 18.5%[1]. It is defined as the recurrence of low-back pain and leg pain associated with the degeneration at the adjacent segments after a symptom-free period. Spondylolisthesis, instability, herniated nucleus pulposus, osteophytic spurs, and spinal stenosis (SS) have been considered to be the main pathological changes of ASD[2,3], and lumbar disc herniation (LDH) was the most common pathological change among them. Revision surgery has become a regular choice after a failed conservative treatment.

The extended posterior lumbar interbody fusion (PLIF) was performed as a general salvage surgery in lumbar ASD after fusion surgery. However, tissue scars resulting from previous surgery and ASD caused by the damage of vertebral motion segments was considered to be associated with further complications[4]. Percutaneous endoscopic lumbar discectomy (PELD) was a minimally invasive surgery used for the treatment of LDH[5,6]. With further development of PELD, Kim et al. applied full-endoscopic lumbar decompression (FELD) for patients with SS and achieved satisfactory clinical outcomes[7,8]. It directly enlarged the spinal canal, decompressed the spinal cord under local anesthesia and avoided repeated damage to the posterior and paraspinal structures, which made FELD a potential alternative to open lumbar surgery. Minimally invasive technique is effective for preserving facet joint, however, indications must be carefully considered when scoliosis or instability are present[9].

The surgical management of symptomatic lumbar ASD remains controversial, and researches comparing outcomes of revision surgery by means of FELD with extended PLIF are rare. Our study has performed FELD as revision surgery for

symptomatic ASD, and the results are satisfactory. Therefore, we attempted to evaluate the clinical and radiologic outcomes of FELD versus extended PLIF for symptomatic ASD resulting from posterior fusion surgery in this study.

Materials And Methods

Patient population

This is a retrospective study performed after achieving the approval of the Ethic Committee of The Peking university Third Hospital, and patient outcomes were collected independently from informed consent. Case assignment was from the result of the whole section discussion before surgery and eventually determined by experienced surgeons.

From January 2014 to December 2017, 65 consecutive patients underwent FELD (n=31) and extended PLIF (n=35) for symptomatic ASD were enrolled. Radiographic examination, computed tomography, and magnetic resonance imaging were applied for preoperative diagnosis and postoperative evaluation.

Inclusion and exclusion criteria

The eligibility criteria were

1) previous posterior fusion surgery for lumbar degenerative disease; 2) suffered from low-back pain or radicular pain in the lower extremities; 3) failed conservative treatment for at least 3 months; 4) ASD including disc herniation and stenosis confirmed by radiologic images; 5) underwent FELD or extended PLIF revision surgery; 6) with at least 24 months of follow-up.

The exclusion criteria were: revision for infection, lumbar fracture, breakage of instrumentation, pseudarthrosis and other causes.

Surgical technique

FELD

There were 2 approaches for endoscopic revision surgeries of lumbar ASD. Transforaminal (TF) approach was applied in patients with ASD at L4-L5 or upper level and interlaminar (IL) approach was applied in L5-S1 level. Special instruments were designed and constructed for foraminotomy and laminectomy, including outer working cannula, trepan, and inner working cannula (Endosurgi, China) (Fig 1). All procedures were carried out under local anesthesia with mixed anesthetic (2% lidocaine 15ml, 1% ropivacaine 10ml and saline 20ml).

The key points of TF approach included: 1) Remove the hyperplastic facet joint with trepan; 2) Remove the osteophytes, hyperplastic ligamentum flavum and disc with "TESSYS-ISEE" techniques (Fig 2)[10].

The key points of IL approach included: 1) sufficient decompression of bony structure to expose the cranial and caudal insertion points of interlaminar ligamentum flavum; 2) en-bloc resection of the unilateral hyperplastic ligamentum flavum to expose the axillary and under-shoulder space of S1 nerve (Fig 3).

Extended PLIF

Extended PLIF was performed with the patient in the prone position under general anesthesia. The previous fused level and adjacent degenerated level were exposed from the standard middle incision. A standard decompression was carried out in the adjacent segments after laminectomy. The extension of fixation and interbody fusion were performed then.

Outcome measurements

The general characteristics of the patients were recorded, including operative time, blood loss, hospital stay. The clinical outcome measures were evaluated preoperatively, 3, 12, and 24 months postoperatively, including visual analog scale (VAS) for low-back and leg pain, Oswestry Disability Index (ODI) and Japanese Orthopaedic Association (JOA) scores for functional disability. The radiographic outcome was measured preoperatively, immediately after surgery, and at the last follow-up, including the disc height (DH), lumbar lordosis (LL), and adjacent-segmental stability. DH was average of anterior and posterior heights of the disc and measured on the lateral radiographs. LL was measured between the upper endplate of the L1 and S1 vertebra. Radiographically instability was diagnosed, if spondylolisthesis >4mm (anterior or posterior translation) was presented at functional imaging, segmental kyphosis >10°, hypermobility in rotation >15°, complete herniated disc, degradation in Weiner Classification of two or more grades, complete collapse of intervertebral space, lateral translation >3mm and disc wedging >5° occurred at follow-up imaging at the adjacent level above or below the instrumentation[11]. Measurements were performed by a single observer in Picture Archiving and Communication System (PACS) (GE, USA).

Statistical analysis

The data was analyzed using SPSS (version 26.0, Chicago, Illinois, USA). Statistical analysis was performed using the t test for continuous variables or the chi-square test for dichotomous variables. These 2 tests were used to compare the demographic parameters and perioperative and postoperative parameters between 2 groups. Statistical significance was defined as $p < 0.05$.

Results

Baseline characteristics

Table 1 demonstrates the baseline characteristics between the FELD group and PLIF group. There were no significant differences in terms of follow-up period, age, duration of symptoms, interval time, sex, BMI, location of ASD, level of ASD, and previous fusion levels ($p > 0.05$). Significant difference was found in adjacent-segmental stability (20/11, stable/unstable, in FELD group versus 12/22, stable/unstable, in PLIF group) between the 2 groups ($p = 0.019$).

Perioperative characteristics

The perioperative characteristics of patients are summarized in Table 2. Significant differences were found in operative time (63.4 ± 38.9 min in FELD group versus 142.4 ± 39.6 min in PLIF group) between 2 groups ($p < 0.001$). Intraoperative blood loss was significantly less for FELD group (9.0 ± 8.9 ml) than in the PLIF group (241.5 ± 100.4 ml, $p < 0.001$). Patients in the FELD group had shorter time to stay at hospital (4.6 ± 2.4 days in FELD versus 8.9 ± 4.1 days in PLIF group, $p < 0.001$).

Clinical and radiologic outcomes

For patients with both stable and unstable adjacent segments, no significant difference was found in terms of preoperative low-back and leg pain VAS, ODI score, and JOA scores between 2 groups ($p > 0.05$). For patients with stable adjacent segments, no significant difference was found in terms of postoperative low-back and leg pain VAS, ODI score, and JOA scores between 2 groups ($p > 0.05$, Table 3). However, for patients with unstable segments, the low-back and leg pain VAS were significantly higher for FELD group than in the PLIF group within 24 months and 3 months

($p < 0.05$, Table 4). Meanwhile, the ODI score was significantly less and the JOA scores was significantly higher for FELD group than in the PLIF group within 12 months ($p < 0.05$, Table 4).

For patients with both stable and unstable adjacent segments, no significant difference was found in terms of preoperative DH and LL between 2 groups ($p > 0.05$). For patients with stable adjacent segments, the DH was significantly restored for PLIF group than in the FELD group immediately after surgery and at the last follow-up ($p < 0.05$, Table 5). However, for patients with unstable adjacent segments, the DH was only significantly restored for PLIF group than in the FELD group immediately after surgery ($p < 0.05$, Table 6). For patients with both stable and unstable adjacent segments, no significant difference was found in postoperative LL between 2 groups ($p > 0.05$).

Complication and recurrence

No complication was occurred in 2 groups until the last follow-up. Recurrence was found in 2 (6.5%, $p > 0.05$) patients in FELD group and further treatment was required, while no patient in PLIF group had recurrence.

Discussion

Typically, revision for ASD after lumbar fusion was performed via a posterior approach with or without extension of the instrumentation and fusion[12]. The extended PLIF can achieve a satisfactory decompression of the spinal cord that results from ASD. However, traditional open spine surgery may lead to laminectomies, muscle damage, ligamentum flavum excision and nerve retraction, which are the main causes of spinal instability and epidural space scarring[13]. FELD has significant advantages over conventional open lumbar surgery in the above aspects, including performing the surgery under local anesthesia, preserving normal posterior and paraspinal structures, less intraoperative blood loss, less postoperative pain, and short hospital stay. In this study, FELD also showed a shorter mean operative time, less intraoperative blood loss, and less hospital stay than extended PLIF. Furthermore, endoscopic surgery doesn't go through the posterior scar tissue, which may avoid the access-related complications for the revision surgery[14].

In previous study, the use of PELD for patients with recurrence of disc herniation had been discussed[15], while the use of PELD for lumbar ASD was rarely mentioned. A prospective cohort study performed by Ba Z et al. compared percutaneous endoscopic transforaminal procedure (PE-TF) and PLIF in treating disc herniation at adjacent segments after lumbar fusion surgeries, the clinical outcomes of 2 approaches were similar, but PE-TF showed advantage in traumatization, cosmetology, hospitalization time, and blood loss[16]. In tradition, disc protrusions without response to conservative treatment is identified as the limited indication for PELD. Major neurological deficit, segmental instability, spondylolisthesis, extruded disc prolapse, narrow spinal canal, and lateral recess are all considered as relative contraindications[17]. It was reported foraminoplastic superior vertebral notch approach with reamers in PELD may offer safe and efficacious results in the relatively limited indications[18], including high grade migration, high canal compromise, and combined foraminal stenosis, which gave a technical support for the treatment of ASD after lumbar fusion. Furthermore, Xiong et al. showed a safe and minimally invasive way to treat lumbar stenosis combined with disc herniation by using TESSYS-ISEEs technique[10]. The TESSYS-ISEEs technique, used in TF approach of FELD, enlarged the narrow intervertebral foramen and spinal canal, which achieved the decompression of the nerve roots and spinal cord for patients with symptomatic lumbar ASD. Meanwhile, the IL approach showed a satisfactory outcome as TF approach in decompression of lumbar lateral recess stenosis[19].

Spinal instability is a frequently cited justification for fusion surgery, the true clinical relevance of spinal instability is poorly understood[20]. Treatment with minimally invasive technique in patients with segmental instability still remains controversial[9]. When we choose the surgical method, the clinical manifestations and radiographic outcomes of patients need to be considered simultaneously. If the patient's main symptoms are radiating pain in the lower

extremities due to nerve compression or intermittent claudication, the main purpose of surgery is decompression. If the patient's primary symptom is mechanical low-back pain due to the lumbar instability, the primary purpose of surgery is fusion. Therefore, in this study, we comprehensively analyzed the clinical manifestations and radiographic outcomes to determine whether the patients performed FELD to achieve decompression or extended PLIF to achieve fusion. The patients were divided into 2 groups based on the radiographic stability of responsible segment next to the fusion segments. For the patients with stable ASD, FELD yielded clinical outcomes not worse than extended PLIF even if the extended PLIF could achieve a more effective restoration in DH. For the patients with unstable ASD, extended PLIF could get better results in relieving low-back pain and leg pain, and improving the function of ASD. Meanwhile, extended PLIF could only achieve a more effective restoration of DH within 3 months. Therefore, we believe that the efficacy of FELD in treating stable lumbar ASD is reliable and a better restoration in DH may be found in patients with stable adjacent segments under extended PLIF.

Furthermore, the recurrence after surgery should also be noted. In previous studies, the recurrence rate after FELD was reported to be 0%-6.9%[21-23]. In contrast, recurrence rate after extended PLIF was relatively low[16,24]. In this study, 2(6.5%) patients underwent FELD had recurrence, while there was no patient underwent extended PLIF had recurrence. Although recurrence rate may be higher in FELD group, no significant difference was found. Meanwhile, no complication was occurred in 2 groups until the last follow-up. Therefore, although the recurrence rate is relatively higher in patients with treatment of FELD, the safety of FELD in treating stable lumbar ASD is still reliable.

Although our study showed some reliable results, there were a few limitations. First, since it was a single-centered retrospective study and our sample size was relatively small, the generalizability of our findings could be limited. A randomized control trail may be more convincing. In addition, the follow-up period is relatively short and a long-term follow-up of a larger sample will be required in the future.

Conclusions

FELD could achieve satisfactory safety and efficacy for the treatment of stable lumbar symptomatic ASD, while extended PLIF had an advantage over FELD for patients with unstable lumbar symptomatic ASD. For patients with stable ASD, low-back pain and leg pain, lumbar function are improved without a significant difference between FELD and PLIF. Meanwhile, extended PLIF could achieve a more effective restoration of DH during the mid-term follow-up. For patients with unstable ASD, extended PLIF has better effect on relieving low-back pain and leg pain during the mid-term follow-up. Extended PLIF could also achieve better effect on improving the function of ASD in the first year after surgery. Meanwhile, extended PLIF could only achieve a more effective restoration of DH within 3 months. FELD may serve as an alternative surgical treatment for stable symptomatic lumbar ASD with less trauma and faster recovery, while extended PLIF still dominates the unstable symptomatic lumbar ASD.

List Of Abbreviations

Adjacent-segment degeneration (ASD);

Full-endoscopic lumbar decompression (FELD);

Posterior lumbar interbody fusion (PLIF);

Oswestry Disability Index (ODI);

Japanese Orthopaedic Association (JOA);

Visual analog scale (VAS);

Disc height (DH);

Lumbar lordosis (LL);

Percutaneous endoscopic lumbar discectomy (PELD);

Spinal steosis (SS);

Lumbar disc herniation (LDH);

Transforaminal (TF);

Interlaminar (IL);

Percutaneous endoscopic transforaminal procedure (PE-TF);

Declarations

Ethics approval and consent to participate

This study was approved by the Ethic Committee of The Peking university Third Hospital, and patient outcomes were collected independently from informed consent.

Consent for publication

Not applicable.

Availability of data and materials

We state that data will not be shared because all raw data were used to prepare the figures included in the article.

Competing interests

The authors declare that they have no competing interests.

Funding

This research did not receive any specific grant from any funding agencies in the public, commercial, or not-for-profit sectors.

Authors' contributions

TL, BZ, and XGL designed the study. TL collected the data, performed the statistical analysis and interpreted the results. ZS and BZ drafted the manuscript. The final manuscript was approved by all authors.

Acknowledgements

The authors wish to thank the medical staff of the Surgical Department at Peking University Third Hospital where all of the surgeries were performed.

References

1. Park P, Garton HJ, Gala VC, Hoff JT, McGillicuddy JE. Adjacent segment disease after lumbar or lumbosacral fusion: review of the literature. *Spine (Phila Pa 1976)*. 2004;29 (17):1938-1944; doi:10.1097/01.brs.0000137069.88904.03.
2. Schlegel JD, Smith JA, Schleusener RL. Lumbar motion segment pathology adjacent to thoracolumbar, lumbar, and lumbosacral fusions. *Spine (Phila Pa 1976)*. 1996;21 (8):970-981; doi:10.1097/00007632-199604150-00013.
3. Kumar MN, Jacquot F, Hall H. Long-term follow-up of functional outcomes and radiographic changes at adjacent levels following lumbar spine fusion for degenerative disc disease. *Eur Spine J*. 2001;10 (4):309-313; doi: 10.1007/s005860000207.
4. Nakashima H, Kawakami N, Tsuji T, Ohara T, Suzuki Y, Saito T, Nohara A, Tauchi R, Ohta K, Hamajima N, Imagama S. Adjacent Segment Disease After Posterior Lumbar Interbody Fusion: Based on Cases With a Minimum of 10 Years of Follow-up. *Spine (Phila Pa 1976)*. 2015;40 (14):E831-841; doi:10.1097/BRS.0000000000000917.
5. Yeung AT, Tsou PM. Posterolateral endoscopic excision for lumbar disc herniation: Surgical technique, outcome, and complications in 307 consecutive cases. *Spine (Phila Pa 1976)*. 2002;27 (7):722-731; doi:10.1097/00007632-200204010-00009.
6. Ahn Y, Lee SH, Park WM, Lee HY, Shin SW, Kang HY. Percutaneous endoscopic lumbar discectomy for recurrent disc herniation: surgical technique, outcome, and prognostic factors of 43 consecutive cases. *Spine (Phila Pa 1976)*. 2004;29 (16):E326-332; doi:10.1097/01.brs.0000134591.32462.98.
7. Kim HS, Paudel B, Jang JS, Oh SH, Lee S, Park JE, Jang IT. Percutaneous Full Endoscopic Bilateral Lumbar Decompression of Spinal Stenosis Through Uniportal-Contralateral Approach: Techniques and Preliminary Results. *World Neurosurg*. 2017;103:201-209; doi:10.1016/j.wneu.2017.03.130.
8. Kim HS, Patel R, Paudel B, Jang JS, Jang IT, Oh SH, Park JE, Lee S. Early Outcomes of Endoscopic Contralateral Foraminal and Lateral Recess Decompression via an Interlaminar Approach in Patients with Unilateral Radiculopathy from Unilateral Foraminal Stenosis. *World Neurosurg*. 2017;108:763-773; doi:10.1016/j.wneu.2017.09.018.
9. Yokosuka J, Oshima Y, Kaneko T, Takano Y, Inanami H, Koga H. Advantages and disadvantages of posterolateral approach for percutaneous endoscopic lumbar discectomy. *J Spine Surg*. 2016;2 (3):158-166; doi:10.21037/jss.2016.09.03.
10. Xiong C, Li T, Kang H, Hu H, Han J, Xu F. Early outcomes of 270-degree spinal canal decompression by using TESSYS-ISEE technique in patients with lumbar spinal stenosis combined with disk herniation. *Eur Spine J*. 2019;28 (1):78-86; doi:10.1007/s00586-018-5655-4.
11. Aota Y, Kumano K, Hirabayashi S. Postfusion Instability at the Adjacent Segments After Rigid Pedicle Screw Fixation for Degenerative Lumbar Spinal Disorders. *J Spinal Disord*. 1995;8 (6):464-473; doi:10.1097/00024720-199512000-00006.
12. Whitecloud TS, 3rd, Davis JM, Olive PM. Operative treatment of the degenerated segment adjacent to a lumbar fusion. *Spine (Phila Pa 1976)*. 1994;19 (5):531-536; doi:10.1097/00007632-199403000-00007.
13. Yuan C, Wang J, Zhou Y, Pan Y. Endoscopic lumbar discectomy and minimally invasive lumbar interbody fusion: a contrastive review. *Wideochir Inne Tech Maloinwazyjne*. 2018;13 (4):429-434; doi:10.5114/wiitm.2018.77744.
14. Hoogland T, van den Brekel-Dijkstra K, Schubert M, Miklitz B. Endoscopic transforaminal discectomy for recurrent lumbar disc herniation: a prospective, cohort evaluation of 262 consecutive cases. *Spine (Phila Pa 1976)*. 2008;33 (9):973-978; doi:10.1097/BRS.0b013e31816c8ade.

15. Li X, Hu Z, Cui J, Han Y, Pan J, Yang M, Tan J, Sun G, Li L. Percutaneous endoscopic lumbar discectomy for recurrent lumbar disc herniation. *Int J Surg.* 2016;27:8-16; doi:10.1016/j.ijisu.2016.01.034.
16. Ba Z, Pan F, Liu Z, Yu B, Fuentes L, Wu D, Zhu J. Percutaneous endoscopical transforaminal approach versus PLF to treat the single-level adjacent segment disease after PLF/PLIF: 1-2 years follow-up. *Int J Surg.* 2017;42:22-26; doi:10.1016/j.ijisu.2017.04.021.
17. Mayer HM, Brock M, Berlien HP, Weber B. Percutaneous endoscopic laser discectomy (PELD). A new surgical technique for non-sequestered lumbar discs. *Acta Neurochir Suppl (Wien).* 1992;54:53-58; doi:10.1007/978-3-7091-6687-1_7.
18. Lee CW, Yoon KJ, Ha SS, Kang JK. Foraminoplasty Superior Vertebral Notch Approach with Reamers in Percutaneous Endoscopic Lumbar Discectomy : Technical Note and Clinical Outcome in Limited Indications of Percutaneous Endoscopic Lumbar Discectomy. *J Korean Neurosurg Soc.* 2016;59 (2):172-181; doi:10.3340/jkns.2016.59.2.172.
19. Li Y, Wang B, Wang S, Li P, Jiang B. Full-Endoscopic Decompression for Lumbar Lateral Recess Stenosis via an Interlaminar Approach versus a Transforaminal Approach. *World Neurosurg.* 2019;128:e632-e638; doi:10.1016/j.wneu.2019.04.221.
20. Hipp JA, Guyer RD, Zigler JE, Ohnmeiss DD, Wharton ND. Development of a novel radiographic measure of lumbar instability and validation using the facet fluid sign. *Int J Spine Surg.* 2015;9:37. doi:10.14444/2037.
21. Ruetten S, Komp M, Merk H, Godolias G. Full-endoscopic interlaminar and transforaminal lumbar discectomy versus conventional microsurgical technique: a prospective, randomized, controlled study. *Spine (Phila Pa 1976).* 2008;33 (9):931-939; doi:10.1097/BRS.0b013e31816c8af7.
22. Hoogland T, Schubert M, Miklitz B, Ramirez A. Transforaminal Posterolateral Endoscopic Discectomy With or Without the Combination of a Low-Dose Chymopapain: A Prospective Randomized Study in 280 Consecutive Cases. *Spine (Phila Pa 1976).* 2006;31 (24):E890-E897; doi: 10.1097/01.brs.0000245955.22358.3a.
23. Choi KC, Kim JS, Kang BU, Lee CD, Lee SH. Changes in back pain after percutaneous endoscopic lumbar discectomy and annuloplasty for lumbar disc herniation: a prospective study. *Pain Med.* 2011;12 (11):1615-1621; doi:10.1111/j.1526-4637.2011.01250.x.
24. Tu Z, Li L, Wang B, Li Y, Lv G, Dai Y. Stand-Alone Anterolateral Interbody Fusion Versus Extended Posterior Fusion for Symptomatic Adjacent-Segment Degeneration: A Retrospective Study of 2 Years' Follow-up. *World Neurosurg.* 2018;115:e748-e755; doi:10.1016/j.wneu.2018.04.165.

Tables

Table 1. Baseline data of patients in two groups

	FELD	PLIF	p value
Patients	31	34	
Mean follow-up period, months	32.1±6.0	35.4±8.7	0.080
Average age, years	61.0±14.3	62.9±10.7	0.548
Duration of symptoms, months	9.2±14.0	15.4±13.9	0.080
Interval time, months	80.7±51.4	80.3±48.2	0.977
Sex, male/female	18/12	19/15	0.859
BMI	25.6±3.8	27.1±3.4	0.085
Location of ASD			0.083
Cranial	14	24	
Caudal	11	8	
Cranial and Caudal	6	2	
Level of ASD			
L1-L2	2	3	0.720
L2-L3	9	15	0.208
L3-L4	17	13	0.180
L4-L5	9	5	0.161
L5-S1	14	8	0.066
Previous fusion, level			0.084
1	19	12	
2	12	18	
3	0	3	
4	0	1	
Adjacent segment stability, stable/unstable	20/11	12/22	0.019

FELD, full-endoscopic lumbar decompression

PLIF, posterior lumbar interbody fusion

ASD, adjacent-segment degeneration

Table 2. The operation data of patients in two groups

	FELD	PLIF	p value
Mean operative time, mins	63.4±38.9	142.4±39.6	<0.001
Mean blood loss, ml	9.0±8.9	241.5±100.4	<0.001
Mean length of hospital stay, days	4.6±2.4	8.9±4.1	<0.001

FELD, full-endoscopic lumbar decompression

PLIF, posterior lumbar interbody fusion

Table 3. Clinical data of patients with stable adjacent segments in two groups

	Preoperative			Postoperative								
				3 months			12 months			24 months		
	FELD	PLIF	p value	FELD	PLIF	p value	FELD	PLIF	p value	FELD	PLIF	p value
ODI	23.2±7.7	24.5±9.4	0.662	13.9±5.7	15.3±9.1	0.585	13.4±5.2	16.1±7.7	0.250	13.6±5.5	16.1±7.2	0.301
JOA	15.9±4.6	13.0±7.4	0.181	21.6±3.8	18.8±7.7	0.269	21.5±3.4	18.8±7.0	0.158	22.0±3.6	19.3±7.7	0.195
VAS back pain	4.7±1.6	4.8±2.0	0.877	2.6±1.3	2.5±1.5	0.845	2.4±1.0	2.8±1.1	0.317	2.5±1.1	2.8±1.3	0.450
VAS leg pain	6.2±1.5	4.6±2.5	0.066	3.1±1.4	2.8±1.7	0.064	3.1±1.2	2.8±1.8	0.652	3.0±1.2	2.9±1.9	0.895

FELD, full-endoscopic lumbar decompression PLIF, posterior lumbar interbody fusion

ODI, Oswestry Disability Index JOA, Japanese Orthopaedic Association VAS, visual analog scale

Table 4. Clinical data of patients with unstable adjacent segments in two groups

	Preoperative			Postoperative								
	FELD	PLIF	p value	3 months			12 months			24 months		
	FELD	PLIF	p value	FELD	PLIF	p value	FELD	PLIF	p value	FELD	PLIF	p value
ODI	24.2±4.4	25.6±7.7	0.593	18.6±3.4	13.8±5.8	0.019	17.7±3.7	14.0±5.4	0.044	17.4±4.0	14.1±5.5	0.087
JOA	15.9±2.4	14.4±4.6	0.227	19.1±2.9	22.0±3.2	0.016	19.2±3.1	21.6±2.6	0.024	19.4±2.8	21.6±3.2	0.052
VAS back pain	5.0±1.2	5.3±1.9	0.668	3.6±1.0	2.4±1.2	0.008	3.4±1.1	2.4±1.3	0.042	3.5±1.6	2.3±1.4	0.042
VAS leg pain	5.7±1.3	5.5±1.7	0.644	3.9±1.0	2.6±1.2	0.005	3.6±0.5	3.0±1.1	0.100	3.5±0.8	3.0±1.4	0.213

FELD, full-endoscopic lumbar decompression PLIF, posterior lumbar interbody fusion

ODI, Oswestry Disability Index JOA, Japanese Orthopaedic Association VAS, visual analog scale

Table 5. Imaging parameters of patients with stable adjacent segments in two groups

	Preoperative			Immediately after surgery			Last follow-up		
	FELD	PLIF	p value	FELD	PLIF	p value	FELD	PLIF	p value
Disc height	9.2±2.7	10.8±1.7	0.071	9.1±2.7	13.3±2.1	<0.001	9.2±2.3	11.6±2.0	0.006
Lumbar lordosis	28.2±9.9	28.0±14.2	0.967	27.8±8.8	30.0±11.8	0.559	26.7±10.7	28.8±10.8	0.585

FELD, full-endoscopic lumbar decompression PLIF, posterior lumbar interbody fusion

Table 6. Imaging parameters of patients with unstable adjacent segments in two groups

	Preoperative			Immediately after surgery			Last follow-up		
	FELD	PLIF	p value	FELD	PLIF	p value	FELD	PLIF	p value
Disc height	8.3±2.5	7.2±2.3	0.176	8.5±2.5	10.3±2.1	0.039	8.9±2.4	9.3±1.7	0.645
Lumbar lordosis	22.8±11.9	22.6±13.0	0.591	23.3±12.8	26.5±11.9	0.489	22.1±12.0	27.2±10.5	0.225

FELD, full-endoscopic lumbar decompression PLIF, posterior lumbar interbody fusion

Figures

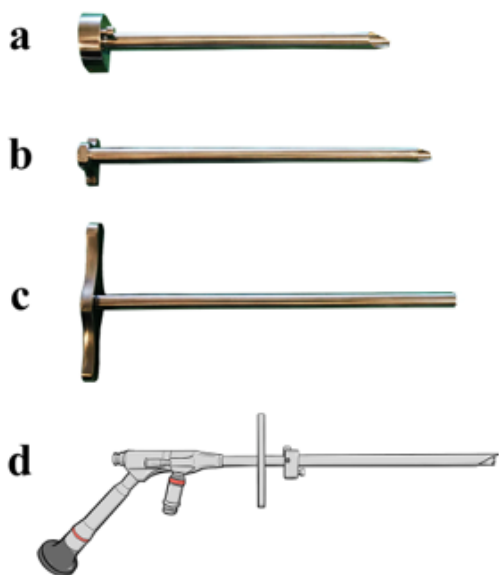


Figure 1

Instruments designed for foraminotomy and laminectomy. a. An outer working cannula was applied as an anchor on the lamina and articular processes. b. A trepan was applied to remove the osteophyte through the working cannula. c. An inner working cannula was applied as a channel of the endoscope. d. The assembled instruments with endoscopic system.

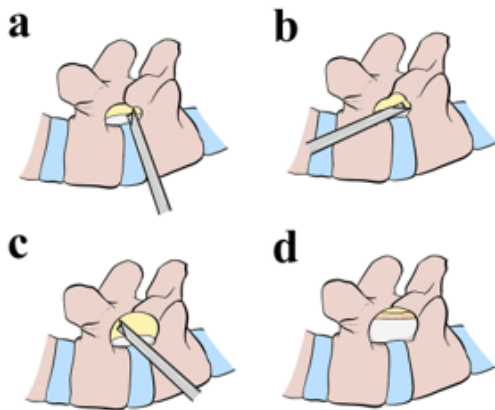


Figure 2

Sagittal schematic diagram of TF approach. a. A trepan was introduced to remove the ventral osteophyte of superior articular process. b. The base and transitional region of the inferior articular process was removed to expose the caudal insertion point of ligamentum flavum. c. The isthmus of the superior articular process was removed to expose the cranial insertion point of ligamentum flavum. d. The osteophytes, hyperplastic ligamentum flavum and disc were removed to achieve the decompression of spinal cord and exposure of nerve root.

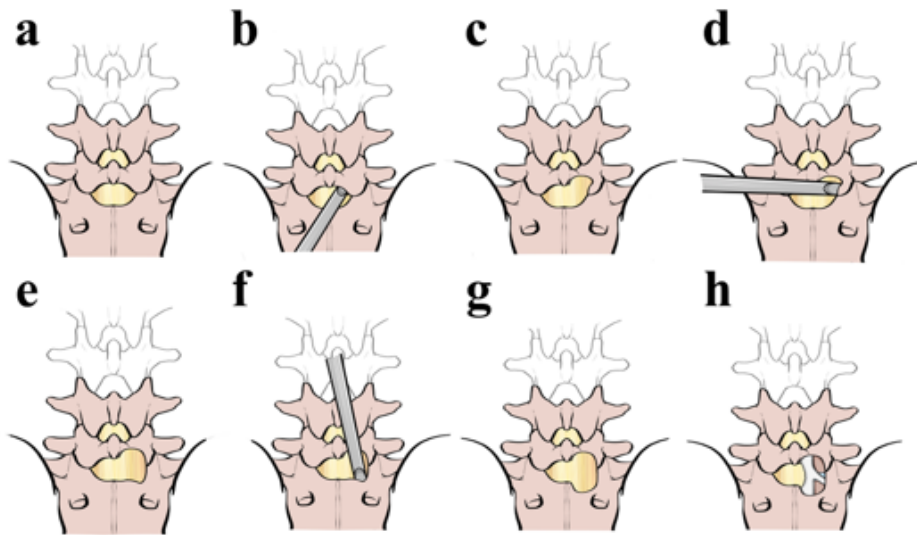


Figure 3

Rear schematic diagram of IL approach. a. A preoperative back view of the L5/S1 segment. b. The trepan was pointed to the inferior margin of the L5 lamina. c. The inferior margin of the lamina and articular process was removed to expose the cranial insertion point of ligamentum flavum. d. The trepan was pointed to the inner margin of the L5-S1 facet joint. e. The inner margin of L5 inferior articular process and S1 superior articular process was removed to expose the outer margin of ligamentum flavum. f. The trepan was pointed to the superior margin of the S1 lamina. g. The superior margin of the lamina and articular process was removed to expose the caudal insertion point of

ligamentum flavum. h. En-bloc resection of the unilateral hyperplastic ligamentum flavum to expose the axillary and under-shoulder space of S1 nerve root.