

Season, Weather, Arthritis, Dermatitis, and Cardiovascular Abnormalities – Systemic Diseases Caused by Foot Fungal Infection and Its Secreted Proteins, Case Report



CHARLES XIAOXIANG ZHU (✉ charles.zhu@live.com)

Case report

Keywords: Arthritis of fungal protein, Aspergillus skin infection, rheumatic diseases pathogenesis, methotrexate, case report

Posted Date: January 23rd, 2020

DOI: <https://doi.org/10.21203/rs.2.21676/v1>

License:   This work is licensed under a Creative Commons Attribution 4.0 International License.
[Read Full License](#)

Abstract

Background

The cause of many rheumatic diseases is still unknown. Some Infections might play a role, but the causative evidence is far from definitive. In this arthritic case, an association between a chronic foot fungal infection with *Aspergillus sydowii* (Aspsy) and arthritis was initially suggested when the treatment of foot hyperkeratosis-like lesions (Xiangya lesions) provoked multiple joints arthritis symptoms. In order to find the association of fungal infection and arthritis, data from scrupulous observations of plantar lesions, arthritic symptoms, and weather features in events of the fungal infection relapses, foot lesion manipulation, or subcutaneous injection of fungal secreted proteins were gathered and analyzed in three years.

Case presentation

Of the patient, relapses of the fungal infections on Xiangya lesions often occurred after rainy and humid days in winter and spring. Significant relapses of the infection aggravated the symptoms of arthritis within a few days, and the symptoms gradually improved in 2-3 weeks after the remission of fungal infection by topical antifungal treatment. Also, repeated trimming/debriding Xiangya lesion or subcutaneous injection of fungal secreted proteins also induced the arthritis symptoms similar to those of foot fungal infections. Arthritis Dermatitis, bradycardia, hypertension, and elevated blood monocytes were concurrent abnormalities. Topical methotrexate on the fresh trimmed plantar lesions was able to prevent and relieve arthritis.

Conclusions

Active fungal infections on plantar Xiangya lesions were associated with cold and humid weather in winter-spring or partial lesion debridement. The active fungal infections induced and exacerbated arthritis, dermatitis, and cardiovascular abnormalities. Fungal secreted proteins may mediate the fungal pathogenicity. Effective treatments of the fungal infection improved arthritis and dermatitis. These pathological characteristics have not been described before and could be a new disease, or one of the unknown pathogenic mechanisms for some known rheumatic diseases, such as rheumatoid arthritis, psoriatic arthritis, and ankylosing spondylitis. The results of this research may provide an insight into a novel pathogenic mechanism for some chronic arthritis and may shed light on further clinical studies on the pathogenesis and environmental factors of some rheumatic diseases.

Keywords: Arthritis of fungal protein, *Aspergillus* skin infection, rheumatic diseases pathogenesis, methotrexate, case report

Full Text

Season, Weather, Arthritis, Dermatitis, and Cardiovascular Abnormalities—Systemic Diseases Caused by Foot Fungal Infection and Its Secreted Proteins, Case Report

Author:

Charles Xiaoxiang Zhu

Address:

88 Xiangya Road, Xiangya Medical School, North Campus, Building 10, Rm 303, Changsha, Hunan 410008, China

□

* Correspondence: Charles Zhu

Telephone: +86 13973168329

Email: charles.zhu@live.com

Abstract

Background, The cause of many rheumatic diseases is still unknown. Some Infections might play a role, but the causative evidence is far from definitive. In this arthritic case, an association between a chronic foot fungal infection with *Aspergillus sydowii* (*Aspsy*) and arthritis was initially suggested when the treatment of foot hyperkeratosis-like lesions (Xiangya lesions) provoked multiple joints arthritis symptoms. In order to find the association of fungal infection and arthritis, data from scrupulous observations of plantar lesions, arthritic symptoms, and weather features in events of the fungal infection relapses, foot lesion manipulation, or subcutaneous injection of fungal secreted proteins were gathered and analyzed in three years.

Case presentation Of the patient, relapses of the fungal infections on Xiangya lesions often occurred after rainy and humid days in winter and spring. Significant relapses of the infection aggravated the symptoms of arthritis within a few days, and the symptoms gradually improved in 2–3 weeks after the remission of fungal infection by topical antifungal treatment. Also, repeated trimming/debriding Xiangya lesion or subcutaneous injection of fungal secreted proteins also induced the arthritis symptoms similar to those of foot fungal infections. Arthritis Dermatitis, bradycardia, hypertension, and elevated blood monocytes were concurrent abnormalities. Topical methotrexate on the fresh trimmed plantar lesions was able to prevent and relieve arthritis.

***Conclusions* Active fungal infections on plantar Xiangya lesions were associated with cold and**

humid weather in winter-spring or partial lesion debridement. The active fungal infections induced and exacerbated arthritis, dermatitis, and cardiovascular abnormalities. Fungal secreted proteins may mediate the fungal pathogenicity. Effective treatments of the fungal infection improved arthritis and dermatitis. These pathological characteristics have not been described before and could be a new disease, or one of the unknown pathogenic mechanisms for some known rheumatic diseases, such as rheumatoid arthritis, psoriatic arthritis, and ankylosing spondylitis. The results of this research may provide an insight into a novel pathogenic mechanism for some chronic arthritis and may shed light on further clinical studies on the pathogenesis and environmental factors of some rheumatic diseases.

Keywords: Arthritis of fungal protein, *Aspergillus* skin infection, rheumatic diseases pathogenesis, methotrexate, case report

Abbreviations:

Background

Methods used in this study

Case presentation

Discussion and Conclusions

Declarations

References:

Figure legends:

Figure 1: Plantar fungal lesions and arthritis and dermatitis manifestations: Panel I: Skin fungal lesions. Photographs of hyperkeratosis-like lesions (Xiangya lesions) of right small toe (A), right plantar (B), left plantar (C), and right heel (D) were recorded at different time, Fig. A2 and D showed relapses of fungal infections, Fig. B2 and C showed trimming/debriding Xiangya lesions; Fig. E Subcutaneous injections of fungal secreted proteins on the right thigh caused local skin reactions, red, swollen, and tender. The numbers, 1,2,3,4 and 5, indicated the injection orders, as the number 5 was 16 hours after the injection and 24 hours interval for each sequential injection. Fig. C and D showed local inflammatory reactions of the skin, which were similar to the skin reaction of subcutaneous injections (Fig E).

Panel II: Arthritis and Dermatitis. Relapse of fungal infection on toes nails and improper treatment led to “sausage toes” (Fig. W) and subsequent finger arthritis (Fig. U and V) and dermatitis (Fig X, Y, and Z). The locations of dermatitis above the left knee (X) and on the lateral of the right ankle (Y) were the frequent contacting points of crossing legs during foot lesion observations. Fig. U and V also showed swollen interphalangeal joints on fingers. Arthritis and dermatitis disappeared in 1–3 months without treatments after fungal infections subsided.

Figure 2: Quantitative arthritis symptoms records during a flare-up of foot fungal infections on the right plantar heel. Sudden onset of pain on the right plantar heel during routine recreational walking on Day 0 had led to fatigue for 2–3 days, otherwise normal, and the pain relieved at rest. Local examination revealed normal skin, only reddish and slightly elevated area approximately 2.5-centimeter diameter, warm and tender by palpation. The partial surface layer of the skin over the lesion, 0.8x1.0 centimeter, was removed on Day 5, topical ciclopirox cream was started to apply on the lesion twice daily, and the fungal lesion became dark red pigmented a day after (not bleeding) (Fig. 1D). Multiple joints stiffness, pain, and tenderness were recorded according to a visual analog scale 0 as no pain to 10 as the most severe pain possible^[7] and displayed in B and C, in which stiffness of four fingers of each hand, F2, F3, F4, and F5, was measured with calipers five times at 8 (within 10 minutes after waking up), 12, 16, 20, and 0'o clock daily, and the average stiffness of four fingers of each hand along with daily record of joint pain and tenderness were plotted and displayed on top of the observational events (D).

Figure 3: Quantitative arthritis symptoms records during subcutaneous injection of fungal secreted proteins. B showed finger stiffness of right hand (red), and left hand (blue), and C showed multiple joint

pain and tenderness during the second trial of subcutaneous injections of fungal secreted. On Day 19, a relapse of fungal infections was retrospectively observed on the right small toe (Fig. 1-A2).

Figure 4: Two trials of observations

Fig A (Trial 1) and Fig B (Trial 2) display daily measurements of blood pressures (top), heart rate (middle) and finger stiffness of both hand (N = 8) (bottom) in five times at wakeup, 12, 16, 20 and 0 o'clock of two trials in the summer-autumn of 2016 (Trial 1) and in the winter of 2017–2018 (Trial 2) plotted along the dates of the treatments and observations as described in the following table.

Events

Trial 1

Trial 2

Treatment-Observation

I

Day 1

Day 1–12

Pre-experimental baselines

II

Day 2–46

Day 13–21

Injections of fungal secreted proteins*

III

Day 47–65

Day 22–40

Observation only

IV

Day 66–72

Day 41–57

Repeated trimming/debriding hyperkeratotic lesions, applying topical antifungal ointments on the fresh trimmed lesions**

V

Day 73–112

Covering the trimmed lesions with cyanoacrylate glue, refreshing every 2–3 days

VI

Day 113–125

Observation only; idled Day 126–179 in Trial 1

VII

Day 180–193

Day 58–85

Repeated trimming/debriding the foot lesions and applying methotrexate ointment on the fresh trimmed lesions

VIII

Day 86–90

Relapse of fungal infection on the right plantar heel with no topical treatment**

IX

Day 91–116

Treating fungal infection on the right heel with topical ciclopirox ointment

* Fungal secreted proteins in the culture medium were used in Trial 1 or after purified and concentrated in PBS in Trial 2.

** Intracellular fungi produced fungal secreted proteins in hyperkeratotic lesions.

Fig C The intraday blood pressures (top), heart rate (middle) and hand stiffness (bottom), at woke up, 12, 16, 20 and 0 o'clock, each value representing the average of 40 (or 38 available) measurements from Day 77 to Day 116 in Trial 2, when the daily average systolic pressures were equal or higher than 140mmHg.

Fig D Daily average finger stiffness of four experiments/observations, Control I and Methotrexate I in Trial 1, Day 65–78 and Day 180–193 respectively, and Control II and Methotrexate II in Trial 2, Day 48–61 and Day 57–70 respectively, were plotted on one chart. For all the experiments, plantar Xiangya lesions were trimmed on Day 0 and further trimmed/debrided the lesions every 2–3 days in the next 6–8 days. Topical antifungal + 0.2% methotrexate cream was given twice daily in Methotrexate I and II and topical antifungal cream in Control I and II. The results indicated that trimming/debriding Xiangya lesions led to the aggravation of finger arthritis and methotrexate prevented the aggravation. In the figure, we also see that the finger stiffness from October 4 of 2016 to January 27 of 2017 and December 23 of 2017 had been improving from 12.7mm to 10.2mm and 5.9mm, respectively.

Figure 5: Mechanism of fungal protein-induced chronic systemic abnormalities (Zhuxiang Syndrome)

Figure 1: Plantar fungal lesions and arthritis and dermatitis manifestations:

Panel I: Skin fungal lesionsPanel II: Arthritis and Dermatitis



Figure 2: Quantitative arthritis symptoms records during a flare-up of foot fungal infections on the right plantar heel.



Figure 3: Quantitative arthritis symptoms records during subcutaneous injection of fungal secreted proteins



Figure 4: Two trials of observations

A. Trial 1: Summer-Fall of 2016B. Trial 2: Winter of 2017–2019



C. Intraday Joint Stiffness, Heart Rate, Blood Pressure D. Topical Methotrexate on Trimmed Lesions Affects Arthritis



Figure 5: Mechanism of fungal protein-induced chronic systemic abnormalities (Zhuxiang Syndrome)



Table 1 Weather affecting eight relapses of foot fungal infection

*Weather conditions

Temperature

(°C)

Humidity

(%)

Barometer

(hPa)

Visibility

(km)

Wind speed

(km/h)

Rain

(days)

Seven days

prior to relapses

Average

11.5

81.4

1023

6.1

8.5

4

(Range)

(-1~19)

(62~92)

(1017~1030)

(3~9)

(6~11)

(2~5)

***3 year*

Average

17.6

75.3

1015.7

7.2

8.5

3

(Range)

(-3~34)

(31~100)

(997~1046)

(1~25)

(2~26)

(0~7)

P-value

<0.01

<0.025

<0.0005

<0.05

<0.5

<0.01

* Daily averages of temperature, humidity, barometer, visibility, wind, and raining days of the seven days prior to the photograph date of eight relapses of the fungal infection were investigated for their associations with the relapses.

** 3 years from May 1, 2015 to April 30, 2018

Background

Introduction Rheumatic arthritis, such as rheumatoid arthritis, psoriatic arthritis, and ankylosing spondylitis, are lifelong maladies with genetic and environmental factors playing a significant role in their pathogenesis. The environmental factors may consist of environmental hazards, dysbiotic conditions, and infections of bacteria, fungi, or viruses [1, 2]. Nonetheless, causative evidence of the environmental factors is far from definitive. One of the difficulties for proving environmental pathogenic factors and mechanisms is the lack of evidence of infecting agents that are persistently present and mediate the pathogenic effects throughout the fluctuating course of the chronic diseases. Also, season and weather are known affecting chronic arthritic symptoms of many patients, but the underlying mechanism is still a mystery [3, 4, 5].

Chronic foot fungal infections are prevalent in the general population [6]; *Aspergillus* species have emerged as a common pathogen of foot fungal infections [7]. Despite the high prevalence of cutaneous fungal infections, their pathogenic effects on human health and systemic diseases have not been adequately studied and are mostly unknown. Increasing research evidence might have implied that *Aspergillus* infection may associate with rheumatic diseases [8, 9, 10], but the underlying causal relationship has yet to explore.

For the same case, we have recently found that fungus *Aspergillus sydowii* causes both extracellular and intracellular infections of foot skin[11]. The *Aspergillus* infected anucleated human skin keratinocytes, formed the fungal-human composite cells (zombie cells), and reanimated them to grow and proliferate to form hyperkeratosis-like lesions, Xiangya lesion, which resists antifungal drugs and produces abundant fungal proteins. An association between the fungal infection and arthritis was initially suspected when arthritis symptoms occurred during the treatment of long-time foot fungal infections and hyperkeratosis-like lesions. In this report, the weather, the recurrence of fungal infections, and the symptoms of chronic arthritis during the three years were dynamically observed and analyzed. Seemingly harmless plantar fungal infections and Xiangya lesions were found responsible for causing chronic arthritis, dermatitis, and cardiovascular abnormalities.

Patient Information and History: The patient was a 58 years old male and recently had flare-ups of arthritis on multiple finger joints and dermatitis after moved to Wuhan. He had a history of joint stiffness, swelling, and pain on fingers and elbows at the age of 15–22-year-old in winters in Changsha, China, and history of tinea pedis, onychomycosis, and plantar callus for more than 43 years. He experienced a sudden onset of itching and painful pustules and plaques skin lesions over wide back area of body and limbs after a casual consumption of alcohols and insomnia for the night in the December of 1982 and

was diagnosed as psoriasis and treated with topical hydrocortisone ointment and oral antibiotics, which had little effect for the lesion improvement. However, two weeks later, he moved Beijing, where indoor temperature and humidity were around 25–28°C and 15–30% respectively (comparing 2–10°C and 80% in Changsha), the lesions were entirely disappeared without treatment in 3–4 weeks and had not recurred since. The arthritis symptoms had also improved after he moved to Beijing and Michigan for the last 30 years, but finger stiffness remained. He had 40 years of smoking history, otherwise healthy. In February 2015, he moved to Wuhan, 310 kilometers north from Changsha, and the two cities have similar weathers all year round. During an episode of aggressive treatment of his onychomycosis and plantar hyperkeratotic lesion by repeated trimming/debriding and applying topical terbinafine and fluconazole ointments, he provoked arthritis symptoms attack in May of 2015. Arthritis symptoms subsided gradually within a month following the improvement of foot lesions. One of his aunts was diagnosed with psoriasis and another with vitiligo and ankylosing spondylitis after their 70s-year-old, otherwise, no other family arthritis history.

Foot examination showed onychomycosis of seven toenails, varying from distal and lateral subungual form to total dystrophic form, two on the left and five on the right foot, and three plantar callus-like hyperkeratosis lesions with pressing pain on feet. The combined surface area of these lesions on two feet was approximately 30 square centimeters. Hand examination revealed proximal interphalangeal joints fusiform with the tenderness of middle and index fingers, stiffness with 3–5 millimeters gaps between distal and proximal phalanges at maximum flexing of the fingers, and bumpy nodules on the digital skin.

Methods Used In This Study

Observations of weather and relapses of the fungal infection: The historical weather data for Wuhan City from May 1 of 2015 to April 30 of 2018 was downloaded at Weather Underground [12]. Foot lesions were examined every 1–3 days, and photographs of the lesions were taken. Recurrences of foot fungal infections were retrospectively determined based upon the appearance of inflammatory features on the photos. The weather conditions of the seven days before the photograph record dates of the relapses were considered affecting fungal growth and being the time needed for fungal growth to become visible lesions. The means of temperature, humidity, barometer, visibility, wind, and days of rain within the period were statistically analyzed with SPSS Statistics 17.0 software (SPSS, Chicago, IL).

Finger stiffness measurement with caliper: A caliper with 0.02mm precision was used to quantitatively measure interphalangeal joint stiffness of the 2nd, 3rd, 4th, and fifth fingers (F2, F3, F4, and F5) of the hands. In measuring, the external jaw of the caliper was pushed till pain or resistance occurred under the jaw pressure, to measure the shortest distance span between the nail and the backside of the proximal phalanx of the finger at maximal flexion. Repeated measurements were avoided because they can affect the flexibility of the joint and make the readings smaller. This method measures the stiffness of the proximal and distal joints of the fingers, not including the metacarpophalangeal joint. The measured reading consists of the thickness of the finger and stiffness of the joint, that is, Finger Stiffness =

Measured reading—Finger thickness, in which finger thickness includes proximal and distal phalanx thickness.

For single measurement, the intra-class correlation coefficient (ICC) was 0.924, and 95% confidence interval was 0.890 to 0.953, for the average of 25 measurements had higher intra-rater reliability with ICC 0.997, and 95% confidence interval 0.995–0.998, which means highly reproducible.

Fungal secreted proteins: Primary culture of skin lesions and subsequent fungal cultures were carried out using human cell culture medium (a chemically defined medium, ATG293, Shenzhen Yisheng Branch Co., Ltd., China). After the fungal culture, the medium was collected by centrifugation at 4000 rpm (3000 g) for 15 minutes and filtered twice through a 0.22µm cut-off syringe filter. Subcutaneous injection used the filtered medium. The medium above was concentrated 33 times on the Amicon Ultra–15 centrifugal filter device (Minipore, UFC 901096) by centrifugation and used for protein quantification on SDS-PAGE. The concentrated proteins were applied to SDS-PAGE and visualized by coomassie blue stain, about thirty protein bands ranging from 5kD to 200kD of molecular weight were detected and quantified with gel image analysis software; as a result, equivalent concentrations of the proteins in the original medium were 0.01 to 1.5µg/mL. Concentrated protein above was diluted with phosphate-buffered saline (PBS) to about five times the concentration of the original medium, and then further sterilized filtering through a syringe filter with a cut-off size of 0.2µm (17597-K, Sartorius, Germany) and stored in a refrigerator at 4 °C before used for subcutaneous injections.

The subcutaneous tests and observations: In this study, the subcutaneous injection of fungal secreted protein to human subjects (researchers) followed current guidelines for skin prick tests that are allergic to air allergens [13, 14]. In the three years, two focused observational trials had been conducted to examine the relationship of foot fungal infections and arthritis, starting with subcutaneous injection of fungal secreted proteins for 46 days in the first trial and nine days in the second trial. For the first trial, 800–1000µL of culture medium from 3 fungal strains and the second trial 200µL of the concentrated fungal secreted proteins were given daily by subcutaneous injections on the front of the thighs, which was the most convenient for self-administering the injections and for observing local reactions. On the trials, the assessments of finger stiffness were measured with calipers five times a day at wakeup, 12, 16, 20, and 0 o'clock, meanwhile taking the blood pressure and heart rate. Joint pain and press pain of joints, including joints of hand digitals, wrists, elbows, knees, ankles, and lumber, was self-examined and recorded in visual analog scale (VAS) once daily[15].

Clinic laboratory tests: multiple clinic laboratory tests of full blood cell count, liver and kidney function tests, autoantibodies rheumatoid factor (RF) and anti-cyclic citrullinated peptides (anti-CCP) and C-reactive protein (CRP), and erythrocyte sedimentation rates were tested at Tongji Medical Center at Optics Valley, Wuhan, and X-ray examinations at the Radiology Department of Nanjing PLA General Hospital, Nanjing and Changsha Central Hospital (Northern Facilities) in outpatient settings.

Treatment of feet lesions: Topical antifungal treatments with terbinafine, fluconazole, clotrimazole, ketoconazole, ciclopirox, urea, and salicylic acid creams were over-the-counter drugs and daily oral

terbinafine 125mg, fluconazole 100mg was prescribed at the local hospital. Methotrexate 5mg/vial was mixed with 2.5 grams of terbinafine cream or ciclopirox cream above into 0.2% methotrexate cream for topical uses. A total of 18 vials of 5mg methotrexate were used on foot lesion for accumulative four months within a year. Liquid cyanoacrylate glue (superglue) was directly applied to the surface of fresh trimmed lesions and polymerized in a minute to form a thin film isolating atmosphere from lesion cells [11].

Case Presentation

Weather and relapses of fungal infection: Ten relapses of plantar fungal infection were photo-recorded from May 1 of 2015 to April 30 of 2018, and all occurred at the hyperkeratosis-like Xiangya lesion. Eight of the ten relapses occurred between October to March, correlating with winter and early spring, and the rest two occurred in August and September of 2017 in a period the subject worked and lived in air-conditioning facilities for more than 20 hours a day. Compared to the 3-year average weather, the 7-day weather during the relapses was higher pressure ($p < 0.0005$), lower temperature ($p < 0.01$), rainy day ($p < 0.01$) and higher humidity ($p < 0.025$) (Table 1).

Fungal infection and arthritis: Some of the recurrences of the fungal infections were barely noticed and were observed only in the photo records review. In the significant relapses, the infection caused topical inflammatory symptoms, such as red, warm, pain, and swollen, and 3–5 day fatigue, and followed by the onset of arthritis symptoms in days, including stiffness, pain, tenderness and swollen around the joints of fingers, toes, limbs and lumbar (Fig. 1 and 2), and cutaneous nodules on side of finger. Arthritis lasted for the entire course of the fungal infections. Dermatitis and cardiovascular abnormalities concurred with arthritis. Although no anti-arthritis remedy was given, arthritis symptoms faded in a week to two weeks after plantar inflammation subsided.

During the episode of arthritis, the blood monocytes count was elevated at $0.61 \times 10^9/L$ during arthritis, and returned to $0.51 \times 10^9/L$, (norm 0.10×10^9 to $0.60 \times 10^9/L$) in remission. Serum galactomannan (GM) was 0.04. The rest laboratory tests, including the rest of the blood cell count, liver and kidney function tests, rheumatoid factor, anti-CCP antibody, erythrocyte sedimentation rates, and C-reactive protein were all in the normal range during relapses or remissions. The X-ray showed the asymmetric increased thickness of soft tissues on the affected fingers and interphalangeal joints and did not reveal any bone and cartilage deformities on the joints of the hands and fingers (data not shown).

Fungal secreted proteins and arthritis: The amount of fungal secreted proteins for subcutaneous injection was equivalent to 1mL fungal culture medium (either straight medium or 200 μ L five times concentrated protein solution in PBS, which consisted of approximately 30 secreted protein peptides at a concentration from 0.01 to 1.5 μ g/mL. The causative protein(s) seemed rather stable as that the protein solution of the injections was stored at 4°C for 14 months and still induced arthritis.

The injections on the front of thighs caused local skin reactions, red, swollen, pain, and tender in areas about 4–8 centimeters in diameters starting in 3–4 hours and lasting for 2–4 days (Fig. 1E). This reaction was similar to the appearance of the skin reaction of the fungal infection or trimming Xiangya lesion. Arthritis symptoms measuring by finger stiffness started in 2–3 days after the initial injection, and in 7–9 days, they quickly improved after the injections ceased (Fig. 3B and C). Once-daily of the injection for nine consecutive days induced arthritis symptoms for 15 days (Fig. 3). Prolonged period injections extended the duration of arthritis accordingly (Fig. 4A). Elevated blood monocytes count, $0.65 \times 10^9/\text{L}$, also occurred. The secreted protein(s) that causes arthritis were very potent and should need no more than $2\mu\text{g}/\text{day}$ in each subcutaneous injection, which is 100,000 times less than the amount 200mg of anti-TNF α antibody used one dose per injection in arthritis treatment.

Subcutaneous injections to lab mouse: Before self-experimentation with subcutaneous injections of fungal proteins, 100 μL of culture medium from 6 fungal strains' cultures and fresh medium as control were given subcutaneously to seven groups of three mice in each group for eight consecutive days, and observations continued for ten additional days after the injections. No apparent adverse effect or skin and joint abnormalities resulted from the injections were observed (data not shown).

Xiangya lesion and arthritis: Overgrowth of plantar hyperkeratosis-like Xiangya lesion rendered walking pain beneath the lesion and warranted to trim the lesion for pain relief every two months or so. Repeatedly trimming/debriding the lesions led to lesion cell rapid growth and local stimulation sensations for 2–3 days by fungal proteins [11] and followed by the arthritis symptoms in 2 days (Fig. 4D). Topical methotrexate applying twice daily on the lesion immediately after trimming/debriding provided local symptom relief as well as prevented the aggravations of arthritis symptoms (Fig. 4D). Similarly, covering the trimmed lesions with cyanoacrylate glue also had the effect of local symptom relief.

Dermatitis: Dermatitis was a concurrent skin manifestation associated with the relapses of arthritis caused by the fungal infection of the foot and activation of the Xiangya lesion, but it was less apparent when the subcutaneous injection of the fungal proteins was from the cultures. Dermatitis of the skin at the exterior side of the right ankle, above the left knee, the back of finger joints, auricles, and behind auricles gradually emerged following the relapses of the foot fungal infections and arthritis and lasted longer (Fig. 1). The skin started with red and itch, gradually became hyperkeratotic, rough, and pigmented. There were bumpy nodules on or near the arthritic joints, some pain in the active phase of arthritis. Eventually, in months after the arthritis symptoms subsided, peeling skin on dermatitis sites occurred, and the skin returned to a regular appearance in the absence of any topical treatment to dermatitis. Nevertheless, some residual of finger stiffness, dermatitis on the back of fingers, finger nodules, and high blood pressures stayed into the summer and throughout the year.

Cardiovascular abnormalities: Edema, high blood pressure, and bradycardia were found to be associated with skin fungal infections (Fig. 4 A and B). The edema manifested as swollen digital joints, finger stiffness, and pitting edema on the plantar soles, especially in the morning or after a one-hour walk (Fig.

4). Its appearance coincided with arthritis, but lasted longer and became less severe and eventually disappeared in late summer and autumn.

An increase of blood pressure (BP), especially with systolic pressure, was found to associate with foot fungal infection and fungal secreted proteins in the two trials, where the 30-day average BP (systolic/diastolic pressure) increased from 129/83mmHg in the early phase of the first trial (N = 150) to 150/89 mmHg at the end of the second trial (N = 150) over 1.5 years (Fig. 4A and B). The 30 day average of BP was at 147/83mmHg in four months without using anti-hypertension medications after the second trial ended. Systolic pressure increased more than diastolic pressures, which indicated a decrease of vascular compliance for the underlying cause, possibly due to atherosclerosis, maybe, a mechanism similar to that of the nodule formation on the fingers. Nevertheless, more research will need for the cause of hypertension.

The heart rate of the subject gradually decreased from 70–80 beats per minute to below 60 beats per minute in two trials (Fig. 4). It was sinus bradycardia on an electrocardiogram. After the first trial, the daily average of heart rate slowly returned to 65–75 beats/minute (5 measurements/day, seven days) in 4 months, and after the second trial, 65–70 beats per minute (5 measurements/day, seven days) in 4 months and 70–82 beats per minute (5 measurements/day, 7 days) in 8 months with a remission of the fungal infection.

Methotrexate: Topical 0.2% Methotrexate ointment on freshly trimmed hyperkeratotic lesions twice daily for seven days showed slow growth of the lesion, relief of topical irritation and preventing arthritis symptoms induced by trimming/debriding the Xiangya lesions (see Fig. 4 D). Methotrexate might also reduce the arthritis symptoms after applied to the lesions of the fungal infection. However, methotrexate did not seem to cure the Xiangya lesion, to reduce the lesion size in the long term, or to prevent relapses of fungal infection after ceased.

Treatment: Active fungal infections subsided after treatments with lesion debridement and topical antifungal drugs, namely terbinafine, ketoconazole or ciclopirox, with or without methotrexate and achieved remissions in 3–5 weeks. Arthritis and dermatitis had not been treated for their symptoms and were improved after active fungal infection retreated (Fig. 2). All topical drugs, including terbinafine, fluconazole, clotrimazole, ketoconazole, ciclopirox, urea, and salicylic acid ointments, or oral terbinafine and fluconazole did not seem effective in reducing hyperkeratotic lesion size or the relapses fungal infection on the lesions after ceased the medicine. Topical methotrexate and cyanoacrylate glue film were able to alleviate local symptoms and shortened the period of surging arthritis symptoms. Nevertheless, the 14 days average finger stiffness had been decreased from 13.5mm to 6.08mm, about 7.4 millimeters improvement of the stiffness (54.9% decrease) in 14 months from October 2016 to December 2017 (Fig. 4-D), possibly due to oral terbinafine 125mg/day or fluconazole 100mg/day for 45 days, 3 times each regimen in two years, plus topical treatments and frequent caliper finger measurements serving as digital flexibility exercises.

Disussion And Conclusions

In summary, this case study has shown that 1) foot chronic fungal infections can cause chronic systemic abnormalities, including arthritis, dermatitis, and cardiovascular abnormalities; 2) the fungal pathogenicity of systemic diseases is mediated by fungal secreted proteins; 3) the mechanism of the seasonal and weather-related environmental factor to trigger arthritis attacks can be mediated by affecting fungal activity on infected skin, and 4) the application of topical methotrexate and antifungal agents onto the fungal lesions prevents or alleviates arthritis symptoms.

Chronic hyperkeratotic lesions of the foot (Xiangya disease) are caused by *Aspsy* infection and are the source of relapse of the fungal infection. The relapse of the fungal infection is often triggered by a high barometer, rainy, cold, and humid weather conditions in winter and spring. The infection involves dermis with an indication of local irritation and pain beneath the lesion and may disperse fungal secreted proteins into the systemic circulation. The fungal secreted proteins per se, without live fungi, distribute to remote organs and tissues of the body and cause complex systemic abnormalities, namely arthritis, dermatitis, and cardiovascular anomalies. It is a pathological process caused by fungal secreted proteins and is named Zhuxiang syndrome (Fig 5). The genetic makeup of each individual may determine the acceptability of fungal infection. The complex of the pathogen-host relationships could manifest a spectrum of variable clinical representations of the diseases in different individuals and different species or strains of fungi. Further investigation will need to find out if more fungi, especially other *Aspergillus* species, have a similar pathogenic mechanism as *Aspsy* of this case.

The Xiangya lesion is an intracellular fungal infection of the skin epithelium consisting of composite human-fungal cells, zombie cells that express fungal proteins [11]. After trimming/debriding the lesion, the remaining lesion cells multiply more rapidly, produce abundant secreted proteins of *Aspsy*, which disperse into the systemic circulation and lead to arthritis and dermatitis. Fungi are ecological species that modify their phenotypes and genotypes in adapting environmental and nutritional conditions [16, 17], which might lead to changes in its secreted proteins according to the locations or the depth into deeper tissues of the human body. It could be conceivable if such infection of *Aspergillus* progressing from skin epithelium to under dermis tissue, blood vessels, muscles, and bones would cause hosts' remote tissue damages accordingly as the diseases progress.

The mechanism of methotrexate, a disease-modifying anti-rheumatic drug (DMARD) in arthritis treatment, is considered acting on the human immune system but is still not clear how it works exactly [18, 19]. Topical use of methotrexate can prevent arthritis symptom attack or relieve arthritis symptoms in 14 days. The mechanism of its effect is more likely due to its inhibitory effect on fungal protein productions rather than to modulate the host immune system.

Aspergillus sydowii, widely present in soil and a known pathogen of sea fan corals [20], has been reported in foot infections cross continents [21, 22, 23], together with other pathogenic *Aspergillus* species[24], are emerging as common causative agents in foot infections[7], and recent researches have implicated potential associations of *Aspergillus* infections with rheumatic diseases[8, 25]. On another aspect, the

clinic characteristics of this case, namely the fluctuation of chronic arthritis, morning stiffness, dermatitis, cardiovascular abnormalities, and season-weather effects and methotrexate effect on arthritis, represent some clinical features of many rheumatic diseases [26, 27]. Foot fungal infections and their secreted proteins in the role of chronic arthritis could be one of the unknown causes for some known chronic arthritis, such as psoriasis, rheumatoid arthritis, or ankylosing spondylitis. Nevertheless, to make the differential diagnoses of rheumatic diseases and Zhuxiang syndrome would be of tremendous value in the diseases' treatment and prognosis because the fungal infection could be curable while most of the rheumatic diseases not.

Conclusions: Active fungal infections on plantar Xiangya lesions were associated with cold and humid weather in winter-spring or partial lesion debridement. The active fungal infections induced and exacerbated arthritis, dermatitis, and cardiovascular abnormalities. Fungal secreted proteins may mediate the fungal pathogenicity. Effective treatments of the fungal infection improved arthritis and dermatitis. These pathological characteristics caused by secreted proteins of *Aspergillus* skin infection have not been described before and could be defined as a new disease, or one of the unknown pathogenic mechanisms for some known rheumatic diseases, such as rheumatoid arthritis, psoriatic arthritis, and ankylosing spondylitis. The results of this research may provide new insights into the pathogenic mechanism for some chronic arthritis and dermatitis and shed light on further clinical studies on the pathogenesis and environmental factors of some rheumatic diseases.

Declarations

Ethics approval and consent to participate: The human subject for this study was to examine the effect only on the researcher and the International Committee of Medical Journal Editors (ICMJE) registration, and approval is not required. The subject of this study was the researcher and the author of this manuscript, who had written consent to participate. A copy of the consent form is available for review by the Editor of this journal.

Consent to publish: Written informed consent for publication of his clinical details and clinical images was obtained from the patient. A copy of the consent form is available for review by the Editor of this journal.

Availability of data and materials: The author guaranty materials described in the manuscript, including all relevant raw data, will be freely available to any scientist wishing to use them for non-commercial purposes upon request.

Competing interests: The authors certify that they have NO affiliations with or involvement in any organization or entity with any financial interest (such as honoraria; educational grants; participation in speakers' bureaus; membership, employment, consultancies, stock ownership, or other equity interest; and expert testimony or patent-licensing arrangements), or non-financial interest (such as personal or professional relationships, affiliations, knowledge or beliefs) in the subject matter or materials discussed in this manuscript.

Funding: This research project was solely the authors' devotions of individual efforts and resources to understanding the mechanisms of diseases and contributing to the improvements of public health and the advances of biomedical sciences. No public or private funding was received for this research.

Authors' Contributions: Single author

Acknowledgments: After writing this research paper, the author feels deeply indebted to many people who have helped him in the entire process of this work and wish to thank them all.

Sicong Ren, MD., Pathologist of Jamaica Hospital Medical Center, New York, USA. Dr. Ren's critiques to some part of this study had been very valuable to the development and completion of this study.

Guangming, Lu, MD., Director of Department of Radiology, Jinling Hospital, Nanjing University School of Medicine, Nanjing, China. Professor Lu provided X-ray, CT, and MRI examinations and discussions on the subject's hand arthritis.

Yunzhi Zhu, MD, Retired radiologist from Children's Hospital, Changsha, China. Dr. Zhu reviewed the hands' X-ray results and interpreted arthritic soft tissue manifestation on the fingers and around finger joints.

Haibo Zhang, MD, Professor of Cardiovascular Surgery, Guangzhou, China, for his consulting in cardiovascular abnormalities and management of this research.

Wenhua Zheng, MD. Ph.D. Associate Professor Macau University, Macau, China. For the discussions of research paper writing.

Kai Li, MD. Ph.D. Professor and CSO Genetalks Biotechnologies Inc. Changsha, China. For reading the manuscript and discussions.

Cibo Huang, MD. Professor and Chair of Department of Rheumatology, Beijing Hospital, Beijing, China. For reading the manuscript.

Xiaoxia Zuo, MD. Professor and Chair of Department of Rheumatology, Xiangya Hospital, Changsha, China. For discussions of rheumatic diseases and arthritis during this research.

Juru Chen, President of GPBIO and Austach Clinic Laboratories Inc. Shanghai, China. Mrs. Chen kindly provided a job opportunity for the author to have the needed money to support the living and research expenses.

Xiong Liu, Ph.D. Scientist of Wuhan Institute of biological products. Dr. Liu helped mice research in this research.

Abbreviations

Aspsy - *Aspergillus sydowii*; VAS - visual analog scale; ICC - intra-class correlation coefficient; anti-CCP - anti-cyclic citrullinated peptides; BP - blood pressure

References

1. Arleevskaya MI, Manukyan G, Inoue R, Aminov R Editorial: Microbial and Environmental Factors in Autoimmune and Inflammatory Diseases. *Front. Immunol.* 2017 Mar 6;8:243.
2. Alexander H, Nestle FO. Pathogenesis and immunotherapy in cutaneous psoriasis: what can rheumatologists learn? *Curr Opin Rheumatol.* 2017 Jan;29(1):71–78.
3. Abasolo L, Tobías A, Leon L, et al. Weather conditions may worsen symptoms in rheumatoid arthritis patients: the possible effect of temperature. *Reumatol Clin.* 2013 Jul-Aug;9(4):226–8.
4. Guedj D, Weinberger A. Effect of weather conditions on rheumatic patients. *Annals of the Rheumatic Diseases* 1990; 49: 158–159.
5. Savage EM, McCormick D, McDonald S, Moore O, Stevenson M, Cairns AP. Does rheumatoid arthritis disease activity correlate with weather conditions? *Rheumatol Int.* 2015 May;35(5):887–90.
6. Burzykowski T, Molenberghs G, Abeck D, Haneke E, Hay R et al. High prevalence of foot diseases in Europe: results of the Achilles Project. *Mycoses.* 2003 Dec;46(11–12):496–505.
7. Bongomin F, Batac CR, Richardson MD, Denning DW. A Review of Onychomycosis Due to *Aspergillus* Species. *Mycopathologia.* 2017;183(3):485–493.
8. Horie M, Tamiya H, Goto Y, Suzuki M, Matsuzaki H, Hasegawa WT, et al. Nonspecific elevation of serum *Aspergillus* galactomannan antigen levels in patients with rheumatoid arthritis. *Respir Investig.* 2016 Jan;54(1):44–9.
9. Schønheyder H, Andersen I, Andersen P. Serum antibodies to *Aspergillus fumigatus* in patients with rheumatic diseases. *Sabouraudia.* 1983 Jun;21(2):149–57.
10. Leboime A, Berthelot JM, Allanore Y, et al. Sinus aspergilloma in rheumatoid arthritis before or during tumor necrosis factor-alpha antagonist therapy. *Arthritis Res Ther.* 2009;11(6):R164.
11. Zhu CX, Li X, Tan X, Wu G. Zombie cells, Composite Cells of Fungal-Human Keratinocytes of Plantar Hyperkeratosis-like Lesions. *Mycopathologia.* 2019 Oct;184(5):597–605.
12. The weather of Wuhan Tianhe International Airport, Hubei, China.
<https://www.wunderground.com/history/monthly/ZHHH>. Accessed May 20, 2018.
13. Bousquet J1, Heinzerling L, Bachert C, et al. Practical guide to skin prick tests in allergy to aeroallergens. *Allergy.* 2012 Jan;67(1):18–24.
14. Wang XD, Zhang L. Introduction of practical guide to skin prick tests in allergy to aeroallergens. *Zhonghua Er Bi Yan Hou Tou Jing Wai Ke Za Zhi.* 2012 Jul;47(7):611–2.
15. Joyce CR, Zutshi DW, Hrubes V, Mason RM. Comparison of fixed interval and visual analogue scales for rating chronic pain. *Eur J Clin Pharmacol.* 1975 Aug 14;8(6):415–20.
16. Baye TM, Abebe T, Wilke RA. Genotype-environment interactions and their translational implications. *Per Med.* 2011;8(1):59–70.

17. Hillary L. Mehl, Peter J. Cotty. Nutrient Environments Influence Competition among *Aspergillus flavus* Genotypes. *Appl. Environ. Microbiol.* Feb 2013, 79 (5) 1473–1480
18. Kahlenberg JM, Fox DA. Advances in the medical treatment of rheumatoid arthritis. *Hand Clin.* 2011;27(1):11–20
19. Mori S, Hidaka M, Kawakita T, et al. Factors Associated with Myelosuppression Related to Low-Dose Methotrexate Therapy for Inflammatory Rheumatic Diseases. *PLoS One.* 2016;11(4):e0154744
20. Rypien KL, Andras JP, Harvell CD. Globally panmictic population structure in the opportunistic fungal pathogen *Aspergillus sydowii*. *Mol Ecol.* 2008 Sep;17(18):4068–78.
21. Summerbell RC, Kane J, Krajden S. Onychomycosis, tinea pedis and tinea manuum caused by non-dermatophytic filamentous fungi. *Mycoses.* 1989 Dec;32(12):609–19.
22. Gupta AK, Cooper EA, MacDonald P, et al. Utility of inoculum counting (Walshe and English criteria) in clinical diagnosis of onychomycosis caused by nondermatophytic filamentous fungi. *J Clin Microbiol.* 2001 Jun;39(6):2115–21.
23. Tsang CC, Hui TWS, Lee KC, Chen JHK, Ngan AHY, Tam EWT, et al. Genetic diversity of *Aspergillus* species isolated from onychomycosis and *Aspergillus hongkongensis* sp. nov., with implications to antifungal susceptibility testing. *Diagn Microbiol Infect Dis.* 2016;84:125–134.
24. de Vries RP, Riley R, Wiebenga A, Aguilar-Osorio G, Amillis S, et al. Comparative genomics reveals high biological diversity and specific adaptations in the industrially and medically important fungal genus *Aspergillus*. *Genome Biol.* 2017 Feb 14;18(1):28.
25. Schønheyder H, Andersen I, Andersen P. Serum antibodies to *Aspergillus fumigatus* in patients with rheumatic diseases. *Sabouraudia.* 1983 Jun;21(2):149–57.
26. Giacomelli R, Afeltra A, Alunno A, et al. International consensus: What else can we do to improve diagnosis and therapeutic strategies in patients affected by autoimmune rheumatic diseases (rheumatoid arthritis, spondyloarthritides, systemic sclerosis, systemic lupus erythematosus, antiphospholipid syndrome and Sjogren's syndrome)? The unmet needs and the clinical grey zone in autoimmune disease management. *Autoimmun Rev.* 2017 Sep;16(9):911–924.
27. Koch AK, Brömme S, Wollschläger B, Horneff G, Keyszer G. Musculoskeletal manifestations and rheumatic symptoms in patients with cystic fibrosis (CF) no observations of CF-specific arthropathy. *J Rheumatol.* 2008 Sep;35(9):1882–91.

Figures

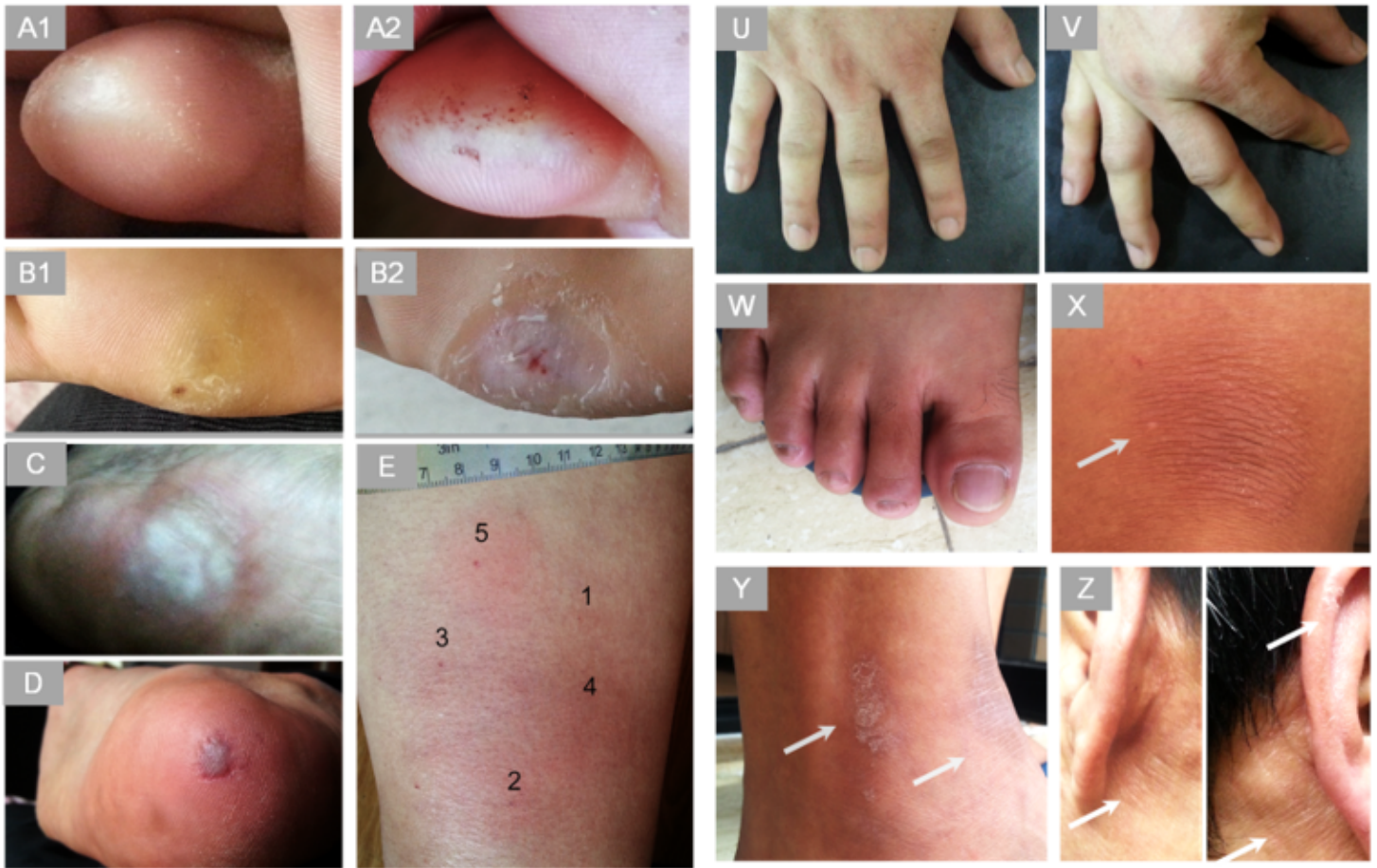

Figure 1

Plantar fungal lesions and arthritis and dermatitis manifestations: Panel I: Skin fungal lesions. Photographs of hyperkeratosis-like lesions (Xiangya lesions) of right small toe (A), right plantar (B), left plantar (C), and right heel (D) were recorded at different time, Fig. A2 and D showed relapses of fungal infections, Fig. B2 and C showed trimming/debriding Xiangya lesions; Fig. E Subcutaneous injections of fungal secreted proteins on the right thigh caused local skin reactions, red, swollen, and tender. The numbers, 1,2,3,4 and 5, indicated the injection orders, as the number 5 was 16 hours after the injection and 24 hours interval for each sequential injection. Fig. C and D showed local inflammatory reactions of the skin, which were similar to the skin reaction of subcutaneous injections (Fig E). Panel II: Arthritis and Dermatitis. Relapse of fungal infection on toes nails and improper treatment led to “sausage toes” (Fig. W) and subsequent finger arthritis (Fig. U and V) and dermatitis (Fig X, Y, and Z). The locations of dermatitis above the left knee (X) and on the lateral of the right ankle (Y) were the frequent contacting points of crossing legs during foot lesion observations. Fig. U and V also showed swollen interphalangeal joints on fingers. Arthritis and dermatitis disappeared in 1-3 months without treatments after fungal infections subsided.

red pigmented a day after (not bleeding) (Fig. 1D). Multiple joints stiffness, pain, and tenderness were recorded according to a visual analog scale 0 as no pain to 10 as the most severe pain possible[7] and displayed in B and C, in which stiffness of four fingers of each hand, F2, F3, F4, and F5, was measured with calipers five times at 8 (within 10 minutes after waking up), 12, 16, 20, and 0'o clock daily, and the average stiffness of four fingers of each hand along with daily record of joint pain and tenderness were plotted and displayed on top of the observational events (D).

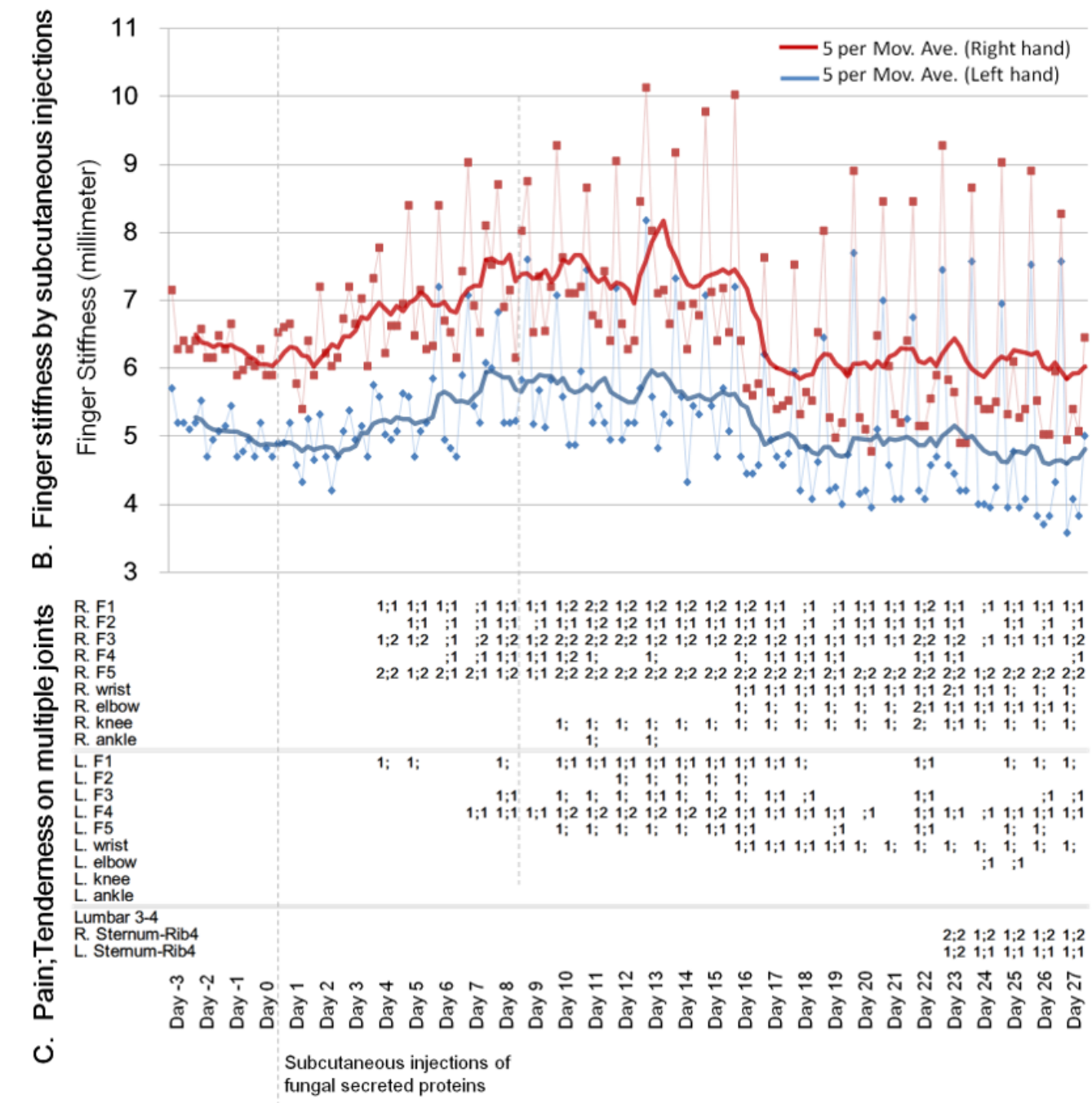


Figure 3

Quantitative arthritis symptoms records during subcutaneous injection of fungal secreted proteins. B showed finger stiffness of right hand (red), and left hand (blue), and C showed multiple joint pain and

tenderness during the second trial of subcutaneous injections of fungal secreted. On Day 19, a relapse of fungal infections was retrospectively observed on the right small toe (Fig. 1-A2).

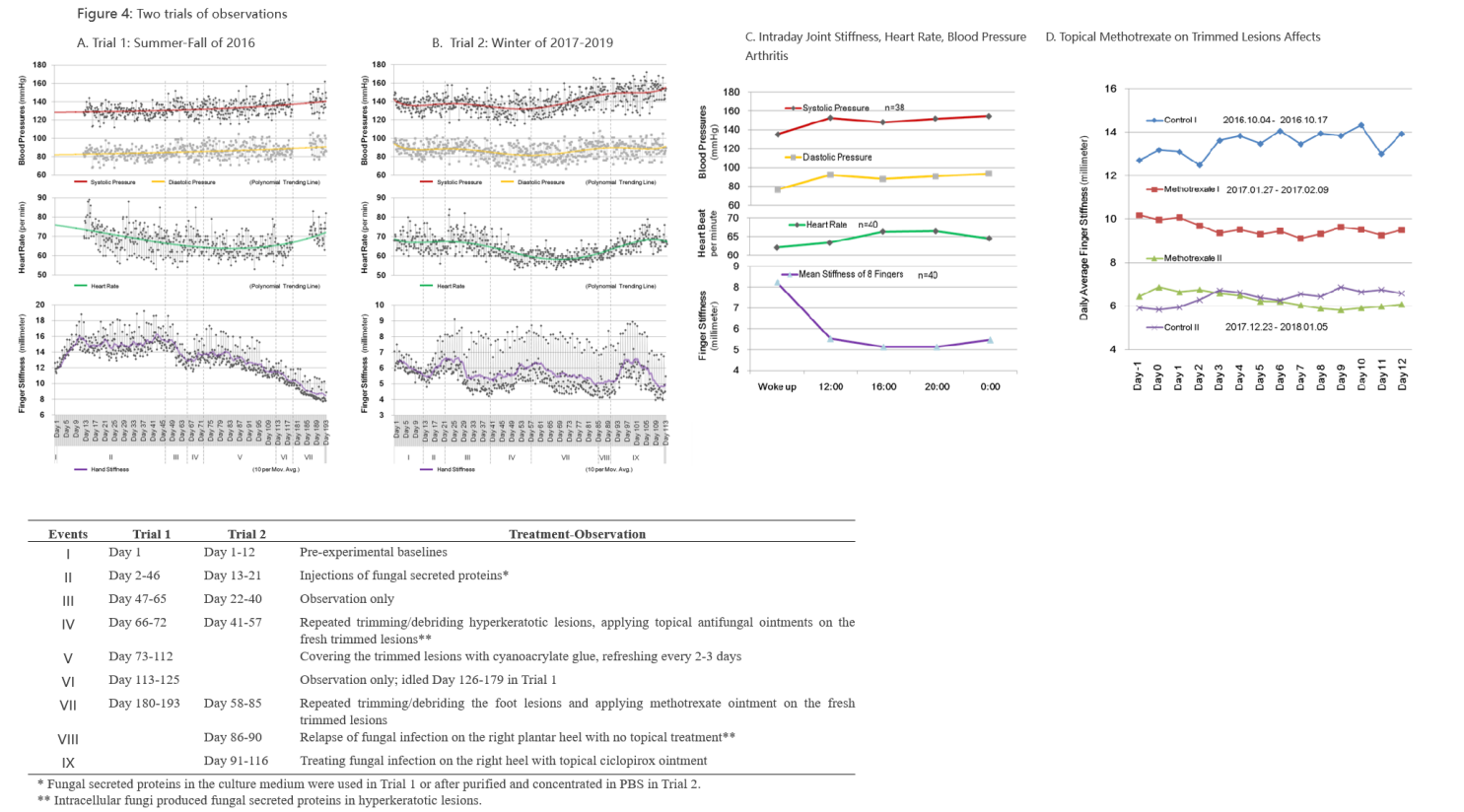


Figure 4

Two trials of observations. Fig A (Trial 1) and Fig B (Trial 2) display daily measurements of blood pressures (top), heart rate (middle) and finger stiffness of both hand (N=8) (bottom) in five times at wakeup, 12, 16, 20 and 0 o'clock of two trials in the summer-autumn of 2016 (Trial 1) and in the winter of 2017-2018 (Trial 2) plotted along the dates of the treatments and observations as described in the above table. Fig C The intraday blood pressures (top), heart rate (middle) and hand stiffness (bottom), at woke up, 12, 16, 20 and 0 o'clock, each value representing the average of 40 (or 38 available) measurements from Day 77 to Day 116 in Trial 2, when the daily average systolic pressures were equal or higher than 140mmHg. Fig D Daily average finger stiffness of four experiments/observations, Control I and Methotrexate I in Trial 1, Day 65-78 and Day 180-193 respectively, and Control II and Methotrexate II in Trial 2, Day 48-61 and Day 57-70 respectively, were plotted on one chart. For all the experiments, plantar Xiangya lesions were trimmed on Day 0 and further trimmed/debrided the lesions every 2-3 days in the next 6-8 days. Topical antifungal + 0.2% methotrexate cream was given twice daily in Methotrexate I and II and topical antifungal cream in Control I and II. The results indicated that trimming/debriding Xiangya lesions led to the aggravation of finger arthritis and methotrexate prevented the aggravation. In the figure, we also see that the finger stiffness from October 4 of 2016 to January 27 of 2017 and December 23 of 2017 had been improving from 12.7mm to 10.2mm and 5.9mm, respectively.

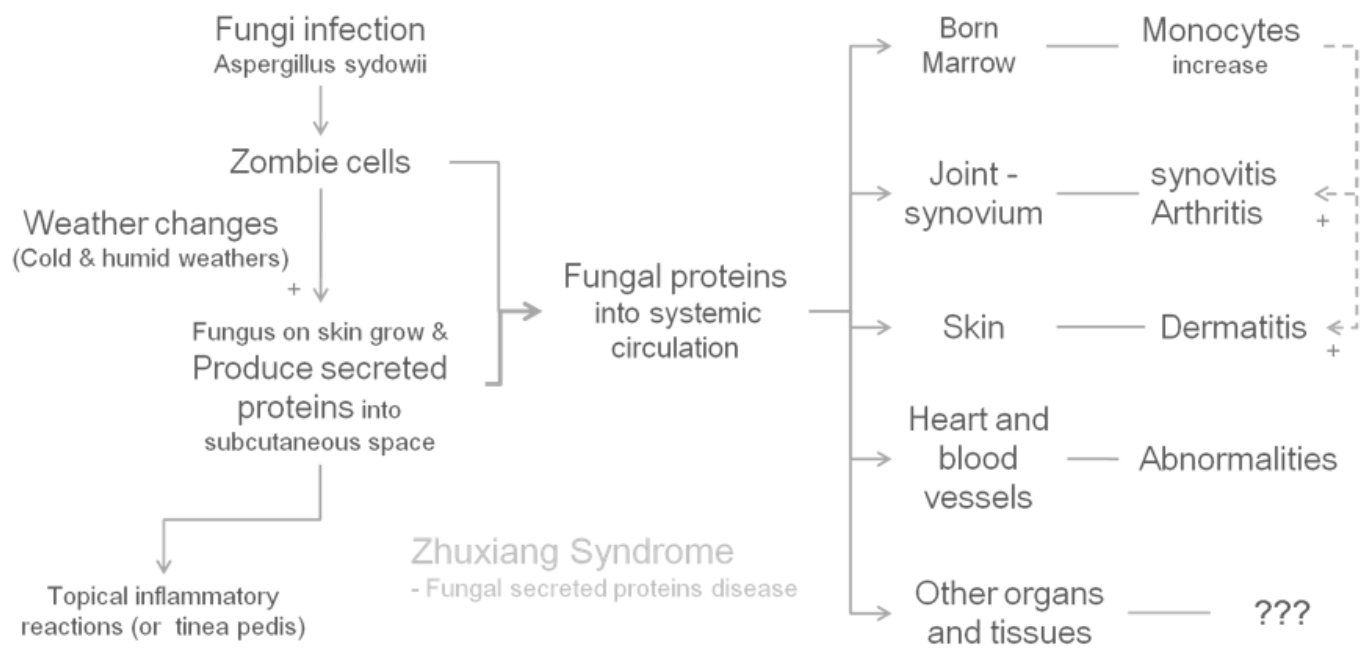


Figure 5

Mechanism of fungal protein-induced chronic systemic abnormalities (Zhuxiang Syndrome)

Supplementary Files

This is a list of supplementary files associated with this preprint. Click to download.

- [CAREchecklistZhu20200113.pdf](#)
- [fig4.png](#)