Mortality in free-ranging Eurasian brown bears (Ursus arctos arctos) in Spain (1998-2018)

Ana Balseiro (abalm@unileon.es)
University of Leon https://orcid.org/0000-0002-5121-7264

Luis José Royo
Servicio Regional de Investigacion y Desarrollo Agroalimentario

Elena Gayo
Universidad de Leon

Ramón Balsera
Gobierno del Principado de Asturias Consejeria de Desarrollo Rural y Recursos Naturales

Olga Alarcia
Junta de Castilla y Leon

Juan Francisco García Marín
Universidad de Leon

Research article

Keywords: Brown bear, Ursus arctos arctos, pathology, cause of death

Posted Date: January 23rd, 2020

DOI: https://doi.org/10.21203/rs.2.21646/v1

Abstract

Background This work summarizes the confirmed causes of death of twenty-five free-ranging Eurasian brown bears (Ursus arctos arctos) from the Cantabrian mountain range submitted for necropsy in Asturias and Castilla y León (northwestern Spain) from 1998 to 2018.

Results Causes of death were classified based on (i) pathological findings and (ii) caused by “human intervention” or “non human intervention”. In four cases (16%) it was not possible to determine the cause of death due to the bad preservation of found remains or insufficient tissue availability. Based on pathological findings seven out of the 21 (33.3%) brown bears in which the cause of death could be determined died due to infectious diseases (clostridiosis n =4 or infectious canine hepatitis n =3), two (9.5%) due to exertional (degenerative) myopathy (one of those bears also showed clostridiosis) and one due to strychnine poisoning (4.8%), neoplasia (4.8%) or mushroom poisoning (4.8%). The remaining animals died due to traumatic lesions (including fights or infanticide), shooting or wire snare. Mortality data was also classified by deaths caused by “human intervention” or “non human intervention”. The death of one bear showing exertional myopathy after handling was not ascribed to any of the former classifications. Six out of the 20 (30%) brown bears died as a consequence of “human intervention” due to illegal hunting (wire snare hunting n =3 or shooting n =2) and, strychnine poisoning (n =1). In contrast, fourteen (14/20, 70%) brown bears died by “non-human intervention”; nine of them (9/20, 45%) due to traumatic lesions (fights n =4, traumas n =3 or infanticide n =2), three (3/20, 15%) due to infectious canine hepatitis caused by canine adenovirus type 1 (CAdV-1) infection, one (1/20, 5%) due to cholangiocarcinoma and another one (5%) due to mushroom poisoning.

Conclusions This study shows that the main causes of death in Eurasian brown bears are those caused by infectious diseases. In contrast to previous data on free-ranging bears for the first time infectious diseases appear as an important cause of death. These data are valuable and may help in the conservation and management of this recovering population.

Background

In Spain the endangered Eurasian brown bear (Ursus arctos arctos) population is located in the Cantabrian mountain range (northwestern Iberian Peninsula) and represents the southwestern limit distribution for this species in Europe [1]. The population of free-ranging Eurasian brown bear has recovered during the last two decades, from approximately 100 individuals in the nineties to 230–260 presently [1, 2]. Brown bears are found dead in nature, sometimes the death is caused by human intervention, i.e. shooting, poisoning or traffic accidents, and on other occasions death is due to non-human intervention, i.e. infanticide [3, 4].

The identification of causes of mortality in wild natural populations is relevant for the correct design of conservation strategies and management programs. However, knowledge on the mortality among bears is limited because of the difficulty in finding the dead animals in nature.

The aim of the present work is to summarize the causes of confirmed deaths and most significant findings related to deaths reported in twenty-five free-ranging Eurasian brown bears submitted for necropsy in Asturias and Castilla y León (northwestern Spain) over the past 20 years. These data are valuable and may help in the conservation and management of this recovering population.

Results

Necropsy findings

The cause of death and relevant pathological findings in the twenty-five brown bears studied is shown in Table 1. In four (4/25, 16%) cases it was not possible to determine the cause of death due to bad preservation of the remains found or insufficient tissue availability.

Table 1

Available data, cause of death and pathological findings of twenty-five free-ranging Eurasian brown bears (Ursus arctos arctos) studied from 1998 to 2018 in Asturias and Castilla y León (northwestern Spain).

Bear	Date	Age	Sex	Cause of death
1	08/05/1998	7 years	Male	Snare/exertional myopathy/gangrenous myositis (Clostridium sordellii and C. bifermentans)
2	12/06/1998	Cub	Female	Infanticide
3	10/06/2000	Adult	N.d.	N.d.
4	06/06/2005	Subadult	Male	N.d.
5	26/09/2005	Adult	Male	Shooting
6	19/11/2005	Adult	N.d.	Poisoning: strychnine
7	14/06/2008	1 year	Male	Infanticide
8	27/08/2012	Adult	Male	Snare/gangrenous myositis (Clostridium sordellii)*
9	29/10/2012	Cub (9 months)	Female	Died after handling and transport/exertional myopathy
10	12/06/2014	3 years	Male	Fighting/gangrenous myositis (Clostridium sordellii and C. septicum)
11	15/06/2014	5 years	Male	Infectious disease: CAdV-1**
12	12/12/2014	9 years	Male	Fighting/septicemia
13	29/04/2015	20 years	Female	Neoplasia: cholangiocarcinoma***
14	23/05/2015	Cub (4 months)	Male	Infectious disease: CAdV-1**
15	16/10/2015	Adult	Male	Traumatic lesions/gangrenous myositis
16	05/03/2016	Adult	Male	Traumatic lesions due to fall
17	08/10/2016	Subadult	Male	Shooting
18	27/11/2016	6 years	Female	Snare/strangled
19	07/01/2017	6 years	Male	Mushroom poisoning; hepatic an renal necrosis
20	03/04/2017	Cub (3 months)	Female	Infectious disease: CAdV-1**
21	21/04/2017	19 years	Male	Fighting and cliff fall

* [5]. ** [6]. *** [8]. Grey shadow: deaths by human intervention. N.d.: not determined. CAdV-1: Canine adenovirus type 1. Bears 5, 7, 9, 11, 12, 15, 18, 24 and 25 are from Castilla y León. The remaining bears are from Asturias.

Bear	Date	Age	Sex	Cause of death
22	21/04/2017	20 years	Male	Fighting and cliff fall
23	29/09/2018	4 years	Female	Traumatic lesions/gangrenous myositis (Clostridium sordellii)
24	27/10/2018	5 years	N.d.	N.d.
25	08/11/2018	7 years	Male	N.d.

* [5]. ** [6]. *** [8]. Grey shadow: deaths by human intervention. N.d.: not determined. CAdV-1: Canine adenovirus type 1. Bears 5, 7, 9, 11, 12, 15, 18, 24 and 25 are from Castilla y León. The remaining bears are from Asturias.

Usually traumatic death causes such as shooting, wire snares, fighting or infanticide were easier to determine not only based on necropsy and histopathological studies but also using complementary diagnostic techniques (i.e. radiography) or knowledge of the behavior of this species. However other causes were more difficult to discern and are reported below. Some animals (i.e. bear number 1) showed several pathological findings that could lead to death.

Infectious diseases

The five bears (bears number 1, 8, 10, 15 and 23) with gangrenous myositis (Table 1), usually a consequence of wire snare hunting, infanticide, fights or traumas, showed serohemorrhagic edema in the abdominal cavity, thorax, pericardium, and skeletal muscle, and hemorrhages in heart, skeletal muscles, stomach, intestine, liver, spleen, and kidney. Microscopically, vascular damage and hyperacute myodegeneration consisted of myonecrosis, edema, gas, extravasation of fibrin into the interstitial spaces, and lacunar dissolution of myofibers in skeletal muscles were observed in those animals. Clostridium sordellii was identified as the etiological agent of the lesions in four of those brown bears [5]. Clostridium bifermentans was also isolated in one of the former four bears, as well as C. septicum in another one. The presence of Clostridium sordellii was always associated with previous muscle damage (i.e. traumas) that triggered its proliferation.

Gross lesions in the three bears (bears number 11, 14 and 20) with infectious canine hepatitis caused by canine adenovirus type 1 (CAdV-1) consisted of hemorrhages in thymus (in cubs), lungs, heart and mesentery; hemorraghic fluid in thoracic and abdominal cavities; friable and yellowish liver; hepatomegaly; thickening of the gall bladder due to edema and congestion of spleen, kidney and meninges [6]. Microscopically the main pathological findings appeared in liver and gall bladder. Liver showed mild centrolobular multifocal degeneration and necrosis of hepatocytes, with the presence of intranuclear inclusions bodies and low inflammatory infiltration mainly of lymphocytes. The gall bladder showed edema of the wall. Additionally, the brain showed edema, congestion, perivascular cuffing, foci of gliosis, and degeneration of neurons, mainly located in the brainstem. CAdV-1 was confirmed by quantitative polymerase chain reaction (qPCR) and immunohistochemistry.

Exertional (degenerative) myopathy

In two animals exertional myopathy was diagnosed. One of them was a brown bear that died after capture by snare for one week which also showed clostridiosis (bear number 1). An additional female cub died due to exertional myopathy after handling (bear number 9). That cub was found alone in the wild when it was two months old and it was bred in captivity until it was nine months old. Then the cub was transported in order to reintroduce it back into the wild dying during the trip. Both animals showed gross lesions consisted of dry and pale cardiac and some skeletal (mainly intercostals and femoral) muscles (Figs. 1a and 1b). Microscopically severe segmental degeneration of muscles was observed consisted of hypercontracted fibers, extensive Zenker´s hyaline degeneration and coagulative necrosis of myofibers (Figs. 1c to 1 h). Bear number 1 also showed an intensive infiltrate mainly consisting of lymphocytes and macrophages, as well as mineralization in the affected muscles (Fig. 1f). In that animal necrotic myofibers with surviving satellite cells, invading macrophages and elongating myoblasts, all indicative of events of regeneration, were also observed (Fig. 1d). The cub also showed hypoplasia of adrenal glands (1.7 grams, 0.004% relative weight; physiological relative weight 0.03%) [7].

Strychnine poisoning

In the bear affected by strychnine poisoning (bear number 6) general hemorrhages were found in several organs (heart, lungs, liver, kidney, spleen, stomach and intestine) often showing hemotorax, hemopericardium and hemoperitoneum. Microscopically vascular damage and diffuse necrosis in those organs were the most common findings. Strychnine was identified by chromatography from hair samples.

Neoplasia

Cholangiocarcinoma was observed in the liver of an old female (bear number 13) [8]. Microscopically liver tumor tissue showed tubular, acinar or pseudoglandular structures in the area facing a large cavity of necrosis with a thick trabecular growth pattern. Multiple small nodules were also present in the gall bladder. Metastatic encapsulated foci of cholangiocarcinoma were located in lung parenchyma, adrenal glands and articulation of the left elbow.

Mushroom poisoning

Bear number19 showed hemorrhagic gastritis and diffuse hepatic and renal necrosis compatible with mushroom poisoning, likely due to ingestion of poisonous Amanita spp, although that could not be confirmed by toxicological analysis.
Causes of death were classified both based on (i) pathological findings and (ii) caused by “human intervention” or “non human intervention”.

Based on pathological findings seven out of the 21 (33.3%) brown bears in which the cause of death could be determined died due to infectious diseases (clostridiosis n = 4 or infectious canine hepatitis n = 3), two (9.5%) due to exertional myopathy (one of those also showed clostridiosis) and one due to strychnine poisoning (4.8%), neoplasia (4.8%) or mushroom poisoning (4.8%). The remaining animals died due to traumatic lesions (including fights and infanticide), shooting or snare.

Mortality data was also stratified by deaths caused by “human intervention” or “non human intervention”. The death of bear number 9 showing exertional myopathy after handling was not ascribed to any of the former classifications. Six out of the 20 (30%) brown bears died as a consequence of “human intervention” due to illegal hunting (wire snare hunting n = 3 or shooting n = 2) and, strychnine poisoning (n = 1). In contrast, fourteen (14/20, 70%) brown bears died by “non-human intervention”; nine of them (9/20, 45%) due to traumatic lesions (fights n = 4, traumas n = 3 or infanticide n = 2), three (3/20, 15%) due to infectious canine hepatitis caused by CAdV-1 infection, one (1/20, 5%) due to cholangiocarcinoma and another one (5%) due to mushroom poisoning. One of the animals that died due to wire snare hunting and three of those that died due to traumatic lesions showed clostridiosis.

Discussion

This study shows that the main causes of deaths in Eurasian brown bears from the Cantabrian mountain range are those caused by infectious diseases (33.3%), namely clostridiosis (associated to previous muscle damage) or infectious canine hepatitis. In Sweden, where ninety-eight animals were analyzed, no deaths of brown bears were attributed to any infectious disease [4]. Thus, the confirmation of C. sordellii and CAdV-1 (the agent of infectious canine hepatitis in dogs) as the first causes of death in Eurasian brown bear is probably the most outstanding finding in this study [6]. In contrast with previous data on brown bears, for the first time infectious diseases are described as an important cause of death. Moreover, the four fatal cases of clostridial infection described to date, compared to the few descriptions reported worldwide, could show a higher susceptibility of the Cantabrian brown bear population to these bacteria [5]. The putative high susceptibility to infectious pathogens reported here might be a consequence of a weaker immune system due to the lower genetic diversity described for this species in the Cantabrian range subpopulation [9, 10]. Another possibility might be a high degree of circulation of the pathogens both in the environment and sympatric species (i.e. CAdV-1 carriers such as wolves) [6].

Two animals died showing exertional myopathy as a consequence of extreme exertion and stress after trapping by a snare or handling. Those are to our knowledge the second and third cases of death by exertional myopathy reported in bears in the literature worldwide. The first case was described by Cattet et al. (2008) in a grizzly bear that died approximately 10 days after capture by leghold snare in Canada [11]. Those three cases confirm the fact that the prolonged suffering in bears might cause exertional myopathy as occurs in other mammal species, i.e. red fox [12]. Therefore that should be taken into account in the management of bears. The acute presentation of adrenal hypoplasia shown in the cub could be precipitated by the physiologic stress suffered [13].

Despite of the limited number of studied cases (related to the conservation status and behaviour of the species that hampers the detection of moribund or dead bears in nature) the data reported in the present work confirm the persistence and relevance of causes of death directly related to human intervention (30%). The total number of mortalities and causes of death are a conservative figure as unreported mortality is difficult to estimate. Additionally the impossibility of establishing the cause of death in four brown bears submitted for necropsy due to the nature and/or conservation status of available samples

must be taken into account when considering the frequency and importance of the different causes of death reported in this paper.

Nevertheless, the confirmation of six out of 25 brown bears submitted to the laboratory for necropsy confirmed as death by shooting, snare and poisoning (4 of them from 1998 to 2008 and two from 2008 onwards) seems to agree with the apparent reduction in illegal killing after the mid-nineties [1, 14], suggested as a key factor for the recovery undergone during last two decades [2]. In this regard human actions were responsible of most grizzly bear mortalities in Canada [3]; as well as in Sweden, Mörner et al. (2005) found that human caused mortality stands for 64% of total submissions; meanwhile bears killed by other bears and infanticide were the most frequent cause of natural death (16%) [4].

The detection of four male bears that died after fighting, three due to traumas, three bears that died due to CAdV-1 infection, two cubs that died due to infanticide, one female died due to a cholangiocarcinoma and one male due to mushroom poisoning confirm the existence of deaths attributable to “non-human mediated” causes (70%) usually difficult to detect in nature, and thus highlight the importance of necropsies.

Traffic induced bear mortality has been documented as a common cause of death in bears in other European countries [4, 15–20]. In our study we have not reported any road-killed animals, despite one bear that died in a traffic accident (the only one reported in Spain to date) in León in 2008, although necropsy of this bear was not performed, and it is not included in this report [21].

Regarding the limited genetic variability of the Cantabrian brown bear population [2], and taking into account that a free-ranging bear can live about 25 years, we can consider that the three animals found dead at the age of 19–20 years have had the opportunity to widely contribute to the genetic stock of the Cantabrian brown bear population. However, two out of the five necropsied cubs (40%) died due to CAdV-1 infection. Thus, we can consider that an important percentage of future progenitors might die due to that infectious disease among others causes, which can be important for the maintenance of genetic variability of the species, even more in this endangered population.

Conclusion

In summary the data in the present work represent a first review of the death causes reported at necropsy in the Cantabrian brown bear population since 1998. The apparent moderate but steady recovery experienced during last decades provides a new landscape for this endangered population, where recovery and conservation works will have to be accompanied by an increasingly important effort on surveillance and management programs of the species, focused on the control of infectious diseases shared between domestic and wild animals under the one health strategy.

Methods

Twenty-five free-ranging Eurasian brown bears, nine from Castilla y León and 16 from Asturias, of different sexes and ages (see Table 1) were necropsied from 1998 to 2018.

After the detection of one dead animal and the exhaustive examination of the area in the field where the bear was found, a complete post mortem examination of each carcass was conducted at the University of León or Servicio Regional de Investigación y Desarrollo Agroalimentario (SERIDA, Asturias). Tissue samples were taken for evaluation using standard methods in microbiology, molecular techniques, virology, parasitology, toxicology and histopathology. A dental histological study [22] was performed when possible in order to determine the age of the bears. Data on bears carcass sites, necropsy findings and laboratory results were considered in making conclusions about the cause of death and allowed tracking of changes and trends in mortality throughout the years.

Ethics approval was deemed unnecessary according to Spanish national regulations (Real Decreto 53/2013).

Declarations

Ethics approval and consent to participate

Not applicable based on Spanish national regulations (Real Decreto 53/2013).

Consent for publication

Not applicable.

Availability of data and materials

The datasets used and/or analysed during the current study are available from the corresponding author on reasonable request.

Competing interests

The authors declare that they have no competing interests.

Funding

Techniques performed were supported by a grant from the Principado de Asturias, PCTI 2018–220 (GRUPIN: IDI2018-000237 and FEDER).

Authors´contributions

AB and JFGM developed the concept of the study and collected all required data; AB, LJR, EG, RB, OA and JFGM collected and processed the samples, and analyzed and interpreted the data. AB and JFGM drafted the manuscript. All authors read and approved the final manuscript.

Acknowledgments

Authors thank colleagues from SERIDA, University of León, Servicios del Principado de Asturias (SERPA), Servicio de Espacios Protegidos y Conservación de la Naturaleza, Dirección General de Biodiversidad from Viceconsejería de Medio Ambiente del Principado de Asturias and Consejería de Fomento y Medio Ambiente de la Junta de Castilla y Léon for the invaluable collaboration. We thank Dr. Kevin P. Dalton for critically reviewing the manuscript.

Author details

[1] Facultad de Veterinaria, Universidad de León, Campus de Vegazana, León, Spain. [2] Servicio Regional de Investigación y Desarrollo Agroalimentario del Principado de Asturias (SERIDA), Villaviciosa, Spain. [3] Consejería de Fomento, Ordenación del Territorio y Medio Ambiente, Oviedo, Asturias, Spain. [4] Consejería de Fomento y Medio Ambiente de la Junta de Castilla y León, Dirección General del Medio Natural, Valladolid, Spain.

Abbreviations

CAdV-1
Canine adenovirus type 1; qPCR:quantitative polymerase chain reaction.

References

1. Naves J, Wiegand T, Fernández A, Stephan T. Riesgo de extinción del oso pardo cantábrico. Oviedo: Fundación Oso de Asturias; 1999.
2. González EG, Blanco JC, Ballesteros F, Alcaraz L, Palomero G, Doadrio I. Genetic and demographic recovery of an isolated population of brown bear *Ursus arctos* L., 1758. Peer J. 2016;4:e1928. doi: 10.7717/peerj.1928
3. Mörner T, Eriksson H, Broejer C, Nilsson K, Uhlhorn H, Agren E, Ryser-Degiorgis M P, Hard af Segerstad C, Jansson DS, Gavier-Widen D. Diseases and mortality in free-ranging brown bear (*Ursus arctos*), wolf (*Canis lupus*) and wolverine (*Gulo gulo*) in Sweden. J Wildl Dis. 2005;41:298–03.
4. Balseiro A, Oleaga Á, Polledo L, Aduriz G, Atxaerandio R, Kortabarria N, García Marín JF. *Clostridium sordellii* in a brown bear (*Ursus arctos*) from Spain. J Wildl Dis. 2013;49:1047–51.
5. García Marín JF, Royo LJ, Oleaga A, Gayo E, Alarcia O, Pinto D, Martínez IZ, González P, Balsera R, Marcos JL, Balseiro A. Canine adenovirus type 1 (CAdV-1) in free-ranging European brown bear

(*Ursus arctos arctos*): A threat for Cantabrian population?. Transbound Emerg Dis. 2018;65:2049–56.

6. Barszcz K, Przespolewska H, Olbrych K, Czopowicz M, Klećkowska-Nawrot J, Goździewska-Harłajczuk K, Kupczyńska M. The morphology of the adrenal gland in the European bison (*Bison bonasus*). BMC Vet Res. 2016;12:161.
7. Balseiro A, Royo LJ, Gayo E, García Marín JF. Cholangiocarcinoma in a free-ranging Eurasian brown bear (*Ursus arctos arctos*) from Northern Spain. J Wildl Dis. 2019; doi: 10.7589/2019-03-054
8. Sommer S. The importance of immune gene variability (MHC) in evolutionary ecology and conservation. Front Zool. 2005;2:16.
9. Swenson JE, Taberlet P, Bellemain E. Genetics and conservation of European brown bears *Ursus arctos*. Mammal Rev. 2011;41:87–98.
10. Kreeger TJ, White PJ, Seal US, Tester JR. Pathological responses of red foxes to foothold traps. J Wild Manage. 1990;54:147–60.
11. Kyritsi EM, Sertedaki A, Charmandari E, Chrousos GP. Familial or Sporadic Adrenal Hypoplasia Syndromes. In: Feingold KR, Anawalt B, Boyce A, Chrousos G, Dungan K, Grossman A, Hershman JM, Kaltsas G, Koch C, Kopp P, Korbonits M, McLachlan R, Morley JE, New M, Perreault L, Purnell J, Rebar R, Singer F, Trence DL, Vinik A, Wilson DP, editors. Endotext [Internet]. South Dartmouth (MA): MDText.com
12. Palomero G, Blanco JC, Ballesteros F, García-Serrano A, Herrero J, Nores C. Record de osas con crías en el occidente cantábrico. Quercus. 2011;301:20–5.
13. Ueckermann VE. Erhebung über die Wildverluste durch den Strassenverkehr und die Verkehrsunfälle durch Wild. Z Jagdwiss. 1964;10:142–68.
14. Frković AR, Ruff L, Cicnjak L, Huber D. Brown bear mortality in Gorski kotar, Yugoslavia. Int Conf Bear Res and Manage. 1987;7:87–92.
15. Kaczensky P, Knauer F, Huber T, Jonosovic M, Adamic M. The Ljubljana-Postojna highway - a deadly barrier for brown bears in Slovenia?. J Wild Res. 1996;1:263–7.
16. Huber D, Kusak J, Frkovic A. Traffic kills of brown bears in Gorski Kotar, Croatia. Ursus. 1998;10:167–71.
17. Kusak J, Huber Đ, Frković A. The effects of traffic on large carnivore populations in Croatia. Bios Conserv. 2000;3:35–9.
18. Seiler S, Helldin JO, Seiler C. Road mortality in Swedish mammals: results of a drivers' questionnaire. Wildl Biol. 2004;10:225–33.
19. Morales M. Primer oso muerto en un atropello en España. 2008. https://elpais.com/sociedad/2008/10/28/actualidad/1225148405_850215.html. Accessed 22 December 2019.
20. Klevezal GA. Recording structures of mammals. Determination of age and reconstruction of life history. AA Balkema Publishers, Rotterdam, Netherlands; 1996.

Figures

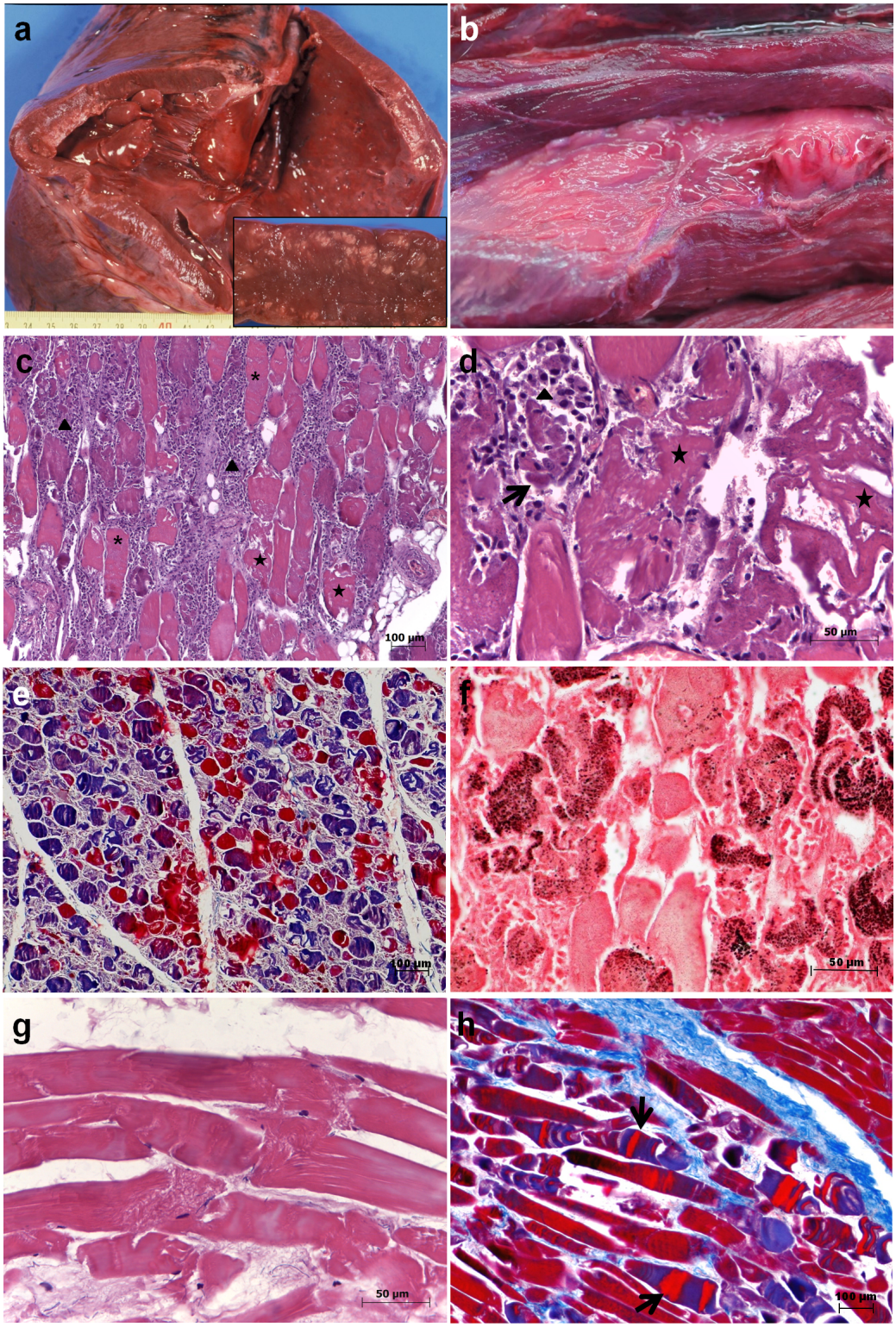

Figure 1

. Severe exertional myopathy in Eurasian brown bears is shown. Figures a, c, d, e and f correspond to bear number 1 and Figures b, g and h to bear number 9 (see Table 1 for details). a) Gross lesions consisted of dry and pale cardiac muscle are observed. Inset: detail of lesions in myocardium. b) Gross lesions

consisted of pale skeletal (femoral) muscle. c) Extensive segmental hyaline degeneration in femoral muscle is observed. Hypercontracted fibers (asterisks), coagulative necrosis and areas of myofibrillar lysis (stars), as well as intensive infiltrate mainly consisted of lymphocytes and macrophages (arrowheads) are also observed. Hematoxylin-eosin staining. d) Detail of necrotic myofibers (stars) with surviving satellite cells (arrow), invading macrophages (arrowhead) and elongating myoblasts (asterisks) indicative of events of regeneration. Hematoxylin-eosin staining. e) Necrotic and lysed myofibers are observed. Mallory Azan staining. f) Calcification (mineralization), hyalinization and necrosis of muscle fibers is shown. Von Kossa staining. g) Segmental degeneration is observed in a longitudinal section of intercostal muscle. In this case infiltrate is not present. Hematoxylin-eosin staining. h) Necrotic and hypercontracted (arrows) myofibers are observed. Mallory Azan staining.