

Validation of methods for effective orifice area measurement of prosthetic valves by two-dimensional and Doppler echocardiography following transcatheter self-expanding aortic valve implantation

Minghu Xiao

Chinese Academy of Medical Sciences & Peking Union Medical College Fuwai Hospital

Yongjian Wu

Chinese Academy of Medical Sciences & Peking Union Medical College Fuwai Hospital

Jingjin Wang

Chinese Academy of Medical Sciences & Peking Union Medical College Fuwai Hospital

Guangyuan Song

Chinese Academy of Medical Sciences & Peking Union Medical College Fuwai Hospital

Jiande Wang

Chinese Academy of Medical Sciences & Peking Union Medical College Fuwai Hospital

Zhenhui Zhu

Chinese Academy of Medical Sciences & Peking Union Medical College Fuwai Hospital

Xu Wang

Chinese Academy of Medical Sciences & Peking Union Medical College Fuwai Hospital

Zhenyan Zhao

Chinese Academy of Medical Sciences & Peking Union Medical College Fuwai Hospital

Hao Wang (✉ fuwaiwanghao@163.com)

Chinese Academy of Medical Sciences & Peking Union Medical College Fuwai Hospital <https://orcid.org/0000-0002-7925-7153>

Research

Keywords: Aortic valve stenosis, Transcatheter aortic valve replacement, Self-expanding valve, 2D Doppler echocardiography, Continuity equation

Posted Date: January 22nd, 2020

DOI: <https://doi.org/10.21203/rs.2.21550/v1>

License:   This work is licensed under a Creative Commons Attribution 4.0 International License. [Read Full License](#)

Abstract

Background: The aim was to compare two echocardiographic methods for prosthetic valve effective orifice area (EOA) measurement following transcatheter self-expanding aortic valve implantation.

Methods: EOA was calculated according to the continuity equation. Two methods were constructed. In Method #1, the left ventricular outflow tract diameter (LVOTd 1) was measured at the entry of the prosthesis (from trailing to leading edge); in Method #2, the LVOTd 2 was measured proximal to the prosthetic valve leaflets (from trailing to leading edge). VTI LVOT was recorded by pulse doppler (PW) from apical windows. The region of the PW sampling should match that of the LVOTd measurement with precise localization.

Results: A total of 113 consecutive patients were included in the study. All patients were followed up at one year. The mean transvalvular pressure gradient correlated better with the indexed EOA 1 (EOAI 1) ($r=-0.701$, $p<0.0001$) than EOAI 2 ($r=-0.645$, $p<0.0001$). Intra-observer reliability of EOA 1 and was EOA 2 was excellent (ICCs ranging from: EOA 1 : 0.923 to 0.984, and EOA 2 : 0.898 to 0.979, respectively). Interobserver reliability of EOA 1 and was EOA 2 was good (ICCs ranging from: EOA 1 : 0.742 to 0.948, and EOA 2 : 0.589 to 0.901, respectively).

Conclusions: For transcatheter self-expanding valve EOA measurement, LVOTd should be measured in the entry of the prosthesis stent (from trailing to leading edge), and VTI LVOT should be measured when the PW sample is located in the entry of the prosthesis stent.

Background

Transcatheter aortic valve implantation (TAVI) has emerged as an alternative to standard surgical aortic valve replacement (SAVR) in high-risk patients with severe aortic stenosis. Five-year results in real-world, elderly, high-risk patients undergoing TAVI with a self-expanding bio-prosthesis provided evidence for continued valve durability with low rates of reinterventions and hemodynamic valve dysfunction [1–3].

Compared with the indexed geometric orifice area, the aortic valve effective orifice area (EOA) (estimated by the continuity equation), which provides complementary information, is one of the main echocardiographic indexes utilized to characterize the hemodynamic performance of prosthetic valves and identify the presence of prosthesis–patient mismatch (PPM) [2,4]. Calculating EOA after TAVI relies on geometric measurement of the left ventricular outflow tract (LVOT) and the velocity time integral (VTI) of the LVOT in addition to Continuous wave Doppler (CW) imaging of the aortic valve (VTI_{AV}). There is little controversy regarding how to measure VTI_{AV} . However, the optimal site for placement of the sample volume to obtain VTI_{LVOT} after TAVI is less well established. Moreover, for transcatheter self-expanding valves, there is no consensus about the optimal site for LVOT measurement on transthoracic echocardiography (TTE). With regard for where to measure the LVOT diameter (LVOTd), initial studies of the self-expanding valve suggested that the LVOTd should be measured just below the hinge points of the visible prosthetic leaflets [5]. However, recent trials have used the ventricular edge of the transcatheter heart valve (THV) [1,6], in other words, in the entry of the stent. A comparison and validation of previously described methods for calculating the EOA for the self-expanding THV is lacking.

The objective of this study was to compare the methods used in previous studies to measure the EOA of the self-expanding THV following TAVI and validate an optimal method using transthoracic 2D echocardiography and Doppler assessment.

Materials And Methods

A total of 121 consecutive patients were included in this study. All patients were diagnosed with symptomatic severe aortic stenosis who underwent TAVR with Venusmedtech-VenusA valve (Figure 1) (Venusmedtech, Hangzhou, China) at Fuwai Hospital. All patients were in outpatient follow-up at our center. TTE data were collected before the procedure and 12 months after the procedure. Exclusion criteria included valve-in-valve TAVR (N=3), patients who could not complete 12 months follow-up for various reasons (N=5): 2 patients died for all causes and 3 patients could not complete follow-up at our center. Finally, in total, 113 patients were included in this study. The local institutional review board approved the study, and written informed consent was obtained from all participants.

The THV was implanted based on CT measurements of the aortic valve annulus. Venusmedtech-VenusA valves with a diameter of 23 mm, 26 mm, 29 mm and 32 mm were used for annulus sizes ranging from 17 to 20 mm, 20 to 23 mm, 23 to 26 mm and 26 to 29 mm, respectively. All clinical, echocardiographic, pre-procedural, and post-procedural data were prospectively collected.

Two-dimensional and Doppler Echocardiography

TTE was performed using a commercially available system (E9 ultrasound system, GE Healthcare, Horten, Norway). Standard two-dimensional and Doppler echocardiographic images were acquired using a phased-array transducer in the parasternal and apical views and stored digitally for offline analysis using EchoPAC software version BT 113 (GE Healthcare, Horten, Norway). Each echocardiographic measurement was averaged from three consecutive cardiac cycles for patients in sinus rhythm and from five consecutive cycles in patients with atrial fibrillation. All measurements were performed according to the recommendations of the American Society of Echocardiography [7].

Continuity Equation for aortic valve effective orifice

The EOA for THV was calculated according to the continuity equation as $(LVOTd)^2 \times 0.785 \times (VTI_{LVOT} / VTI_{THV})$ [7]. The indexed EOA (EOAI) was calculated as EOA/body surface area (BSA).

LVOTd was measured from a zoomed parasternal long-axis acquisition. Two methods were constructed (Figure 2). In Method #1, LVOTd₁ was measured at the entry of the prosthesis stent and from the trailing to the leading edge of the stent, whereas in Method #2, LVOTd₂ was measured proximal to the prosthetic valve leaflets (0.5 to 1.0 cm below the aortic valve annulus) and from the trailing to leading edge.

VTI_{THV} was mainly measured by CW from apical windows or occasionally from other acoustic windows (e.g., the right parasternal or suprasternal) to obtain the highest VTI_{THV}. VTI_{LVOT} was recorded by PW from apical windows. The region of the PW sampling should match that of the LVOTd measurement with precise localization.

Due to the LVOT's elliptical geometry, the LVOTd was measured in the 5-chamber view again (the parasternal long axis view and 5-chamber view are two planes lying perpendicular to each other). The minimal diameter and maximal diameter were defined as the shorter LVOTd and the longer LVOTd, respectively. The circularity of the basal plane was expressed as the eccentricity index ($EI = 1 - (\text{minimal diameter} / \text{maximal diameter})$) [8].

Intra-observer and interobserver measurement variability

Twenty-six patients were randomly selected, and EOA measurements were repeated in these patients by 2 independent observers. Intra-observer and interobserver variability in the measurements were calculated.

Relationships between EOAs and mean gradient (MG)

The relationships between the EOAs and the MG were evaluated to validate the measurements of EOA obtained by Method #1 and Method #2.

In low flow-state conditions, the MG may be pseudo-normalized, and the EOA may be pseudo-severized, which may alter the relationship between the EOAI and the MG [9]. Taking into account of the stroke volume (SV) could be quantitated with either pulsed-wave Doppler at the LVOT site or with a volumetric approach. In our study, for Method #1 and Method #2, the different LVOTd measurement got different SV. So, SV was measured with the volumetric approach: LV end-diastolic volume minus end-systolic volume (evaluated via the biplane Simpson method). It was indexed for BSA (SVi). Therefore, we grouped patients by SVi as follows: group 1 (N=57): SVi >35 ml/m² and group 2 (N=56): SVi <35 ml/m², and we performed a sub-analysis of the Doppler echocardiographic data.

Depth of THV placement in LVOT was also studied. The depth of delivery was defined as the distance from the native aortic annular margin on the side of the noncoronary cusp (leftward on the described projection) to—on the corresponding side—the most proximal edge (deepest in the left ventricle) of the deployed stent-frame. This was measured using 2D TTE.

Statistical analysis

Data are expressed as the mean with standard deviation or the number of patients (percentages), as appropriate. The χ^2 test was used with 2-tailed p values to compare categorical variables. The paired samples t test was used to compare variables between different methods of EOA measurement. Correlations between variables were determined using Pearson correlation methods. Relationships between EOAs and MG were assessed with multiple nonlinear regression models, and the equation providing the best fit was retained. The results for intra-observer and interobserver variability between methods of measurement were assessed using the intraclass correlation coefficient (ICC) [10] and Bland-Altman [11] methods, respectively. All statistical analysis was performed with IBM SPSS Statistics, version 20.0. software (SPSS Inc., Chicago, IL). p < 0.05 was considered statistically significant.

Results

Baseline characteristics of the 113 patients included in the study are presented in Table 1. All patients were followed up at one year (355±13 days). A total of 33 patients (29.2%) received a 23-mm valve, 50 patients (44.2%) received a 26-mm valve, and 30 patients (26.6%) received a 29-mm valve.

Table 1. Baseline clinical characteristics

Age, years	77.2±5.5
Male	72 (63.7)
Body surface area, m ²	1.73±0.19
NYHA function class	
II	25 (22.1)
III	65 (57.5)
IV	23 (20.4)
Left ventricular ejection fraction, %	53.8±12.7
Diabetes mellitus	38 (33.6)
Dyslipidaemia	75 (66.4)
Hypertension	77 (68.1)
Society of Thoracic Surgeons score, %	11.27±9.4
Cardiac history	
Coronary artery disease	53 (46.9)
Previous myocardial infarction	14 (12.4)
Prior coronary artery bypass surgery	5 (4.4)
Prior percutaneous coronary intervention	23 (20.4)
Prior atrial fibrillation/atrial flutter	11 (9.7)
Prior III° Atrioventricular block	3 (2.7)
Prior sick sinus syndrome	1 (0.9)
Pre-existing pacemaker	7 (6.2)
Prior transient ischaemic attack	38 (33.6)

Values are shown as the mean ±SD or n (%); NYHA, New York Heart Association.

The results of follow-up echocardiography assessments after TAVI are presented in Table 2. EOA₁ was significantly larger than EOA₂. LVOTd₁ was larger than LVOTd₂. The peak velocity at level 2 was significantly higher than the peak velocity at level 1. The LVOT was less elliptical in the entry of the THV stent than proximal to the prosthetic valve leaflets (Table 2).

Table 2. Follow-up Doppler echocardiographic data in the entire cohort.

Variable	Post-TAVI		<i>p</i> value
	Method #1	Method #2	
LVOTd, cm	1.84±0.21	1.64±0.18	<0.001
EOA, cm ²	1.56±0.39	1.48±0.41	0.001
EOAI, cm ² /m ²	0.93±0.23	0.88±0.24	0.001
VTI _{LVOT} , cm	23.37±5.34	27.47±5.77	<0.001
Velocity of LVOT, cm/s	118.56±26.52	140.34±24.51	<0.001
EI	0.04±0.05	0.11±0.06	0.001

Values are shown as the mean ±SD; TAVI, transcatheter aortic valve implantation; EOA, effective orifice area; EOAI, indexed EOA; LVOTd, left ventricular outflow tract diameter; VTI, velocity time integral; EI, eccentricity index.

Mean depth of THV in LVOT in the whole cohort was 11.62±3.78mm. 63(55.7%) patients had the ‘optimal’ placement of the THV (5-10mm below the native non-coronary cusp). 50(44.3%) patients ‘suboptimal’ placement (48(42.5%) patients: ≥10mm; and 2(1.8%) patients ≤5 mm).

Normal flow-state condition and low flow-state condition (Table 3)

In the subgroups, LVOTd₁, LVOTd₂, VTI_{LVOT}, VTI_{THV}, EOA₁, EOAI₁, MG and LVEDD were larger in group 1 than in group 2.

Table 3. Follow-up Doppler echocardiographic data in the subgroups

Variable	Group1 (N=57)	Group 2 (N=56)	<i>P value</i>
Age, years	76.6±5.8	77.8±5.2	0.259
Male	37(65)	35(63.5)	0.899
Body surface area, m ²	1.67±0.13	1.68±0.15	0.496
LVOTd of Pre-TAVI, mm	24.2±2.2	23.5±2.0	0.081
EOA of Pre-TAVI, cm ²	0.61±0.16	0.63±0.19	0.652
THV size, mm	26.5±1.8	25.5±2.3	0.028
LVEF, %	64.9±9.1	64.0±10.5	0.663
LVEDD, mm	50.2±6.1	47.7±6.7	0.041
SVI, ml/ m ²	43.34±7.24	27.97±4.78	≪0.001
LAD, mm	40.9±6.5	42.2±6.8	0.279
LVOTd ₁ , cm	1.94±0.19	1.69±0.19	≪0.001
LVOTd ₂ , cm	1.53±0.15	1.42±0.15	≪0.001
VTI of LVOT in level 1, cm	25.1±4.8	21.6±5.3	≪0.001
VTI of LVOT in level 2, cm	29.0±5.2	26.1±5.3	0.005
VTI of THV, cm	44.7±10.6	36.9±8.8	≪0.001
MG of THV, mmHg	9.9±4.5	8.9±4.1	0.026
EOA ₁ , cm ²	1.70±0.42	1.42±0.30	≪0.001
EOA ₂ , cm ²	1.54±0.44	1.43±0.38	0.164
EOAI ₁ , cm ² /m ²	1.01±0.23	0.85±0.20	≪0.001
EOAI ₂ , cm ² /m ²	0.92±0.24	0.85±0.23	0.138
IVS, mm	11.33±1.95	11.78±2.03	0.241
LVPW, mm	11.02±1.92	11.30±1.83	0.442
Depth of THV in LVOT, mm	11.70±3.72	11.49±3.92	0.786
EI ₁	0.05±0.05	0.04±0.04	0.953
EI ₂	0.11±0.06	0.11±0.06	0.295

Values are shown as the mean ±SD or n (%); THV, transcatheter heart valve; LVEF, left ventricular ejection fraction; LVEDD, left ventricular end-diastolic diameter; IVS, interventricular septum; LVPW, left ventricular post wall; MG, mean gradient; Other abbreviations as Tables 2.

Intra-observer and interobserver variability

Intra-observer and interobserver agreement in EOA measurements derived using Method #1 and Method #2 are expressed by intraclass correlation and summarized in Table 4.

A Bland-Altman plot comparing the values of EOA₁ versus EOA₂ is shown in Figure 3. Compared with EOA₂, EOA₁ had lower interobserver and intra-observer variability.

Table 4. Interobserver and Intra-observer variability

Variable	Intraclass correlation	95% CI
Intra-observer agreement		
Method #1	0.965	0.923-0.984
Method #2	0.953	0.898-0.979
Inter-observer agreement		
Method #1	0.884	0.742-0.948
Method #2	0.792	0.589-0.901

CI, confidence intervals.

Relationships between EOAI_s and MG (Table 5)

In the whole cohort, MG correlated better with EOAI₁ than with EOAI₂ (Figure 4A and 4B). In group 1, which includes the data obtained from patients with SVi>35 ml/m², MG correlated better with EOAI₁ than with EOAI₂ (Figure 4C and 4D). In group 2 (SVi<35 ml/m²), MG correlated better with EOAI₁ than with EOAI₂ (Figure 4E and 4F).

Table 5. Relationships between EOAI_s and MG

	Whole cohort	p value	Group 1	p value	Group 2	p value
EOAI ₁ - MG	0.645	<0.001	0.701	<0.001	0.696	<0.001
EOAI ₂ - MG	0.602	<0.001	0.645	<0.001	0.515	<0.001

Discussion

To the best of our knowledge, this study is the first to validate the methods used for calculating the EOA of the self-expanding THV by 2D and Doppler echocardiography. Our results confirm that Method #1 was better than Method #2; in other words, it is preferable to measure LVOTd in the entry of the stent and from the trailing to leading edge, while the optimal site for placement of the sample volume to obtain VTI_{LVOT} was in the entry of the stent.

As a functional determination of prosthesis size, in vivo EOA can vary widely, depending on a number of factors related to the measurement technique used and the patient state. Variability can be introduced during the measurement of LVOTd or VTI_{LVOT} [12,13]. The characteristics of a self-expanding THV [14] include remodelling and outward expansion of the self-expanding valve with the nitinol frame [6]. Follow-up data obtained using TTE at 12 months after TAVI were selected to reduce the influence of the time factor.

For a self-expanding valve, there is no consensus regarding the optimal site for measuring LVOTd on TTE. In the 2009 American Society of Echocardiography guidelines for echocardiographic assessment of prosthetic valve function, it is recommended that LVOTd should be measured just beneath the prosthesis sewing ring [15]. However, this method can serve as a general rule for all types of prosthetic aortic valves. In the 2019 American Society of Echocardiography guidelines for the evaluation of valvular regurgitation after percutaneous valve replacement, it is recommended that LVOTd should be measured using different method in different situations: 1. when a self-expanding valve is placed low in the LV, particularly if the lower end of the stent is not in close proximity to the anterior mitral leaflet and interventricular septum, LVOTd is to measure the inner edge-to-inner edge diameter of the valve stent immediately proximal to the cusps; 2. when a self-expanding valve is placed just beneath the aortic annulus, and the lower end of the stent is close proximity to the anterior mitral leaflet and interventricular septum, it is recommended that LVOTd should be measured using the outer edge-to-outer edge diameter at the lower (ventricular) end of the valve stent for a self-expanding valve [16]. In Jilaihawi's study [5], depth of implantation was on average 10.5 ± 3.4 mm, which was similar with our data. In our study, for most patients (111, 98%), the depth of THV placement in LVOT were more than 5mm and the lower end of the stent is not in close proximity to the anterior mitral leaflet and interventricular septum. Hence, in our study, LVOTd was measured from the trailing to leading edge (inner edge-to-inner edge diameter of the valve stent).

For transcatheter balloon expandable valves, Marie-Annick Clavel et al. recommended measuring LVOTd immediately proximal to the stent [17]. Compared Marie-Annick Clavel's Method #2 with our Method #1, the first difference is that a self-expanding valve was employed; and the second difference is that in Marie-Annick Clavel's Method #2 LVOTd was measured outside the stent and from outer-to-outer. For balloon expandable valves, the depth of THV placement in LVOT was less than the self-expanding valve, and the lower end of the stent is close proximity to the anterior mitral leaflet and interventricular septum. Previous studies of the self-expanding valve suggested that LVOTd should be taken just below the hinge points of the visible prosthetic leaflets, measuring the inner-to-inner stent [5], which was similar to our Method #2.

In our study, two methods were constructed: Method #1: LVOTd and VTI_{LVOT} were measured in the entry of the prosthesis stent, and Method #2: LVOTd and VTI_{LVOT} were measured proximal to the visible prosthetic leaflets. For

the methods in which we calculated the LVOTd of the self-expanding THV using the outer edge to outer edge diameter, the confused borders of the stent may have contributed to the variance observed in the measurement of LVOTd, which represents an external dimension of the prosthesis and not its internal orifice. Especially for patients with poor image quality. Therefore, we did not validate the methods used to calculate the LVOTd using the outer-to-outer edge. The correlation between EOA and MG has been previously reported to be highly predictive of adverse outcomes [12]. Our study shows that MG correlated better with EOA_1 than EOA_2 in the whole cohort and in the both subgroups (with $SVI > 35 \text{ ml/m}^2$ and $SVI < 35 \text{ ml/m}^2$). Intra-observer and interobserver variability were lower for Method#1 than Method# 2. These results suggest that Method #1 provides a more accurate and reliable estimate of EOA for transcatheter self-expanding valves. Possible reasons for the higher variability observed when using Method #2 include the following: first, it was difficult to precisely identify the base of the prosthetic cusps due to acoustic shadowing created by the prosthesis stent and the calcification of the native aortic valve and annulus. Second, the shape of the LVOT is more elliptical at this level. Third, there is significant flow acceleration within the stent proximal to the prosthetic leaflets.

In view of the special structure of transcatheter self-expanding valves, they have a longer left-ventricular stent. Although the THV is designed for circular deployment, the THV device landing zone often has a non-circular shape, and the LVOT's geometry is more circular at the entry of the prosthesis stent than at the level proximal to the prosthetic valve leaflets [18]. In our study, the EI of the LVOT was smaller in the entry of the prosthesis stent than at the level proximal to the prosthetic valve leaflets. The more elliptical shape of the LVOT may result in significant underestimations of true cross-sectional areas. Second, there was significant flow acceleration at the level within the stent that was proximal to the prosthetic leaflets (left ventricular side) [19]. In our study, the peak velocity of the LVOT when calculated proximal to the leaflets was significantly higher than the velocity measured in the entry of the stent, resulting in an overestimated EOA. The flow acceleration proximal to the leaflets is mostly related to the elliptical shape of the LVOT and the turbulent flow at this level [20]. In both Marie-Annick Clavel's method #2 and our Method #1, the flow acceleration within the stent proximal to the prosthetic leaflets was avoided. However, in some studies, flow acceleration is ignored, resulting in a larger EOA ($1.7 \pm 0.5 \text{ cm}^2$; e.g., in Jilaihawi's study [5]). When we compared our Method #1 and Method #2, although VTI_{LVOT} was higher when using Method #2 (because of the flow acceleration proximal to the cusps), the geometry of the LVOT was more elliptical at this level, resulting in a smaller EOA_2 .

Limitations

The most obvious limitation of our study was the absence of an accepted gold standard for EOA measurement. Because a transcatheter self-expanding valve was employed in this study, the results of this study may not be applicable to transcatheter balloon expandable valves. With regard for the eccentricity index, the LVOTd was measured in a 5-chamber view or parasternal long axis view, and the minimal diameter and maximal diameter may therefore not be accurate. No 3D imaging was used. Our study was a single-centre study that included a relatively small number of patients. Further studies that include a larger number of patients and longer follow-up are needed to establish the normal reference values of the valve hemodynamic parameters of transcatheter valves and determine whether their hemodynamic performance is maintained in the long term.

Conclusions

For transcatheter self-expanding valves, measuring LVOTd at the entry and from the trailing to leading edge of the stent is likely more appropriate than other methods for the estimation of EOA by transthoracic Doppler echocardiography. Moreover, the pulsed-wave Doppler sample should be located in the entry of the stent and on the same horizontal line used to measure the LVOTd.

Abbreviations

TAVI: Transcatheter aortic valve implantation; EOA: effective orifice area; EOAI: indexed valve effective orifice area; LVOTd: diameter of left ventricular outflow tract; VTI: velocity time integral

MG: mean transvalvular pressure gradient.

Declarations

Ethics approval and consent to participate

The local institutional review board approved the study, and written informed consent was obtained from all participants.

Consent for publication

We have the necessary consent from the patients who has individual personal images and data in the publication.

Availability of data and materials

The data, analytic methods, and study materials will be made available to other researchers for purposes of reproducing the results or replicating the procedure, upon request.

Competing interests

There was no grant or any financial support from the industry. There was no conflict of interest for each author.

Funding

None.

Author's contributions:

Hao Wang, Yongjian Wu, Jingjin Wang and Minghu Xiao were involved in the design of the study and interpretation of data and were major contributors in writing the manuscript. Minghu Xiao, Guangyuan Song and Jingjin Wang were involved in the analysis and interpretation of data and in writing the manuscript. Guangyuan Song, Zhenyan Zhao, Zhenhui Zhu, Jiande Wang and Xu Wang were involved interpretation of data and in writing the manuscript. Yongjian Wu and Hao Wang were involved in critically revising the manuscript. All authors read and approved the final manuscript.

Authors details

¹Department of Echocardiography, Fuwai Hospital, National Center for Cardiovascular Diseases, Chinese Academy of Medical Sciences and Peking Union Medical College, Beijing, China

²Department of Cardiology, Fuwai Hospital, National Center for Cardiovascular Diseases, Chinese Academy of Medical Sciences and Peking Union Medical College, Beijing, China

³Department of Surgery, Fuwai Hospital, National Center for Cardiovascular Diseases, Chinese Academy of Medical Sciences and Peking Union Medical College, Beijing, China

Acknowledgement

The authors thank Xin Yuan for revising the manuscript for language and statistical analysis.

References

1. Marco Barbanti, Anna Sonia Petronio, Davide Capodanno, Federica Ettori, Antonio Colombo, Francesco Bedogni, Federico De Marco, Marco De Carlo, Claudia Fiorina, Azeem Latib, Luca Testa, Giuseppe Bruschi, Arnaldo Poli, Cristina Giannini, Salvatore Curello, Diego Maffeo, Carmelo Sgroi, Paola Martina, Simona Gulino, Martina Patanè, Yohei Ohno, Guilherme F. Attizzani, Sebastiano Immè, Stefano Cannata, Alessandra Gentili, Agnese Rossi, Corrado Tamburino. Transcatheter aortic-valve replacement with a self-expanding prosthesis. *N Engl J Med*. 2014;370(19): 1790–1798.
2. Ulrich Gerckens, Corrado Tamburino, Sabine Bleiziffer, Johan Bosmans, Peter Wenaweser, Stephen Brecker, Jia Guo, Axel Linke. Final 5-year clinical and echocardiographic results for treatment of severe aortic stenosis with a self-expanding bioprosthesis from the ADVANCE Study. *Eur Heart J*. 2017;38(36): 2729-2738.
3. Dayimi Kaya, Zulkif Tanriverdi, Huseyin Dursun, Tugce Colluoglu. Echocardiographic outcomes of self-expanding CoreValve versus balloon-expandable Edwards SAPIEN XT valves: the comparison of two bioprosthesis implanted in a single centre. *Int J Cardiovasc Imaging*. 2016; 32(9): 1371–1378.
4. Pibarot P, Dumesnil JG. Prosthetic heart valves: selection of the optimal prosthesis and long-term management. *Circulation*. 2009;119(7): 1034–1048.
5. Hasan Jilaihawi, Derek Chin, Tomasz Spyt, Mohamed Jeilan, Mariuca Vasa-Nicotera, Johan Bence, Elaine Logtens, Jan Kovac. Prosthesis-patient mismatch after Transcatheter aortic valve implantation with the Medtronic-Corevalve bioprosthesis. *Eur Heart J*. 2010;31(7): 857–864.
6. Jae K. Oh, Stephen H. Little, Sahar S. Abdelmoneim, Michael J. Reardon, Neal S. Kleiman, Grace Lin, David Bach, Linda Gillam, Biswajit Kar, Joseph Coselli, Partho P. Sengupta, Kanny Grewal, James Chang, Yanping Chang, Mike Boulware, David H. Adams, Jeffrey J. Popma. Regression of Paravalvular Aortic Regurgitation and Remodeling of Self-Expanding Transcatheter Aortic Valve. *JACC Cardiovasc Imaging*. 2015; 8(12): 1364-1375.
7. Helmut Baumgartner, Judy Hung, Javier Bermejo, John B. Chambers, Arturo Evangelista, Brian P. Griffin, Bernard Lung, Catherine M. Otto, Patricia A. Pellikka, Miguel Quiñones. Echocardiographic assessment of valve stenosis: EAE/ASE recommendations for clinical practice. *J Am Soc Echocardiogr*. 2009; 22(5): 1–23.
8. Sanjay Doddamani, Ricardo Bello, Mark A. Friedman, Anita Banerjee, James H. Bowers Jr, Bette Kim, Prashant R. Vennalaganti, Robert J. Ostfeld, Garet M. Gordon, Divya Malhotra, Daniel M. Spevack.

- Demonstration of left ventricular outflow tract eccentricity by real time 3D echocardiography: implications for the determination of aortic valve area. *Echocardiography*. 2007;24(8): 860-866.
9. Florent Le Ven, Mélanie Freeman, John Webb, Marie-Annick Clavel, Miriam Wheeler, Éric Dumont, Chris Thompson, Robert De Larochellière, Robert Moss, Daniel Doyle, Henrique B. Ribeiro, Marina Urena, Luis Nombela-Franco, Josep Rodés-Cabau, Philippe Pibarot. Impact of Low Flow on the Outcome of High-Risk Patients Undergoing Transcatheter Aortic Valve Replacement. *J Am Coll Cardiol*. 2013;62(9): 782-788.
 10. Fleiss JI. Reliability of measurement. In: *The design and Analysis of Clinical Experiments*. New York: John Wiley & Sons. 1986; 1-32.
 11. Bland JM, Altman DG. Statistical methods for assessing agreement between two methods of clinical measurement. *Lancet*. 1986; 1: 307-310.
 12. Gillinov AM, Blackstone EH, Rodriguez LL. Prosthesis patient size: measurement and clinical implications. *J Thorac Cardiovasc Surg*. 2003;126(2): 313-316.
 13. Luigi Badano, Roberto Mocchegiani, Daniele Bertoli, Giuseppe DeGaetano, Lorenzo Carratino, Laura Pasetti, Michelangelo Caudullo, Antonietta Budini, Bruno Mannello, Giancarlo Passerone. Normal echocardiographic characteristics of the Sorin Bicarbon bileaflet prosthetic heart valve in the mitral and aortic positions. *J Am Soc Echocardiogr*. 1997;10(6): 632-643.
 14. Kumar R, Latib A, Colombo A, Carlos E. Ruiz. Self-Expanding Prostheses for Transcatheter Aortic Valve Replacement. *Prog Cardiovasc Dis*. 2014;56(6): 596-609.
 15. William A. Zoghbi, John B. Chambers, Jean G. Dumesnil, Elyse Foster, John S. Gottdiener, Paul A. Grayburn, Bijoy K. Khandheria, Robert A. Levine, Gerald Ross Marx, Fletcher A. Miller Jr., Satoshi Nakatani, Miguel A. Quiñones, Harry Rakowski, L. Leonardo Rodriguez, Madhav Swaminathan, Alan D. Waggoner, Neil J. Weissman, Miguel Zabalgaitia. Recommendations for evaluation of prosthetic valves with echocardiography and doppler ultrasound: a report from the American Society of Echocardiography's Guidelines and Standards Committee and the Task Force on Prosthetic Valves. *J Am Soc Echocardiogr*. 2009;22(9): 975–1014.
 16. William A. Zoghbi, Federico M. Asch, Charles Bruce, Linda D. Gillam, Paul A. Grayburn, Rebecca T. Hahn, Ignacio Inglessis, Ashequl M. Islam, Stamatios Lerakis, Stephen H. Little, Robert J. Siegel, Nikolaos Skubas, Timothy C. Slesnick, William J. Stewart, Paaladinesh Thavendiranathan, Neil J. Weissman, Satoshi Yasukochi, Karen G. Zimmerman. Guidelines for the Evaluation of Valvular Regurgitation After Percutaneous Valve Repair or Replacement: A Report from the American Society of Echocardiography Developed in Collaboration with the Society for Cardiovascular Angiography and Interventions, Japanese Society of Echocardiography, and Society for Cardiovascular Magnetic Resonance. *J Am Soc Echocardiogr*. 2019;32(4): 431-475.
 17. Marie-Annick Clavel, Josep Rodés-Cabau, Éric Dumont, Rodrigo Bagur, Sébastien Bergeron, Robert De Larochellière, Daniel Doyle, Éric Larose, MSc Jean G. Dumesnil, Philippe Pibarot. Validation and Characterization of Transcatheter Aortic Valve Effective Orifice Area Measured by Doppler Echocardiography. *JACC Cardiovasc Imaging*. 2011;4(10):1053-1062.
 18. Arnold C.T. Ng, Victoria Delgado, Frank van der Kley, Miriam Shanks, Nico R.L. van de Veire, Matteo Bertini, Gaetano Nucifora, Rutger J. van Bommel, Laurens F. Tops, Arend de Weger, Giuseppe Tavilla, Albert de Roos,

Lucia J. Kroft, Dominic Y. Leung, Joanne Schuijf, Martin J. Schalij, Jeroen J. Bax. Comparison of Aortic Root Dimensions and Geometries Before and After Transcatheter Aortic Valve Implantation by 2- and 3-Dimensional Transesophageal Echocardiography and Multislice Computed Tomography. *Circ Cardiovasc Imaging*. 2010;3(1): 94-102.

19. Sofia Shames, Agnes Koczo, Rebecca Hahn, Zhezhen Jin, Michael H. Picard, Linda D. Gillam. Flow Characteristics of the SAPIEN Aortic Valve: The Importance of Recognizing In-Stent Flow Acceleration for the Echocardiographic Assessment of Valve Function. *J Am Soc Echocardiogr*. 2012;25(6): 603-609.
20. Eric Sirois, Wenbin Mao, Kewei Li, Joseph Calderan, Wei Sun. Simulated Transcatheter Aortic Valve Flow: Implications of Elliptical Deployment and Under-Expansion at the Aortic Annulus. *Artif Organs*. 2018;42(7): 141–152.

Figures



Figure 1

The VenusA Transcatheter Artery Valve produced by VenusMedtech is a self-expanding valve device that has been approved by the China Food and Drug Administration (registration No:20173460680) and officially listed in China.

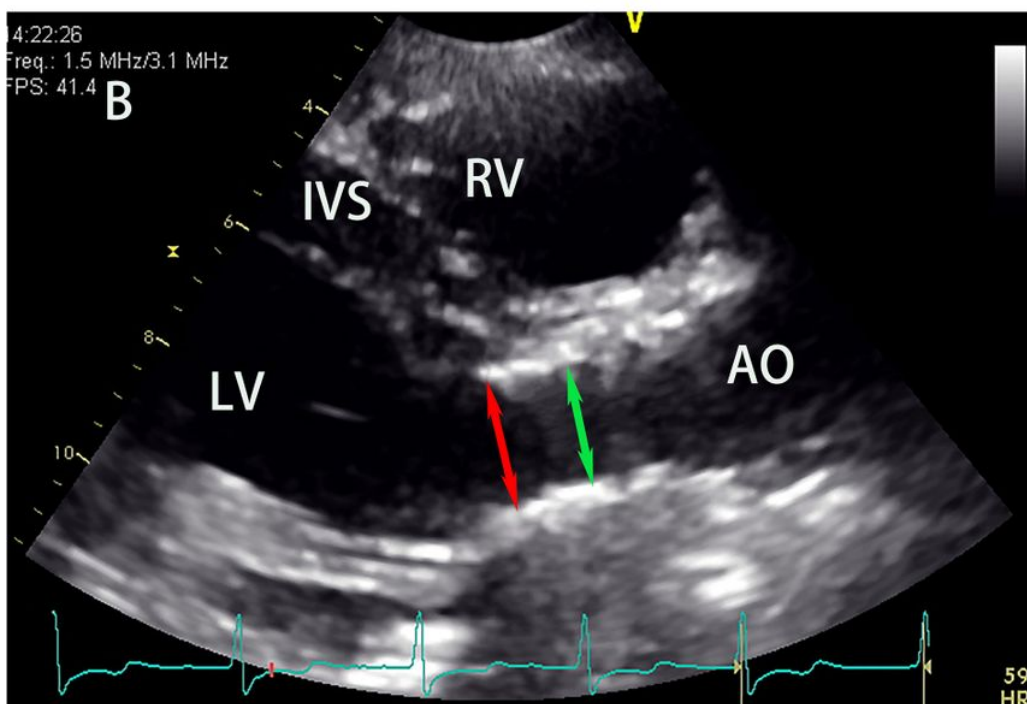
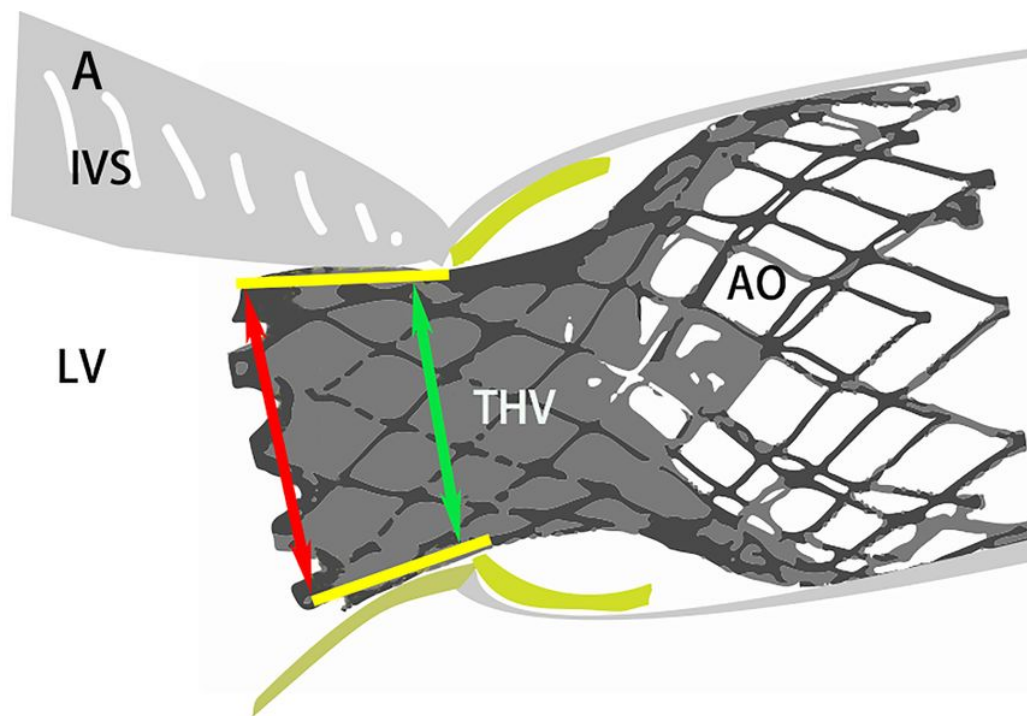


Figure 2

Measurement of left ventricular outflow tract diameter (LVOT). Zoomed LVOT in parasternal long-axis view. (A) Schematic drawing of LVOT diameter measurements obtained using Method# 1 and Method #2. (B) LVOT diameter measurement by 2D echocardiography. In Method #1, LVOT was measured at the entry of the prosthesis stent from the trailing to leading edge of the stent (inner to inner edge, red arrow). In Method #2, measurements were obtained proximal to the prosthetic valve leaflets (0.5 to 1.0 cm below the aortic valve annulus) from the trailing to leading edge (inner to inner edge, green arrow). LV, left ventricle; RV, right ventricle; AO, ascending aorta; THV, transcatheter heart valve; IVS, interventricular septum.

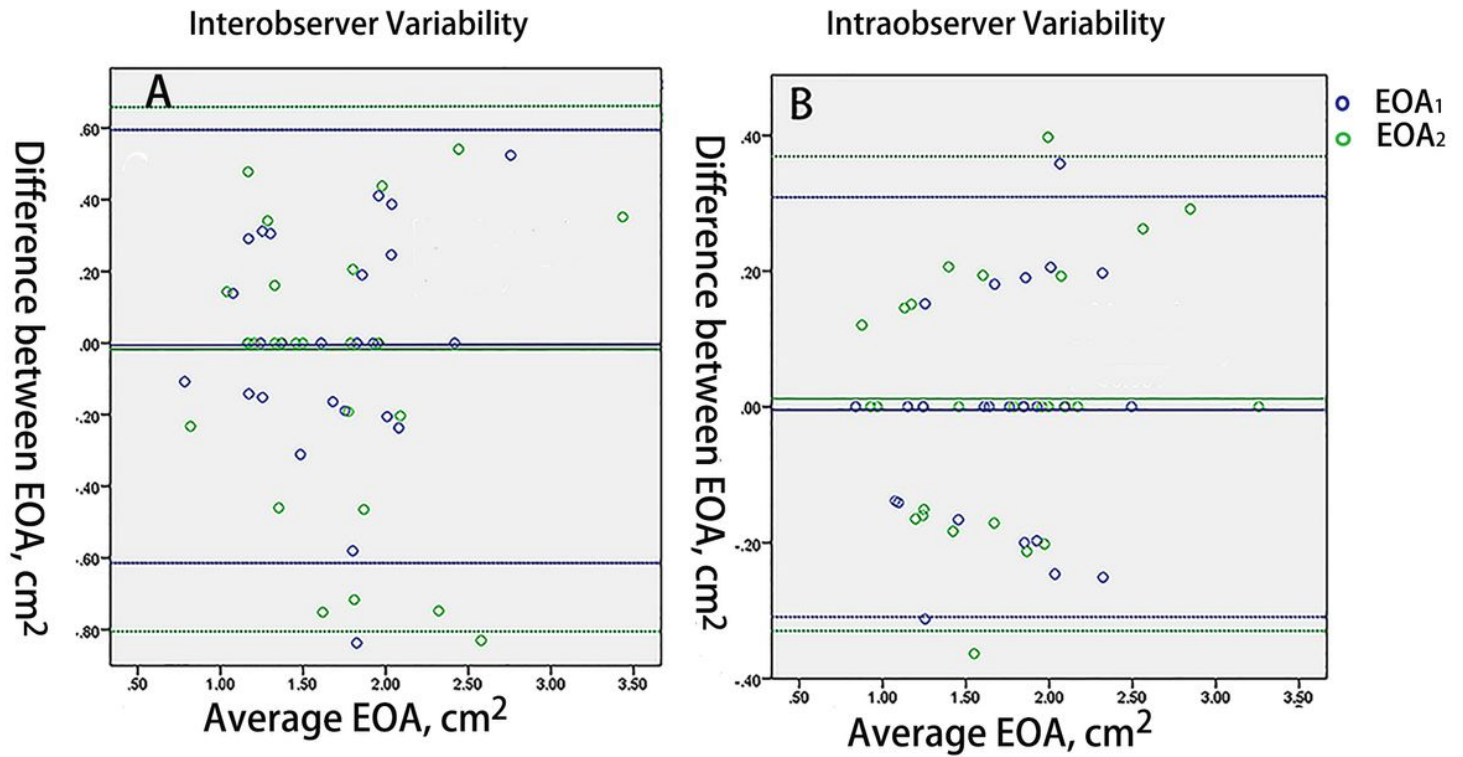
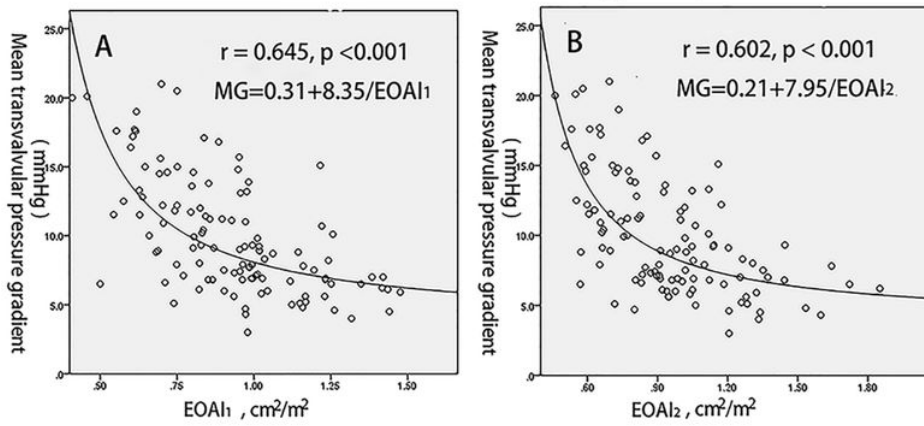


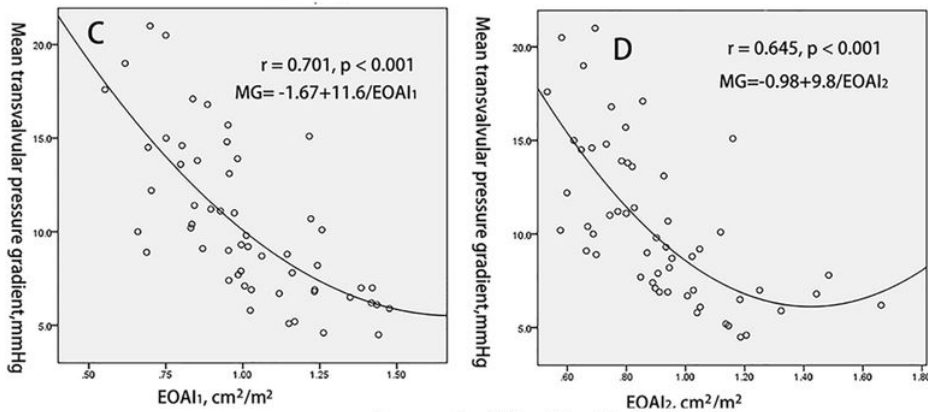
Figure 3

This figure shows a Bland-Altman plot comparing the interobserver and intra-observer variability in measurements obtained in the prosthetic self-expanding valve effective orifice area (EOA) when using different methods. Method #1 versus Method #2: interobserver (A) and intra-observer (B) variability; EOA1 (blue dots); EOA2 (green dots).

in the whole cohort, (N = 113)



Group 1: $SV_i > 35\text{ml/m}^2$, (N=57)



Group 2: $SV_i < 35\text{ml/m}^2$, (N=56)

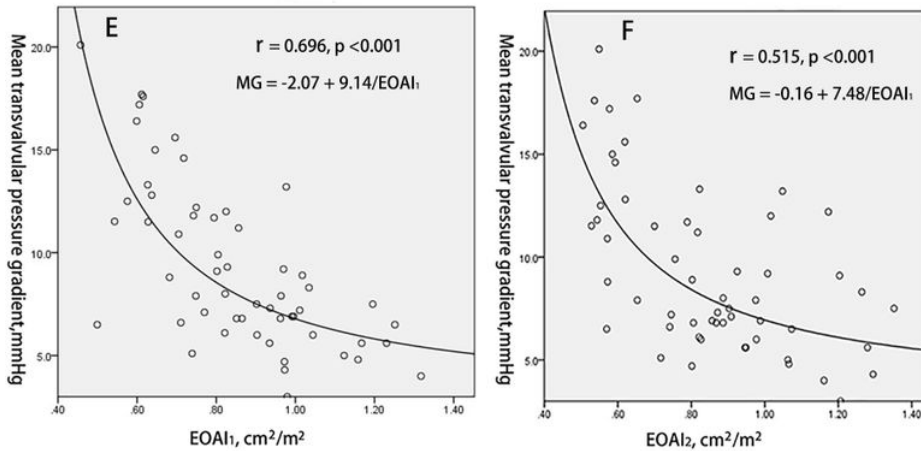


Figure 4

This figure shows the correlation between the mean transvalvular pressure gradient (MG) and the indexed effective orifice area (EOAI). A: EOA1 and MG in the Whole Cohort; B: EOA2 and MG in the Whole Cohort; C: EOA1 and MG in Group 1; D: EOA2 and MG in Group 1; E: EOA1 and MG in Group 2; F: EOA2 and MG in Group 2.