

Fractional CO₂ laser combined with 595-nm PDL inhibiting hypertrophic scars via measuring BMP-7 and Fas expression in rabbit models

Jinxia Zhang

Chinese PLA General Hospital <https://orcid.org/0000-0002-8528-9602>

Shuanglin Zhou

Chinese PLA General Hospital

Zhikuan Xia

Chinese PLA General Hospital

Zhuoying Peng

Chinese PLA General Hospital

Rongya Yang (✉ 7023858@qq.com)

Chinese PLA General Hospital

Nano Express

Keywords: hypertrophic scar, fractional CO₂ laser, 595-nm pulsed dye laser, BMP-7, Fas

Posted Date: December 10th, 2020

DOI: <https://doi.org/10.21203/rs.3.rs-120537/v1>

License: © ⓘ This work is licensed under a Creative Commons Attribution 4.0 International License. [Read Full License](#)

Abstract

Background and Objectives

Although the treatment of hypertrophic scar (HS) remain challenging, fractional CO₂ laser (FCO₂L) and 595-nm pulsed-dye laser (PDL) have proved clinical efficacy. Meanwhile, BMP-7 and Fas proteins are demonstrated to promote wound healing and inhibit scar formation, yet few reports on the effect of the two proteins on hypertrophic scarring are available, and their molecular mechanisms remain unclear. In current study, we attempted to observe the effect of combined use of FCO₂L with 595-nm PDL in HS animal models through determining the expression of BMP-7 and Fas in scar inhibition.

Materials and Methods

Twenty New Zealand white rabbits were randomized to control group, FCO₂L group, PDL group and combined treatment group. Four HS samples were developed at each ear of individual rabbit. FCO₂L was respectively applied to simple FCO₂L and combined treatment group, and simple 595-nm PDL and combined treatment group. Totally, 3 sessions of treatments were carried out once every 14 days. Then, the changes of fibroblasts and collagens in HSs and expression of BMP-7 and Fas proteins in the scar tissues were determined via histological and immunohistochemical studies, ELISA, CCK8 test, RT-PCR and Western blot assay.

Results

HSs were flattened and shrunk after treatment, especially in rabbits treated by FCO₂L plus 595-nm PDL group, in which obviously decreased abnormal fibroblast and collagen were noted. The deference was significant compared to other groups($P < 0.001$). Moreover, expression of BMP-7 and Fas was both increased in the combined treatment group compared to single FCO₂L or 595-nm PDL therapy group ($P < 0.001$).

Conclusions

FCO₂L combined with 595-nm PDL can improve HSs in rabbit models by inhibiting excessive fibroblast growth and collagen deposition. This may be associated with increased BMP-7 and Fas expression in the scar tissues. And our findings may pioneer a new therapeutic strategy for alternative treatment of HSs.

Introduction

Hypertrophic scar (HS) represents a frequent complication in abnormal wound healing, and remains intractable in its treatment[1–3], because abnormal and excessive fibroblast growth and collagen deposition play critical roles in the process of HS formation[3–6]. HSs are characterized by signs of hard and red nodules, and symptoms of pain and itch, and treatment of them primarily rely on corticosteroid injection, laser therapy and surgery[4–8]. Fractional CO₂ laser(FCO₂L) and 595-nm pulsed dye laser (PDL) are selective phototherapeutics, and have been validated to be effective in therapy of HS[9–14], yet their underlying mechanisms remain unclear, and need validation through measurement of bone morphogenetic protein-7(BMP-7) and Fas gene, the two important proteins that affect the prognosis of this condition on molecular study basis.

BMP-7, a TGF- β superfamily, has been shown to effectively inhibit the fibrosis process through regulating cell proliferation, differentiation and apoptosis in various organs and tissues in series of studies[15–25]. Jin Y[22] found that BMP-7 can undermine TGF- β 1 signaling pathway and reduce myocardial fibrosis to protect the heart, and more reports described that BMP-7 was involved in the development of hypertrophic scars after wound healing and capable of inhibiting the transformation of rat hair mastoid cells (DPCs) into fibroblasts[16, 17, 20, 21, 24, 25]. Still, further studies revealed that BMP-7 can produce inhibitory effects on excessive scar formation by activating BMP-7/Smad1/5/8 signaling pathway in fibroblasts to interfere with the cellular functions and reduce cell proliferation in HSs via inhibiting the BMP-7 related signaling pathway[19, 24, 25].

Fas and Fas ligand (FasL) are critical factors of Fas-associated death domain (FADD) activated via special death receptor in cell surfaces and amino acid sequences[26–28]. Along with C-terminal death domain, Fas/FasL can irritate TCR apoptosis and activation-induced cell death (AICD)[28]. As a member of nerve growth factor superfamily, the expression of Fas can be triggered to cause death of T cells[26–28]. Furthermore, Fas has proved to attenuate the process of hyper fibroblasts in HSs, for which a number of therapeutic strategies focused on boosting the expression of Fas against highly-expressed fibroblasts in scar formation have been attempted on molecule basis [29–34].

Both FCO₂L and 595-nm PDL have been validated to be conventional treatment options for HSs with clinical safety and efficacy[9–14]. FCO₂L for HS is based on fractional and micro-holes with almost identical density and depth, and suppresses abnormal and irregular fibrosis and collagen, thus reducing scar formation at the HSs[40–46]. This is evidenced by flattened and shrunk scars following treatment[14, 43–46]. PDL to treat hypertrophic scars is on the principle basis of selective photothermolysis[9–12, 38, 39] instead of skin resurfacing like carbon dioxide laser, since improvement of HS is to reduce the proliferation and excessive microvasculature. In addition, 595-nm PDL can create deeper penetration than 585-nm PDL, and destroy extra hemoglobin and blood vessels at the HS and other skin conditions[35–38]. The effectiveness of 595-nm PDL for HSs has been evaluated and documented in some studies[9–12, 35–39].

Currently, HS still remains a medical problem because of its complex physiologic wound healing cascade, though combined therapeutic strategies have been attempted in its treatment[11, 13, 37, 39, 41]. Nevertheless, the role of BMP-7 and Fas expression following by FCO₂L combined with 595-nm PDL is rarely available. In this study, we attempted to investigate the mechanisms of the two proteins in attenuating the scar formation and promoting the wound healing in rabbit models.

Materials And Methods

Animals

This study was approved by the Seventh Medical Center of PLA General Hospital(scl2019-056) in compliance with the guidelines of the animal center. Twenty New Zealand white rabbits (Xishan Animal Experiment Center, Beijing, China)(2.03 ± 0.37)kg were randomly divided into four groups ($n = 5$ for each group), namely: control group, FCO₂L group, PDL group and combined treatment group (FCO₂L plus PDL). Four 1 × 1 cm surgical wounds were made on the ventral side of each ear after injecting pelltobarbitalum Natricum (5%, 1 ml/kg)(Xiya Reagent Co., Ltd, Shandong, China), with the skin removed, auricular cartilage preserved and hemostasis. Totally, 160 hypertrophic scars were created, and observed once a week.

Medicine and instruments

Upon the wounds developing into HS at day 28, FCO₂L(Ultrapulse, Lumenis Ltd., Yokneam, Israel) was applied to the rabbits in FCO₂L and combined treatment group, and 595-nm PDL(Vbeam2, Syneron & Candela., Boston, USA) was used to treat the animals in PDL and combined treatment group. Parameters were set according to previous studies[42–44] and the instructions for users supplied by the manufacturer. FCO₂L: (Combo mode; square matrix: 6 mm; Deep:12.5 mJ, 15%; Superficial: 90 mJ,40%); 595-nm PDL: (Fluence:15J/cm², square matrix: 7 mm, Pulse duration:10 ms). Treatment was repeated twice on each HS. Totally, three rounds of treatments were administered once every 14 days.

Histological study

HS samples were obtained at day 70, and stained and measured with HE and Van Gieson(VG) for observation of the cellular proteins and collagen fibers in tissues. Scar samples were initially fixed and embedded in conventional protocol, and then sectioned into 5 µm in thickness. Staining was made in the middle of each section. The features of HS were examined, and hypertrophic index was measured ($HI = A / B$ (A = vertical thickness from the highest point of HS to the surface of cartilage; B = vertical thickness from the normal skin to the surface of cartilage). Apart from that, NA (numerical densities of fibroblasts on area) and AA (area density of collagen fibers on area) were calculated to determine the density of collagen fibers in scar tissues.

Immunohistochemical study

Immunohistochemical study was performed to observe the expression of BMP-7 and Fas. The sections were dewaxed, rehydrated, graded and distilled, and then activated by endogenous peroxidase to trigger antigen repair. Moreover, streptavidin-peroxidase enzyme(CST, Mass., USA)and Mayer's hematoxylin (MHS32, Sigma, USA) were used to dye and re-stain the sections. Software Image-Pro plus for windows(version 6.0, Media Cybernetics, Inc. USA) was used to analyze the results.

ELISA study

ELISA was conducted to measure Type I(SEA571Rb,Wuhan,China) and type III(SED087Rb,Wuhan, China) collagens. The scar samples were coated on the plastic porous plate and washed out, then the antibodies were added to bond the specific antigens. The enzyme and substrates were colored by adding primary and secondary antibodies. Results were automatically estimated using enzyme-labeled instrument.

CCK8 test

Cell counting kit-8(CCK8) was employed to investigate the viability of fibroblasts and the content of Col-I and III in the samples. Fibroblasts from HSs were inoculated in 96-well plates(2×10^4 cells/ml) by cell suspension (100 ul/well)for 24 h.CCK8(HY-K0301,MCE,USA) was dissolved and added into each well at 0, 24, 48, 72 and 96 h, respectively. Then, ELISA was performed to observe the absorbance value of Col-I and II at 450 nm.

Real time-PCR

TRIzol™ Reagent(Invitrogen™, Hudson estuary, USA) was used to isolate RNA from the HSs, and transcribed to cDNA by PrimeScript™ Double Strand cDNA Synthesis Kit(Takara, Shiga, Japan). And Real-Time PCR System®(Applied Biosystems, Life Technologies) was performed at 95 °C for 5 min, 60°C and 72°C for 30 s, and 40 cycles in 4°C for 20 min. The Primer Information(5'to3') of this two proteins was:BMP-7(F:ACCTCCAGGGCAAGCACAACCT, R:CGTCAGTGAGGAAGCGGCTATCT),Fas(F:TGAACCATCACCGACTTCCTCCTA,R:GCCACTCTTGGACACCAGCAT). Gel UV analyzer (Applied Biosystems, Life Technologies) was used to photograph according to the manufacturer's protocols, The formula of $2^{-(\Delta\Delta Ct)}$ was used to analyze relative gene expression in the samples.

Western blot assay

Western blot assay was carried out to examine the expression of BMP-7 and Fas. The sections were initially digested, lysed and transmitted to a polyvinylidene difluoride membrane, and immunoblotted in buffer overnight. Primary and secondary antibodies were applied to incubate the reactive protein. Mouse monoclonal anti-BMP-7(ab99359,abcam,UK), anti-Fas(ab56032, abcam,UK) antibodies and control protein (ACTIN, CST,Mass., USA) were used to measure BMP-7 expression, and the results were analyzed using Image J software.

Statistical analyses

The results were analyzed by SPSS 19.0 software(SPSS Inc., Chicago, IL). Means(M) \pm standard deviation(SD) was used to express the databases and A value of *, $P < 0.05$, **, $P < 0.01$ or ***, $P < 0.001$ were accepted as statistical significance.

Results

FCO₂L combined with 595-nm PDL reduced HSs

The HSs became flattened and shrunk in rabbits treated by combined FCO₂L with 595-nm PDL compared to the therapy with simple FCO₂L or 595-nm PDL(Fig. 1).The scar thickness was lower in combined treatment group(0.61 ± 0.05) than in other groups(1.10 ± 0.08 ; 1.19 ± 0.10) (Fig. 2a)(*** $P < 0.001$). Fibroblasts were more regular, and collagen fibers were less in the treatment groups, especially in the combined treatment group(Fig. 1). Furthermore, HI, AA and NA were all reduced most in rabbits treated by FCO₂L plus 595-nm PDL (1.49 ± 0.19 ; 29.14 ± 2.40 ; 3.49 ± 0.09) compared to animals undergone simple FCO₂L(2.36 ± 0.12 ; 41.93 ± 2.30 ; 4.26 ± 0.11) or 595-nm PDL group(2.59 ± 0.19 ; 46.57 ± 2.38 ; 4.54 ± 0.13)(Fig. 2b-d), with significant difference among groups(*** $P < 0.001$).

ELISA study exhibited decreased contents of type I collage and the ratio of Col-I and III (F + P: 0.30 ± 0.05 ; 0.92 ± 0.22), (FCO₂L: 0.66 ± 0.08 ; 3.37 ± 0.58), (PDL: 0.56 ± 0.08 ; 4.07 ± 0.37) (Fig. 3b,c) (*** $P < 0.001$). CCK-8 results indicated that the viability of fibroblasts cells were suppressed, and the A450 value was depressed more in the combined treatment group(0.45 ± 0.34) compared to that in FCO₂L and 595-nm PDL groups(0.65 ± 0.05 ; 0.72 ± 0.06) (Fig. 3a,4a) (*** $P < 0.001$).

Combined use of FCO₂L with 595-nm PDL boosted BMP-7 and Fas expression

Expression of both BMP-7 and Fas was up-regulated as indicated by immunohistochemistry, Western blot assay and RT-PCR detection (Fig. 4a,b,5a-f). Relevant analysis showed that BMP-7 level was significantly increased in the combination treatment group(36.96 ± 1.16 ; 0.52 ± 0.06 ; 1.83 ± 0.67) compared to simple FCO₂L(30.84 ± 1.15 ; 0.36 ± 0.28 ; 1.50 ± 0.09) or 595-nm PDL treatment(30.06 ± 0.79 ; 0.29 ± 0.04 ; 1.35 ± 0.12) (Fig. 5a,c,e). The difference was significant among the findings verified by immunohistochemistry Western blot assay and RT-PCR ($***P < 0.001$).

The Fas expression was noted in combined treatment group(Fig. 4a,b), in which the IOD data and the relevant expression of Fas were also increased(35.60 ± 1.47 ; 0.51 ± 0.03 ; 1.76 ± 0.08) compared to simple FCO₂L treatment(31.29 ± 1.05 ; 0.32 ± 0.60 ; 1.41 ± 0.08) or 595-nm PDL(28.92 ± 0.89 ; 0.30 ± 0.02 ; 1.29 ± 0.10)(Fig. 5b,d,f) ($***P < 0.001$).

Figure 5**(a)** The IOD data of BMP-7 were increased most in the combined treatment group after treatment($***P < 0.001$ vs. Control; FCO₂L vs. F+P, $***P < 0.001$; PDL vs. F+P, $***P < 0.001$). **(b)** The IOD data of Fas showed the same trend($***P < 0.001$ vs. Control; FCO₂L vs. F+P, $***P < 0.001$; PDL vs. F+P, $***P < 0.001$). **(c)** The relevant expression of BMP-7(WB) was the highest in the combined treatment group($***P < 0.001$ vs. Control; FCO₂L vs. F+P, $***P < 0.001$; PDL vs. F+P, $***P < 0.001$). **(d)** Obviously up-regulated relevant expression of Fas (WB) in the combined treatment group($***P < 0.001$ vs. Control; FCO₂L vs. F+P, $***P < 0.001$; PDL vs. F+P, $***P < 0.001$). **(e)** Evidently increased relevant expression of BMP-7(RT-PCR) in the combined treatment group($***P < 0.001$ vs. Control; FCO₂L vs. F+P, $***P < 0.001$; PDL vs. F+P, $***P < 0.001$). **(f)** Relevant expression of Fas(RT-PCR) was the highest in the combined group($***P < 0.001$ vs. Control; FCO₂L vs. F+P, $***P < 0.001$; PDL vs. F+P, $***P < 0.001$).

Discussion

Hypertrophic scar commonly results from abnormal wound healing with a complex pathologic process, and poor understanding of its etiology and pathology makes it difficult to completely remove the scars and achieve better prognosis of this condition[1–3]. Development and reoccurrence of HS are associated with irregular and disorder fibroblasts and overproduction of collagens in the skin, which potentially trigger certain clinical symptoms and manifestations, including high and red nodules, pain and itch at the lesion[3, 4]. Untreated HSs can also bring about some physiological and psychological disturbance from cosmetic disfigurement and even economic burden for the victims[2]. Clinically, lasers of diverse parameters are recognized as effective and safe treatment options for HSs, especially fractional CO₂ laser and 595-nm PDL[5–14]. The primary mechanisms of the two laser systems may be involved in some inter-cell factors and pathways in skin resurfacing, such as BMP-7 and Fas expression[29–33, 45, 46]. Nonetheless, few evidences on how the two proteins work in HS remodeling following combined use of FCO₂L with 595-nmPDL, for which we attempted to observe and verify the mechanisms in rabbit models.

In our study, flattened, shrunk and softened HSs were seen in the animals models after 3 sessions of therapy, and the improvement was better at the lesions treated by FCO₂L plus 595-nm PDL than simple use either of the laser modality. Still, irregular and disordered fibroblasts and collagens were suppressed after treatment,

especially in rabbits in the combined treatment group via verification by ELISA, CCK8 test, HE and VG staining. Further immunohistochemical study, Western blot analysis and RT-PCR indicated evidently up-regulated expression of BMP-7 and Fas at the HSs after combined treatment. These findings demonstrate that combined use of FCO2L with 595-nm PDL can generate expression of BMP-7 and Fas proteins in HS tissues.

BMP7 is a member of TGF β superfamily and has been verified to reduce fibrosis in various tissues[16–25,47–49]. Previous clinical observations indicated that BMP-7 can suppress fibrosis in renal and myocardial through reducing epithelial-mesenchymal transition and counteracting TGF- β 1 signaling pathway[21,22]. Moreover, BMP-7 participates in the process of wound healing, inhibits dermal papilla cells, thus limiting the initiation of proliferative fibroblasts in hypertrophic scars[15,16,24,25]. Guo J and Lin Q[25] had created HSs in mouse models to investigate the inhibitory effects of BMP7 on scar formation, and found that BMP-7 promoted wound healing, induced fibroblast apoptosis and inhibited scar formation by suppressing collagen deposition and expression of fibrotic proteins in scar tissues. The inhibitory effects of BMP-7 may be attributed to activated BMP-7/Smad1/5/8 signaling pathway, which is consistent with another observation[24]. By the findings aforementioned, we hypothesized that the efficacy in our protocol that combined use of FCO2L with 595-nm PDL has achieved should be the result of boosted BMP7 expression.

We also found that FCO2L plus 595-nm PDL profile could result in increase of Fas expression in hypertrophic scar samples. This gene is of important role in the process of cell apoptosis by Fas-associated death domain (FADD) and activation-induced cell death (AICD)[26–28], and significantly elevated in fibroblasts during HS formation and wound repair through apoptotic signal-way transaction and reducing redundant fibrosis[29–31], on which basis many clinical and pre-clinical measures have been developed to target the treatment of HSs[29–34, 50]. Le X and Wu WW[50] investigated the expression of Fas ligand and FADD in HS models, and found that FADD can check cell proliferation and promotes apoptosis of hypertrophic scar fibroblasts by enhancing FasL expression. Additional clinical study also confirmed imbalance of proliferation and apoptosis of cells in HS tissues due to the sensitivity of Fas expression, and concluded that Fas sensitivity enhancement should be a promising therapeutic target in HSs[34]. Besides, Li XY[32] and Liu YB[33] reported that TSG-6 and tunicamycin could trigger Fas/FasL signaling pathway and activate the apoptosis of fibroblasts in hypertrophic scars, which is consistent with our findings.

Fractional CO2 laser and 595-nm PDL in treating hypertrophic scars build on the principle of selective photothermolysis, and their efficacies have been clinically proved[9–14, 35–46]. In current study, we attempted combined use of the two laser modalities in rabbit models, with BMP-7 and Fas expression detected in the HS tissues. FCO2L, with 10600 nm wavelength, is an effective and safe technique in HSs through identical density and depth micro-holes, leading to reforming and reordering of abnormal collagen fibrils[40–46, 51–54]. The efficacies of FCO2L were also confirmed by Makboul[45] as well as other observations[14, 51–54]. Additionally, FCO2L was also found to inhibit HSs by enhancing the expression of BMP-7 and Fas, which is similar to our results.

PDL, another laser modality with selective photothermolysis, has been clinically used for decades, and can effectively inhibit microvasculature in HSs [3, 9]. Previous studies revealed that PDL can reduce abnormal mast cells, fibroblasts and keratinocytes in HSs [10–12], and particularly could produce better effects by 585-nm wavelength for post-surgery scars, and promote vascularity and pliability of skins at the HSs[9, 12, 35–39].

Nevertheless, simple use of either FCO₂L or PDL failed to achieve satisfactory prognosis in treating HSs, and there remains necessary to expand evidence and develop optimal therapeutic options, for which combined use of FCO₂L and 595-nm PDL was attempted in early-stage of HSs, and the results showed that the clinical scores (VAS, VSS and POSAS) as well as disordered collagens and fibers were significantly improved after treatment[11, 13, 37, 39, 41, 55–57]. This may be involved in the role of 595-nm PDL that is capable of promoting BMP-7 and Fas expression, which is confirmed in our study.

Limitations and prospects

Current study was performed merely in rabbit models, and need further investigation on diverse animal models. In addition, verification of long-lasting benefits and scar recurrences is necessary in clinical settings because of the hard follow-up in animal models.

Conclusions

Combined use of FCO₂L with 595-nm PDL can inhibit HSs in rabbit models, which may be associated with boosted BMP-7 and Fas protein expression through regulating the signaling pathway of the two proteins that are responsible for scar formation. Our findings may lay a foundation for an emerging option in the treatment of HS in clinic.

Declarations

Conflict of Interest

The authors declare that they have no competing interests in this study.

Acknowledgements

We would like to thank Shuanglin Zhou MD., Zhikuan Xia MD. and Zhuoying Peng for the study conception and technical assistance in acquisition of the data and photo preparation.

References

- [1] Zhang J, Li Y, Bai X, et al. Recent advances in hypertrophic scar[J]. *Histol Histopathol.* (2018)33:27-39
- [2] Finnerty CC, Jeschke MG, Branski LK, et al. Hypertrophic scarring: the greatest unmet challenge after burn injury [J].*Lancet*,2016,388(10052):1427-1436.
- [3] Brian Berman, Andrea Maderal, Brian Raphael. Keloids and Hypertrophic Scars: Pathophysiology, Classification, and Treatment[J]. *Dermatol Surg*, 43 Suppl 1, S3-S18 Jan 2017.
- [4] Zhu Z, Ding J, Tredget EE. The molecular basis of hypertrophic scars[J]. *Burns Trauma.* 2016;4:2. Published 2016 Jan 21.

- [5] Kuehlmann B, Stern-Buchbinder Z, Wan DC, et al. Beneath the Surface: A Review of Laser Remodeling of Hypertrophic Scars and Burns[J]. *Adv Wound Care (New Rochelle)*. 2019;8(4):168–176.
- [6] Toro DD, Dedhia R, Tollefson TT. Advances in scar management: prevention and management of hypertrophic scars and keloids[J]. *Curr Opin Otolaryngol Head Neck Surg*, 2016, 24(4):324-332.
- [7] Artzi O, Friedman O, Al-Niaimi F, et al. Mitigation of Postsurgical Scars Using Lasers: A Review[J]. *Plast Reconstr Surg Glob Open*. 2020;8(4):e2746. Published 2020 Apr 24.
- [8] Seago M, Shumaker PR, Spring LK, et al. Laser Treatment of Traumatic Scars and Contractures: 2020 International Consensus Recommendations[J]. *Lasers Surg Med*. 2020;52(2):96-116.
- [9] Pongcharoen P, Pongcharoen B, Disphanurat W. The effectiveness of a 595 nm pulsed-dye-laser in the treatment of surgical scars following a knee arthroplasty[J]. *J Cosmet Laser Ther*. 2019;21(6):352-356.
- [10] Lin L, Guo P, Wang X, et al. Effective treatment for hypertrophic scar with dual-wave-length PDL and Nd:YAG in Chinese patients[J]. *J Cosmet Laser Ther*. 2019;21(4):228-233.
- [11] Safra T, Shehadeh W, Koren A, et al. Early intervention with pulse dye and CO2 ablative fractional lasers to improve cutaneous scarring post-lumpectomy: a randomized controlled trial on the impact of intervention on final cosmesis[J]. *Lasers Med Sci*. 2019;34(9):1881-1887.
- [12] Forbat E, Al-Niaimi F. Nonvascular uses of pulsed dye laser in clinical dermatology [published online ahead of print, 2019 Apr 19]. *J Cosmet Dermatol*. 2019;10.1111/jocd.12924.
- [13] Radmanesh M, Mehramiri S, Radmanesh R. Fractional CO2 laser is as effective as pulsed dye laser for the treatment of hypertrophic scars [published online ahead of print, 2019 Nov 25]. *J Dermatolog Treat*. 2019;1-4.
- [14] Patel SP, Nguyen HV, Mannschreck D, et al. Fractional CO2 Laser Treatment Outcomes for Pediatric Hypertrophic Burn Scars[J]. *J Burn Care Res*. 2019;40(4):386-391.
- [15] Bramlage C P , G.A. Müller. Bone Morphogenetic Protein7 (BMP7)[J]. *Der Nephrologe*, 2010, 5(6):528-530.
- [16] Weiskirchen R, Meurer SK, Gressner OA, Herrmann J, Borkham-Kamphorst E, Gressner AM. BMP-7 as antagonist of organ fibrosis. *Front Biosci* 2009; 14: 4992–5012.
- [17] Xiong F, Hausdorf J, Niethammer TR, Jansson VA, Klar RM. Temporal TGF- β 1 Supergene Family Signalling Cues Modulating Tissue Morphogenesis: Chondrogenesis within a Muscle Tissue Model? *Int J Mol Sci*. 2020 Jul 9;21(14):4863. doi: 10.3390/ijms21144863. PMID: 32660137; PMCID: PMC7402331.
- [18] Limandjaja GC, van den Broek LJ, Breetveld M, et al. Characterization of In Vitro Reconstructed Human Normotrophic, Hypertrophic, and Keloid Scar Models. *Tissue Eng Part C Methods*. 2018;24(4):242–253.
- [19] Guo J, Lin Q, Shao Y, Rong L, Zhang D (2017) miR-29b promotes skin wound healing and reduces excessive scar formation by inhibition of the TGF-beta1/Smad/CTGF signaling pathway. *Can J Physiol Pharmacol* 95(4):437–442.

- [20] Salazar VS, Gamer LW, Rosen V. BMP signalling in skeletal development, disease and repair. *Nat Rev Endocrinol*. 2016 Apr;12(4):203-21. doi: 10.1038/nrendo.2016.12. Epub 2016 Feb 19. PMID: 26893264.
- [21] Liu L, Wang Y, Yan R, Liang L, Zhou X, Liu H, Zhang X, Mao Y, Peng W, Xiao Y, Zhang F, Liu L, Shi M, Guo B. BMP-7 inhibits renal fibrosis in diabetic nephropathy via miR-21 downregulation. *Life Sci*. 2019 Dec 1;238:116957. doi: 10.1016/j.lfs.2019.116957. Epub 2019 Oct 23. PMID: 31655195.
- [22] Jin Y, Cheng X, Lu J, Li X. Exogenous BMP-7 Facilitates the Recovery of Cardiac Function after Acute Myocardial Infarction through Counteracting TGF- β 1 Signaling Pathway. *Tohoku J Exp Med*. 2018 Jan;244(1):1-6. doi: 10.1620/tjem.244.1. PMID: 29279455.
- [23] Zeisberg M, Hanai J, Sugimoto H, Mammoto T, Charytan D, Strutz F, Kalluri R. BMP-7 counteracts TGF-beta1-induced epithelial-to-mesenchymal transition and reverses chronic renal injury. *Nat Med*. 2003 Jul;9(7):964-8. doi: 10.1038/nm888. PMID: 12808448.
- [24] Bin S, Li HD, Xu YB, Qi SH, Li TZ, Liu XS, Tang JM, Xie JL. BMP-7 attenuates TGF- β 1-induced fibroblast-like differentiation of rat dermal papilla cells. *Wound Repair Regen*. 2013 Mar-Apr;21(2):275-81. doi: 10.1111/wrr.12015. Epub 2013 Feb 25. PMID: 23437931.
- [25] Guo J, Lin Q, Shao Y, Rong L, Zhang D. BMP-7 suppresses excessive scar formation by activating the BMP-7/Smad1/5/8 signaling pathway. *Mol Med Rep*. 2017 Aug;16(2):1957-1963. doi: 10.3892/mmr.2017.6779. Epub 2017 Jun 14. PMID: 28627680; PMCID: PMC5561965.
- [26] Wang M, Su P. The role of the Fas/FasL signaling pathway in environmental toxicant-induced testicular cell apoptosis: An update. *Syst Biol Reprod Med*. 2018 Apr;64(2):93-102. doi: 10.1080/19396368.2017.1422046. Epub 2018 Jan 4. PMID: 29299971.
- [27] Meroni SB, Galardo MN, Rindone G, Gorga A, Riera MF, Cigorraga SB. Molecular Mechanisms and Signaling Pathways Involved in Sertoli Cell Proliferation. *Front Endocrinol (Lausanne)*. 2019 Apr 16;10:224. doi: 10.3389/fendo.2019.00224. PMID: 31040821; PMCID: PMC6476933.
- [28] Yoshino O, Matsuno H, Nakamura H, Yudoh K, Abe Y, Sawai T, Uzuki M, Yonehara S, Kimura T. The role of Fas-mediated apoptosis after traumatic spinal cord injury. *Spine (Phila Pa 1976)*. 2004 Jul 1;29(13):1394-404. doi: 10.1097/01.brs.0000129894.34550.48. PMID: 15223929.
- [29] Fan XL, Zhou H, Xia ZM, Niu HX, Luo JJ. [Effects of Huoxue Zhitong decoction on transmembrane protein I and II induced apoptosis of signal transmission of the epidural scar tissue]. *Zhongguo Gu Shang*. 2011 Feb;24(2):154-7. Chinese. PMID: 21442802.
- [30] Lee SH, Shin MS, Kim HS, Park WS, Kim SY, Jang JJ, Rhim KJ, Jang J, Lee HK, Park JY, Oh RR, Han SY, Lee JH, Lee JY, Yoo NJ. Somatic mutations of Fas (Apo-1/CD95) gene in cutaneous squamous cell carcinoma arising from a burn scar. *J Invest Dermatol*. 2000 Jan;114(1):122-6. doi: 10.1046/j.1523-1747.2000.00819.x. PMID: 10620127.
- [31] Lu F, Gao j, Li X. [The distribution of cell cycle on fibroblasts derived from the pathological scars and analysis of Fas gene mutations in keloids using polymerase chain Reaction-based single-strand conformation

polymorphism]. *Zhonghua Yi Xue Za Zhi*. 2000 Sep;80(9):709-12. Chinese. PMID: 11798842.

[32] Li XY, Li T, Li XJ, Wang JN, Chen Z. TSG-6 Induces Apoptosis of Human Hypertrophic Scar Fibroblasts via Activation of the Fas/FasL Signalling Pathway. *Folia Biol (Praha)*. 2018;64(5-6):173-181. PMID: 30938674.

[33] Liu YB, Gao JH, Liu XJ, Lu F, Liu HW. [The effect of tunicamycin on Fas protein expression and its function in fibroblasts from hypertrophic scar and keloid]. *Zhonghua Zheng Xing Wai Ke Za Zhi*. 2009 May;25(3):213-6. Chinese. PMID: 19803206.

[34] Lu F, Gao J, Ogawa R, Hyakusoku H, Ou C. Fas-mediated apoptotic signal transduction in keloid and hypertrophic scar. *Plast Reconstr Surg*. 2007 May;119(6):1714-21. doi: 10.1097/01.prs.0000258851.47193.06. PMID: 17440345.

[35] Anderson RR, Parrish JA. Microvasculature can be selectively damaged using dye lasers: a basic theory and experimental evidence in human skin[J]. *Lasers Surg Med*. 1981;1(3):263-276.

[36] Liu A, Moy RL, Ross EV, et al. Pulsed dye laser and pulsed dye laser-mediated photodynamic therapy in the treatment of dermatologic disorders[J]. *Dermatol Surg*. 2012;38(3):351-366.

[37] Liu XJ, Ouyang HW, Lei Y, et al. Moist exposed burn therapy in recovery of patients with immature, red hypertrophic scars successfully treated with a pulsed dye laser in combination with a fractional CO2 laser[J]. *J Cosmet Dermatol*. 2020;19(6):1353-1358.

[38] Nouri K, Rivas MP, Stevens M, et al. Comparison of the effectiveness of the pulsed dye laser 585 nm versus 595 nm in the treatment of new surgical scars[J]. *Lasers Med Sci*. 2009;24(5):801-810.

[39] Lei Y, Ouyang HW, Tan J. [Effect of Pulsed Dye Laser in Combination With Ultra-Pulsed Fractional Carbon Dioxide Laser in Treating Pediatric Burn Scars at Early Stage]. *Zhonghua Shao Shang Za Zhi*. 2020;36(5):357-362. 595

[40] Lee SJ, Suh DH, Lee JM, et al. Dermal remodeling of burn scar by fractional CO2 laser[J]. *Aesthet Plast Surg* 2016;40:761–8.

[41] Zuccaro J, Muser I, Singh M, et al. Laser Therapy for Pediatric Burn Scars: Focusing on a Combined Treatment Approach[J]. *J Burn Care Res*. 2018;39(3):457–462.

[42] Waibel JS, Wulkan AJ, Rudnick A, Daoud A. Treatment of Hypertrophic Scars Using Laser-Assisted Corticosteroid Versus Laser-Assisted 5-Fluorouracil Delivery. *Dermatol Surg*. 2019;45(3):423-430.

[43] Lee SJ, Suh DH, Lee JM, Song KY, et al. Dermal remodeling of burn scar by fractional CO2 laser. *Aesthet Plast Surg* 2016;40:761–8.

[44] Poetschke J, Dornseifer U, Clementoni MT, et al. Ultrapulsed fractional ablative carbon dioxide laser treatment of hypertrophic burn scars: evaluation of an in-patient controlled, standardized treatment approach. *Lasers Med Sci*. 2017;32(5):1031-1040.

- [45] Makboul M, Makboul R, Abdelhafez AH, Hassan SS, Youssif SM. Evaluation of the effect of fractional CO₂ laser on histopathological picture and TGF- β 1 expression in hypertrophic scar[J]. *J Cosmet Dermatol*. 2014;13(3):169-179.
- [46] Mignon C, Rodriguez AH, Palero JA, et al. Fractional laser photothermolysis using Bessel beams[J]. *Biomed Opt Express*. 2016;7(12):4974–4981.
- [47] Xiao Y, Jiang X, Peng C, Zhang Y, Xiao Y, Liang D, Shi M, Wang Y, Zhang F, Guo B. BMP-7/Smads-induced inhibitor of differentiation 2 (Id2) upregulation and Id2/Twist interaction was involved in attenuating diabetic renal tubulointerstitial fibrosis. *Int J Biochem Cell Biol*. 2019 Nov;116:105613. doi: 10.1016/j.biocel.2019.105613. Epub 2019 Sep 17. Erratum in: *Int J Biochem Cell Biol*. 2019 Oct 17;:105623. PMID: 31539631.
- [48] Rendl M, Polak L, Fuchs E. BMP signaling in dermal papilla cells is required for their hair follicle-inductive properties. *Genes Dev* 2008; 22: 543–57.
- [49] Salazar VS, Gamer LW, Rosen V. BMP signalling in skeletal development, disease and repair. *Nat Rev Endocrinol*. 2016 Apr;12(4):203-21. doi: 10.1038/nrendo.2016.12. Epub 2016 Feb 19. PMID: 26893264.
- [50] Le X, Wu WW. The therapeutic effect of Interleukin-18 on hypertrophic scar through inducing Fas ligand expression. *Burns*. 2020 Jul 15:S0305-4179(20)30467-8. doi: 10.1016/j.burns.2020.07.008. Epub ahead of print. PMID: 32782165.
- [51] Azzam OA, Bassiouny DA, El-Hawary MS, et al. Treatment of hypertrophic scars and keloids by fractional carbon dioxide laser: a clinical, histological, and immunohistochemical study[J]. *Lasers Med Sci*. 2016;31(1):9-18.
- [52] Poetschke J, Dornseifer U, Clementoni MT, et al. Ultrapulsed fractional ablative carbon dioxide laser treatment of hypertrophic burn scars: evaluation of an in-patient controlled, standardized treatment approach[J]. *Lasers Med Sci*. 2017;32(5):1031-1040.
- [53] Levi B, Ibrahim A, Mathews K, et al. The Use of CO₂ Fractional Photothermolysis for the Treatment of Burn Scars[J]. *J BurnCare Res*. 2016;37(2):106-114.
- [54] Rodriguez-Menocal L, Davis SS, Becerra S, et al. Assessment of Ablative Fractional CO₂ Laser and Er:YAG Laser to Treat Hypertrophic Scars in a Red Duroc Pig Model[J]. *J Burn Care Res*. 2018;39(6):954-962.
- [55] Biondo G, Greco S, Mavilia L, Mercuri SR. Treatment of nodular facial angiofibromas in tuberous sclerosis, using ultrapulse carbon dioxide laser. *Clin Exp Dermatol*. 2014 Aug;39(6):738-40. doi: 10.1111/ced.12327. Epub 2014 May 30. PMID: 24890518.
- [56] Ouyang HW, Li GF, Lei Y, et al. Comparison of the effectiveness of pulsed dye laser vs pulsed dye laser combined with ultrapulse fractional CO₂ laser in the treatment of immature red hypertrophic scars[J]. *J Cosmet Dermatol*. 2018;17(1):54-60.

Figures

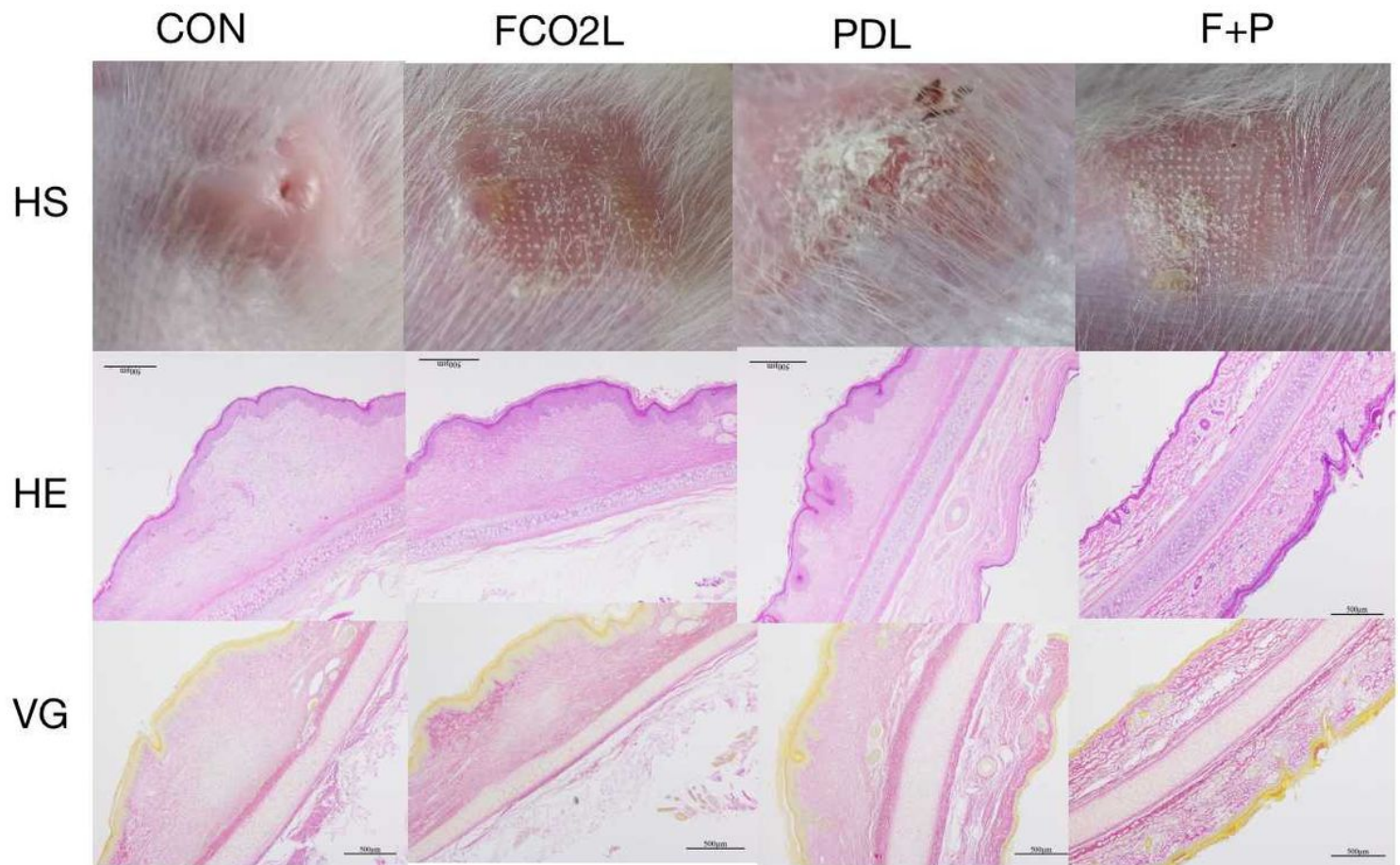


Figure 1

After treatment, flattened and shrunk HSs were seen in rabbits' ear at day 70. Fibroblasts were more regular and collagen fibers were less in the treatment groups, especially in the combined(F+P) treatment group(HE (HE_{x40}) and VG(VG_{x40}) staining).

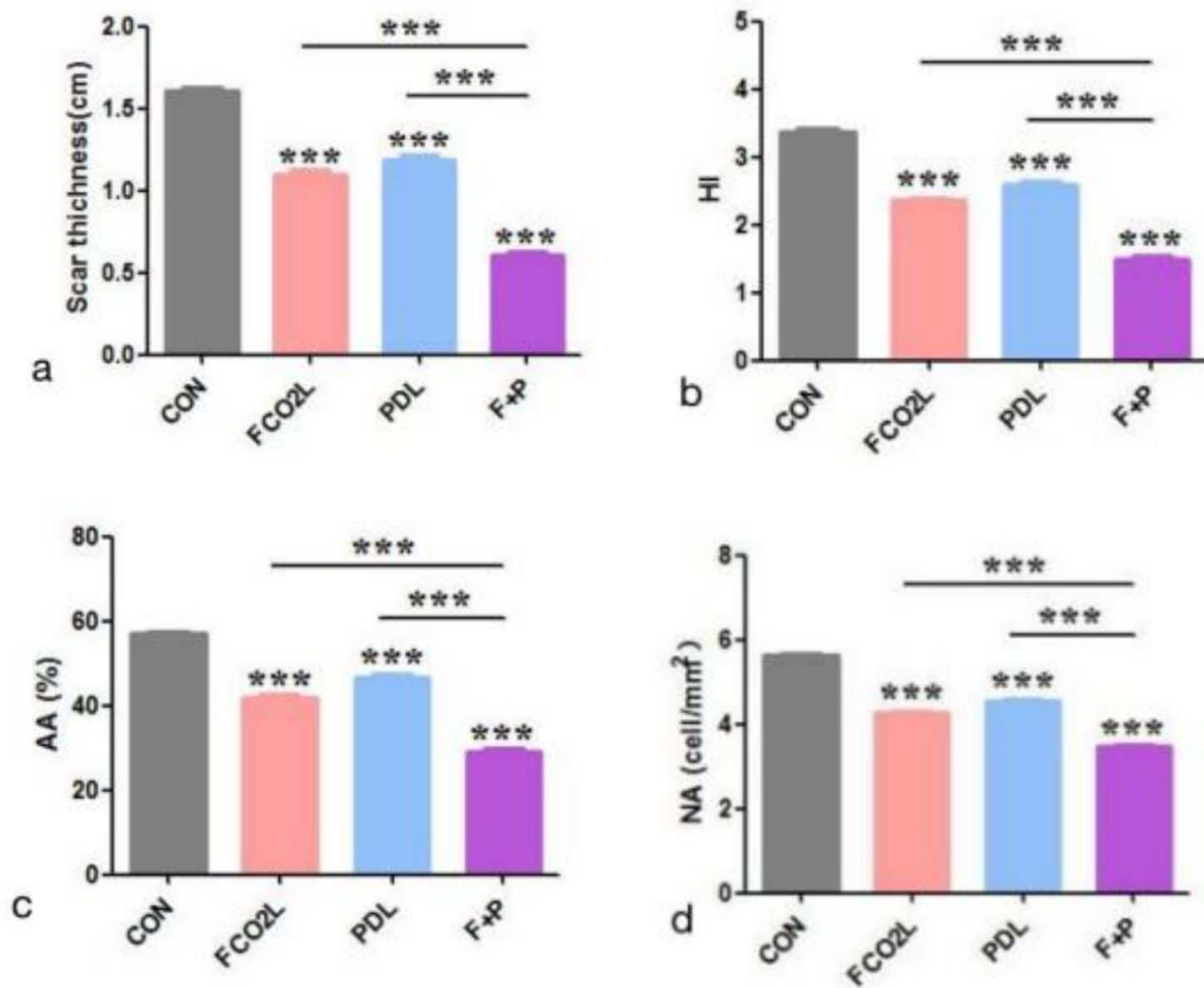


Figure 2

(a) Greatly reduced scar thickness was observed in the combined treatment group following therapy (** $P < 0.001$ vs. Control; FCO2L vs. F+P, ** $P < 0.001$; PDL vs. F+P, ** $P < 0.001$). (b) HI was lower in the combined treatment group compared to simple FCO2L or 595-nm PDL group (** $P < 0.001$ vs. Control; FCO2L vs. F+P, ** $P < 0.001$; PDL vs. F+P, ** $P < 0.001$). (c) Decreased AA was noted in the combined treatment group (** $P < 0.001$ vs. Control; FCO2L vs. F+P, ** $P < 0.001$; PDL vs. F+P, ** $P < 0.001$). (d) Lowest NA was seen in the combined treatment group (** $P < 0.001$ vs. Control; FCO2L vs. F+P, ** $P < 0.001$; PDL vs. F+P, ** $P < 0.001$).

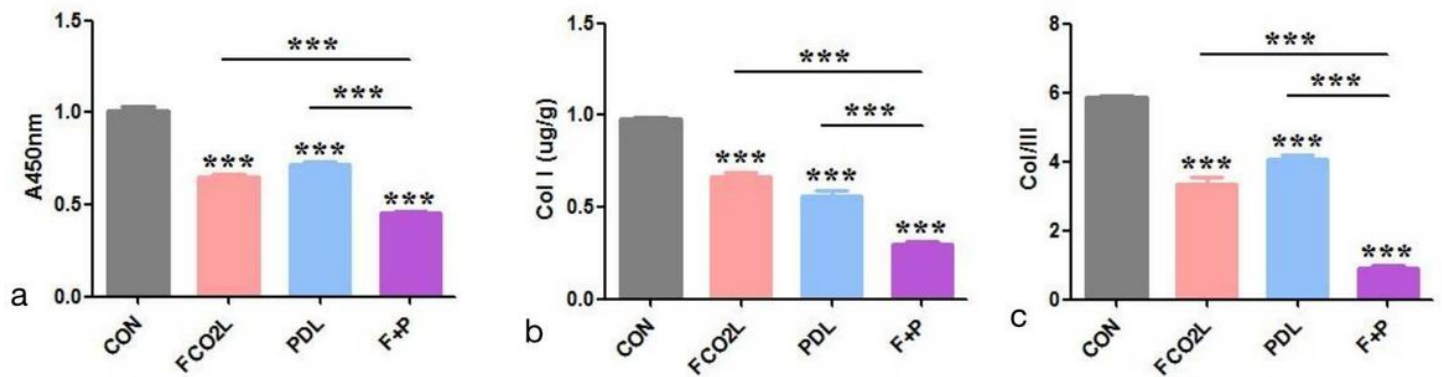


Figure 3

(a) The lowest A450nm value was measured in the combined treatment group compared to other groups(***P<0.001 vs. Control; FCO2L vs. F+P,***P<0.001; PDL vs. F+P, ***P<0.001). (b) The content of Col-I was decreased most in the combined treatment group(***P<0.001 vs. Control; FCO2L vs. F+P,***P<0.001; PDL vs. F+P, ***P<0.001). (c) Significantly reduced the ratio of Col-I and III was seen in the combined treatment group(***P<0.001 vs. Control; FCO2L vs. F+P,***P<0.001; PDL vs. F+P, ***P<0.001).

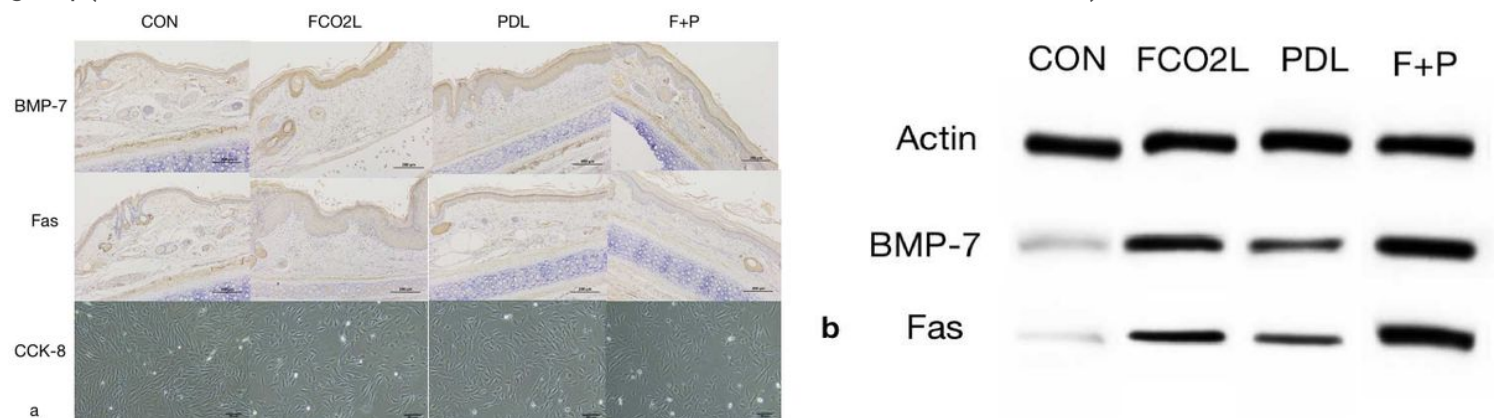


Figure 4

(a) The expression of BMP-7 and Fas proteins and the viability of fibroblasts were both notably decreased in the combination group than that in single treatment groups. (b) Western blot analyses indicated the lowest the expression of BMP-7 and Fas proteins in the combined treatment group.

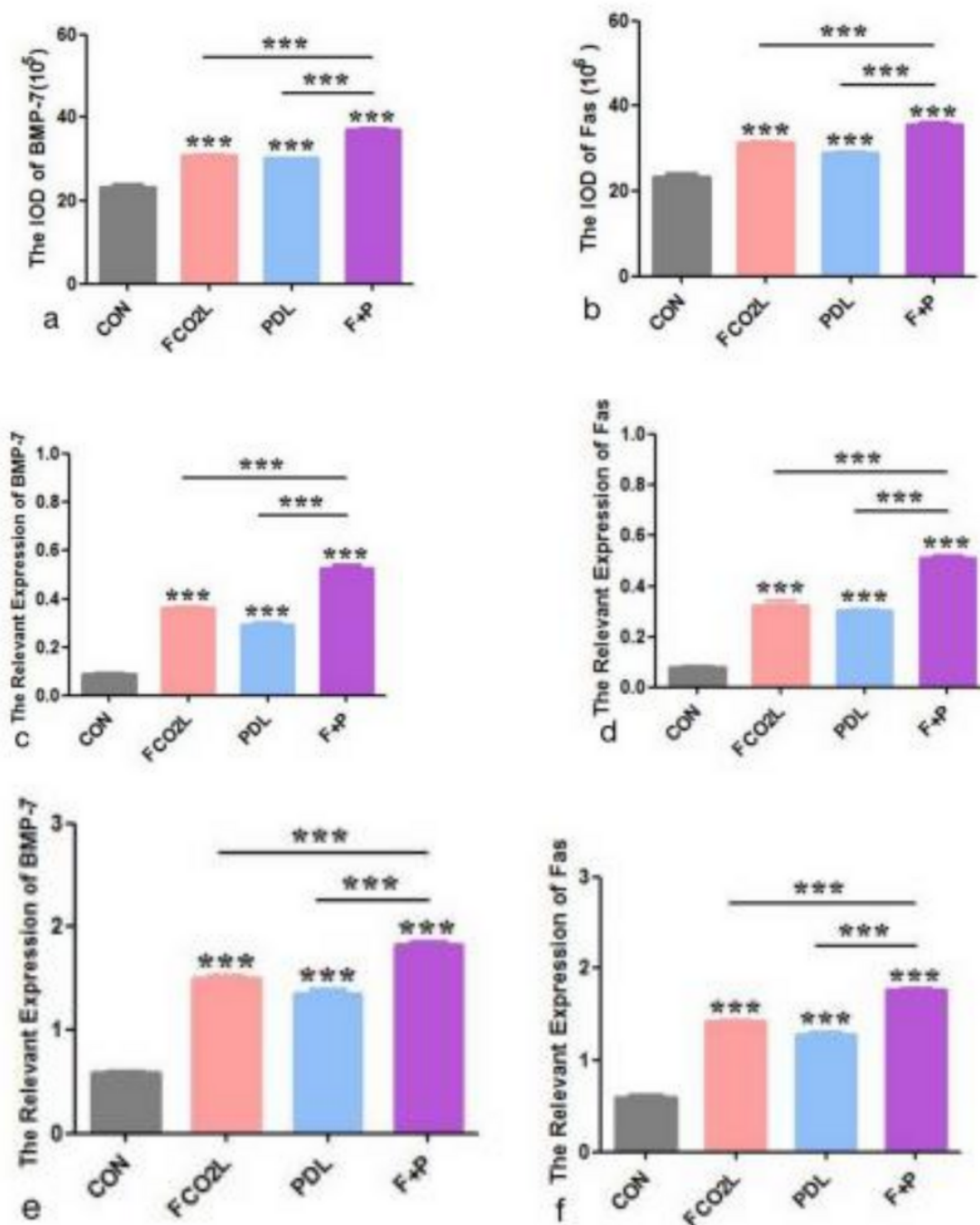


Figure 5

(a) The IOD data of BMP-7 were increased most in the combined treatment group after treatment(***P<0.001 vs. Control; FCO2L vs. F+P,***P<0.001; PDL vs. F+P, ***P<0.001). (b) The IOD data of Fas showed the same trend(***P<0.001 vs. Control; FCO2L vs. F+P,***P<0.001; PDL vs. F+P, ***P<0.001). (c) The relevant expression of BMP-7(WB) was the highest in the combined treatment group(***P<0.001 vs. Control; FCO2L vs. F+P,***P<0.001; PDL vs. F+P, ***P<0.001). (d) Obviously up-regulated relevant expression of Fas (WB) in the combined treatment group(***P<0.001 vs. Control; FCO2L vs. F+P,***P<0.001; PDL vs. F+P, ***P<0.001). (e) Evidently increased relevant expression of BMP-7(RT-PCR) in the combined treatment group(***P<0.001 vs.

Control; FCO2L vs. F+P,***P<0.001; PDL vs. F+P, ***P<0.001). (f) Relevant expression of Fas(RT-PCR) was the highest in the combined group(***P<0.001 vs. Control; FCO2L vs. F+P,***P<0.001; PDL vs. F+P, ***P<0.001).