

# Risk factor analysis and severity assessment of wound hematoma after anterior cervical spine surgery: A retrospective study

Kai Zhou

chongqing medical university

Zhengxue Quan (✉ [walleyezhu@163.com](mailto:walleyezhu@163.com))

Chongqing Medical University

Zhongyuan He

Sun Yat-Sen University

Ke Tang

Chongqing University of Medical Science: Chongqing Medical University

---

## Research article

**Keywords:** wound hematoma, risk factors, hypertension, heparin use, hemostasis

**Posted Date:** December 4th, 2020

**DOI:** <https://doi.org/10.21203/rs.3.rs-120516/v1>

**License:**   This work is licensed under a Creative Commons Attribution 4.0 International License.

[Read Full License](#)

---

# Abstract

## Background

We aim to explore the risk factors independently associated with postoperative wound hematoma in patients who have undergone anterior cervical spine surgery.

## Methods

The clinical data of patients with cervical spondylosis or cervical disc herniation who underwent anterior cervical spine surgery by the senior author from January 2011 to December 2017 were evaluated. Multivariate logistic regression was conducted to compare the hematoma group and the no-hematoma group to determine which factors were independently associated with hematoma formation in patients who need evacuation. The Mann-Whitney U test was conducted to compare the Neck Disability Index score in the two groups.

## Results

A total of 678 patients met the criteria and underwent anterior cervical spine surgery. Thirteen patients undergone hematoma evacuation. Multivariate logistic regression analysis identified that history of hypertension ( $p = 0.039$  OR = 4.42 95% CI 1.08–18.07) and therapeutic heparin use ( $p = 0.020$  OR = 4.58 95% CI 1.27–16.59) were independent risk factors for hematoma formation. The t-test showed no significant differences between the hematoma group and the no-hematoma group in terms of APTT or PT levels ( $p > 0.05$ ). The Mann-Whitney U test indicated that there was no difference in NDI scores between the two groups ( $p > 0.05$ ).

## Conclusion

History of hypertension and therapeutic heparin use are risk factors for hematoma formation. Meticulous hemostasis, moderate muscle subtraction, and perioperative airway management are critical for avoiding hematoma development. The Neck Hematoma Scores can quickly determine the severity of a hematoma in the absence of radiographic image evidence.

## Background

The past decades have seen increasingly rapid advances in the field of anterior cervical spine surgery (ACSS). In 1958, Smith and Robinson first proposed anterior cervical discectomy and fusion (ACDF)[1]. After that, anterior cervical corpectomy and fusion (ACCF) and anterior cervical discectomy and arthroplasty (ACDA) were successively presented. Most clinical studies have confirmed the effectiveness of these procedures [2–4]. Moreover anterior cervical surgery is minimally invasive, the postoperative

effects are good. However, because of the anatomical complexity of the anterior cervical approach, with the presence of many vital structures, complications occasionally occur, among which wound hematoma, dysphagia, and recurrent laryngeal nerve injury are the most common[5].

The development of postoperative wound hematoma is a critical complication in the clinic that needs to be discovered and treated in time. If not handled properly, this complication can cause serious consequences, such as airway compromise and neurological deficit, and it can even be life-threatening. To date, several studies have investigated the risk factors for wound hematoma formation and the results are differ [6–8]. Therefore, the present research explores the effects of risk factors and the bleeding sites of wound hematoma formation, in order to minimize the occurrence of this dangerous complication.

## Methods

This retrospective study consisted of 678 consecutive patients who underwent anterior cervical spine surgery from January 2011 to December 2017. The criteria of inclusion and exclusion were as follows:

### Inclusion criteria

- (1) Patients > 18 years old
- (2) Patients were diagnosed with cervical spondylosis or cervical disc herniation
- (3) Patients with first neck surgery
- (4) Patients with elective surgery.

### Exclusion criteria

- (1) Patients were diagnosed with tumor, trauma, infection, deformity, diffuse idiopathic skeletal hyperostosis (DISH), and ossification of the posterior longitudinal ligament (OPLL)
- (2) Patients with anterior and posterior combined surgery.

There were 355 males and 323 females included in our study. The patient data recorded in a database included: sex, age, preoperative symptoms, surgical procedures, surgical levels, low-level segment (C6/7 segment), operative time, blood loss, body mass index (BMI), preoperative comorbidities (hypertension, diabetes), smoking history, therapeutic heparin usage, activated partial thromboplastin time (APTT) and prothrombin time (PT) examination before and after surgery. All patients underwent careful preoperative neurological examinations, routine blood examinations, coagulation examinations, anterior and lateral cervical X-rays, CT scans with 3-dimensional reconstruction, and cervical MRI examinations. Patients who had taken antiplatelet or anticoagulant agents daily received heparin replacement therapy(Enoxaparin Sodium (CLEXANE) 4000iu qd) until five days prior to surgery. Heparin use was discontinued 12 hours before surgery was performed, and antiplatelet or anticoagulant agents were continued two days after surgery.

All surgeries were performed by the senior author, through the right side of the neck, under general anesthesia and endotracheal intubation. All operations were carried out by the senior surgeon, and hemostasis was performed carefully during the operation. Plate fixation(SKYLINE, SLIMLOC and VENTURE anterior cervical plate system), cages(n-HA/PA66 cage), and autografts were used in all surgeries except ACDA. An artificial disc(Prodisc-C, Prestige LP) was used for ACDA. The hemostatic methods included electrocautery and bipolar electrocautery as well as the use of bone wax, which was used when corpectomy was performed, and hemostatic agents (Surgiflo Ethicon), which were applied in the intervertebral space and longus colli. At the end of the operation, a subfascial drainage tube was placed through a separate stab incision and was removed the next day after surgery. All patients with postoperative wound hematoma were included in the case group, while the remaining patients were included in the control group.

The occurrence of postoperative wound hematoma is critical and develops rapidly, and the radiographic images are often lacking. Therefore, it is important to diagnose hematoma quickly and determine whether evacuation is necessary. We made the Neck Hematoma Scores (NHS) according to the patient's symptoms and signs to better evaluation. (Table 1). Closed observation for less than 3 points, 3 to 5 points suture line remove is suggested, more than 5 points evacuation is necessary.

Table 1  
Neck Hematoma Score(NHS)

Symptom	Neck sign	General	Points
Voice quality changed	Elevated drain output	Restlessness	1
Difficulty breathing	Suture line bleeding	Agitation	2
Inspiratory stridor	Wound swelling	Panic	3
Cyanosis	Tracheal deviation	Somnolence	4
≤3 points: closed observation; 3–5 points: remove suture line; ≥5points: evacuation			

We followed all patients and used Neck disability index (NDI) scores to evaluate postoperative neck function. We divided the NDI scores of all patients into three groups according to the corresponding time the preoperative group, early postoperative group (> 3 mon < 12 mon), and late postoperative group (> 12 mon).

## Statistics

SPSS software version 24.0 was used for statistical analysis. The measurement data in line with a normal distribution were expressed as the mean ± standard deviation, and the rest were expressed as the median (InterQuartile Range); the counting data were expressed as a percentage. Univariate logistic regression analysis was conducted to analyze the risk factors for wound hematoma. Factors of p < 0.05 were added to multivariate logistic regression analysis. Odds ratios (ORs) and 95% confidence intervals

(CIs) were determined when statistically significant differences ( $p < 0.05$ ) were found in multivariate logistic regression. T-tests and Mann-Whitney U tests were employed for other measurement data.

## Results

A total of 678 patients who met the inclusion and exclusion criteria were included in the study. Of these patients (Table 2), 354 were male (52.2%) and 324 were female (47.8%). The patients' ages ranged between 25 and 84 years, with a mean age (of  $53.7 \pm 11.2$ ) years. The BMI ranged between 15.1 and 37.3, with an average of ( $23.7 \pm 2.9$ ). There were 307 cases of radiculopathy (45%), 223 cases of myelopathy (33%), and 148 cases of myeloradiculopathy (22%). There were 305 cases who underwent ACDF (45%), 236 ACCF (35%), 79 ACDA (12%) and 58 who underwent ACDF + ACCF (8%).

Table 2  
Patients' demographic characteristics

Variable	Hematoma group		No-hematoma group		p value
	Mean	SD	Mean	SD	
Age	55.6	9.35	53.6	11.2	<b>0.512</b>
BMI	24.2	2.9	23.7	2.9	<b>0.556</b>
	Median	IQR	Median	IQR	
Operative time(hr)	2.17	1.96–2.67	2.0	1.59–2.5	<b>0.180</b>
Blood loss(ml)	100.0	50.0-150.0	50.0	50.0-100.0	<b>0.414</b>
	N	(%)	N	(%)	
Sex					
Male	10	76.9	344	51.7	-
Female	3	23.1	321	48.3	<b>0.089</b>
Symptom					
Radiculopathy	3	23.1	304	45.7	-
Myelopathy	4	30.8	218	32.9	<b>0.420</b>
Myeloradiculopathy	6	46.1	143	21.5	<b>0.143</b>
Procedure					
ACDF	5	38.5	300	45.2	-
ACCF	5	38.5	231	34.6	<b>0.202</b>
ACDA	2	15.4	77	11.6	<b>0.997</b>
ACDF + ACCF	1	7.6	57	8.6	<b>0.245</b>
Level					
1	4	30.8	222	33.5	-
2	8	61.5	345	51.8	<b>0.683</b>
3	1	7.7	95	14.3	<b>0.629</b>
3+	0	0	3	0.5	-
Comorbidity					

BMI = body mass index; ACDF = anterior cervical discectomy and fusion; ACCF = anterior cervical corpectomy and fusion; ACDA = anterior cervical discectomy and arthroplasty

Variable	Hematoma group		No-hematoma group		p value
History of hypertension	8	61.5	122	18.3	0.001
Diabetes	2	15.4	62	9.3	0.451
Smoking history	6	46.2	211	31.7	0.104
C6/7 segment	4	30.8	236	35.5	0.725
Heparin use	4	30.8	25	3.76	0.000
BMI = body mass index; ACDF = anterior cervical discectomy and fusion; ACCF = anterior cervical corpectomy and fusion; ACDA = anterior cervical discectomy and arthroplasty					

Thirteen cases(1.9%) of hematoma occurred in the study. All patients were graded with NHS and ten patients underwent evacuation (Table 3). The earliest hematoma occurred 1 hour after surgery, and the latest appeared 44 hours after surgery, with a mean time of 11 (2.5–37.5) hours. Evacuation surgery was performed cautiously by senior author through the original incision and hematomas were proved in the surgery. During the wound exploration, bleeding sites were found in some patients as follows: longus colli in 3 patients, the longus colli and omohyoid in 1 patient, the platysma in 2 patients, the drainage stab incision in 2 patients, and the esophageal wall in 1 patient, and 1 patients had no distinct bleeding sites. A gelatin sponge was placed in front of the plate after adequate hemostasis and a rubber drainage tube was placed at the incision.

Table 3  
Hematoma patients

Patient	Gender	Age	Symptom	Procedure	Time to onset(hr)	Hemorrhage site	NHS
1	M	52	Myeloradiculopathy	ACCF C5-C7	5	Longus colli	6
2	M	42	Myelopathy	ACCF C4-C6	33	-	3
3	F	75	Radiculopathy	ACCF C5-C7	26	Longus colli	8
4	F	46	Myeloradiculopathy	ACDA C5-C6	42	Drainage stab incision	6
5	M	60	Myeloradiculopathy	ACCF C3-C5	30	Drainage stab incision	7
6	M	53	Radiculopathy	ACDF C3-C4	44	Esophageal wall	9
7	F	58	Myeloradiculopathy	ACDA C5-C6	11	-	4
8	M	67	Myeloradiculopathy	ACCF C3-C5	5	Platysma	6
9	M	65	Myelopathy	ACCF C4-C6 ACDF C6-C7	3	Longus colli	6
10	M	53	Radiculopathy	ACDF C5-C6	1	Unseen	7
11	M	55	Myelopathy	ACDF C4-C6	2	Platysma	7
12	M	45	Myelopathy	ACDF C5-C6	2	-	4
13	M	52	Myeloradiculopathy	ACDF C5-C7	44	Longus colli and omohyoid	6
NHS indicates Neck Hematoma Score.							

## Risk factor analysis

Univariate logistic regression analysis showed that heparin usage ( $p < 0.001$ ), and history of hypertension ( $p = 0.001$ ) met the criteria for multivariate logistic regression ( $p < 0.05$ ). The results showed that history of hypertension ( $p = 0.039$  OR = 4.42 95% CI 1.08–18.07) and therapeutic heparin use ( $p = 0.020$  OR = 4.58 95% CI 1.27–16.59) were statistically significant, and were independent risk factors for hematoma



development (Fig. 1). Sex ( $p = 0.089$ ) was a possible risk factor but was not statistically significant. There was no significance difference in age, BMI, symptoms, surgical procedures, operative time, surgical level, low-level segment (C6/7 segment), diabetes, or smoking history.

All patients underwent examinations for activated partial thromboplastin time (APTT) and prothrombin time (PT) before the operation and immediately after operation. A t-test was conducted, and the results showed no significant differences between the hematoma group and the no-hematoma group (Figs. 2–3).

## Clinical outcome

Neck Disability Index (NDI) scores were recorded to compare the two postoperative times between the hematoma group and the non-hematoma group. The early follow-up time was 3–12 months; and the late follow-up time was > 12 months. A Mann-Whitney U test was conducted, and there was no significant difference (Fig. 4).

## Discussion

ACSS is commonly used and widely recognized by spine surgeons. Hematomas formation, however, is the most problematic and devastating complication, and cannot be overemphasized. An initial objective of the study was to identify risk factors that would lead to hematoma formation and to detect hematoma quickly.

The incidence of hematoma was 1.9% in our study, which is in accordance with previous reports (0.2–2.4%)[5, 6, 9, 10]. History of hypertension was a risk factor for hematoma formation, and this finding was consistent with that of Palumbo, who mentioned that the surgical stress reaction and anesthesia could cause increased arterial blood pressure, especially in hypertensive patients[11]. Patient 10 in our study had a hematoma after 1 hour in the postanesthesia care unit (PACU) during extubation(Fig. 5). Coughing during extubation can cause increased venous blood pressure, leading to the occurrence of hematoma. Poor perioperative blood pressure control will significantly increase the incidence of hematoma[12]. Patient 8 had a history of chronic pharyngitis, and severe cough after surgery may have resulted in hematoma formation. Therefore, perioperative airway management is also essential.

O'Neill's study concluded that therapeutic heparin usage was a risk factor for hematoma formation, which is in line with the results of our study. But he did not discuss it much, especially in terms of timing and dosage[10]. In our study, all patients who received heparin replacement therapy discontinued heparin until 12 hours before surgery and continued 2 days after surgery. All hematomas occurred within 48 hours, and a possible explanation for this might be that the leading cause of hematoma formation is the preoperative use of heparin. Perhaps the time of withdrawal of heparin should be advanced and the preoperative monitoring of heparin dosage is also important.

The NHS was based on our clinical experience and analysis of recent literature. Patient 10 is diagnosed with hematoma formation in 5 minutes by using NHS, and the total is 7 points(difficulty breathing (2

points), wound swelling (3 points), agitation (2 points)). The picture is taken in the operation room prior to the hematoma evacuation and Consent was obtained from the patient for publication.

Due to anticoagulants will effect APTT and PT levels. Therefore the preoperative and postoperative APTT and PT outcomes were collected from all the patients and differences were compared. The results showed no statistical significance.

Many studies have suggested that ossification of the posterior longitudinal ligament (OPLL) and diffuse idiopathic skeletal hyperostosis (DISH) are risk factors for hematoma formation[10, 13]. It is known that meticulous hemostasis is a crucial procedure for preventing hematoma formation[5, 10, 14]. Compared with general cervical spondylopathy surgery, however, OPLL and DISH surgeries are relatively involved and require higher levels of surgical skills[15, 16, 17]. Hence, we did not include this type of surgery in our study.

Nine patients were found to have specific hemorrhage sites during the evacuation procedure. Several studies have reported on the site of hemorrhage, but most have not reported distinct bleeding points during the wound exploration. Nambu concluded that the hemorrhage site during postoperative neck surgery mostly occurred on the muscle surface, and excessive muscle subtraction and too much blunt dissection may be the causes of bleeding[18]. The feeding vessels of the vertebral body are often found on the ventral side of the longus colli. Thus, the stretcher or retractor should be placed on the superficial surface of the longus colli. Kunkel found 1 case where the hematoma bleeding site was platysma[12]. Therefore, more attention should be paid to the hemostasis of the longus colli, platysma, and drainage stab incision. Bipolar electrocautery is indispensable and can achieve sufficient hemostasis.

Two patients developed hematoma after drainage removal, and the bleeding site was found at drainage stab point. At present, an increasing number of reports have tended to indicate that the use of drainage cannot prevent the occurrence of hematoma. In contrast, the use of drainage may increase the risk of hematoma formation during removal[10, 19, 20, 21]. These views are consistent with our results, and it is still controversial whether the use of drainage is necessary.

Our study also found that 6 cases of hematoma occurred within 12 hours, and 6 cases of hematoma occurred within 24–48 hours. Monika indicated that hematomas usually occurred within 6–12 hours after surgery[22]. Song mentioned that 67% of hematomas occurred within 24 hours, and the remaining cases occurred within 72 hours[23]. Understanding the timing of hematoma occurrence is valuable to improve the hematoma prevention and management.

Our findings may be somewhat limited by the lack of radiographic image of hematoma and small sample size to validate the Neck Hematoma Score. The application of heparin dose and preoperative blood pressure should be further quantified. The inclusion and exclusion criteria were strictly controlled to exclude confounding factors, but the occurrence of hematoma was still affected by some subjective factors. Therefore, we tried to obtain objective, independent risk factors through this study, and a large sample and multicenter study is still needed in the future.

# Conclusion

ACSS is prevalent for treating cervical spine diseases, and postoperative wound hematoma is a severe complication, with a low incidence but with fatal consequences. Our study demonstrates that history of hypertension and therapeutic heparin use are risk factors for hematoma formation. Meticulous hemostasis, moderate muscle subtraction, and perioperative airway management are also crucial for avoiding hematoma development. Hematoma often occurs within 48 hours, especially within 12 hours, so more attention should be given during this time. The Neck Hematoma Scores can quickly determine the severity of a hematoma in the absence of radiographic image evidence and instruct whether evacuation is necessary.

# Abbreviations

ACSS

anterior cervical spine surgery

ACDF

anterior cervical discectomy and fusion

ACCF

anterior cervical corpectomy and fusion

ACDA

anterior cervical discectomy and arthroplasty

ACAF

anterior controllable antedisplacement fusion

NDI

neck disability index

APTT

activated partial thromboplastin time

PT

prothrombin time

OPLL

ossification of the posterior longitudinal ligament

DISH

diffuse idiopathic skeletal hyperostosis

BMI

body mass index

# Declarations

*Ethics approval and consent to participate*

This study is a retrospective clinical study and has approved by The First Hospital of Chongqing Medical University Ethics Committee. All patients had signed the consent form.

### ***Consent for publication***

Written informed consent for publication was obtained from all participants.

### ***Availability of data and materials***

The data is available from the corresponding author on reasonable request.

### ***Competing interests***

There are no known conflicts of interest associated with this publication.

### ***Funding***

This study did not receive funding support.

### ***Authors' contributions***

KZ and ZH collected the data. KZ analyzed the data and wrote the manuscript. ZQ and KT contributed to the study design. ZQ, KT, ZH and KZ performed the surgery. All authors read and approved the final manuscript.

### ***Acknowledgements***

Not applicable.

## **References**

- [1] Smith GW, Robinson RA. The treatment of certain cervical-spine disorders by anterior removal of the intervertebral disc and interbody fusion. J Bone Joint Surg Am.1958;40-A:607-24.
- [2] Emery SE, Bohlman HH, Bolesta MJ, Jones PK. Anterior cervical decompression and arthrodesis for the treatment of cervical spondylotic myelopathy: Two to seventeen-year follow-up. J Bone Joint Surg Am.1989;80A: 941-51.
- [3] Sasso RC, Anderson PA, Riew KD, J G Heller. Results of cervical arthroplasty compared with anterior discectomy and fusion: four-year clinical outcomes in a prospective, randomized controlled trial. J Bone Joint Surg Am.2011;93(18): 1684-1692.
- [4] Song KJ, Choi BW, Lee DH, Dong-Hyun Lee, Dong-Ju Lim, Seung-Yeol Oh, Sung-Soo Kim. Acute airway obstruction due to postoperative retropharyngeal hematoma after anterior cervical fusion: A retrospective analysis. J Orthop Surg Res.2017;12:19.

- [5] Kostas N. Fountas, Eftychia Z. Kapsalaki, Leonidas G Nikolakakos, Hugh F Smisson, Kim W Johnston, Arthur A Grigorian, Gregory P Lee, Joe S Robinson Jr. Anterior Cervical Discectomy and Fusion Associated Complications. *SPINE*.2007;32;21;2310–2317.
- [6] Esther Quick,1 M.B., B.S. and Roger W. Byard, M.D. Postoperative Cervical Soft Tissue Hemorrhage with Acute Upper Airway Obstruction *J Forensic Sci*.2013;58 264-266.
- [7] Sethi R, Tandon MS, Ganjoo P. Neck hematoma causing acute airway and hemodynamic compromise after anterior cervical spine surgery . *J Neurosurg Anesthesiol*.2011;20 : 69-70.
- [8] Yu NH , Jahng TA , Kim CH , Chun Kee Chung. Life-threatening late hemorrhage due to superior thyroid artery dissection after anterior cervical discectomy and fusion . *Spine*.2010;35;E739 – 42.
- [9] Bertalanffy H, Eggert HR. Complications of anterior cervical discectomy without fusion in 450 consecutive patients. *Acta neurochirurgica*.1989;99(1-2):41-50.
- [10] O'Neill KR, Neuman B, Peters C, Riew KD. Risk factors for postoperative retropharyngeal hematoma after anterior cervical spine surgery. *Spine*.2014;39(4):E246-52.
- [11] Palumbo MA, Aidlen JP, Daniels AH, Bianco A, Caiati JM. Airway compromise due to laryngopharyngeal edema after anterior cervical spine surgery. *Journal of clinical anesthesia*. 2013;25(1):66-72.
- [12] Kunkel J, James M E. Gomer, M J Spebar, R J Delgado, B S Jarstfer, G J Collins. Wound Hematomas After Carotid Endarterectomy. *The American Journal of Surgery*.1984;148;844-846.
- [13] Feng Yu Liu, Li Shuang Huo. Prevalence of hematoma after anterior cervical spine surgery: a meta-analysis. *International Journal of Clinical and Experimental Medicine*.2017;10; 15937-15949.
- [14] Tasiou A, Giannis T, Brotis AG, Siasios I, Georgiadis I, Gatos H. Anterior cervical spine surgery-associated complications in a retrospective case-control study. *Journal of spine surgery (Hong Kong)*.2017;3(3):444-59.
- [15] David N Bernstein; Michelle Prong, Etka Kurucan ,Amit Jain, Emmanuel N Menga ,K Daniel Riew, Addisu Mesfin. National Trends and Complications in the Surgical Management of Ossification of the Posterior Longitudinal Ligament (OPLL). *Spine (Phila Pa 1976)*.2019;15;44(22):1550-1557.
- [16] Masashi Yamazaki, Akihiko Okawa, Takayuki Fujiyoshi, Junko Kawabe, Takeo Furuya, Tamiyo Kon, Masao Koda. Intraoperative Spinal Subarachnoid Hematoma in a Patient With Cervical Ossification of the Posterior Longitudinal Ligament. *Spine*.2011;35;359-362.
- [17] Ryoji Tsuchida, Shiro Imaizumi, Kotaro Satake, Toshiki Iwase, Naoki Ishiguro. Epidural Hematoma Associated with Spinal Fracture in Diffuse Idiopathic Skeletal Hyperostosis. *Turkish Neurosurgery*.2014;24;98-101.

- [18] Nambu J, Keizo Sugino.Characteristics of Postoperative Bleeding after Neck Surgery. *Surgical Science*.2013;4, 192-195.
- [19] Bryce A. Basques, Daniel D. Bohl, Nicholas S Golinvaux, Alem Yacob, Arya G Varthi, Jonathan N Grauer. Factors Predictive of Increased Surgical Drain Output After Anterior Cervical Discectomy and Fusion. *SPINE*.2014;39;728-735.
- [20] Kazunari Kogure,Yoji Node, Tomonori Tamaki, Michio Yamazaki, Ichiro Takumi, Akio Morita. Indwelling Drains Are Not Necessary for Patients Undergoing One-level Anterior Cervical Fixation Surgery. *Journal of Nippon Medical School*.2015;82;124-129.
- [21] Woods RS, Woods JF, Duignan ES, Timon C. Systematic review and meta-analysis of wound drains after thyroid surgery. *The British journal of surgery*.2014;101(5):446-56.
- [22] Monika P, John F, Soobin Kang. Acute post-operative airway complications following anterior cervical spine surgery and the role for cricothyrotomy. *Journal of Spine Surgery*.2019;5;142-154.
- [23] Jiang L, Tan M, Dong L, Liang Dong, Feng Yang, Ping Yi, Xiangsheng Tang, Qingying Hao. Comparison of Anterior Decompression and Fusion With Posterior Laminoplasty for Multilevel Cervical Compressive Myelopathy: A Systematic Review and Meta. *J Spinal Disord Tech*.2015;28(8): 282-290.
- [24] Michael A. Rosenbaum, Manjunath Haridas. Life-threatening neck hematoma complicating thyroid and parathyroid surgery. *The American Journal of Surgery*.2008;195;339-343.
- [25] Tew JM, Mayfield FH.Complications of surgery of the anterior cervical spine. *Clin Neurosurg*.1976;23: 424-34.
- [26] Thakur NA, McDonnell M, Paller D, Palumbo M. Wound hematoma after anterior cervical spine surgery: in vitro study of the pathophysiology of airway obstruction. *Am J Orthop (Belle Mead NJ)*.2013;42(6):E35–7.
- [27] Weiliang. Miao, Xiaojun. Ma, Deyong Liang, Yu Sun. Treatment of hematomas after anterior cervical spine surgery: A retrospective study of 15 cases. 2017;*Neurochirurgie* 8-12.
- [28] Pieter Noordzij J., MAJ, MC, USAF. Airway compromise caused by hematoma after thyroid fine-needle aspiration. *American Journal of Otolaryngology*.2005;26;398-399.
- [29] Yi S, Yoon DH, Kim KN, Kim SH, Shin HC. Postoperative spinal epidural hematoma: risk factor and clinical outcome. *Yonsei Med J*.2006;47(3): 326–32.
- [30] Marotta N, Landi A, Tarantino R, Mancarella C, Ruggeri A, Delfini R. Five-year outcome of stand-alone fusion using carbon cages in cervical disc arthrosis. *Eur Spine J*.2011;20;1;S8- 12.

[31] Kai Zhou, Zhongyuan He, Ke Tang, Zhengxue Quan. Wound hematoma after anterior cervical spine surgery: A retrospective study of risk factor analysis. 07 Jan, 2020, PREPRINT available at Research Square. DOI:10.21203/rs.2.20210/v1.

Tables

Table1. Neck Hematoma Score(NHS)			
Symptom	Neck sign	General	Points
Voice quality changed	Elevated drain output	Restlessness	1
Difficulty breathing	Suture line bleeding	Agitation	2
Inspiratory stridor	Wound swelling	Panic	3
Cyanosis	Tracheal deviation	Somnolence	4
≤3 points: closed observation; 3-5 points: remove suture line; ≥5points: evacuation			

<b>Table 2.</b> Patients' demographic characteristics					
Variable	Hematoma group		No-hematoma group		p value
	Mean	SD	Mean	SD	
Age	55.6	9.35	53.6	11.2	<b>0.512</b>
BMI	24.2	2.9	23.7	2.9	<b>0.556</b>
	Median	IQR	Median	IQR	
Operative time(hr)	2.17	1.96-2.67	2.0	1.59-2.5	<b>0.180</b>
Blood loss(ml)	100.0	50.0-150.0	50.0	50.0-100.0	<b>0.414</b>
	N	%	N	%	
Sex					
Male	10	76.9	344	51.7	-
Female	3	23.1	321	48.3	<b>0.089</b>
Symptom					
Radiculopathy	3	23.1	304	45.7	-
Myelopathy	4	30.8	218	32.9	<b>0.420</b>
Myeloradiculopathy	6	46.1	143	21.5	<b>0.143</b>
Procedure					
ACDF	5	38.5	300	45.2	-
ACCF	5	38.5	231	34.6	<b>0.202</b>
ACDA	2	15.4	77	11.6	<b>0.997</b>
ACDF+ACCF	1	7.6	57	8.6	<b>0.245</b>
Level					
1	4	30.8	222	33.5	-
2	8	61.5	345	51.8	<b>0.683</b>
3	1	7.7	95	14.3	<b>0.629</b>
3+	0	0	3	0.5	-
Comorbidity					
History of hypertension	8	61.5	122	18.3	<b>0.001</b>
Diabetes	2	15.4	62	9.3	<b>0.451</b>



Smoking history	6	46.2	211	31.7	<b>0.104</b>
C6/7 segment	4	30.8	236	35.5	<b>0.725</b>
Heparin use	4	30.8	25	3.76	<b>0.000</b>

BMI= body mass index; ACDF= anterior cervical discectomy and fusion; ACCF= anterior cervical corpectomy and fusion; ACDA= anterior cervical discectomy and arthroplasty

Table 3. Hematoma patients								
Patient	Gender	Age	Symptom	Procedure	Time to onset(hr)	Hemorrhage site	NHS	
1	M	52	Myeloradiculopathy	ACCF C5-C7	5	Longus colli	6	
2	M	42	Myelopathy	ACCF C4-C6	33	-	3	
3	F	75	Radiculopathy	ACCF C5-C7	26	Longus colli	8	
4	F	46	Myeloradiculopathy	ACDA C5-C6	42	Drainage stab incision	6	
5	M	60	Myeloradiculopathy	ACCF C3-C5	30	Drainage stab incision	7	
6	M	53	Radiculopathy	ACDF C3-C4	44	Esophageal wall	9	
7	F	58	Myeloradiculopathy	ACDA C5-C6	11	-	4	
8	M	67	Myeloradiculopathy	ACCF C3-C5	5	Platysma	6	
9	M	65	Myelopathy	ACCF C4-C6 ACDF C6-C7	3	Longus colli	6	
10	M	53	Radiculopathy	ACDF C5-C6	1	Unseen	7	
11	M	55	Myelopathy	ACDF C4-C6	2	Platysma	7	
12	M	45	Myelopathy	ACDF C5-C6	2	-	4	
13	M	52	Myeloradiculopathy	ACDF C5-C7	44	Longus colli and omohyoid	6	
NHS indicates Neck Hematoma Score.								

## Figures

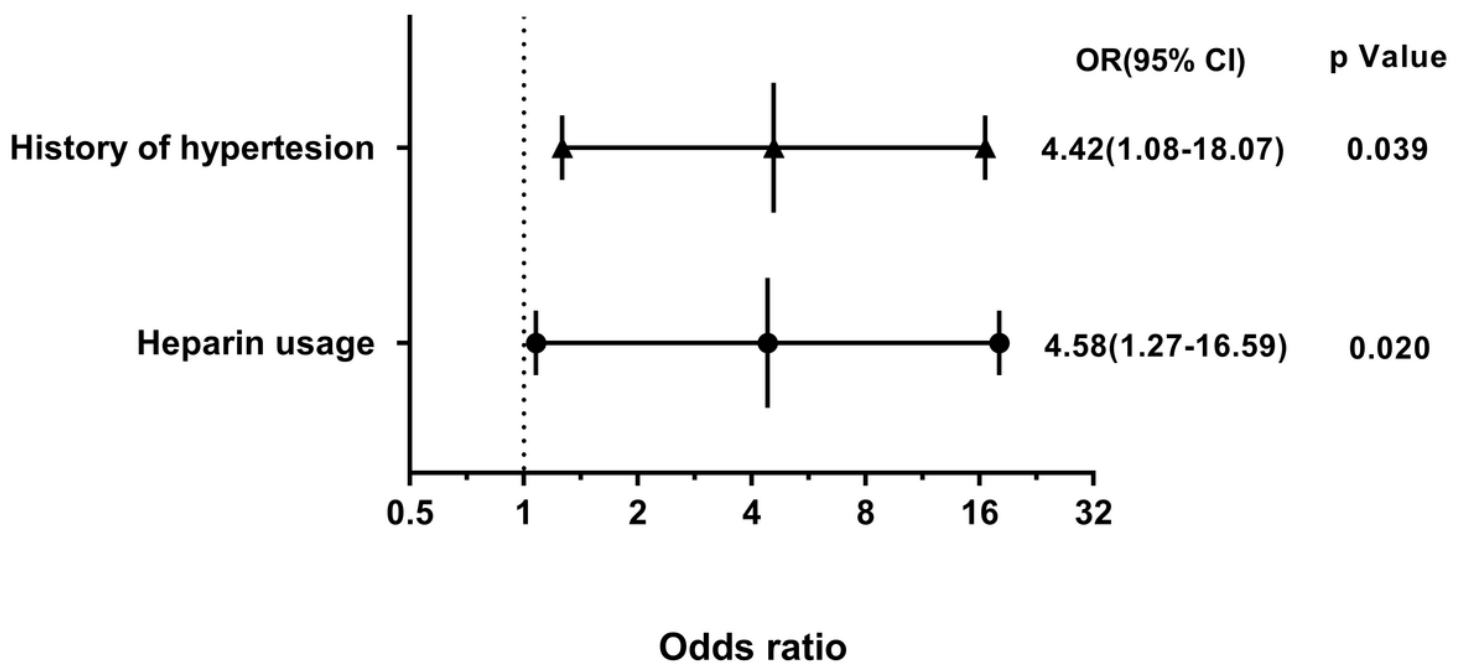
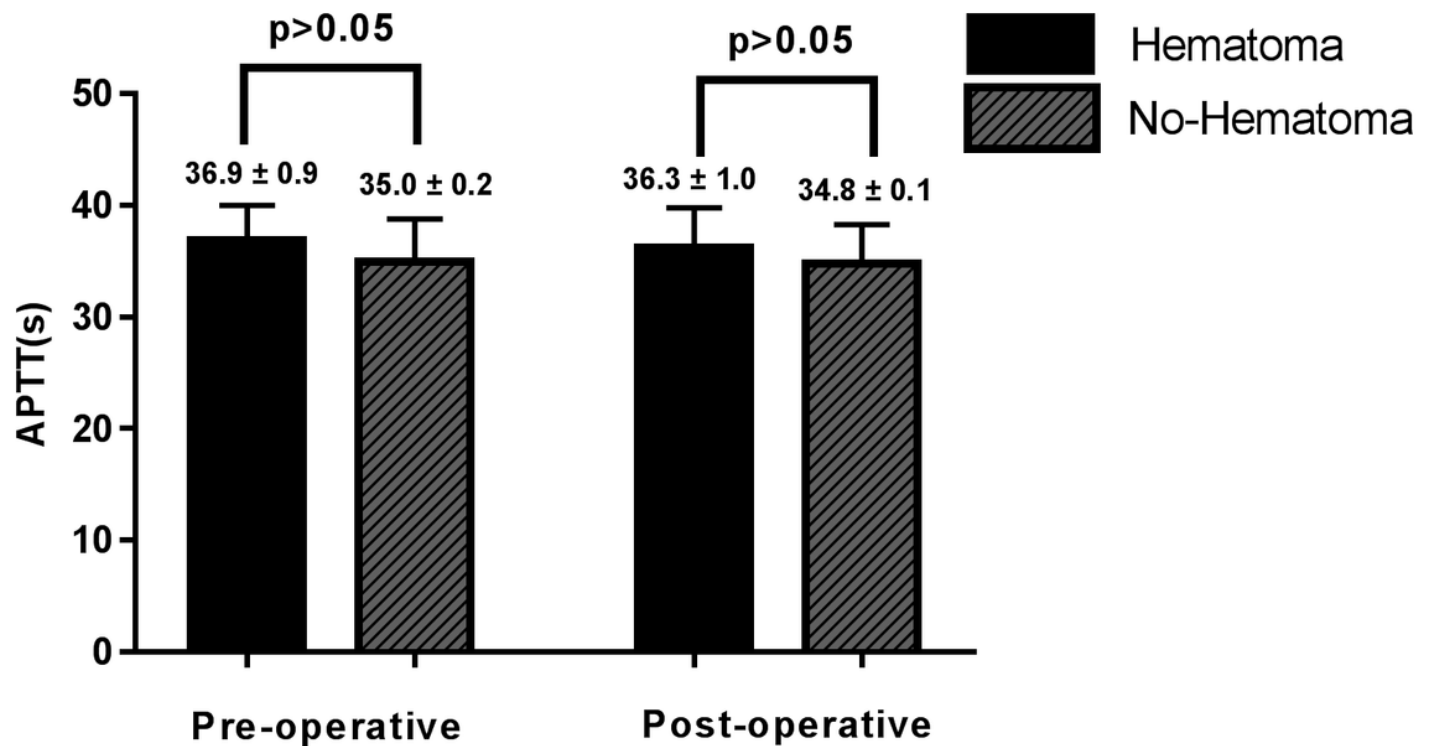


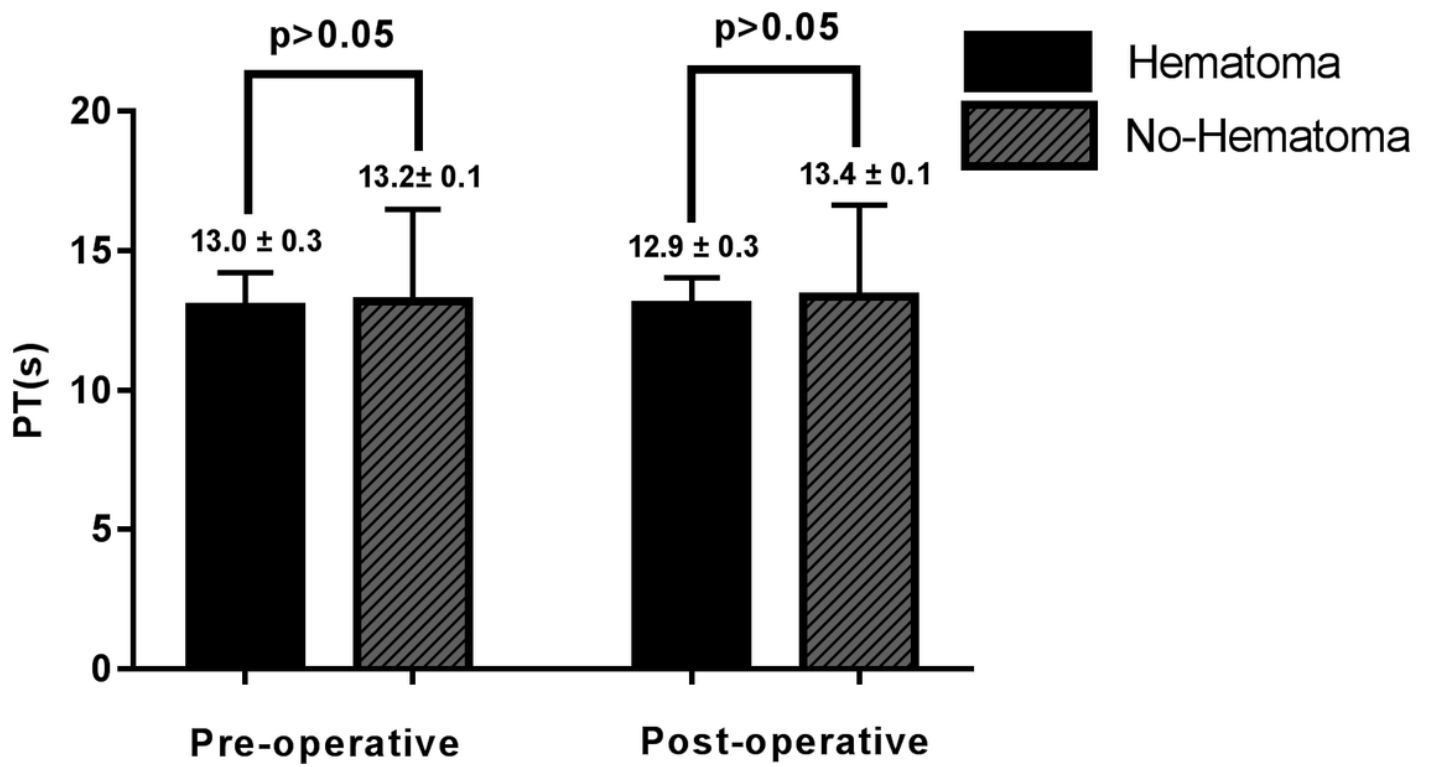
Figure 1

The multivariate logistic regression result shows that history of hypertension and therapeutic heparin use are statistically significant( $p < 0.05$ ).



**Figure 2**

No statistically significant differences were found in APTT and PT levels between two groups at either time point( $p>0.05$ ).



**Figure 3**

No statistically significant differences were found in APTT and PT levels between two groups at either time point( $p>0.05$ ).

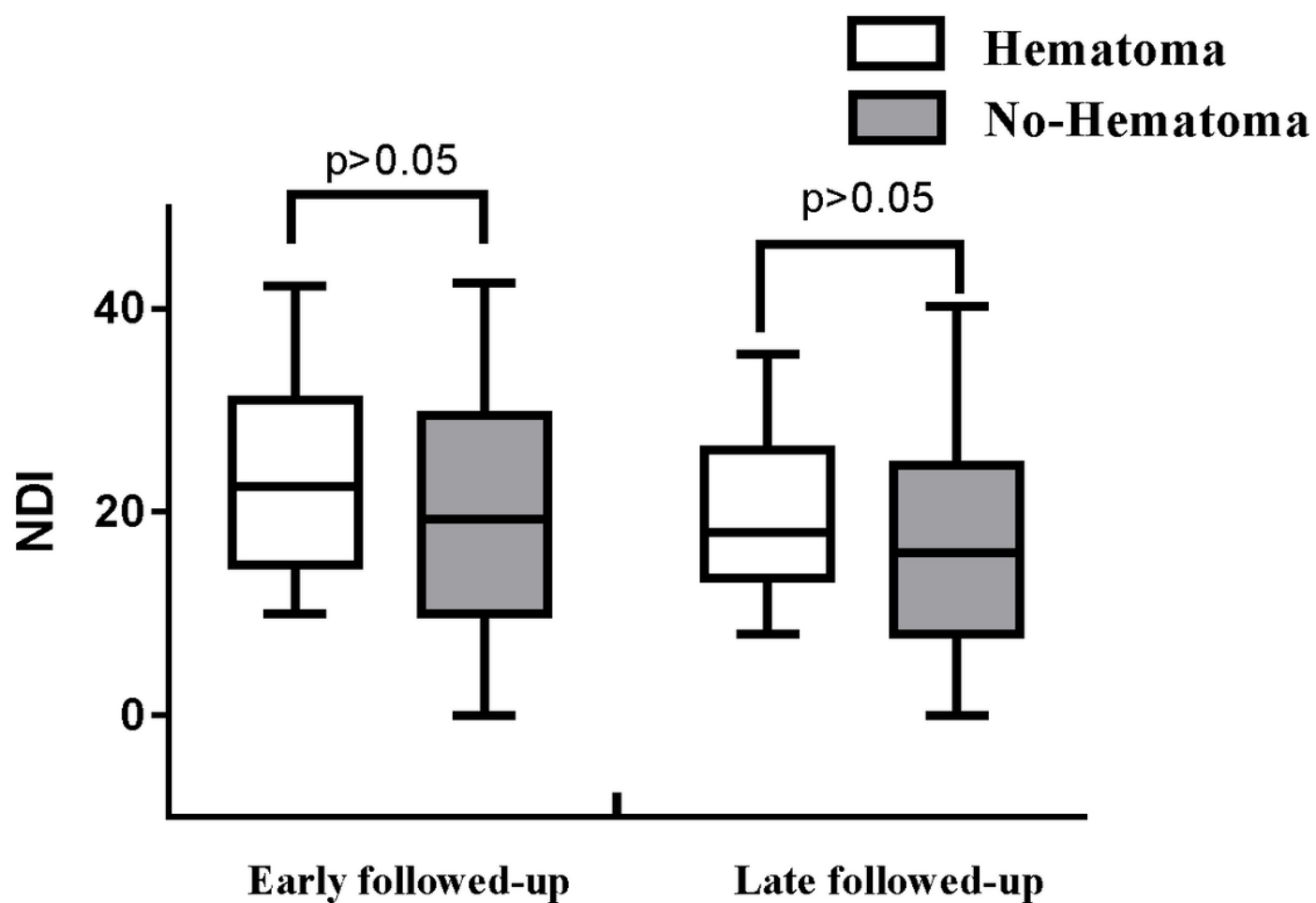
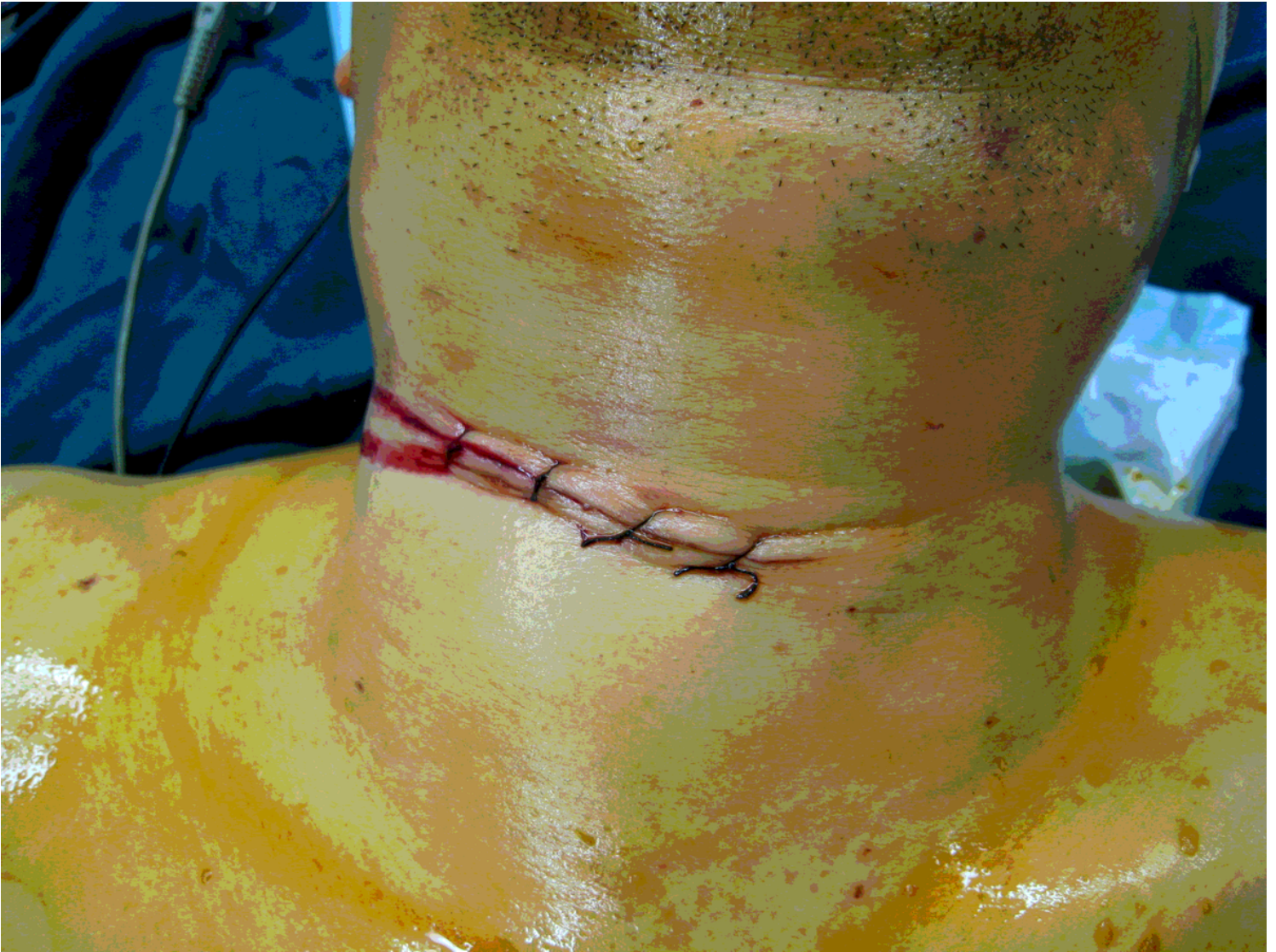

Figure 4

Nonparametric test found that the difference has no statistically significant in NDI scores between two group at either time point( $p > 0.05$ ).



**Figure 5**

Patient 10 has a history of hypertension and chronic pharyngitis. The NHS total is 7(difficulty breathing (2 points), wound swelling (3 points), agitation (2 points)). The picture is taken in the operation room prior to the hematoma evacuation.